

## The Anterior Less Invasive Approach to the Hip Joint (LISA)-Technical Description for Treatment in the Elderly for Hip Endoprosthesis after Femoral Neck Fracture

A. Paech, F. Renken, M. Brahm, A.P. Schulz, S. Hillbricht and Ch. Jürgens  
Department of Traumatology, University Hospital Schleswig Holstein, Campus Lübeck,  
Ratzeburger Allee 160, D-23538 Lübeck, Germany

**Abstract:** Minimally invasive Total Hip Arthroplasty (THA) aims at reduction of tissue damage to accelerate recovery. The anterior approach promises optimal soft tissue preservation. The anterior minimal-invasive approach used in his study consists of a modified Smith-Petersen-Approach. In order to reduce the morbidity rate, a standardised use of minimally invasive surgical approach has been evaluated in endoprosthetic surgery of geriatric patients. Aim of this study is to present a minimal-invasive approach to the hip joint (modified Smith-Petersen-Approach) as a standard in geriatric hip fracture endoprosthesis under the aspect of approach morbidity reduction.

**Key words:** Anterior, LISA, hip joint, hip endoprosthesis, femoral neck fracture

### INTRODUCTION

The incidence of proximal fractures of the femur is steadily increasing and its treatment has acquired a very high therapeutic significance. The recovery of autonomous mobility and quality of life is at the same time enormously affected by the complexity of the fracture. Medial femoral neck fractures type Garden 3 and 4, especially in elderly patients with several concomitant disorders, ought to be taken care of in a definite considerate way. Treatment should allow a prompt postoperative mobilisation under full weight bearing. Therefore, endoprosthetic surgery represents a good alternative in the treatment of this group of patients (Wagner, 1978). The choice is either a bipolar hip prosthesis or a total hip femoral prosthesis according to bone structure and quality in geriatric patients. With a high grade of activity also an alternative is the primarily press fit implantation.

With the significantly larger range of motion using diameter 32 or 36 head with corresponding diameter of the inlays and slender conus the total hip prosthesis obtains nearly the non-luxation security of a bipolar hip prosthesis.

In order to reduce the morbidity rate, a standardised use of minimally invasive surgical approach has been evaluated in endoprosthetic surgery of geriatric patients. Aim of this study is to present a minimal-invasive approach to the hip joint (modified Smith-Petersen-Approach) as a standard in geriatric hip fracture endoprosthesis under the aspect of approach morbidity reduction.

### THE SURGICAL APPROACH

Minimally invasive Total Hip Arthroplasty (THA) aims at reduction of tissue damage to accelerate recovery. The anterior approach promises optimal soft tissue preservation.

The anterior minimal-invasive approach used in his study consists of a modified Smith-Petersen-Approach:

The patient is positioned supine. A surgical arm table is installed on the contra-lateral side of the operation table. This way the not affected leg may be abducted to a maximum position, which is essential for exposition of the affected leg (Fig. 1 a,b).

The incision starts two transverse fingers below and laterally of the spina iliaca anterior superior and follows the anteromedial portion of the muscle belly of the M. tensor fascia lata. The incision length of initially 8 cm may be extended if required.

Using this kind of approach the main trunk of lateral femoral cutaneous nerve is usually neither visible nor affected (Fig. 2 a-c).

In the following after longitudinal incision of the muscle fascia one is able to prepare digitally forward through to the front part of the joint capsule. Through this the N. cutaneus femoris lateralis is also prevented from damage. Subsequently the front part of the joint capsule is demonstrated by pushing the M. rectus femoris in a medial and the Mm. gluteus medius et minimus in a lateral direction (Fig. 3 a-f).

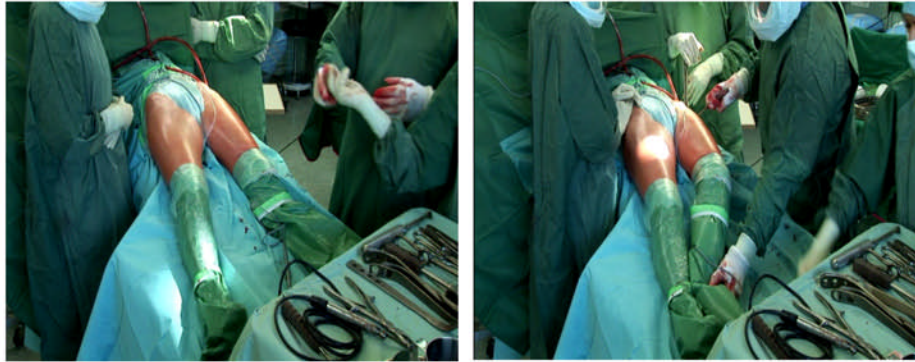


Fig. 1a-b: Patient positioning ( maximal adduction and 20° hyperextension)

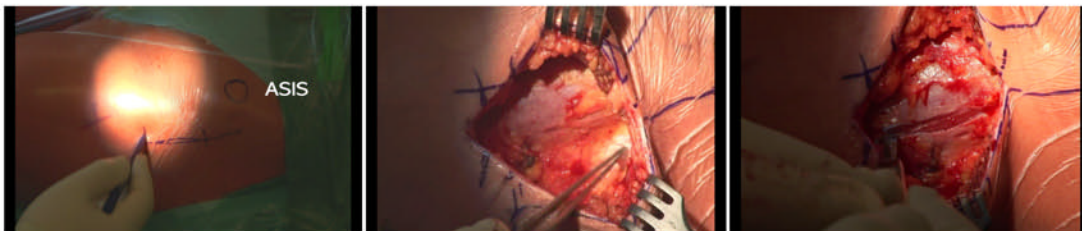


Fig. 2 a-c: Incision, splitting of fascia lata, ASIS= ant. sup. iliaca spine

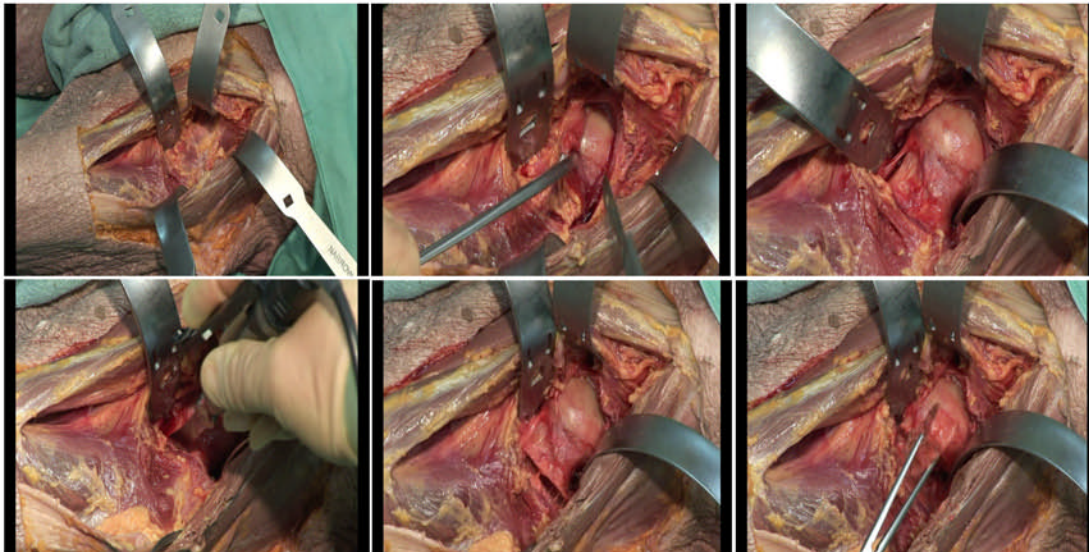


Fig. 3 a-f: Illustration of ventral capsule and double osteotomy as demonstrated in a cadaver preparation

The ascending branch of the circumflexa femoris artery with the concomitant veins, which show in the distal part of the wound are coagulated or better ligated. Now specifically double bended Homan-retractors are to be placed between joint capsule and M. psoas on the medial part and M. gluteus minimus on the lateral part

onto the femoral neck. Another Homan-retractor is placed onto the forward edge of the acetabulum medially of the M. rectus femoris. After a t-shaped athrotomy and resection of joint capsule the collateral Homan-retractors are positioned around the osseous part of the femoral neck.

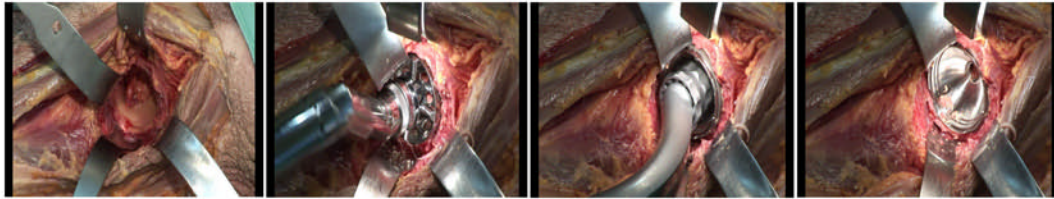


Fig. 4 a-d: Socket reaming and implantation of the trident socket “press-fit”

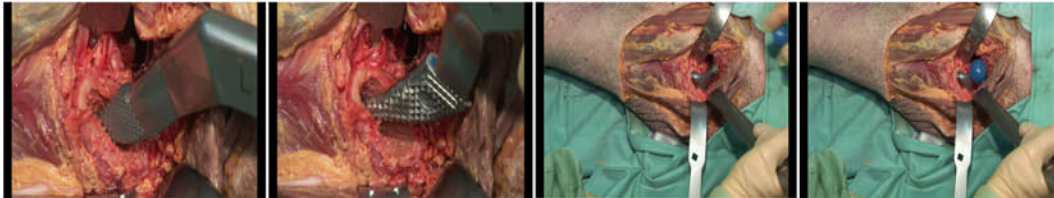


Fig. 5 a-d: Preparation of medullary cavity and implantation of femoral shaft in corpse preparation

The transition from the femoral neck to Trochanter major is exposed carefully, since from here the femoral neck osteotomy is accomplished in typical 45° position as double osteotomy. By this the resection of the femoral head is much easier after removing the bone slice.

One of the human retractors is left on the ventral rim of the acetabulum, three others are placed medially laterally and posterior of the acetabulum rim. The femur is pushed in a dorsal direction by the caudal posterior human retractor. Through this one achieves a very good exposition of the acetabulum. The socket reaming is done with a purpose built offset handle, which is used under protection of the human retractors (Fig. 4 a-d). The implantation of the hip socket is also done with an offset handle (Rachbauer and Noger, 2004; Rachbauer *et al.*, 2004).

The use approach allows both an unproblematic cementless, as well as a cemented socket implantation. Is a bipolar hip endoprosthesis to be implanted, a sparing resection of the left capsule and bone may be carried out.

Subsequently the femoral shaft is prepared. Therefore the femur is externally rotated and adducted to a maximum extend and the operation table may be tilted 20 degrees.

In order to expose the femur it is lifted with a hook positioned at the calcar femoris. This position is held by a specific double spiked retractor, which is placed inbetween greater trochanter and the glutei medius et minimus muscles.

If this maneuver cannot be accomplished satisfactory due to contractures, a dorsal capsule release has to be performed (Berger, 2004; Rachbauer and Nogler, 2004; Rachbauer *et al.*, 2004). Rarely an additional detachment of the M. piriformis is required. After adduction of the leg the femoral medullary cavity is rasped with special offset raffle reamers (Fig. 5 a-d).

After implantation of the stem a probe reposition with comparison of leg length is done. When using a bipolar hip endoprosthesis the head is placed into the acetabulum before reposition and is coupled with a corresponding metal head in situ. This procedure is in our experience out to be much more soft tissue caring than external coupling and reposition.

A test reposition, with leg length- and movement check can also be done using stem raffles. Corresponding trial heads in several lengths are also advantageous when implanting a bipolar endoprosthesis.

Wound closure is done after the definite reposition and adequate lavage, coagulation and redon drainage insertion. The fascia latae is sutured tightly and after subcutaneous suture a continuous subcuticular suture may be performed. Finally an elastic bandage is applied. We use single shot antibiotics perioperatively and low molecular heparin for 4 weeks.

## DISCUSSION

The results of our first experiences with fracture endoprosthesis as total or hemiarthroplasty showed the possibility to expose the femur sufficiently even with a smaller ventral incision in order to securely implant an endoprosthesis. A carefully prepared joint capsule allows a sufficient retraction of the femur. An essential precondition is the use of specific instruments like human retractors, offset raffles and offset-handles. The exposure of acetabulum and medullary cavity is excellent (Light and Keggi, 1980; Rachbauer, 2005).

The reposition of the bipolar head in situ when implanting a bipolar endoprosthesis has been well proven. This is successfully done after placing the socket in the acetabulum.

A usually often used extracorporeal assembly of the components might cause problems during reposition maneuver due to the smaller incision.

Even in obese patients there is a relatively thin layer of subcutaneous fatty tissue using this approach, so the ventral LISA approach may be used easily for endoprosthetic implantation. An intertrigo or other skin infection in the approach zone is a contraindication.

In other respects the ventral approach zone is of hygienically advantage in the often incontinent elderly patient. We have now incorporated this method in the daily routine in a randomised controlled trial.

### REFERENCES

- Berger, R., 2004. Direct anterior approach In: Hozak, W.J., M. Krismer and M. Nogler *et al.* (Hrsg) Minimally invase total joint arthroplasty. Springer, Berlin Heidelberg, New York, pp: 108-112.
- Light, T.R. and K.J. Keggi, 1980. Anterior approach to hip arthroplasty. *Clin. Orthop.*, 152: 255-260.
- Rachbauer, F., 2005. Minimal-invasive Hüftendoprothetik über einen direkten vorderen Zugang. *Orthopäde*, pp: 34.
- Rachbauer, F. and M. Nogler, 2004. Direct Anterior Approach. In: Hozak W.J., M. Krismer and M. Nogler *et al.* (Eds.) Minimally Invase Total Joint Arthroplasty. Springer, Berlin Heidelberg New York, pp: 29-32.
- Rachbauer, F., M. Nogler, E. Mayr and M. Krismer, 2004. Minimally Invasive Single-Incision Anterior Approach for Total Hip Arthroplasty. In: Hozak, W.J., M. Krismer and M. Nogler *et al.* (Eds.) Minimally invase total joint arthroplasty. Springer, Berlin Heidelberg, New York, pp: 54-59.
- Wagner, H., 1978. Surface replacement arthroplasty of the hip. *Clin. Orthop.*, 134: 102-130.