

Direct Bond Eyelet with Silver Chain in Surgical Orthodontics: A Case Report

Panagiotis Kafas and Marios Theodoridis

Department of Oral Surgery and Radiology, School of Dentistry,
Aristotle University, Thessalonica, Greece

Abstract: A male patient, 22 years old presented to the clinic for evaluation of the upper right impacted canine. It was decided to apply orthodontic traction via a new direct bond eyelet with chain material. A great emphasis on the discussion was given to the easy application of this material with the advantages and disadvantages in comparison to other well described methods. The golden goal of primary intention in the field of healing may give superior aesthetic and functional results. Concluding, this new orthodontic material may be used in surgical orthodontics as a cost effective technique.

Key words: Surgical orthodontics, direct bond, eyelet, chain, case report

INTRODUCTION

Currently, tooth impaction is a common clinical situation requiring in most of the cases a surgical approach. Surgery may be essential for two main reasons. First of all, maintaining the concept of tooth “saving”, surgery is required for orthodontic reasons. Secondly, a surgical approach for extraction of an impacted tooth is required for reasons specified by each Dental Council.

Many techniques have been described and implemented for the orthodontic traction of impacted teeth. The final management decision should be based on multidisciplinary approach if we consider that oral surgeons and orthodontists collaborate for the treatment. It is therefore, a situation focused on the dental and medical characteristics of each individual in accordance to the dental staff ability.

Surgical orthodontics is an all inclusive term that may contain orthognathic surgery which resolves dentoskeletal anomalies and exposure and bonding of the impacted teeth prepared for orthodontic traction. In our case, exposure and bonding of the impacted tooth has been discussed as an alternative to the other old fashioned methods such as threaded pins, coronal caps and tooth wiring or two parts bracket-wiring (El-Abdin *et al.*, 1995; Kokich and Mathews, 1993). In the English literature, there was no scientific information about the use of OptiMim[®] (OrthoOrganizers, Inc, USA) direct bond eyelet with chain for the orthodontic traction of upper impacted canines. Therefore, this technical

report described a unique case of multidisciplinary cooperation regarding the use of a new material.

CASE REPORT

A male, 22 years old, presented to the clinic for radiological evaluation of the impacted upper right permanent canine. The medical history was free. No allergies reported and the patient was non-smoker. The pre-orthodontic panoramic tomography revealed the almost horizontal impaction of the associated tooth towards to the midline (Fig. 1). According to the occlusal x-ray at the beginning of the orthodontic treatment the tooth was located palatally (Fig. 2). The vertical image tube to shift method was performed for determining the location of the impacted canine (Jacobs, 1999).

It was decided to expose and bond on the coronal surface of the tooth a special commercial bracket contained a chain (Fig. 3). This was performed after the extraction of the deciduous tooth (No 53) which located on the vertical eruption line. The chain Opti-Mim[®] (30 mm length), was sterling-silver, biocompatible and specially fabricated for sterilization in autoclave (Fig. 4). A unilateral envelope palatal flap was raised protecting the midline location of the incisal nerve that pass through the incisal foramen. The tooth was exposed by removing the bone using a tungsten carbide round bur in a straight handpiece 1:1 at 28000 rpm. To protect the tooth surface from the bur cut the exposure completed using small chisel and mallet with mild force. The crown cleaned

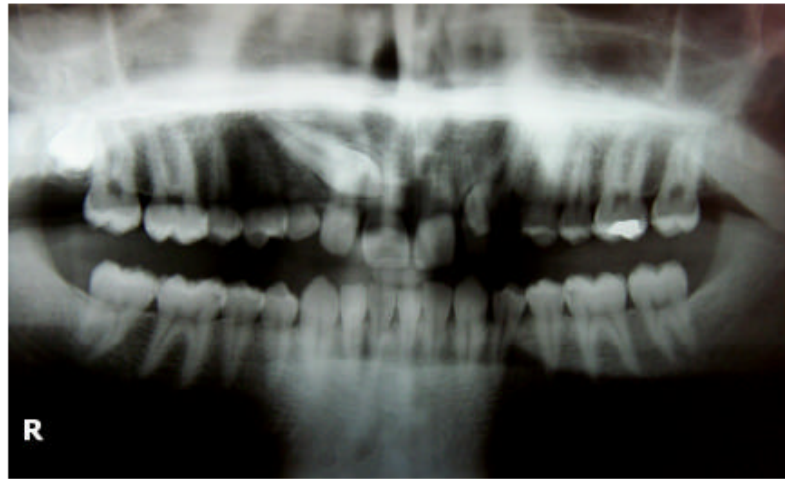


Fig. 1: Panoramic tomography showed the upper right impacted canine

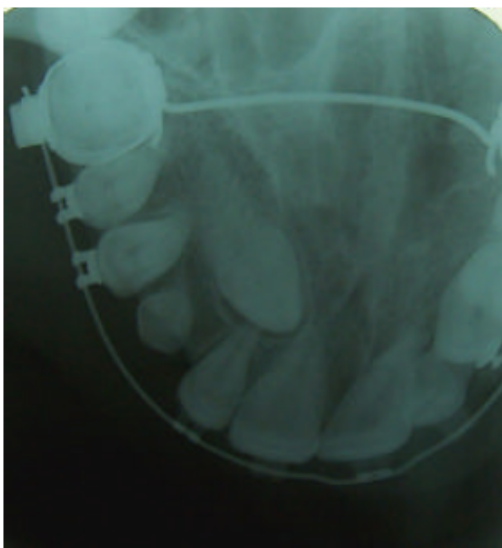


Fig. 2: Occlusal x-ray revealed the palatal impaction of the tooth

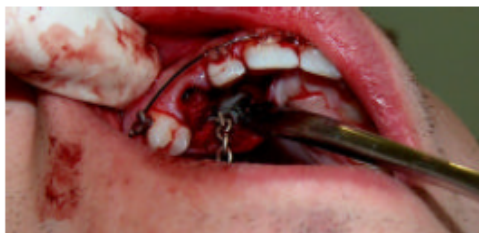

Fig. 3: The Opti-Mim[®] bracket bonded on palatal tooth surface

thoroughly from the granulation tissue. To protect the area from hydration a ribbon gauze used between



Fig. 4: The OptiMim[®] direct bond eyelet with chain used for the traction of the impacted canine

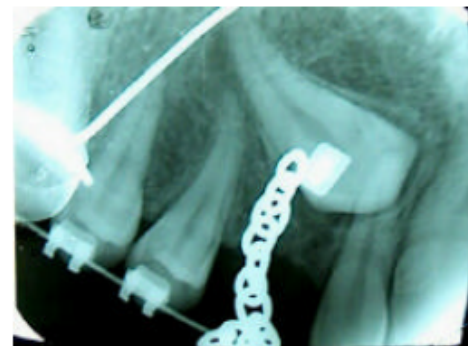

Fig. 5: Checking the bonding intraoperatively with periapical x-ray

the coronal part and the bone margin. The routine method of acid etching and bonding of the bracket performed on a dry surface which achieved using a single sterile plastic syringe. The bracket bonded on tooth

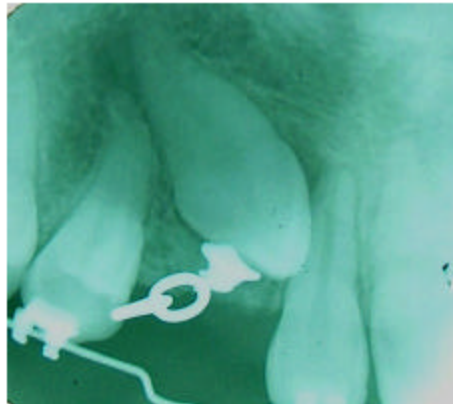

Fig. 6: At the follow up the coronal movement of the impacted canine assessed on periapical x-ray. The tooth is bulbous; a negative factor for rapid orthodontic traction

surface using primer activated orthodontic adhesive (Mono-lok2™, Rocky Mountain Orthodontics, USA). The end part of the chain, sutured on buccal vestibulum (3/0, polypropylene), but firstly passed through the incision line after flap closure and suturing of the edges (4/0 silk). The patient covered empirically with antibiotics (per os Amoxicillin 500 mg tds, 4/7). A small periapical x-ray revealed the correct location of the bracket and chain on the tooth surface (Fig 5). Three months later, at the follow up, another periapical x-ray showed the successive coronal movement of the impacted tooth in relation to the adjacent teeth (Fig 6).

DISCUSSION

Epidemiologically, maxillary canine impaction is the second most common after third molar impaction (Jarjoura *et al.*, 2002). The cause of this pathological process may be the long path of eruption, tooth size-arch length discrepancies, abnormal position of the tooth bud, prolonged retention or early loss of the deciduous canine, trauma, the presence of an alveolar cleft, ankylosis, cystic or neoplastic formation, dilaceration of the root, supernumerary teeth and odontomas (Bayram *et al.*, 2007).

Many surgical techniques have been described with advantages and disadvantages. In our case, we used the one stage exposure and bonding closed technique. This technique allowed the tissues to heal primarily without the formation of extended granulation tissue. The two sides of the surgical trauma should be sutured without tension allowing an uneventful tissue healing. This technique is closed; therefore the silver covered chain may be passed through the incision line. This depends on the incision design. The oral surgeon may perform an incision

compatible to plastic surgery requirements allowing the tissues to approximate without tension on suturing. The healing due to primary intention is the golden key of this technique. On the other hand, the main disadvantage considered to be the unexpected situation of bracket debonding. Therefore, the oral surgeon should be certain on the quality of the bonding technique. Probably the most safe and appropriate test of checking the bonding is to apply a mild force on the chain using dental tweezers. In our case we have used primer activated orthodontic adhesive. The common acid-etching technique used in restorative dentistry performed on the tooth surface. This application is difficult if we consider the narrow surgical field and the microhaemorrhage from the surrounding tissues. To overcome this surgical event, the use of iodoform ribbon gauze has been inserted between the surgical crown periphery and bone margins with the microtip suction constantly attached peripherally to the acid etched tooth surface. Other isolation materials used for preventing hydration of the exposed tooth surface may be bone wax, oxidized cellulose or small gauze. The dryness of the tooth surface performed using single used plastic syringe. This is considered safe due to small force of expelled air preventing the formation of surgical emphysema. The bracket is then bonded to the tooth surface using orthodontic tweezers. It is better to evaluate the bonding of the bracket a few minutes after the initial application to allow the primer activated orthodontic adhesive to set properly.

The granulation tissue is mainly formed in the open surgical technique which had been used for many decades. The main disadvantage of the granulation tissue healing or secondary intention seems to be the time required for the completion of the process. This is explained in one simple way from the requirement of tissue dressing retaining the opening that surrounds the impacted tooth (Caminiti *et al.*, 1998). The periodontal dressing should be retained in the surgical area usually for two to three weeks preventing the formation of the granulation tissue over the surgical opening. This may cause prolonged discomfort, speech and eating difficulties, stimulation of gag reflex when extended to posterior palate and long term healing process. The important advantage of repeating the bonding part of the technique in cases of unexpected debonding should not overcome the disadvantages.

We suggest the close technique for the exposure and bonding to be performed in one stage allowing the orthodontist to apply orthodontic traction forces earlier than the other methods. This may have as a consequence a rapid rehabilitation with cosmetic appearance and totally functional dental arc. The Opti-Mim® direct bond eyelet with chain was found useful in the field of surgical orthodontics. Concluding, the chain links were

big enough in diameter (about 2.5 mm) to thread power elastics for the orthodontic traction providing an easy and clear application field for the orthodontist.

REFERENCES

- Bayram, M., M. Ozer and I. Sener, 2007. Maxillary canine impactions related to impacted central incisors: Two case reports. *J. Contemp. Dent. Pract.*, 8: 72-81.
- Caminiti, M.F., G.K. Sandor and C. Giambattistini and B. Tompson, 1998. Outcomes of the surgical exposure, bonding and eruption of 82 impacted maxillary canines. *J. Can. Dent. Assoc.*, 64: 572-579.
- El-Abdin, H., I. Nashashibi and H. Shaikh, 1995. Surgical exposure and orthodontic traction of unerupted teeth: A preliminary study. *Saudi. Dent. J.*, 7: 17-22.
- Jacobs, S.G., 1999. Localization of the unerupted maxillary canine: How to and when to. *Am. J. Orthod. Dentofacial. Orthop.*, 115: 314-322.
- Jarjoura, K., P. Crespo and J.B. Fine, 2002. Maxillary canine impactions: Orthodontic and surgical management. *Compend. Contin. Edu. Dent.*, 23: 23-31.
- Kokich, V.G. and D.P. Mathews, 1993. Surgical and orthodontic management of impacted teeth. *Dent. Clin. North Am.*, 37: 181-204.