

46, XY Complete Gonadal Dysgenesis (Swyer Syndrome): Report of Two Different Cases

Ahmed S. Elagwany, S. Ziad and M.D. Abouzaid
Department of Obstetrics and Gynecology, Alexandria University, Egypt

Abstract: Swyer's syndrome is a distinct type of pure gonadal dysgenesis characterized by a 46, XY karyotype in female phenotypic patients. It shows an abnormality in testicular differentiation. To present cases of Swyer syndrome. Researchers present the clinical, sonographic, endocrine findings, genetic analyses and treatment in two cases of phenotypic females with XY karyotype and gonadal dysgenesis. All patients presented with primary amenorrhea. All patients had female-type external genitalia. Secondary sexual characters were developed in all cases. FSH levels were high. Chromosome analyses revealed a 46, XY male karyotype with no detectable mosaicism. The surgical findings were streak gonads, one of them with bilateral gonadoblastoma. Bilateral gonadectomy followed by hormone replacement therapy. Researchers aimed to underline the necessity of considering 46, XY complete pure gonadal dysgenesis in the differential diagnosis in every adolescent female patient with delayed puberty and the importance of early gonadectomy in order to avoid the risk for gonadal tumor development.

Key words: Swyer syndrome, gonadal dysgenesis, amenorrhea, patient, karyotype

INTRODUCTION

Constitutional causes constitute the most frequent reason for delayed puberty in males while gonadal differentiation disorders or organic diseases are the major causes in females. The lack of appearance of secondary sex characteristics in females and males by the age of 13 and 14, respectively is described as delayed puberty (Adriana and Gary, 2003).

In 1955, Swyer first described two phenotypic women with gonadal dysgenesis without the stigma of Turner syndrome (46, XY pure gonadal dysgenesis, now known as Swyer syndrome) (Adriana and Gary, 2003; Berek and Hacker, 2005). The chance of tumor development in Swyer syndrome is 20-30%. The most common tumor described is bilateral gonadoblastoma but also seen are dysgerminoma and even embryonal carcinoma (Berek and Hacker, 2005; Behtash and Zarchi, 2007). About 5% of dysgerminomas are discovered in patients who are phenotypically females with abnormal gonads and 46, XY karyotype (Adriana and Gary, 2003; Behtash and Zarchi, 2007).

In this case report, researchers aimed to present a case with pure gonadal dysgenesis who presented with complaints of primary amenorrhea and was detected to have bilateral dysgenetic gonads 46, XY karyotype as a rare cause of male pseudo-hermaphroditism.

CASE REPORTS

Case 1: A 16 years old girl was brought to the outpatient, department by her parents, due to amenorrhea and poor breast development. The patient did not give any history of cyclical abdominal pain, hormonal intake, radiation exposure, chemotherapy or any central nervous symptoms, such as headache or visual disturbances. She gave no history of significant trauma or of having undergone any surgical procedure. There was no history of childhood tuberculosis.

She was the second child of a non-consanguineous marriage and mother's age at the time of delivery was 20 years. On general examination she was 160 cm tall and weighed 65 kg. There was no evidence of acanthosis nigricans, acne, hirsutism, goiter, cushingoid features or turners stigmata. Her school performance was good. There was no other case with a history of delayed puberty in the family. The remaining systemic examination showed no pathological finding.

Patient had development of breast from 12 years of age. She developed pubic hair from the age of 11 years. Pubic hair was present though the axillary hair was sparse. Her phenotype was completely female including a vaginal opening and there was no evidence of clitoromegaly, the hymen was intact. Examination of secondary sexual characteristics revealed that the breast was in Tanner's stage 3 (Fig. 1).

Ultrasonography (USG) of the pelvis revealed a small sized uterus, no endometrial interface and bilaterally small sized gonadal masses with no follicles both kidneys are normal. At the time of laparoscopy at a later date revealed both gonadal masses were small hypoplastic uterus and fallopian tubes and examination under anesthesia showed that the vagina and the cervix were poorly developed.

Routine urine analysis, biochemical parameters and complete blood count were in normal ranges. The results of endocrinological evaluation were as follows: FSH 37 mIU mL⁻¹ (N: 2.6-11), LH 17 IU mL⁻¹ (N: 0.4-7.0) estradiol 10 pg mL⁻¹, total testosterone 27 ng dL⁻¹ (N: 220-800). Her bone age was consistent with the age of 16. A karyotype repeated from two different laboratories showed 46, XY (Fig. 1).

Patient was taken up for an operative laparoscopic procedure under general anesthesia. Intraoperative, the patient had no peritoneal or omental nodule. She also had no deposits over bowel, mesentery and liver surface. And a bilateral gonadectomy was performed (Fig. 1).

Histopathological examination of the both gonadal masses revealed gonadoblastoma. Both fallopian tubes showed normal histology. The patient received four cycles of combination chemotherapy of BEP regimen comprising of cisplatin, etoposide and bleomycin and responded well.

Subsequently, the patient was started on Hormone Replacement Therapy (HRT) with conjugated estrogens 0.625 mg day⁻¹ and cyclical medroxy progesterone acetate. The patient attained menarche. The secondary sexual characteristics have shown some improvement.

Case 2: A 26 years old female came to the outpatient department with her husband, due to amenorrhea and primary infertility. The patient is married for one and half

year. The patient did not give any history of cyclical abdominal pain, hormonal intake, radiation exposure, chemotherapy or any central nervous symptoms, such as headache or visual disturbances. She gave no history of significant trauma or of having undergone any surgical procedure. There was no history of childhood tuberculosis.

She was the first child of a non-consanguineous marriage and mother's age at the time of delivery was 23 years. On general examination, she was 170 cm tall and weighed 75 kg. There was only evidence of acanthosis nigricans in axilla bilaterally but no acne, hirsutism, goiter, cushingoid features or turners stigmata. Her school performance was good. There was no other case with a history of delayed puberty in the family. The remaining systemic examination showed no pathological finding.

Patient had development of breast from 12 years of age. She developed pubic hair from the age of 11 years. Pubic hair was present though the axillary hair was sparse. Her phenotype was completely female including a vaginal opening and there was no evidence of clitoromegaly, the hymen was deflorated. Examination of secondary sexual characteristics revealed that the breast was in Tanner's stage 5 (Fig. 2a, b).

Ultrasonography (USG) of the pelvis revealed a small sized uterus, no endometrial interface and bilaterally non visualized gonads, both kidneys are normal. At the time of laparoscopy at a later date revealed bilateral streak gonads, small hypoplastic uterus and fallopian tubes and examination under anesthesia showed that the vagina and the cervix were poorly developed.

Routine urine analysis, biochemical parameters and complete blood count were in normal ranges. The results of endocrinological evaluation were as follows: FSH 96 m IU⁻¹ mL (N: 2.6-11), LH 30IU mL⁻¹

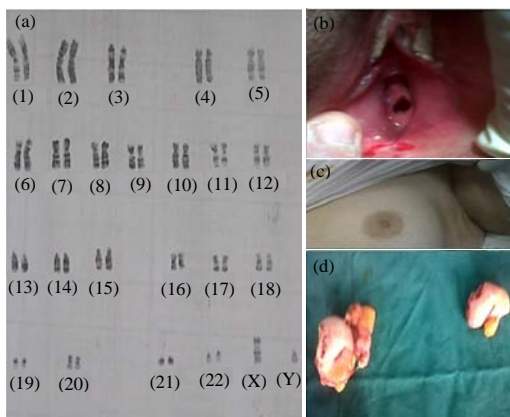


Fig. 1: Examination of secondary sexual characteristics (Stage 3)

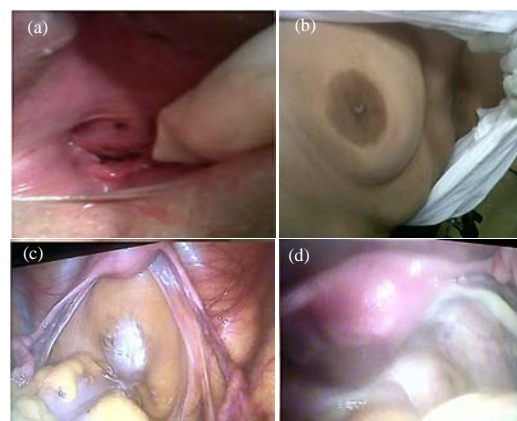

Fig. 2: Examination of secondary sexual characteristics (Stage 5)

(N: 0.4-7.0) estradiol 23 pg mL⁻¹, total testosterone 27 ng dL⁻¹ (N: 220-800). A karyotype repeated from two different laboratories showed a genotype of pure XY.

Patient was taken up for an operative laparoscopic procedure under general anesthesia revealing bilateral streak gonads (Fig. 1c, d) and a bilateral gonadectomy was performed. The histopathology of the excised gonads showed fibrous tissue without follicles or neither ovarian nor testicular tissues. Subsequently, the patient was started on Hormone Replacement Therapy (HRT) with conjugated estrogens 0.625 mg day⁻¹ and cyclical medroxy progesterone acetate. The patient attained menarche. The secondary sexual characteristics have shown some improvement.

DISCUSSION

In utero, sexual differentiation follows a sequential pattern. After fertilization, there is establishment of the genotype of the embryo and under the influence of the single gene determinant (testes determining factor) on the short arm of the Y chromosome, there is differentiation of the primordial gonads into the testes. The ovaries develop by default, in the absence or non-functioning of the Y chromosome. This differentiation of the primordial gonads into the testes or ovary will lead to an alteration of the hormonal milieu of the fetus which in turn results in the corresponding differentiation of the internal and external genitalia (Adriana and Gary, 2003).

The main differential diagnosis of Swyer's syndrome is mixed gonadal dysgenesis which is more frequently seen than the former. These patients have a normal life expectancy provided they have undergone bilateral gonadectomy. These patients can have normal sexual relations and theoretically they can conceive using donor oocytes and artificial reproductive techniques. They need to be on lifelong HRT.

The incidence of Swyer syndrome reported in literature is 1:100,000 (Speroff and Fritz, 2005). Very few cases (<100) have been reported in the world literature (Speroff and Fritz, 2005; Hawkins, 1993; Cotinot *et al.*, 2002; Fernandes *et al.*, 2010). It is characterized by a 46, XY karyotype, a female phenotype with normal female external genitalia and a hypoplastic to normal uterus, streak gonads and primary amenorrhea (Speroff and Fritz, 2005; Hawkins, 1993). Majority show minimal breast development (Speroff and Fritz, 2005; Hawkins, 1993; Cotinot *et al.*, 2002). However in the present case, the unique feature was well developed breast corresponding to Tanner stage 5. This may be explained due to estrogen secretion from the gonadoblastoma as well as due to the action of exogenously administered estrogen (Kim *et al.*,

1993; Gibbons *et al.*, 1999). Gonadoblastomas are benign tumors composed of germ cells and sex cord stroma (Adriana and Gary, 2003; Gibbons *et al.*, 1999). Most of the patients in possession of gonadal dysgenesis and a Y chromosome develop gonadoblastoma or dysgerminoma (Hawkins, 1993; Cotinot *et al.*, 2002).

CONCLUSION

In this case, researchers noted dysgerminoma associated with evidence of residual or burnt out gonadoblastoma in the same gonad and gonadoblastoma in the other. Since, dysgenetic gonads have a very high risk of developing into malignant germ cell neoplasm, a prophylactic bilateral gonadectomy is strongly recommended (Fernandes *et al.*, 2010; Han *et al.*, 2011; Kim *et al.*, 1993).

REFERENCES

- Adriana, A. and D. Gary, 2003. Disorders of Sexual Differentiation. In: Pediatric Endocrinology, Lifshitz, F. (Eds.). Marcel Decker, New York, pp: 319-345.
- Behdash, N. and M.K. Zarchi, 2007. Dysgerminoma in three patients with Swyer syndrome. World J. Surgical Oncol., Vol. 5. 10.1186/1477-7819-5-71
- Berek, J.S. and N.F. Hacker, 2005. Clinical Gynecologic Oncology. 5th Edn., Lippincott Williams and Wilkins, Philadelphia, pp: 509-536.
- Cotinot, C., E. Pailhoux, F. Jaubert and M. Fellous, 2002. Molecular genetics of sex determination. Semin Reprod Med., 20: 157-167.
- Fernandes, G.C., P.A. Sathe and L.P. Naik, 2010. Bilateral gonadoblastomas with unilateral dysgerminoma in a case of 46 XY Pure Gonadal Dysgenesis (Swyer syndrome). Indian J. Pathol. Microbiol., 53: 376-378.
- Gibbons, B., S.Y. Tan, C.C.W. Yu, E. Cheah and H.L. Tan, 1999. Risk of gonadoblastomas in female patients with Y chromosome abnormalities and dysgenetic gonads. J. Pediatric Child Health, 35: 210-213.
- Han, Y., Y. Wang, Q. Li, S. Dai, A. He and E. Wang, 2011. Dysgerminoma in a case of 46, XY pure gonadal dysgenesis (swyer syndrome): A case report. Diagnostic Pathol., Vol. 6. 10.1186/1746-1596-6-84
- Hawkins, J.R., 1993. Mutational analysis of SRY in XY females. Human Mutations, 2: 347-350.
- Kim, S.K., I.S. Sohn, J.W. Kim, C.H. Song, C.I. Park, M.S. Lee and K.R. Kim, 1993. Gonadoblastomas and dysgerminoma associated with 46, XY pure gonadal dysgenesis-a case report. J. Korean Med. Sci., 8: 380-384.
- Speroff, L. and M.A. Fritz, 2005. Clinical Gynecologic Endocrinology and Infertility. 7th Edn., Lippincott Williams and Wilkins, Philadelphia, pp: 322-359.