

## Rupture of the Right Coronary Cusp of the Aortic Valve Caused by Blunt Chest Trauma

<sup>1</sup>Asuman B. Yesilay, <sup>1</sup>Ozcan Ozeke, <sup>2</sup>Kerim Cagli, <sup>1</sup>Bulent Deveci, <sup>1</sup>Kumral Ergun, <sup>1</sup>Mehmet Dogan, <sup>1</sup>Veli Kaya and <sup>1</sup>Erdem Guler  
<sup>1</sup> Department of Cardiology, <sup>2</sup>Department of Cardiovascular Surgery, Yuksek Ihtisas Hospital, Ankara, Turkey

**Abstract:** Although cardiac trauma is one of the leading causes of death among victims of blunt injury, it is frequently overlooked. or missed because of other obvious injuries. Therefore, it is very important to specifically look for heart-related injuries in these patents. We present a patient with aortic valve insufficiency due to rupture of the right coronary cusp caused by blunt chest trauma.

**Key words:** Cardiac trauma, ruptured aortic cusp

### CASE REPORT

A 38-year-old man with a history of traumatic injury 1 years ago in a traffic accident presented with exertional dyspnea, which had been insidious in onset and slowly progressive over a period of 4 weeks. He had no history of intravenous drug use or any connective tissue disorder. On physical examination, he appeared tired but not in acute distress. The blood pressure measured 160/60 mmHg and the pulse was regular with a rate of 95 beats. General physical examination showed no abnormalities except for a 2/4 diastolic murmur at the left sternal border. An electrocardiogram revealed atrial fibrillation. No abnormality of the heart and lungs were apparent on chest X-ray examination. Two-dimensional echocardiography in parasternal long axis (Fig. 1) and apical long axis (Fig. 2A)

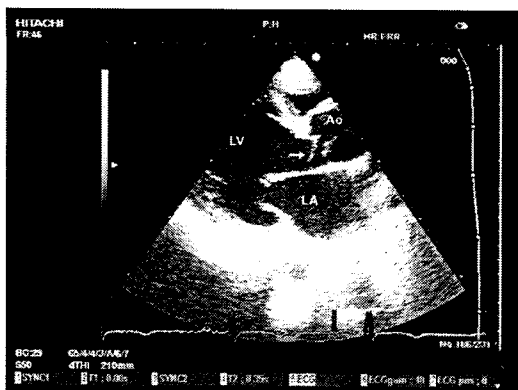


Fig. 1: Two dimensional echocardiography in the parasternal long axis view shows the ruptured right aortic valve cusp (arrow). LV, left ventricle; LA, left atrium; Ao, aort

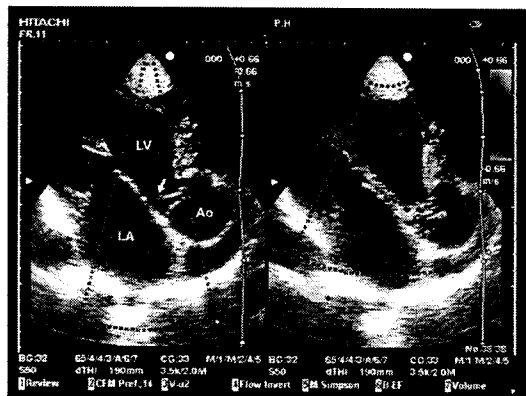


Fig. 2: The ruptured right aortic cusp (arrow) in apical long axis view and a moderately eccentric aortic regurgitation in color Doppler echocardiography is seen. LV, left ventricle; LA, left atrium; Ao, aort

views showed a downward displacement of the ruptured right aortic valve cusp that was mildly thickened and moderately dilated and normal systolic function of the left ventricle. No vegetations were seen. A moderately eccentric aortic regurgitation was noticed by color Doppler echocardiography (Fig. 2B). The patient was scheduled for surgery; implantation of a St Jude 27 mm mechanical valve was performed. The patient made an uneventful recovery and was discharged 1 week later.

### DISCUSSION

Although cardiac trauma is one of the leading causes of death among victims of blunt injury, it is frequently overlooked. or missed because of other obvious injuries.

Therefore, it is very important to specifically look for heart-related injuries in these patents<sup>[1]</sup>. Cardiac injury following blunt chest trauma can result in myocardial contusion, hemopericardium and rupture of the ventricles, papillary muscles, or cardiac valves. Traumatic aortic valve regurgitation is a rare complication of non-penetrating thoracic trauma. The mechanism of rupture of the aortic valve is thought to be a sudden increase in intrathoracic pressure during diastole, when the pressure gradient across the aortic valve is maximal and the valve is closed<sup>[2-5]</sup>.

Nearly all authors recommend that surgical intervention should be done as soon as possible, however it can be delayed for treatment of other life-threatening injuries. Although Aortic Valve Replacement (AVR) are recommended to repair traumatic aortic valve regurgitation, the number of cases reports with conservative surgery is increasing. The conservative surgery should be performed for only isolated lesion in order to avoid AVR and its potential complications especially in young patients with healthy valves. However, the AVR is the safest technique for complex or multiple injuries of the aortic valve<sup>[6-8]</sup>. Because the our patient has atrial fibrillation and aortic valvuloplasty is associated in the long term with a high rate of failure, which requires reoperation, in this case, AVR was preferred by the surgical team. This case emphasizes the important role of the transthoracic echocardiography in evaluating of patients of blunt injury .

## REFERENCES

1. Parmley, L.F., W.C. Manion and T.W. Mattingly, 1958. Nonpenetrating traumatic injury of the heart. *Circulation*, 18: 371-396.
2. Westaby, S. and N. Brayley, 1990. ABC of major trauma. *Thoracic Trauma-I. BMJ.*, 300: 1639-43.
3. Vidmar, J., D. Brilej, G. Voga, N. Kovacic and V. Smrkolj, 2003. Aortic valve insufficiency due to rupture of the cusp in a patient with multiple trauma. *Unfallchirurg*, 106: 514-518.
4. Unal, M., E. Demirsoy, A. Gogus, H. Arbatli, A. Hamzaoglu and B. Sonmez, 2001. Acute aortic valve regurgitation secondary to blunt chest trauma. *Tex Heart Inst. J.*, 28: 312-314.
5. Nekkanti, R., S.R. Aaluri, N.C. Nanda and O. Mukhtar, 2001. Transesophageal echocardiographic diagnosis of traumatic rupture of the noncoronary cusp of the aortic valve. *Echocardiography*, 18: 189-190.
6. Meunier, J.P., N. Berkane, S. Lopez, C. Sicart-Toulouse, B. Malzac, C. Isetta, J.P. Camous and M. Baudouy, 2004. Traumatic aortic regurgitation: Diagnostic, management and treatment *Arch Mal. Coeur. Vaiss.*, 97: 613-618.
7. Halstead, J., A.R. Hosseinpour and F.C. Wells, 2000. Conservative surgical treatment of valvular injury after blunt chest trauma. *Ann. Thorac. Surg.*, 69: 766-768.
8. Pretre, R. and B. Faidutti, 1993. Surgical management of aortic valve injury after nonpenetrating trauma. *Ann. Thorac. Surg.*, 56: 1426-1431.