

## Simultaneous Atrial and Ventricular Extrastimulation for Differentiation of Atrioventricular Nodal Reentrant Tachycardia from Orthodromic Atrioventricular Reentrant Tachycardia Using Septal Accessory Pathways

Bernhard Strohmer, Christiana Scherthaner and Maximilian Pichler  
Department of Cardiology, Salzburger Landeskliniken,  
Paracelsus Private Medical University, Salzburg, Austria

**Abstract:** Determination of tachycardia mechanism by electrophysiological techniques is essential for a definite diagnosis of paroxysmal supraventricular tachycardia and a prerequisite for a safe and efficacious ablation. The purpose of this study was to determine, whether simultaneous atrial and ventricular (AV) extrastimulation is useful for differentiating Atrioventricular Nodal Reentrant Tachycardia (AVNRT) from orthodromic Atrioventricular Reentrant Tachycardia (AVRT) using a septal accessory pathway. Forty-eight consecutive patients underwent electrophysiological study with induction of 51 types of tachycardias. Based on standard criteria AVNRT was diagnosed in 40 patients (4 atypical AVNRT) and AVRT through a septal accessory pathway in 11 patients. The diagnostic value of simultaneous AV extrastimulation was tested and the preexcitation index (PI) was compared to that obtained with single and double ventricular extrastimulation. Simultaneous AV extrastimulation was applicable in all patients with AVNRT except in one patient with slow/slow form. This pacing maneuver resulted in atrial and/or ventricular preexcitation in 11% of tested patients (PI  $115 \pm 35$  ms). Simultaneous AV extrastimulation was applicable in 50% of patients with septal AVRT (PI  $24 \pm 28$  ms), whereas in the other half of patients loss of simultaneous capture was observed. Simultaneous AV extrastimulation is a useful and rapid pacing maneuver for differentiation of AVNRT from orthodromic AVRT through a septal accessory pathway. This pacing technique is valid as long as simultaneous capture is achieved during tachycardia and may complete commonly used diagnostic steps in paroxysmal junctional tachycardias.

**Key words:** Atrioventricular nodal reentrant tachycardia, atrioventricular reentrant tachycardia, septal accessory pathway, simultaneous atrial and ventricular extrastimulation, preexcitation index

### INTRODUCTION

In general, the distinction between Atrioventricular Nodal Reentrant Tachycardia (AVNRT) and orthodromic atrioventricular reentrant tachycardia (AVRT) utilizing an accessory bypass tract is easily made by the ventriculoatrial intervals during Paroxysmal Supraventricular Tachycardia (SVT)<sup>[1]</sup>. In case of retrograde concentric activation sequence, however, diagnosis of SVT may be challenging, particularly when dual AV node physiology is not observed with initiation of tachycardia. Furthermore, some cases of AVNRT can have a relatively long and misleading ventriculoatrial interval due to atypical retrograde exit sites<sup>[2,3]</sup>. Because conventional criteria may have some limitations, there has been a need for additional diagnostic techniques to distinguish AVNRT from AVRT using a septal accessory

pathway<sup>[4]</sup>. Successful and safe ablation of SVT in close proximity to the AV node is dependent on an accurate diagnosis of the tachycardia mechanism. Ventricular-based atrial preexcitation during reciprocating tachycardia is commonly used for differentiation between AVNRT and septal AVRT by calculation of the Preexcitation Index (PI)<sup>[5,6]</sup>. The present study was performed to evaluate the diagnostic value of a novel pacing technique, namely simultaneous atrial and ventricular (AV) extrastimulation.

### MATERIAL AND METHODS

**Patient characteristics:** Forty eight consecutive patients (24 men and 24 women; mean age  $53 \pm 17$  years, range 17 to 88 years) with symptomatic SVT underwent diagnostic electrophysiological study and radiofrequency ablation. None of the patients had significant structural heart

**Corresponding Author:** Bernhard Strohmer, M.D. Department of Cardiology, Paracelsus Private, Medical University Salzburg Landeskliniken, Muellner Hauptstrasse 48A-5020 Salzburg, Austria  
Tel : ++43-662-4482-340 Fax: ++43-662-4482-3486

disease. All patients gave informed consent and all procedures were performed in the postabsorptive state. All antiarrhythmic drugs had been stopped for at least five drug half-lives. The patients were lightly sedated with midazolam and fentanyl.

**Electrophysiological study:** Quadripolar recording and pacing catheters were positioned in the high right atrium, in the His-bundle position and in the right ventricular apex. A luminal decapolar catheter was placed in the coronary sinus with confirmation of the proximal bipole at the coronary sinus os by contrast injection. Intracardiac electrograms were filtered between 30 and 500 Hz and recorded by a computerized analysis system (CardioLab®, Prucka Engineering, GE Medical Systems). Pacing was performed utilizing a multichannel stimulator (DTU 215, Bloom Associates, Ltd., Reading, PA, USA) with 2 ms rectangular stimuli at twice the diastolic threshold. Following induction of tachycardia, the mechanism was identified on certainty based on standard criteria and on the results of ablation.<sup>14,7</sup>

**Pacing maneuvers:** During sustained and stable SVT, single ventricular, double ventricular and simultaneous AV extrastimuli were coupled to the last sensed ventricular beat and shortened by 10-ms intervals until preexcitation, tachycardia termination or local refractoriness occurred. These pacing maneuvers were prospectively performed and repeated at least twice to verify reproducibility of measurements.

**Calculation of the preexcitation index:** The standard PI was used to quantitate the degree of ventricular prematurity required for the ventricular impulses to affect atrial preexcitation and served as reference value<sup>15,6</sup>. PI for single ventricular extrastimulation:  $PI = V_1V_1 - V_1V_2$ , [ $V_1V_1$  = reentrant tachycardia cycle length,  $V_1V_2$  = longest interval able to preexcite the atrium by >10 ms]. PI for double ventricular extrastimulation:  $PI = V_1V_1 - V_{ie}V_3$ , [ $V_{ie}V_3 = V_2V_3 - (V_1V_1 - V_1V_2)$ ,  $V_{ie}$  is the „expected“  $V_1$  if  $V_2$  was not present. This term of the equation essentially serves to nullify the prematurity of the paced  $V_2$  beat.  $V_2V_3$  = longest interval between the first and second pacing extrastimulus able to preexcite the atrium by >10 ms,  $V_1V_2$  = interval between  $V_1$  and the first pacing extrastimulus]. The PI for simultaneous AV extrastimulation was used to determine the degree of AV prematurity to preexcite either the ventricle or the atrium.  $PI_{AV} = V_1V_1 - V_1A_2V_2$ , [ $V_1A_2V_2$  = longest ventricular coupling interval able to preexcite the atrium or the ventricle respectively of the following beat by >10 ms].

A second PI was used to normalize the preexcitation with respect to tachycardia cycle length<sup>15</sup>. The PI<sub>2</sub> was

calculated for single ventricular, double ventricular and simultaneous AV extrastimulation separately using a formula with the PI as numerator and the respective tachycardia cycle length as denominator (e.g.,  $PI_2$  for single ventricular extrastimulation =  $V_1V_2 / V_1V_1$ ).

**Statistics:** Continuous variables are expressed as Mean ± SD and were compared using the appropriate Student's *t*-test. Termination and the preexcitation results of AVNRT compared with AVRT were compared by Fisher's exact test. A value of  $p < 0.05$  was considered significant.

## RESULTS

A total of 51 types of reentrant tachycardias were induced by atrial or ventricular pacing in 48 non-selected patients. Forty patients (16 men and 24 women; mean age  $55 \pm 16$  years) were diagnosed to have AVNRT, 36 of them presented the typical form (slow/fast AVNRT) and 4 patients the atypical form (two fast/slow and two slow/slow AVNRT). Orthodromic AVRT involving a septal accessory pathway was found in 11 patients (10 men and one women; mean age  $42 \pm 15$  years). The pathway was located in the right posteroseptal area in 5 patients, in the left posteroseptal area in 2 patients and in the right midseptal region in 4 patients.

In AVNRT (N=40), the mean tachycardia cycle length was  $332 \pm 62$  ms (range: 235 to 500 ms). The ventricular to high-right atrial interval was  $44 \pm 35$  ms (range: 0 to 141 ms) in typical AVNRT and  $214 \pm 64$  ms (range: 90 to 365 ms) in atypical AVNRT. In AVNRT, only 10% (4/40) of patients showed atrial preexcitation with single ventricular extrastimulation (PI  $153 \pm 32$  ms, range: 110 to 188 ms) and 55% (16/29) of the tested patients with double ventricular extrastimulation (PI  $170 \pm 50$  ms, range: 106 to 290 ms). Simultaneous AV extrastimulation was delivered in 39/40 patients and was inapplicable in only one patient who had a slow/slow AVNRT. Simultaneous AV extrastimulation resulted in preexcitation in 11% (4/38) of the patients at a PI  $118 \pm 35$  ms (range: 85 to 162 ms) (Fig.1).

In AVRT (N=11), the mean tachycardia cycle length was  $342 \pm 55$  ms (range: 245 to 414 ms). In this respect no significant difference existed between both types of SVT (Table 1). The mean ventricular to high-right atrial interval was  $150 \pm 17$  ms (range: 99 to 290 ms). In septal AVRT, atrial preexcitation occurred in 10/11 (91%) patients with single ventricular extrastimulation (PI  $58 \pm 20$  ms, range: 34 to 105 ms). In the remaining patient, who had a right posteroseptal pathway, the tachycardia reproducibly terminated by introducing a single ventricular extrastimulus, which was not conducted to the atria. Ventricular-induced atrial preexcitation was achieved with delivery of single ventricular extrastimulation more

Table 1: Comparison of tachycardia cycle length for patients with and without preexcitation in response to single ventricular, double ventricular and simultaneous AV extrastimulation

		AVNRT		Septal AVRT		
		n/N (%)	CL (ms)	p-value	n/N (%)	CL (ms)
<b>Preexcitation</b>		40 (100)	332±62*	*n.s.	11 (100)	342±55*
Using single VE	Yes	4/40 (10)	453±55	0.018	10/11 (91)	337±63
	No	36/40 (90)	319±46		0/11 (0)	—
Using double VE	Yes	16/29 (55)	355±61	0.037	4/4 (100)	341±63
	No	13/29 (45)	311±44		0/4 (0)	—
Using AV-E	Yes	4/38 (11)	398±105	NS	5/10 (50)	332±45
	No	34/38 (89)	323±51		0/10 (0)	—

AVNRT= Atrioventricular Nodal Reentrant Tachycardia, AVRT= Atrioventricular Reentrant Tachycardia; N= total Number of tested patients, n=Number of patients with and without preexcitation, respectively, CL= Cycle Length (Mean±SD in milliseconds), Ve= Ventricular Extrastimulation, AV-E= simultaneous Atrial and Ventricular Extrastimulation.

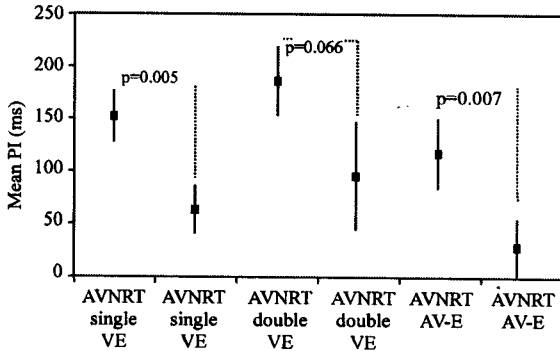


Fig. 1: Comparison of preexcitation indices (PI, expressed in milliseconds as Mean ± SD) obtained with single ventricular, double ventricular and simultaneous AV extrastimulation between patients with Atrioventricular Nodal Reentrant Tachycardia (AVNRT) and orthodromic Atrioventricular Reentrant Tachycardia (AVRT) using a septal accessory pathway. VE=ventricular extrastimulation, AV-E= simultaneous AV extrastimulation.

frequently in AVRT compared to AVNRT (10/11 (91%) vs 4/40 (10%) patients). With double ventricular extrastimulation atrial preexcitation was consistently observed during AVRT (PI 95±54 ms, range: 46 to 158 ms). Simultaneous AV extrastimulation was applicable in 50% (5/10) of patients with AVRT at a PI of 24±28 ms (range: 10 to 74 ms) (Fig.1). In the other half of the patients - four had a right posteroseptal and one had a midseptal pathway - this technique was inapplicable owing to loss of simultaneous capture. However, with loss of atrial capture the pacing maneuver resembled single ventricular extrastimulation that resulted in atrial preexcitation. The PI obtained with AV extrastimulation remained significantly different for both types of SVT after correcting the PI for the underlying tachycardia cycle length (Table 1 and 2). AVRT terminated by single ventricular extrastimulation more frequently than AVNRT (7/11 (64%) vs 4/40 (10%) patients, respectively). Termination of AVRT occurred in

5/7 patients without depolarizing the atrium and in only 1/4 patients with AVNRT. Simultaneous AV extrastimulation resulted in termination of AVRT in 2/5 (40%) patients, in both cases after a short run of atrial fibrillation, whereas in AVNRT termination was noticed in 9/38 (24%) patients.

### DISCUSSIONS

**Main findings:** The results of this study indicate that AVNRT can be distinguished reliably from septal AVRT by simultaneous AV extrastimulation. This pacing maneuver was performed during ongoing SVT to obtain ventricular-induced atrial preexcitation and/or atrial-induced ventricular preexcitation. Moreover, simultaneous AV extrastimulation was helpful to find out whether the tachycardia involved the atrium and the ventricle as a critical part in the reentrant circuit. From a practical perspective, simultaneous AV extrastimulation was easy to perform and served to calculate a PI that was successful in elucidating the tachycardia mechanism.

In AVRT, this pacing maneuver resulted in shorter ventricular return cycles when compared to the return cycles obtained with single ventricular extrastimulation (Fig. 3). This finding was uniformly related to the relatively short coupling interval of the atrial extrastimulus applied with simultaneous AV pacing during AVRT (Fig. 3, Panel B). Simultaneous AV extrastimulation was inapplicable more frequently in AVRT than in AVNRT. In AVNRT, a substantial prematurity of AV extrastimulation was required to achieve preexcitation, typically prior to activation of the His-bundle. This type of response was characteristic for AVNRT and resulted in a PI of at least 85 ms.

**Preexcitation index:** The Preexcitation Index (PI) was introduced by Miles and coworkers as an aid to determine the mechanism of SVT many years ago [5]. Essentially this technique was developed to localize an accessory pathway prior to surgical ablation therapy. The responses to single ventricular extrastimulation are preexcitation of

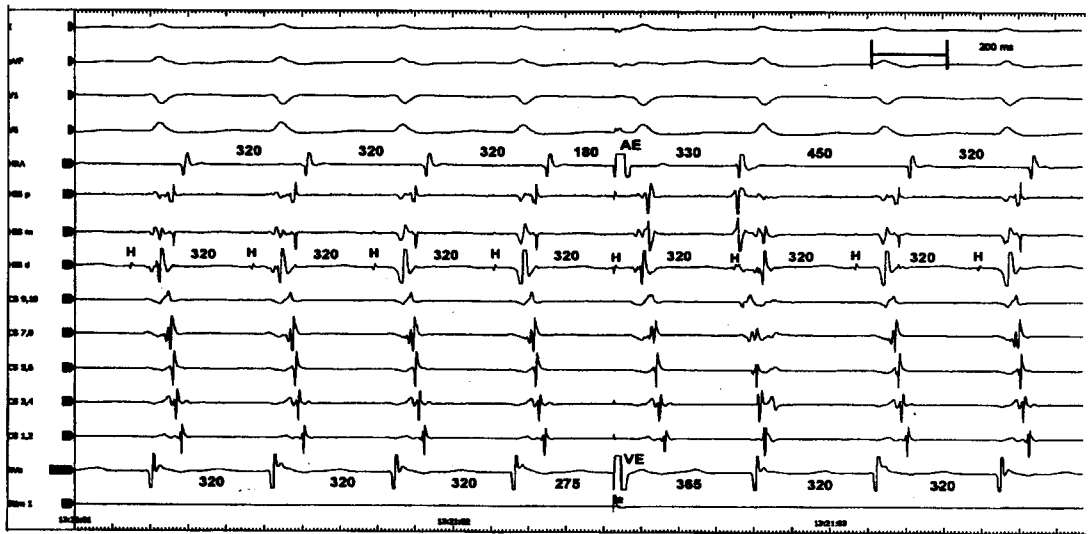


Fig. 2: Simultaneous AV extrastimulation (AE/VE) was delivered on time with His bundle activation during supraventricular tachycardia with an equivocal VA interval (110 ms). Both extrastimuli and a repetitive atrial response were dissociated from ongoing tachycardia without disturbing the H-H intervals (tachycardia cycle length 320 ms). This result pointed indirectly to atrioventricular nodal reentrant tachycardia, as neither the atrium nor the ventricle seemed to be an obligatory part of the reentrant circuit. Shown are surface leads I, aVF, V<sub>1</sub>, V<sub>6</sub>, intracardiac electrograms from the high right atrium (HRA), His bundle (proximal to distal), coronary sinus (CS 9,10 = proximal, CS 1,2 = distal) and right ventricular apex (RVA). Recordings were obtained at 200 mm sec paper speed; the intervals on the tracings are given in milliseconds

the atrium in relation to His-bundle refractoriness or termination of the reentrant tachycardia when the his is refractory (indicative for AVRT). Moreover, it is of diagnostic importance whether the atrium is depolarized or not (excluding an atrial tachycardia) when termination occurs.

**Single vs double ventricular extrastimulation:**

Interestingly, preexcitation seemed to be more difficult to demonstrate with double rather than with single ventricular extrastimulation in both types of arrhythmias (Fig.1). This phenomenon was probably related to a delay in the retrograde specific conduction system from the shortened ventricular coupling intervals in some of the patients. Nevertheless, the use of double ventricular extrastimulation extended the ability to obtain atrial preexcitation in AVNRT compared to single ventricular extrastimulation (in 55% vs 10% of patients, respectively). A group of authors, however, reported that the P<sub>is</sub> calculated with double premature ventricular extrastimuli corresponded closely to those using a single paced premature beat<sup>[6]</sup>.

**Rate-corrected preexcitation index:** For accurate analysis one has to take into consideration that

preexcitation might be easier to achieve in tachycardias with slower cycle lengths (Table 1)<sup>[9]</sup>. Thus, a second PI was introduced to normalize preexcitation with respect to tachycardia cycle length<sup>[5]</sup>. A statistically significant difference was found between the mean PI<sub>2</sub> for AVNRT and septal AVRT using simultaneous AV extrastimulation (Table 2). In contrast to the basic results, the PI<sub>2</sub> was only weakly significant as far as single ventricular extrastimulation was concerned and did not reach statistical significance as far as double ventricular extrastimulation was concerned.

**Simultaneous AV extrastimulation and AVNRT:** The only tachycardia characteristic being indicative for typical AVNRT is a septal ventriculoatrial interval shorter than 70 ms or a ventricular to high-right atrial interval of less than 95 ms<sup>[1,4]</sup>. Of interest, no single pacing maneuver -

Table 2: Comparison of preexcitation indices between patients with Atrioventricular Nodal Reentrant Tachycardia (AVNRT) and septal Atrioventricular Reentrant Tachycardia (AVRT) after correction for the underlying tachycardia cycle length.

Rate-corrected PI (ms)	AVNRT	Septal AVRT	p-value
PI <sub>2</sub> using single VE	0,66	0,83	0.040
PI <sub>2</sub> using double VE	0,52	0,72	0.093
PI <sub>2</sub> using AV-E	0,70	0,93	0.002

Abbreviations as in Table 1. PI<sub>2</sub> = mean preexcitation index normalized for tachycardia cycle length.

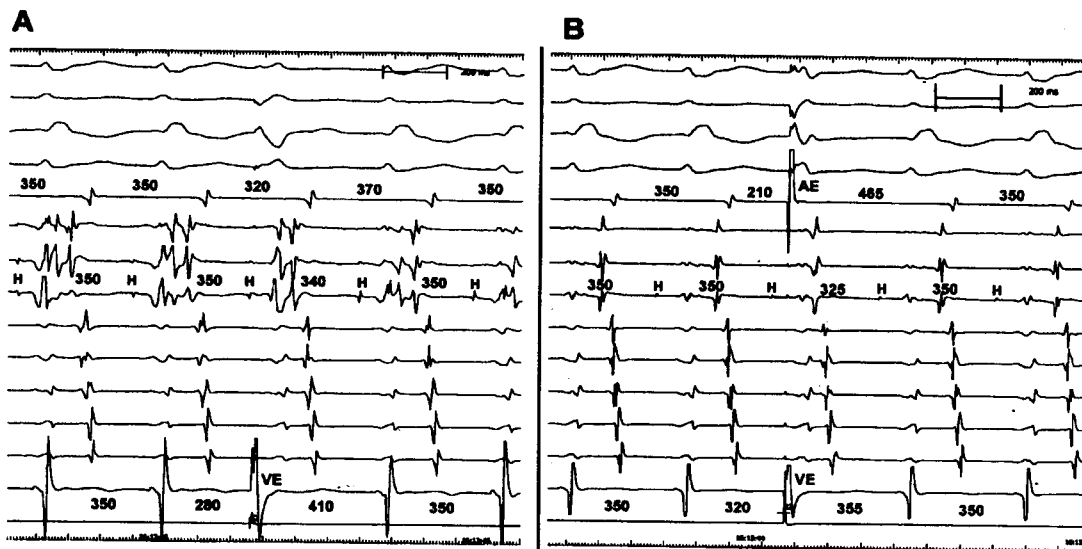


Fig. 3: Panel A depicts ventricular-induced atrial preexcitation obtained with the longest possible coupling interval of single ventricular extrastimulation during supraventricular tachycardia with right bundle branch block. In this example the preexcitation index was 70 ms ( $PI = V_1V_1 - V_1V_2 = 350\text{ms} - 280\text{ms}$ ). Panel B shows the effect of adding an atrial extrastimulus, introduced as part of simultaneous AV extrastimulation during the same tachycardia. Despite the relatively long coupling interval of Ventricular Extrastimulation (VE), the timing of Atrial Extrastimulation (AE) was much earlier than the atrial preexcitation obtained with single ventricular extrastimulation. Thus, a short preexcitation index of 30 ms was calculated ( $PI_{AV} = V_1V_1 - V_1A_2V_2 = 350\text{ms} - 320\text{ms}$ ) that was indicative of atrioventricular reentrant tachycardia through a septal accessory pathway. The surface leads and intracardiac electrograms are displayed as in Fig. 2.

delivered either from the atrium or from the ventricle - is considered to be diagnostic for AVNRT<sup>(4)</sup>. Therefore, invasive electrophysiological studies may occasionally leave uncertainty in the correct diagnosis for cases with longer ventriculoatrial intervals.

The prevailing clinical understanding of AVNRT is based on a model of dual AV nodal pathways that are functionally and anatomically distinct. However, the exact anatomic tachycardia circuit in AVNRT remains elusive. Some experimental and clinical studies provide evidence in favor of an intra-AV nodal concept, which assumes that the slow and fast pathways exist within the AV node<sup>(9,10)</sup>. Some data suggest involvement of perinodal atrial tissue (atrionodal inputs) in the reentry circuit of AVNRT<sup>(11,12)</sup>.

Present study derived from simultaneous AV extrastimulation may be in line with an intranodal concept of AVNRT. Both the atrium and the ventricle could be easily dissociated from the micro-reentrant circuit in up to 90% of patients without any disturbance of AVNRT (Fig. 2). However, our data do not provide sufficient proof that the circuit of AVNRT is entirely intranodal. Theoretically, perinodal atrial tissue that is necessary to the circuit becomes uncoupled from the rest of the atrium, when captured by an atrial extrastimulus.

**Previous Studies:** A number of studies have evaluated a variety of diagnostic characteristics and maneuvers for distinction of AVNRT from AVRT using a septal accessory pathway. One study reported the usefulness of the differences in the HA interval during SVT and ventricular pacing at the same rate to distinguish AVNRT ( $\Delta$  HA interval  $>10$  ms) from septal AVRT<sup>(13)</sup>. Some authors found that a difference in the ventriculoatrial interval during tachycardia and ventricular pacing  $>90$  ms differentiated all patients with AVNRT from those with septal accessory pathways<sup>(14)</sup>. Other investigators observed ventricular fusion during resetting and entrainment in septal AVRT but not in AVNRT<sup>(15)</sup>. Another technique is based on differential pacing and a difference in ventriculoatrial intervals  $>10$  ms between apical and posterobasal right ventricular pacing (ventriculoatrial index) discriminating concealed posteroseptal pathways from AV node pathways<sup>(16)</sup>. The response to ventricular pacing and entrainment was shown to be useful in distinguishing atypical AVNRT from septal AVRT by calculating the difference between the stimulus-atrial and ventriculoatrial interval ( $>85$  ms with atypical AVNRT) and the difference between the post-pacing interval and the tachycardia cycle length

(>115 ms with atypical AVNRT)<sup>[17]</sup>. Another study demonstrated that a difference in the AH interval between atrial pacing and the tachycardia of more than 40 ms may be indicative of atypical AVNRT and can be used to exclude other types of long RP tachycardia<sup>[18]</sup>. Para-Hisian pacing may be helpful to identify the presence of a retrograde conducting accessory pathway<sup>[19]</sup>. Recently, Para-Hisian entrainment has been demonstrated to fully differentiate orthodromic AVRT from AVNRT<sup>[20]</sup>. However, this elegant technique has its own limitations and particularly Para-Hisian resetting may be sometimes cumbersome.

**Study limitations:** One limitation of our technique is the fact that simultaneous AV extrastimulation during AVRT prevents the appreciation of ventricular induced atrial preexcitation. However, as soon as atrial refractoriness is reached the pacing maneuver resembles standard ventricular extrastimulation. A second limitation is the relatively small number of patients with atypical AVNRT, who are of major interest in the differential diagnosis to septal accessory pathways. Finally, calculation of PIs might be influenced by the fact that the further the pacing electrode is away from the anatomic location of the tachycardia circuit, the more premature the extrasystole must be to enter the reentrant circuit<sup>[21]</sup>.

### CONCLUSIONS

The use of simultaneous AV extrastimulation is a valid technique to determine the PI during SVT with retrograde concentric activation. Correction of the PIs for the underlying tachycardia cycle length enhanced the significance of this pacing maneuver. However, it is uncommon to unravel the mechanism of SVT on the basis of a single finding and occasionally tachycardia diagnosis is one of exclusion. Consequently, careful observation of tachycardia features together with application of multiple pacing maneuvers is considered most useful to determine the correct diagnosis of paroxysmal SVT.

### ACKNOWLEDGEMENTS

The authors are indebted to Chun Hwang, M.D., for his valuable ideas regarding this study.

### REFERENCES

1. Benditt, D.G., E.L. Pritchett, W.M. Smith and J.J. Gallagher, 1979. Ventriculoatrial intervals: diagnostic use in paroxysmal supraventricular tachycardia. *Ann. Intern. Med.* 91: 161-166.

2. Hwang, C., D.J. Martin, J.S. Goodman, E.S. Gang, W.J. Mandel, C.D. Swerdlow, C.T. Peter and P.S. Chen, 1997. Atypical atrioventricular node reciprocating tachycardia masquerading as tachycardia using a left-sided accessory pathway. *Am. J. Coll. Cardiol.*, 30:218-225.
3. Dizon, J., J. Reiffel, J. Kassotis, I. Woollett and H. Garan, 2003. Change in the retrograde atrial activation sequence following radiofrequency modification of the atrioventricular node: Implications for the electrophysiologic circuit of a variant of atrioventricular nodal reentrant tachycardia. *J. Cardiovasc Electrophysiol*, 14: 461-466.
4. Knight, B.P., M. Ebinger, H. Oral, M. H. Kim, C. Sticherling, F. Pelosi, G.F. Michaud and S.A. Strickberger, and F. Morady, 2000. Diagnostic value of tachycardia features and pacing maneuvers during paroxysmal supraventricular tachycardia. *J. Am. Coll. Cardiol.*, 36: 574-582.
5. Miles, W.M., R. Yee, G.J. Klein, D.P. Zipes and E.N. Prystowsky, 1986. The preexcitation index: An aid in determining the mechanism of supraventricular tachycardia and localizing accessory pathways. *Circulation*, 74:493-500.
6. Wagshal, A.B., S.K. Huang, L.A. Pires, R.S. Mittleman, O.T. Greene and C.D. Schuger, 1995. Use of double ventricular extrastimulation to determine the preexcitation index in atrioventricular nodal reentrant tachycardia. *Pacing Clin. Electrophysiol.*, 18:2041-2052.
7. Josephson, M.E., 1993. Supraventricular tachycardias. In: *Clinical Cardiac Electrophysiology: Techniques and Interpretations*. 2nd ed. Philadelphia, PA: Lea and Febiger.
8. Benditt, D.G., Jr. D.W. Benson, A. Dunnigan, G.C. Gornick, W.S. Ring, A. Almquist, H.G. Tobler and S. Milstein, 1987. Role of extrastimulus site and tachycardia cycle length in inducibility of atrial preexcitation by premature ventricular stimulation during reciprocating tachycardia. *Am. J. Cardiol.*, 60: 811-819.
9. Josephson, M.E. and J.M. Miller, 1993. Atrioventricular nodal reentry: evidence supporting an intranodal location. *Pacing Clin Electrophysiol* 16: 599-614.
10. Yamabe, H., I. Misumi, H. Fukushima, K. Ueno, Y. Kimura and Y. Hokamura, 1999. Electrophysiological delineation of the tachycardia circuit in atrioventricular nodal reentrant tachycardia. *Circulation*, 100: 621-627.

11. Inoue, S. and A.E. Becker, 1998. Posterior extensions of the human compact atrioventricular node: a neglected anatomic feature of potential clinical significance. *Circulation* 97:188-193. Erratum in: *Circulation*, 97: 1216.
12. Suzuki, F., T.O. Harada, T. Kawara, K. Tanaka, K. Hirao and K. Hiejima, 1991. Demonstration of right and left atrial dissociation by atrial rapid pacing or extrastimulation during fast-slow (uncommon) form of atrioventricular nodal reentrant tachycardia. *Pacing Clin. Electrophysiol.*, 14: 2010-2015.
13. Miller, J.M., M.E. Rosenthal, C.D. Gottlieb, J.A. Vassallo and M.E. Josephson, 1991. Usefulness of the delta HA interval to accurately distinguish atrioventricular nodal reentry from orthodromic septal bypass tract tachycardias. *Am. J. Cardiol.*, 68:1037-1044.
14. Tai, C.T., S.A. Chen, C.E. Chiang and M.S. Chang, 1999. Characteristics and radiofrequency catheter ablation of septal accessory atrioventricular pathways. *Pacing Clin Electrophysiol* 22:500-511.
15. Ormaetxe, J.M., J. Almendral, A. Arenal, J.D. Martinez-Alday, A. Pastor, J.P. Villacastin and J.L. Delcan, 1993. Ventricular fusion during resetting and entrainment of orthodromic supraventricular tachycardia involving septal accessory pathways: implications for the differential diagnosis with AV nodal reentry. *Circulation*, 88: 2623-2631.
16. Martinez-Alday, J.D., J.J. Almendral, A. Arenal, J.M. Ormaetxe, A. Pastor, J.P. Villacastin, O. Medina, R. Peinado, J.L. Delcan, 1994. Identification of concealed posteroseptal Kent pathways by comparison of ventriculoatrial intervals from apical and posterobasal right ventricular sites. *Circulation*, 89: 1060-1067.
17. Michaud, G.F., H. Tada, S. Chough, R. Baker, K. Wasmer, C. Sticherling, H. Oral, F. Pelosi, B.P. Knight, S.A. Strickberger and F. Morady, 2001. Differentiation of atypical atrioventricular node reentrant tachycardia from orthodromic reciprocating tachycardia using a septal accessory pathway by the response to ventricular pacing. *J. Am. Coll. Cardiol.*, 38: 1163-1167.
18. Man, K.C., M. Iebauer, E. Daoud, S.A. Strickberger, W. Kou, B.D. Williamson and F. Morady, 1995. Comparison of atrial-His intervals during tachycardia and atrial pacing in patients with long RP tachycardia. *J. Cardiovasc. Electrophysiol.*, 6: 700-710.
19. Hirao, K., K. Otomo, X. Wang, K.J. Beckman, J.H. McClelland, L. Widman, M.D. González, M. Arruda, H. Nakagawa, R. Lazzara and W.M. Jackman, 1996. Para-Hisian pacing. A new method for differentiating retrograde conduction over an accessory AV pathway from conduction over the AV node. *Circulation*, 94: 1027-1035.
20. Reddy, V.Y., K. Jongnarangsin, C.M. Albert, H. Sabbour, D. Keane, T. Mela, B. McGovern and J.N. Ruskin, 2003. Para-Hisian entrainment: a novel pacing maneuver to differentiate orthodromic atrioventricular reentrant tachycardia from atrioventricular nodal reentrant tachycardia. *J. Cardiovasc. Electrophysiol.*, 14: 1321-1328.
21. Goldberger, J., Y. Wang and M. Scheinman, 1992. Stimulation of the summit of the right ventricular aspect of the ventricular septum during orthodromic atrioventricular reentrant tachycardia. *Am. J. Cardiol.*, 70: 78-85.