

Hepatic Capillariosis in African Giant Rats (*Cricetomys gambianus*, Waterhouse) Around Zaria, Nigeria

¹S.J. Sambo, ¹N.D.G. Ibrahim, ¹H.M. Kazeem, ¹S. Adamu, ¹P.H. Mammam and ²M.N. Ali
¹Department of Veterinary Pathology and Microbiology, ²Department of Veterinary Anatomy,
Faculty of Veterinary Medicine, Ahmadu Bello University, Zaria, Nigeria

Abstract: Thirty-five adults clinically healthy African giant rats captured around Zaria were purchased for examination between April to August, 2006. Each rat was euthanized with chloroform and postmortem examination was conducted on them. Subsequently, a liver specimen was obtained from each rat and fixed in 10% buffered neutral formalin. They were later processed, sectioned at 5 µm thickness, stained with Haematoxylin and Eosin (H and E) technique and the slides were examined using the light microscope (Olympus®). Photomicrographs were taken with the Deluxe® photomicroscope (x40 Objective). Twenty-five (71.4%) of the rats had normal livers grossly, while 10 (28.6%) exhibited gross changes. There were whitish and grayish patchy areas of necrosis in 5 (14.3%), fatty change in 2 (5.7%) and slight congestion in 3 (8.6%) livers from the rats. Light microscopy revealed ova of *Capillaria hepatica* within the parenchyma of the livers from 2 (5.7%) of the rats which had hepatic necrosis grossly. The ova were predominantly immature, while few matured ones had the typical bipolar nature of ova of *Capillaria* sp. The preponderance of these ova distorted the parenchyma and compressed the hepatic cells in the affected areas. Mild fatty degeneration was observed in close association to the ova and elsewhere within unaffected portions of the hepatic parenchyma. The consumption of African giant rats may lead to human cases of capillariosis if not properly cooked or roasted.

Key words: Hepatic capillariosis, African giant rats, Zaria, Nigeria

INTRODUCTION

Capillaria hepatica is a helminth which occurs in the liver of numerous rodents (Soulsby, 1982) known to serve as important reservoirs of some parasitic zoonoses (Stojcevic *et al.*, 2002). The African giant rat (*Cricetomys gambianus*, waterhouse) is one of such rodents which live in close association with humans in Nigeria, especially in the rural communities, where they are widely eaten as a delicacy and socially acceptable for consumption (Ajayi and Olawale, 1971). Continuous hunting and eating of African giant rats was considered to be endangering the species, hence its domestication was attempted (Ajayi, 1974, 1975). Ajayi (1978) determined its growth performance on commercial rations.

The growing importance of African giant rats in Nigeria is obvious from the reports on their anatomy (Ogwuegbu and Aire, 1983; Oke *et al.*, 1988, 1989; Oke and Aire, 1990, 1996), ecology (Oke, 1985), the haematology (Oyewale *et al.*, 1998) and the plasma biochemical values (Olayemi and Adeshina, 2002) among

others. These provide the basic information which may be required to domesticate and adopt the African giant rat as a convenient experimental laboratory animal for investigating diseases of great significance to man and his domestic animals, as reported by Dipeolu *et al.* (1981).

It is, therefore, of paramount importance to record naturally occurring diseases of the African giant rats in the environment, especially those that are of significance to human health as capillariosis. The prevalence of Capillariosis due to *C. hepatica* was reported in the Norway rats, but there seems to be scarcity of information on the status of the disease in Nigeria, despite continuous consumption of the rodents. It is an established fact that human access to undeveloped areas inhabited by wild animals may provide room for disease hazards to man and domestic animals (Wells *et al.*, 1981). This study reports *C. hepatica* ova in sections of some livers obtained from African giant rats caught around Zaria, Nigeria. The findings call for proper and other forms of processing procedures of the meat as a means of control against capillariosis in both humans and rodents.

MATERIALS AND METHODS

Thirty-five adult African giant rats captured with locally made traps by hunters around Zaria were purchased for the purpose of this investigation. They were obtained in batches of 5 and kept in metal box shoe-like cages for an average of 3 days prior to examination between April to August, 2006.

Each rat was kept separately and euthanised with chloroform, followed by a detailed postmortem examination. Subsequently, a liver specimen was obtained from each of the examined rats and fixed in 10% buffered neutral formalin (Luna, 1968). These specimens were later processed, sectioned at 5 μ m thick and stained with Haematoxylin and Eosin (H and E) technique. The slides were examined using the light microscope and micrographs were taken with the Deluxe[®] photomicroscope (x40 objective).

RESULTS

Twenty-five (71.4%) of the African giant rats examined had no observable gross lesions in their livers, while 10 (28.6%) had various gross changes. From the later, there were whitish to grayish focal areas of necrosis 5 (14.3%), fatty change 2 (5.7%) and slight congestion 3 (8.6%) in the livers of the rats.

On microscopic examination, the ova of *Capillaria hepatica* were found within the parenchyma of the livers from 2(5.7%) of the rats; which had hepatic necrosis grossly (Plate 1-3). The ova seen on the sections were predominantly immature, while few mature ones had the typical bipolar nature of the ova of *Capillaria* species. The preponderance of these ova distorted the hepatic parenchyma and compressed the hepatic cells in affected

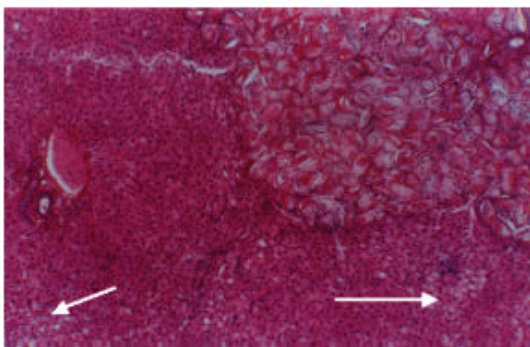


Plate 1: Photomicrograph of an African giant rat liver. Note the presence of ova of *Capillaria hepatica* in the liver parenchyma and the mild fatty degeneration (arrows). H and E stain. X 250

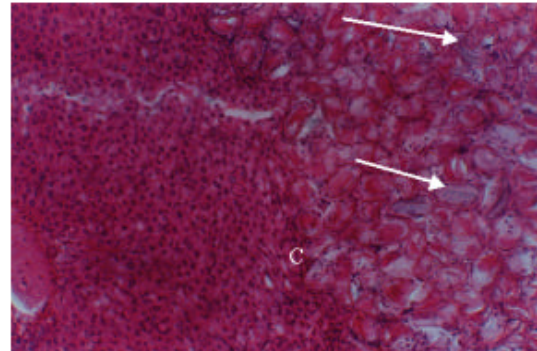


Plate 2: Photomicrograph of the same African giant rat liver in plate 1. Note the preponderance of immature ova of *Capillaria hepatica* with few mature ones (arrows) and compression of hepatic cells (C). H and E stain. X 400

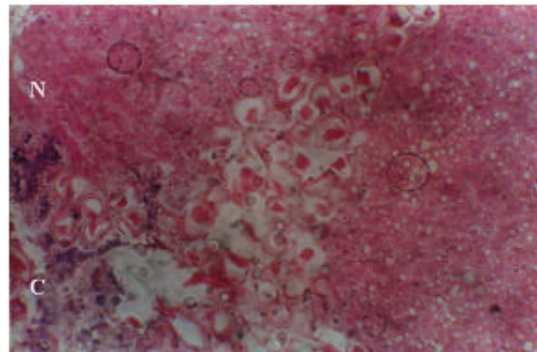


Plate 3: Photomicrograph of another African giant rat liver. Note the areas of calcification (C), necrosis of hepatic cells (N) and the fatty degeneration around the ova of *Capillaria hepatica*. H and E stain. X 250

areas; with infiltration of macrophages. A mild fatty degeneration was also observed in close association to the ova and elsewhere within unaffected portions of the hepatic parenchyma (Plate 1 and 2). There were also areas of necrosis, calcification and fatty degeneration, predominantly adjacent to the ova of *C. hepatica*, all of which appeared collapsed, in the section of liver from the second African giant rat (Plate 3).

DISCUSSION

The observation of various gross lesions on the livers of clinically healthy African giant rats examined in this study was similar to those described in the Norway rats of Croatia (Stojcevic *et al.*, 2002). However, the incidence of capillariosis in the rats (5.7%) being reported

in the present study is slightly higher than the 3.91% found in Croatia. This may be due to some species or environmental factors that favour the transmission of *C. hepatica* in the rats around Zaria.

Capillariosis, being a zoonotic disease (Soulsby, 1982; Stojcevic *et al.*, 2002) puts those people who hunt and eat the rats in Zaria and probably in Nigeria and other parts of the world, at risk of being affected by the disease. It has been recorded, in Colombia, that close interactions between man and wild mammals, especially in undeveloped areas may create disease hazards or reservoirs for man and his domestic animals (Wells *et al.*, 1981).

CONCLUSION

This study reveals a strong possibility that there may have been some uninvestigated cases of human capillariosis especially where infected rats were eaten as a delicacy in a poorly cooked or roasted state.

The presence of gross lesions in the livers of clinically healthy wild African giant rats suggest that those changes which may be found on experimental infections of this species of rats (Dipeolu *et al.*, 1981) could be affected by the naturally occurring pathologies of certain disease conditions. Therefore, the results of such experimental investigations with these rats being acquired from the wild environment need to be interpreted with caution. Consequently, the campaign for domestication of African giant rats (Ajayi, 1974; 1975) would need much emphasis at such a time as ours, both to control zoonoses and prevent the extinction of the species. Such effort will provide for a scientific way to increase the reproductive performance, increase the protein production and its quality for consumption in our local communities.

REFERENCES

- Ajayi, S.S and O.O. Olawale, 1971. Some indications of the social acceptance of the African Giant Rat in southern Nigeria. *Niger. J. For.*, 2: 36-37.
- Ajayi, S.S., 1974. The biology and domestication of the African Giant Rat (*Cricetomys gambianus*, water house). Ph.D Thesis, University of Ibadan, Ibadan.
- Ajayi, S.S., 1975. Domestication of African Giant Rat. Department of forest Resource management. University of Ibadan, pp: 1-44.
- Ajayi, S.S., 1978. Giant Rat (*Cricetomys gambianus*, water house) on commercial rations and varying dietary protein levels. *Lab. Anim.*, 12: 109-112.
- Dipeolu, O.O., O.A. Akinboade and F. Ogunji, 1981. Observation on the African Giant Rat (*Cricetomys gambianus*, water house), experimentally infected with solitary trypanosomes. *Bull. Anim. Health Prod. Afr.*, 29 (4): 393-397.
- Luna, L.G., 1968. Manual of Histologic Staining Methods of the Armed Forces Institute of Pathology. 3rd Edn. McGraw-Hill Book Company, New York, pp: 34-36.
- Ogwuegbu, S.O. and T.A. Aire, 1983. Histomorphometric photochemical and micro stereological studies and the accessory gland of the male African Giant Rat in Ibadan, Nigeria. *Afr. J. Ecol.*, 21: 329-333.
- Oke, A.O., 1985. Effect of season and the reproductive organs of the male African Giant Rat in Ibadan, Nigeria. *Afr. J. Ecol.*, 32: 67-70.
- Oke, A.O., T.A. Aire, O. Adeyemo and E. Health, 1988. Structure of the epididymis of the African Giant Rat: Histological physiochemical and microsteological studies. *J. Anatomy*, 160: 9-19.
- Oke, A.O., T.A. Aire, O. Adeyemo and E. Health, 1989. The ultrastructure of the epididymis of African Giant Rat. *J. Anatomy*, 65: 75-85.
- Oke, A.O. and T.A. Aire, 1990. Ultrastructure evidence of secretion in different zones of epididymis of the African Giant Rat. *Veterinarski Arhiv*, 60 (4): 207-222.
- Oke, A.O. and T.A. Aire, 1996. The coagulating gland of the African Giant Rat. *Trop. Veterinarian*, 14: 23-29.
- Olayemi, F.O. and E. Adeshina, 2002. Plasma biochemical values in the African Giant Rat (*Cricetomys gambianus*, water house) and the West African hunch backed tortoise (*Kinixys erosa*). *Veterinarski Arhiv*, 72 (6): 335-342.
- Oyewale, J.O., F.O. Olayemi and A.O. Oke, 1998. Hematology of the wild adult African Giant Rat (*Cricetomys gambianus*, water house). *Veterinarski Arhiv*, 68: 91-99.
- Soulsby, E.J.L., 1982. Helminths, Arthropods and Protozoa of Domestic Animals. 6th Edn. Bailliere Tindall, London, pp: 696-888.
- Stojcevic, D., A. Marinculic and Z. Mihaljevic, 2002. Prevalence of *Capillaria hepatica* in Norway rats (*Rattus norvegicus*) in Croatia. *Veterinarski Arhiv.*, 72 (3): 141-149.
- Wells, E.A., A.D. Alessandro, G.A. Marales and D. Angel, 1981. Mammalian wild life diseases as hazards to man and livestock in an area of lianos Orientales of Columbia. *J. Wild Life Dis.*, 17 (1): 153-161.