

## Dicephalic Atlodymus Monster Associated with Hydrops Amnii in a Buffalo Cow: A Case Report

H. El-Sheikh, A.O. Hegab and S.M. Zaabel  
Department of Theriogenology, Faculty of Veterinary Medicine,  
Mansoura University, Mansoura, Egypt

**Abstract:** A still born atlodymus dicephalus female buffalo calf was delivered after performing a caesarian section in a buffalo cow suffering from dystocia and hydrops amnii. The right head had a cleft palate. The pharynx, larynx and spinal cord of each head join its surpassing of the other head into a single trachea, esophagus and spinal cord, respectively. Hydrops amnii in this case was attributed to defective deglutition due to cleft palate.

**Key words:** Dicephalic calf, cleft palate, hydrops amnii, buffalo cow, deglutition, pharynx

---

### INTRODUCTION

Congenital duplication can be defined as imperfectly separated monozygotic twins with subsequent malformations ranging from partial duplication of one part of the body up to almost total formation of 2 fused feti (Easton, 1985; McGirr *et al.*, 1987; Sinowatz, 2010). Dicephalus (synonyms; double headed, two headed or cranial duplication) is a state of embryonic duplications which involve the head with or without involvement of the neck (Majeed *et al.*, 1971; Eichler and Krogh, 1985; Wakuri *et al.*, 1990; Madarame *et al.*, 1993, 1994; Otonari *et al.*, 1993; Bahr and Distl, 2004; Buck *et al.*, 2009). This report describes and discusses a case of dicephalus in a buffalo calf.

### CASE REPORT

A 5 year old primiparous buffalo-cow was presented to the clinic (Veterinary Educational Hospital, Faculty Veterinary Medicine, Mansoura University, Egypt) with a case history of dystocia and ruptured first water bag. Inspection of the animal revealed normal birth pain and a pear shaped abdomen from the rear view. Vaginal examination revealed a fully dilated cervix and an intact amniotic sac. Manual rupture of the amniotic sac was carried out with subsequent expulsion of a large amount of amniotic fluid. Further examination revealed a calf with a cranial duplication which could not be delivered per vagina and thus a caesarian section was carried out. A still born dicephalic calf was delivered.

### RESULTS AND DISCUSSION

The pear shaped abdomen and expulsion of a large amount of amniotic fluid are clear evidences about presence of hydrops amnii (hymdrannios) in this case. External inspection and necropsy of the fetus revealed a full term female buffalo calf with normal structures in the trunk, tail and limbs. Moreover, the internal organs were normal. The calf presented two complete and separate heads on a single neck. Both heads were nearly of the same size. Each head showed 2 eyes, 2 ears, mandible and maxilla (Fig. 1). Examination of the oral cavity showed that the right head had a cleft palate. Moreover, the two larynx and two pharynx fuse caudally with each other into a single trachea and esophagus, respectively (Fig. 2).

Each skull had its own 2 occipital condyles. Two fused atlas were adapted to receive the occipital condyles from each skull. The spinal cord from each skull merged with its surpassing after leaving atlas to form a single spinal cord (Fig. 3).

Any factor responsible for incomplete separation of the primitive streak after day 13 of fertilization is considered an etiological factor for congenital duplication. These factors may be genetic or environmental (Gilmore and Fehheimer, 1969; Easton, 1985; McGirr *et al.*, 1987).

Congenital anomalies result in economical losses as they result in dystocia with subsequent risks on the dam. Also, the lost calf is another financial lost (Roberts, 1986). Double headed calf represent a case of absolute fetal oversize with subsequent provoke of dystocia in animals. Such condition could be resolved through fetotomy or caesarian section (Long, 2009). In this case, caesarian section was carried out to enable further investigations.

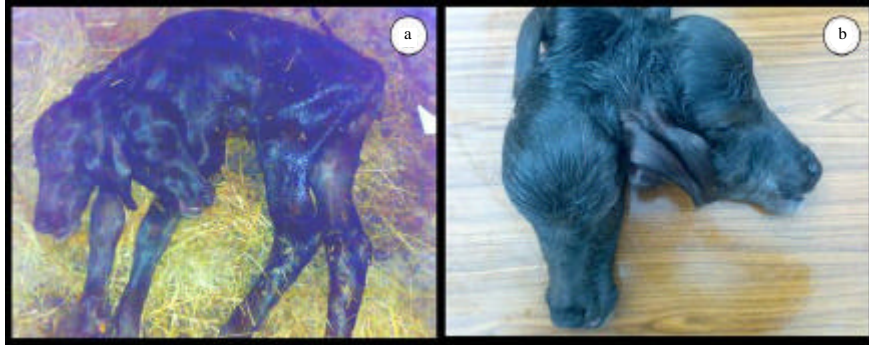


Fig. 1: Dicephalic female buffalo calf had 4 eyes, 4 ears, 2 mandibles and 2 maxilla (a, b)

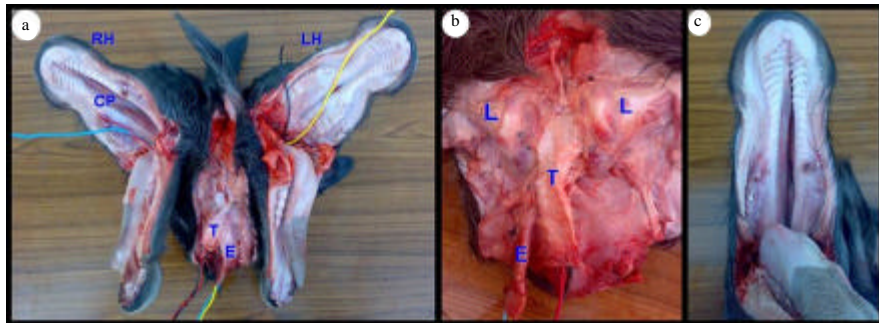


Fig. 2: The two larynx and two pharynx merge caudally with each other into a single trachea and esophagus, respectively (a, b). Cleft palate in the right head (a, c). RH; Right Head, LH; Left Head, CP; Cleft Palate, L; Larynx, T; Trachea, E; Esophagus

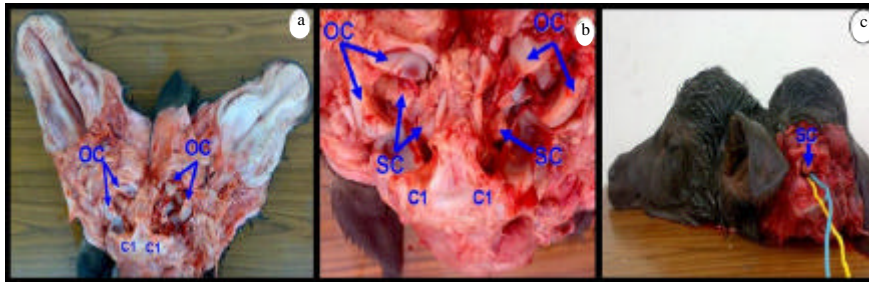


Fig. 3: Two fused atlas were adapted to receive the occipital condyles of both skulls (a, b). The spinal cord from each head merge with its surpassing after leaving the atlas to form a single spinal cord (b, c). OC; Occipital Condyle, C1; 1st cervical vertebrae (atlas), SC; Spinal Cord

Dicephalic fetus could be found as one of the following forms; Atlodymus (two complete and separate skulls and one neck), Iniodymus (two skulls with fusion at the occipital level) and Derodymus (two complete and separate skulls with 2 separate necks) as stated by Camon *et al.* (1992). According to the previously mentioned terms, this fetus was atlodymus dicephalus buffalo calf. Cleft palate (palatoschisis) usually result from partial or complete failure of apposition and fusion of the

palatine processes resulting in an opening between oral and nasal cavities (Sinowatz, 2010). Live calf with cleft palate will suffer from difficulty in suckling, dysphagia and dripping of milk from nostrils during suckling (Sinowatz, 2010).

Hymdrannios is defined as excessive accumulation of amniotic fluid in the amniotic sac. It could be the result of fetal anomalies such as impaired deglutition or renal dysgenesis or agenesis (Drost, 2007). The hymdrannios

reported in this case may be due to cleft palate and/or connection between the pharynx of both heads with subsequent impaired or defective deglutition with further accumulation of amniotic fluid.

#### REFERENCES

- Bahr, C. and O. Distl, 2004. Case report: Diphallus in a German Holstein calf. Dtsch Tierarztl Wochenschr, 111: 85-86.
- Buck, B.C., M. Zoeller, W. Baumgartner and O. Distl, 2009. A rare occurrence of dicephalus, scoliosis and complex heart anomalies in a male black and white German Holstein calf. Berl Munch Tierarztl Wochenschr, 122: 116-120.
- Camon, J., D. Sabate, J. Verdu, J. Rutllant and C. Lopez-Plana, 1992. Morphology of a dicephalic cat. Anat Embryol., 185: 45-55.
- Drost, M., 2007. Complications during gestation in the cow. Theriogenology, 68: 487-491.
- Easton, T.W., 1985. A possible mechanism of partial twinning in a calf. Anat. Rec., 212: 100-102.
- Eichler, V.B. and J.E. Krogh, 1985. Developmental abnormalities of a newborn two-headed calf, with special reference to the anterior vessels and compound heart. Vet. Pathol., 22: 189-191.
- Gilmore, L.O. and N.S. Fechheimer, 1969. Congenital abnormalities in cattle and their general etiological factors. J. Dairy Sci., 52: 1831-1836.
- Long, S., 2009. Abnormal Development of the Conceptus and Its Consequences. In: Veterinary Reproduction and Obstetrics, Noakes, D.E., T.J. Parkinson and G.C.W. England (Eds.). Saunders Ltd., London.
- Madarame, H., N. Ito and S. Takai, 1993. Dicephalus, arnold-chiari malformation and spina bifida in a Japanese black calf. Zentralbl Veterinarmed A, 40: 155-160.
- Madarame, H., S. Takai and N. Ito, 1994. Two-headed, two-necked conjoined twin calf with Arnold-Chiari malformation in a Japanese shorthorn calf. Anatomia Histologia Embryologia, 23: 275-280.
- Majeed, M.A., S.S. Hussain and G. Hur, 1971. The structure of a double-headed buffalo calf (*Dicephalus dipus dibrachius*). Vet. Rec., 88: 393-395.
- McGirr, W.J., G.D. Partlow and K.R. Fisher, 1987. Two-headed, two-necked conjoined twin calf with partial duplication of thoracoabdominal structures: Role of blastocyst hatching. Anat. Rec., 217: 196-202.
- Otonari, S., M. Nakai, R. Yamaguchi, M. Hagio and T. Nasu, 1993. Five cases of cranial duplication in calf. J. Vet. Med. Sci., 55: 493-495.
- Roberts, S.J., 1986. Veterinary Obstetrics and Genital Diseases. David and Charles Inc., Ithaca, New York.
- Sinowatz, F., 2010. Teratology. In: Essentials of Domestic Animal Embryology, Hyttel, P., F. Sinowatz and M. MVEjlsted (Eds.). Elsevier, USA., pp: 338-382.
- Wakuri, H., T. Mori and K. Mutoh, 1990. Arnold-Chiari malformation and associated anomalies in a dicephalic newborn calf. Okajimas Folia Anatomica Japonica, 67: 339-350.