



Comparative Pathology of Lymphoid Organs of Broiler Chicken in Commonly Encountered Disease Outbreaks

Basharat Maqbool and M.M. Darzi

Department of Veterinary Pathology, FVSc & AH, SKUAST-K, 190 006 Shuhama Alusteng, Jammu Kashmir

Key words: Lymphoid organs, broiler chickens, pathology, epithelial desquamation, disease

Abstract: The study was conducted to assess the pathological status of lymphoid organs in commonly encountered diseases of broiler chickens in Kashmir valley. Three types of disease outbreaks included Infectious bursal disease, Newcastle disease and Colibacillosis were studied. A total of 500 broiler chickens from each disease outbreak were examined. In case of IBD, the gross and histopathological changes were mainly in bursa of Fabricius which included enlargement, oedema, congestion, haemorrhages, necrosis, epithelial desquamation and lymphocyte depletion followed by changes in thymus, spleen, caecal tonsils and Harderian gland. In Newcastle disease, the severity of lesions like enlargement, stippled appearance, congestion, necrosis and lymphocyte depleted areas were more in spleen and caecal tonsils whereas in Colibacillosis the changes were more detectable in spleen viz; enlargement, stippled appearance, congestion and necrotic areas. Qualitative increase was observed in neutral and acid mucopolysaccharides and acid phosphatase activity while alkaline phosphatase showed mild activity in inflammatory epithelial areas of bursa, caecal tonsils and harderian gland in all the three disease outbreaks.

Corresponding Author:

Basharat Maqbool

Department of Veterinary Pathology, FVSc & AH, SKUAST-K, 190 006 Shuhama Alusteng, Jammu Kashmir

Page No.: 6-14

Volume: 10, Issue 2, 2017

ISSN: 1993-5412

Veterinary Research

Copy Right: Medwell Publications

INTRODUCTION

The avian immune system is composed of several lymphoid organs like thymus, bursa of Fabricius, spleen, caecal tonsils and Harderian gland which play an important role in defense mechanism thereby preventing pathogen entry and infection (Riddel, 2001). The thymus is a flat, multiple lobed organ, located in the neck in close association with the vagus nerve and jugular veins. It is the primary location for development of T lymphocytes. The bursa of Fabricius is an organ unique to birds and is the sole site of B cell maturation and differentiation. The

bursa is a blind sac on the dorsal surface of the cloaca, lined internally with major and minor longitudinal folds, containing the bursal follicles. Approximately 8,000-12,000 follicles are found in the bursa, consisting of a medulla and a cortex, with the cortex containing large numbers of closely packed lymphocytes (Glick, 1988). The spleen, a lymphocyte predominant organ, is a major site of antigen processing and antibody production in mature birds (Olah *et al.*, 2003).

The caecal tonsil can serve as an alternative location for B cell differentiation and plays a role in antibody production and cell-mediated immune functions. The

cecal tonsil is considered a prime site for virus isolation for diseases past the acute stage of infection, especially important in isolating infectious bronchitis. The Harderian gland is located behind the eyeball within the orbit and is the major secondary lymphoid organ of the HALT. The Harderian gland contains large numbers of plasma cells, with 80-90% of the cell population being B cells, thus, serves as the major antibody secreting accessory gland of the lacrimal apparatus and is important in development of vaccinal immunity (Sharma, 1991).

In the present scenario poultry has key contributions to global livestock production. Reproductive traits, a short productive lifespan, production of eggs and worldwide distribution, favour the use of poultry as a major source of animal protein. A good health status is necessary to maintain production and optimum feed conversion efficacy thereby securing an important and affordable animal protein source. However, some immunosuppressive diseases viz; Infectious Bursal Disease (IBD), Newcastle Disease (ND) and Colibacillosis have a negative impact on poultry health and production. Infectious bursal disease is one of the most important immunosuppressive viral diseases affecting the poultry industry worldwide. Infectious Bursal Disease Virus (IBDV), a member of the Birnaviridae family is highly tropic for the bursa of Fabricius and its main target are dividing B cells thereby leading to immunosuppression. Newcastle disease is a highly contagious disease of many avian species caused by viruses belonging to the avian paramyxovirus (APMV)-1 group, part of the genus *Avulavirus*, family Paramyxoviridae (Alexander, 2001). The histopathological changes viz; lymphoid depletion, necrosis and apoptosis in the spleen, thymus and bursa of Fabricius have been reported in ND infection (Brown *et al.*, 1999; Kommers *et al.*, 2003). Colibacillosis caused by *Escherichia coli* is a major problem encountered in poultry, especially, broilers in India. The disease is responsible for causing considerable economic losses to poultry farmers. *E. coli* infections were responsible for 8.9% mortality in broilers during the period from July 1987 to June 1990 in some parts of Haryana, India (Mahajan *et al.*, 1994).

These above immunosuppressive diseases have major effect on poultry health and production. Therefore, the status of the lymphoid organs can reflect the defensive capacity of the poultry bird to counter the infectious agents.

MATERIALS AND METHODS

Study area and sampling: The bird population under study comprised of broilers raised for commercial purposes in District Ganderbal, Pulwama, Budgam and Anantnag of Kashmir valley. The samples included the

diseased or dead broiler chickens received from various poultry farms in the Division of Veterinary Pathology. Complete history with regard to population, signs of the disease, along with its morbidity and mortality, were noted. The broiler chickens were then subjected to thorough post-mortem examination and the materials were collected for the following studies.

Pathology

Gross pathology: Broiler chickens were systematically subjected to detailed macroscopic examination with special emphasis on the lymphoid organs (bursa of Fabricius, Thymus, spleen, caecal tonsils and Harderian gland) and the lesions were recorded.

Histopathology: Representative tissue samples from the lymphoid organs like bursa of Fabricius, spleen, thymus, caecal tonsils and Harderian gland were collected in 10% formalin. The tissue samples were processed for routine paraffin embedding technique and 5 μ thin sections were stained with Harris' Haematoxylin and Eosin as per Luna.

Histochemistry: Parallel tissue sections were specially stained for demonstration of Acid and Neutral Mucin by Combined Alcian Blue PAS stain.

Histoenzymatic studies: Histoenzymatic study was carried out for the demonstration of alkaline-phosphatase and acid-phosphatase in tissue sections. Alkaline phosphatase was demonstrated by using Gomori's Calcium Cobalt method and Acid phosphatase by using Gomori's Lead Phosphate method (Gurr, 1958).

RESULTS AND DISCUSSION

The present study has focussed on the gross, histopathological, histochemical and histoenzymatic changes in the lymphoid organs of broiler chickens affecting with Infectious bursal diseases, Newcastle disease and Colibacillosis.

Gross pathology: In all the outbreaks of IBD bursa was the primary organ involved where it showed various types of lesions ranging from haemorrhages, oedema, congestion, presence of catarrhal exudate, necrotic foci, etc. which were in concordance with the findings of earlier workers (Zakeri and Kashefi, 2012). The increase in bursal size and weight in IBD could be attributed to the oedema, hyperaemia (Helmbodt and Garner, 1964; Cheville, 1967). The haemorrhages in bursa (Fig. 1) and in other lymphoid organs has been suggested as an immune mediated damage to the blood vessel in IBDV infection which is mainly due to the effect of macrophage

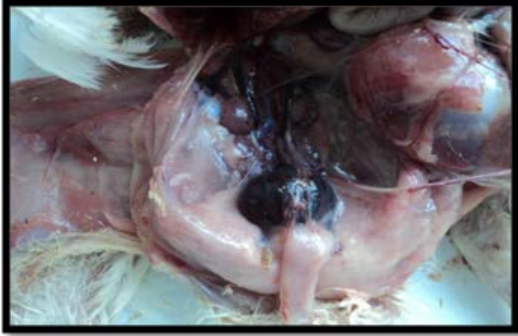

Fig. 1: Enlarged and dark red discolouration of bursa in IBD infected broiler chicken

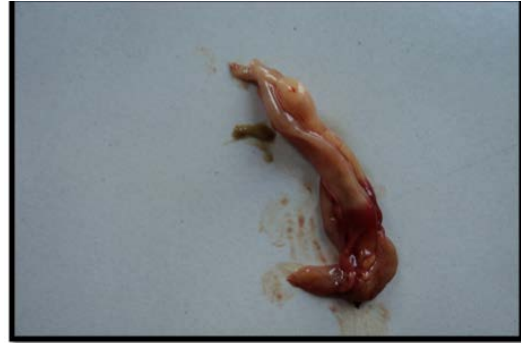

Fig. 3: Congestion and enlargement of caecal tonsils in ND affected broiler chicken

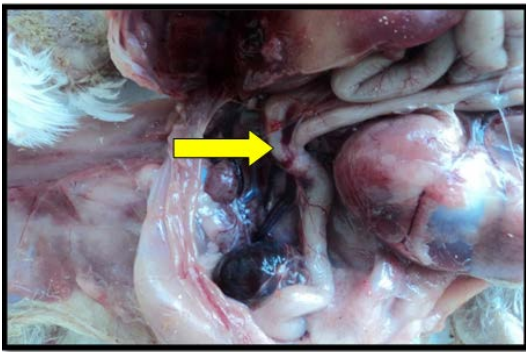


Fig. 2: Caecal tonsils were swollen (arrow) and haemorrhagic in IBD infected broiler chicken



Fig. 4: Congested and enlarged spleen in ND affected broiler chicken

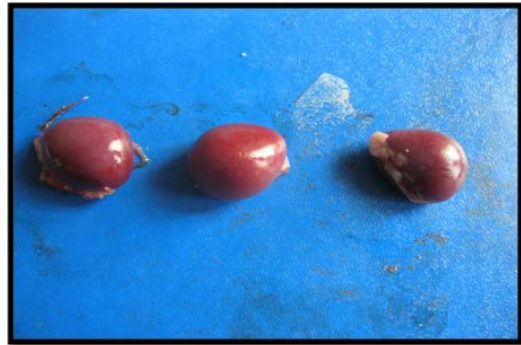

Fig. 5: Congestion and enlargement of spleen in Colibacillosis affected broiler chicken

derived Tumor Necrosis Factor (TNF) and interleukins or due to Disseminated Intravascular Coagulation (DIC) (Shibatani *et al.*, 1997; Dos-Santos *et al.*, 2004). The spleen was enlarged, congested and very often small grey foci were observed which were uniformly dispersed on the surface of the spleen as reported earlier. Thymus was slightly enlarged whereas the caecal tonsils were enlarged, haemorrhagic or congested (Fig. 2) which were similar to earlier findings (Hair *et al.*, 2004). However, no gross lesions were appreciable in Harderian gland.

In Newcastle disease outbreaks, grossly, the caecal tonsils and spleen were the most affected lymphoid organs. The caecal tonsils were haemorrhagic and enlarged (Fig. 3) whereas the spleen had a stippled appearance, congested and enlarged (Fig. 4) as reported earlier by Brown *et al.* (1999) and Mishra *et al.* (2000). The swelling of spleen and caecal tonsils was probably due to the inflammatory response and compensatory hyperplasia of lymphocytes in these organs that occurred during viral replication in these lymphoid tissues. The pathological changes in the splenic follicles and caecal tonsils could be attributed to the ND virus induced apoptosis. It is an antiviral mechanism of host defense

utilized by eukaryotic cells to minimize viral replication and reduce damage caused by infection while clearing the invading pathogens.

In Colibacillosis the gross lesions were more prominent in spleen which included enlargement and congestion (Fig. 5). Such findings were similar to those described by earlier workers (Nakamura *et al.*, 1985; Zanella *et al.*, 2000). The possible cause of lesions in case of *E. coli* infection could be attributed to its virulence factors like adhesions which play an important role in its

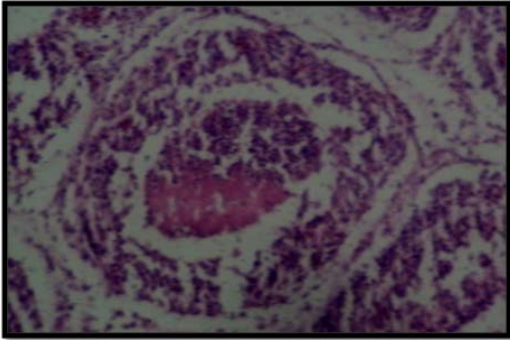


Fig. 6: Section of bursa of Fabricius of IBD affected broiler chicken revealing cellular infiltration, necrosis and lymphoid depletion HE. X600

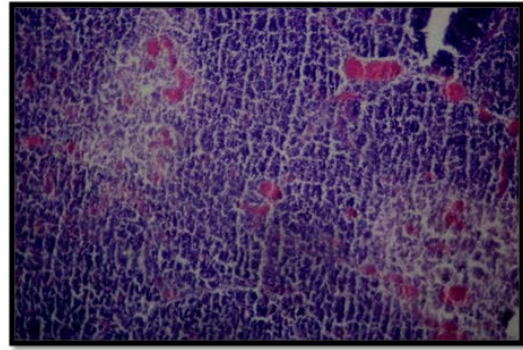


Fig. 7: Section of thymus of a broiler chicken affected with IBD revealing congestion and mild lymphoid depletion. HE. X300

colonization in the host as already reported (Babai *et al.*, 2000). Toxins like cytolethal distending toxin, cytotoxic necrotizing factor and Vacuolating Autotransporter Toxin (VAT) causing cytotoxic effects in cells had been reported by Parreira and Gyles (2003) and Rodriguez-Siek *et al.* (2005). The ability of iron acquisition mechanisms to obtain iron is important in the pathogenesis of Avian Colibacillosis (Dozois *et al.*, 2003; Sabri *et al.*, 2006). Similarly the ability of protectins to resist complement is a common characteristic in the pathogenesis of Colibacillosis (Nolan *et al.*, 2003). The invasins contributes to the invasion of bacteria into the deeper tissues of internal organs and thus plays a critical in the pathogenesis of *E. coli* infection (Germon *et al.*, 2005).

Histopathology: In Infectious bursal disease, the bursal follicles revealed severe lymphoid depletion, follicular necrosis, haemorrhages, cellular infiltration, congestion and epithelial desquamation (Fig. 6) which were similar findings as reported by Chevillie (1967) and Mandelli, etc. The pathogenesis of IBD had been attributed to the high concentration of virus produced by the bursa of Fabricius (Winterfield and Hitchner, 1962; Snedeker *et al.*, 1967). The haemorrhages in bursa and in other lymphoid organs has been suggested as an immune mediated damage to the blood vessel in IBDV infection which is mainly due to the effect of macrophage derived Tumor Necrosis Factor (TNF) and interleukins or due to Disseminated Intravascular Coagulation (DIC) (Shibatani *et al.*, 1997; Dos-Santos *et al.*, 2004). In thymus congestion, mild cortical depletion and necrosis were present (Fig. 7) and such findings are well supported by earlier reports (Williams and Davison, 2005). In spleen lymphoid depletion was observed in white pulp. These findings were in concordance with the earlier findings. Caecal tonsils revealed depletion and necrotic changes in the lymphoid follicle while as in the Harderian gland alveolar narrowing and

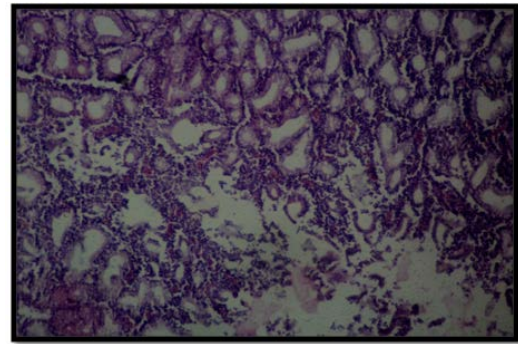


Fig. 8: Section of Harderian gland of a broiler chicken affected with IBD revealing alveolar narrowing, lymphoid depletion and epithelial desquamation. HE. X600

congestion were observed (Fig. 8). Such findings were supported by the earlier research findings (Nunoya *et al.*, 1992; Tanimura *et al.*, 1995).

The lesions observed histopathologically in case of IBD could be attributed to the release of Interferons by the virus infected cells (Gelb and Kleven, 1979). The interferon stimulates the production of many new proteins having antiviral activity. This will cause releasing of necrotic factors. Antibodies are released which may cause destruction of infected cells not only through complement mediated cytolysis but also through the activities of T cytotoxic cells by Antibody Dependent Cell mediated Cytotoxicity (ADCC) (Tizard, 1996). Due to the antiviral activity stimulation of macrophage, T cytotoxic and natural killer cells activated by the interferon lead to target cell degeneration and necrosis (Tizard, 1996) and thus, the lesions seen in the organs due to IBDV infections could be due to the immune mediated responses rather than massive viral replication (Skeeles *et al.*, 1980). In Newcastle Disease affected flocks the histopathological findings were more prominent in caecal tonsils. Lesions like cellular infiltration, lymphoid depletion, oedema and

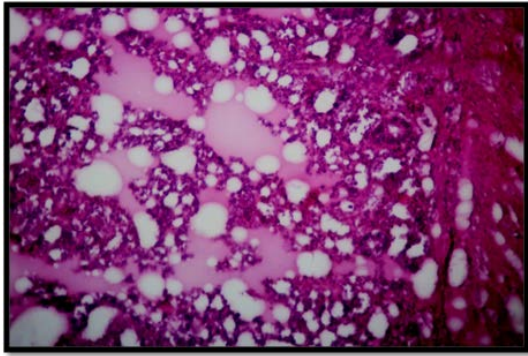


Fig. 9: Section of caecal tonsil of a broiler chicken affected with ND revealing necrotic areas and oedema. HE. X300

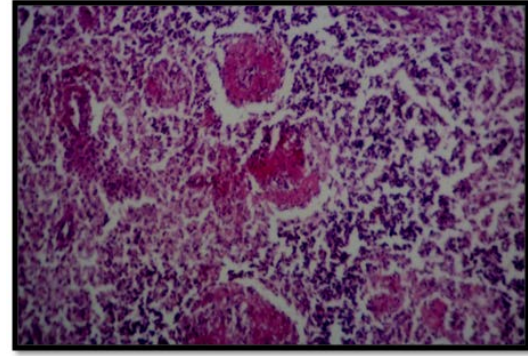


Fig. 11: Section of spleen of a broiler chicken affected with Colibacillosis revealing mild lymphoid depletion, inflammatory and necrotic changes. HE. X400

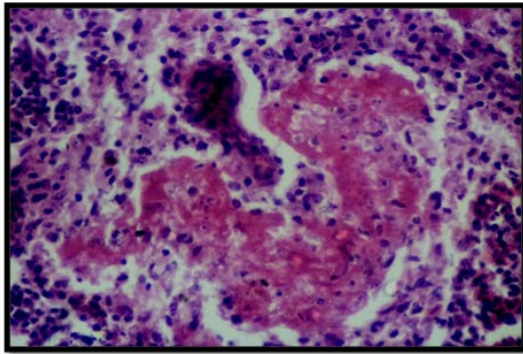


Fig. 10: Section of spleen of a broiler chicken affected with ND revealing necrosis and lymphoid depletion. HE. X400

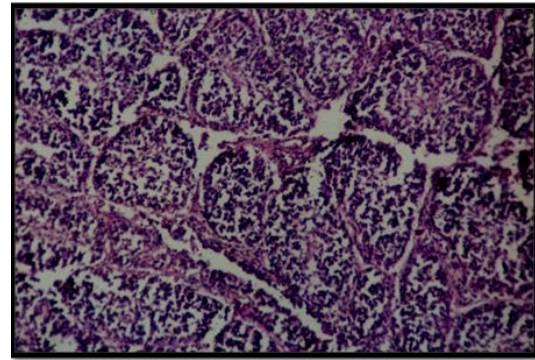


Fig. 12: Section of bursa of Fabricius of a broiler chicken affected with Colibacillosis revealing normal follicles. HE. X400

necrosis in lymphoid nodules of caecal tonsils (Fig. 9) were found in consonance with the findings of earlier workers (Hamid *et al.*, 1991; Anis *et al.*, 2013). Lymphoid depletion, inflammatory and necrotic changes observed in spleen (Fig. 10) and thymus were supported well by earlier workers (Banerje *et al.*, 1994; Kommers *et al.*, 2001). The lesions in bursa, thymus and spleen are described as a sequela to chronic necrosis or viral induced apoptosis (Elmore, 2006). The possible cause of lesions in case of Newcastle disease is attributed to the indirect viral effects in triggering apoptosis in macrophages, lymphocytes and other lymphoid cells in these lymphoid organs as reported by Anis *et al.* (2013).

In Colibacillosis, the spleen was the most affected organ. Congestion, inflammatory changes, depletion of lymphocytes and necrosis were observed in spleen (Fig. 11). These results are in agreement with the findings of earlier workers (Cheville and Arp, 1978; Truscott *et al.*, 1974; Nakamura *et al.*, 1985). The common histological findings in this study like focal necrosis, congestion and lymphocyte depletion in the

spleen support an active role for Chick Lethal Toxin (CLT) in the pathogenesis of *E. coli* disease (Truscott *et al.*, 1974). Normal follicles were observed in bursa (Fig. 12). However, in some broiler chickens mild lymphoid depletion observed in follicles was similar to the findings mentioned by earlier researchers (Cheville and Arp, 1978; Nakamura *et al.*, 1985). In thymus, the lesions like medullary congestion and mild cortical depletion (Fig. 13) were like those reported earlier (Truscott *et al.*, 1974; Nakamura *et al.*, 1985). The lymphoid depletion in bursa and thymus could be the result of toxins liberated by *E. coli*.

The pathogenesis of *E. coli* disease is complex, it may well be understood that capsular substances and endotoxin play a part in its early process of systemic invasion and dissemination (Truscott *et al.*, 1974). Medearis *et al.* (1968) suggested the type of endotoxin in *E. coli* which might be related to its ability to resist phagocytosis. The findings of Truscott and Inniss (1967) suggested a role for endotoxin in the pathogenesis of

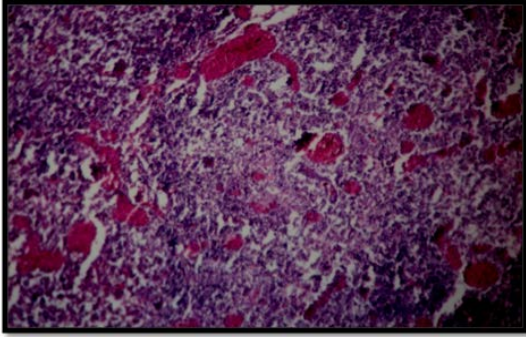


Fig. 13: Section of thymus of a broiler chicken affected with Colibacillosis revealing congestion and mild corticular depletion. HE. X300

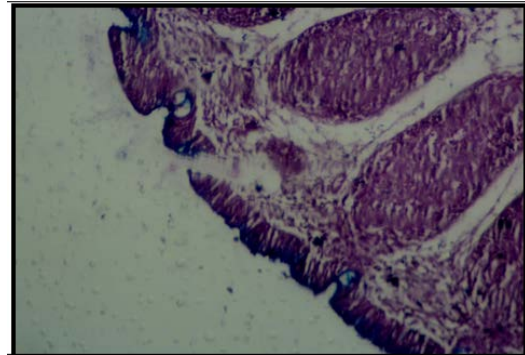


Fig. 15: Bursal epithelium positive for acid mucin. 5.7x10x

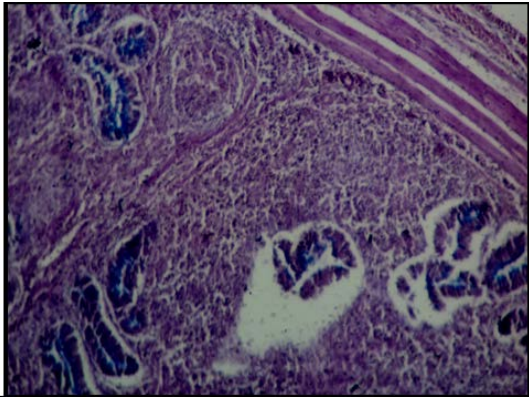


Fig. 14: Caecal glandular epithelium positive for acid mucin. 3.3x10X Normal

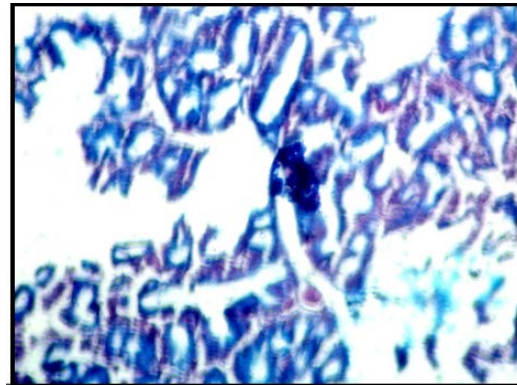


Fig. 16: Harderian gland positive for acid mucin inside epithelial cells. 4.9x10x

Colisepticemia. Rogers (1973) had suggested that the ability of *E. coli* strains to produce iron-binding catechols is related to their virulence, thus, further indicating the complexity of this process.

Histochemistry: Histochemical investigations revealed positive reaction for neutral mucopolysaccharide in the basement membranes while infiltrating cells, glandular epithelium, goblet cells, glandular secretions and hyperplastic cells were positive for acid mucopolysaccharides. These findings were in consonance with that of Tuli *et al.* (1992) who reported increased alcian blue positive material near the parasitic infestation in the mucosa indicating degenerative and necrotic changes. In present study the histochemical examination, in all the IBD infected groups reveals that only glandular epithelial cells and the areas with more inflammatory zones were found positive for acid mucopolysaccharides. Among all the lymphoid organs, the caecal glandular epithelium (Fig. 14), bursal follicular epithelium (Fig. 15) and the lobular epithelium of harderian gland (Fig. 16) were found positive for acid mucopolysaccharides but the

thymus, spleen and the lymphoid follicles present in all these lymphoid organs were positive for neutral mucopolysaccharides. However, in case of Colibacillosis and Newcastle Disease infected broiler chickens, same findings were observed as that of IBD except the caecal tonsils in Newcastle Disease where the caecal glandular epithelium was found to be more positive for acid mucopolysaccharides (Fig. 17) with no signs of acid mucin in the parenchymal tissue of any lymphoid organ. These findings were in consonance with that of Mobini (2012), Peters (1967) and Helmboldt and Garner (1964).

Various researchers have opined that hypersecretion of mucopolysaccharides in and around the lesions may be attributed to prolonged irritative action of insults. Qualitative increase in both acid and neutral mucopolysaccharides has been attributed to inflammatory process (Darzi *et al.*, 2003; Shah, 2009). Darzi *et al.* (2003) reported that the inflammatory exudates revealed qualitative increase in acid mucopolysaccharides and the basement membrane positive for neutral mucopolysaccharides in spontaneous hepatic coccidiosis in rabbits and opined that it constitutes a component of

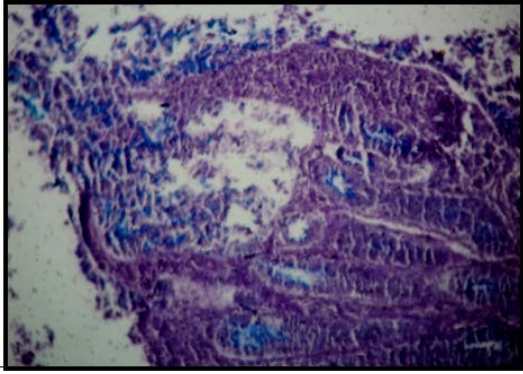


Fig. 17: Caecal glands positive for acid mucin. 2.8×10X

local defense reaction. The present study was also supported by Dezfuli *et al.* (2010) who found number of mucous cells close to the site of parasite attachment within the intestine significantly higher than the number detected in uninfected individuals and in infected individuals at sites 1 cm or greater from the point of parasite attachment staining positively for acid glycoconjugates. Increased production of mucopolysaccharides might also be attributed to their probable role in the inflammation and prolonged irritative action of different insults which are believed to determine hypersecretion of these substances (Lupu *et al.*, 1959).

Histoenzymatic study: Phosphatases are present in a wide variety of animal tissues. They are responsible for the hydrolysis of organic phosphate esters. Alkaline phosphatase exhibits optimal activity at high pH values while acid phosphatase exhibit optimal activity at low pH values (Bancroft, 1975). Wolf *et al.* (1942) has reported that nuclei of alveolar and bronchial cells in a normal lung revealed moderate to high acid phosphatase activity while cytoplasm stained occasionally. In present study an increased activity was observed in inflammatory regions. The staining of duplicate sections of lymphoid organs in case of IBD infected broiler chickens for acid phosphatase revealed a mild activity in bursal interfollicular epithelium, caecal epithelium and in lobular epithelium of harderian gland with the nuclei staining deeply and cytoplasm moderately. In all the lymphoid organs, the degenerating lymphatic nodules showed much lighter staining than normal ones. However, the tissue sections stained for alkaline phosphatase revealed mild reaction in inflammatory zone around the epithelial region of bursa, caecal tonsils and harderian gland with no enzyme activity observed in other lymphoid organs. In case of two other diseases, i.e., Newcastle disease and Colibacillosis, the histoenzymatic study of lymphoid organs revealed the same results as that of Infectious bursal disease with more strong enzyme activity in spleen and caecal tonsils in NCD and in spleen in case Colibacillosis. Humason

reported that acid phosphatase was almost exclusively associated with the lysosomes and considered it as a marker for them. Dawson) also, observed that acid phosphatases are lysosomal enzymes present within phagolysosomes of absorptive cells and in macrophages. The lysosomal theory for intracellular digestion has also been upheld for tumour regression and high acid phosphatase activity ascribed to presence of mononuclear cells in giant-cell tumours (Jeffree and Price, 1965). An increased acid phosphatase activity was also, noted in the areas of fibroplasias. It has been reported that acid phosphatase directly stimulate collagen synthesis (Ishibe *et al.*, 1991).

Alkaline phosphatase belongs to a class of enzymes with restricted tissue distribution. In the adult mammal, alkaline phosphatase is present in most tissues but high activities are found only in a few, thus, the small intestine, kidney, bone and placenta have specific activities one to two orders of magnitude above those of other organ (Moss and Handersson, 1999). Kabat and Furth (1940) reported that the usual alveolar epithelium did not contain alkaline phosphatase but cuboidal alveolar epithelium contained some of this enzyme. In present study only mild alkaline phosphatase activity was evident in inflammatory zone around the lymphoid organs. This is contrary to the reports of increased activity in the aspirates from chronic bronchitis (Kuhn and Kock, 1975) and in inflammatory exudate in cases of pleurisy (Sarojini and Ramakrishan, 1991; Syablo, 1991; Gazquez *et al.*, 1997; Metinatas *et al.*, 1997; Gupta *et al.*, 2004).

CONCLUSION

This study revealed that lymphoid organs showed marked pathological changes in IBD, Newcastle disease and Colibacillosis in broiler chicken thereby suggesting role of immunosuppression in all the encountered diseases. The bursal involvement was more intense in IBD alone whereas caecal tonsils involvement was more in ND and spleen was more affected in Colibacillosis. However, the Harderian gland showed changes in IBD denoting that IBD induced pathological changes in this particular gland.

REFERENCES

- Alexander, D.J., 2001. Gordon Memorial Lecture. Newcastle disease. Br. Poult. Sci., 42: 5-22.
- Anis, Z., T. Morita, K. Azuma, H. Ito, T. Ito and A. Shimada, 2013. Histopathological alterations in immune organs of chickens and ducks after experimental infection with virulent 9a5b Newcastle disease virus. J. Comparative Pathol., 149: 82-93.
- Babai, R., B.E. Stern, E.J. Hacker and E.Z. Ron, 2000. New fimbrial gene cluster of S-fimbrial adhesin family. Infect. Immun., 68: 5901-5907.

- Bancraft, J.D., 1975. Histochemical Techniques. 2nd Edn., Butterworths, London, Boston, ISBN: 9780407000339, Pages: 348.
- Banerjee, M., W.M. Reed, S.D. Fitzgerald and B. Panigrahy, 1994. Neurotropic velogenic Newcastle disease in cormorants in Michigan: Pathology and virus characterization. Avian Diseases, 38: 873-878.
- Brown, C., D.J. King and B.S. Seal, 1999. Pathogenesis of Newcastle disease in chickens experimentally infected with viruses of different virulence. Vet. Pathol., 36: 125-132.
- Cheville, N.F. and L.H. Arp, 1978. Comparative pathologic findings of *Escherichia coli* infection in birds. J. Am. Vet. Med. Assoc., 173: 584-588.
- Cheville, N.F., 1967. Studies on the pathogenesis of Gumboro disease in the bursa of fabricius, spleen and thymus of the chicken. Am. J. Pathol., 51: 527-551.
- Darzi, M.M., M.S. Mir, S.A. Kamil, N. Nashiruddullah and Z.H. Munshi, 2010. Pathological changes and local defense reaction occurring in spontaneous hepatic coccidiosis in rabbits (*Oryctolagus cuniculus*). World Rabbit Sci., 15: 23-28.
- Dezfuli, B.S., F. Pironi, M. Campisi, A.P. Shinn and L. Giari, 2010. The response of intestinal mucous cells to the presence of enteric helminths: Their distribution, histochemistry and fine structure. J. Fish Dis., 33: 481-488.
- Dos-Santos, B.M., M.P. Moraes, P.R. Barrios, S.Y. Marin and W.M. Nascimento, 2004. Occurrence of infectious bursal disease post vaccination with low passage attenuated vaccine. Arq Inst. Biol. Sao Paulo, 74: 511-513.
- Dozois, C.M., F. Daigle and R. Curtiss, 2003. Identification of pathogen-specific and conserved genes expressed in vivo by an avian pathogenic *Escherichia coli* strain. Proc. Natl. Acad. Sci. USA., 100: 247-252.
- Elmore, S.A., 2006. Histopathology of the lymph nodes. Toxicologic Pathol., 34: 425-454.
- Gazquez, I., J.M. Porcel, M. Vives, M.V. de Vera and M. Rudio, 1997. Pleural alkaline phosphatase in separation of transudative and exudative pleural effusions. Chest, 112: 569-570.
- Gelb, J. and S.H. Kleven, 1979. Studies on interferon induction by IBDV. Avian Dis., 23: 634-645.
- Germon, P., Y.H. Chen, L. He, J.E. Blanco and A. Bree et al., 2005. *ibeA*, a virulence factor of avian pathogenic *Escherichia coli*. Microbiology, 151: 1179-1186.
- Glick, B., 1988. Bursa of fabricius: Development, growth, modulation and endocrine function. CRC Crit. Rev. Poult. Biol., 1: 107-132.
- Gupta, K.B., V. Ghalaut, P.P. Gupta, P. Arora and S. Tandon, 2004. Efficiency of pleural fluid alkaline phosphatase and ratio to serum levels in distinguishing exudates from transudates. Lung India, 21: 46-49.
- Hair, B.L.W., M. Tee and U. Chulan, 2004. Response of gut associated lymphoid tissues of chickens to very virulent infectious bursal disease virus of Malaysian isolate. J. Anim. Vet. Adv., 3: 142-147.
- Hamid, H., R.S.F. Campbell and L. Parede, 1991. Studies of the pathology of velogenic Newcastle disease: Virus infection in non-immune and immune birds. Avian Pathol., 20: 561-575.
- Helmboldt, C.F. and E. Garner, 1964. Experimentally induced Gumboro disease (IBA). Avian Dis., 8: 561-575.
- Ishibe, M., R.N. Rosier and J.E. Puzas, 1991. Human prostatic acid phosphatase directly stimulates collagen synthesis and alkaline phosphatase content of isolated bone cells. J. Clin. Endocrinol. Metabolism, 73: 785-792.
- Jeffree, G.M. and C.H.G. Price, 1965. Bone tumours and their enzymes: A study of the phosphatases, non-specific Esterases and Beta-glucuronidase of Osteogenic and cartilaginous tumours, fibroblastic and giant-cell lesions. J. Bone Joint Surg., 47: 120-136.
- Kabat, E.A. and J. Furth, 1941. A histochemical study of the distribution of alkaline phosphatase in various normal and neoplastic tissues. Am. J. Pathol., 17: 303-318.
- Kommers, G.D., D.J. King, B.S. Seal and C.C. Brown, 2001. Virulence of pigeon-origin Newcastle disease virus isolates for domestic chickens. Avian Dis., 45: 906-921.
- Kuhn, S.H. and M.A. De Kock, 1975. A preliminary study of elevated alkaline phosphatase and cathepsin in bronchial aspirates of patients with lung cancer and bronchitis. Chest, 68: 326-330.
- Lupu, N.G., D. Velican, C. Velican and V. Olinescu, 1959. The action exerted by certain pneumoconiotic factors upon the acid mucopolysaccharide contents of pulmonary macrophages. Br. J. Ind. Med., 16: 244-247.
- Mahajan, N.K., N. Jindal and R.C. Kulshreshtha, 1994. Major broiler diseases in some parts of Haryana. Indian J. Animal Sci., 64: 1118-1122.
- Medearis Jr, D.N., B.M. Camitta and E.C. Heath, 1968. Cell wall composition and virulence in *Escherichia coli*. J. Exp. Med., 128: 399-414.
- Metintas, M., O. Alatas, F. Alatas, O. Colak, N. Ozdemir and S. Erginel, 1997. Comparative analysis of biochemical parameters for differentiation of pleural exudates from transudates: Light's criteria, cholesterol, bilirubin, albumin gradient, alkaline phosphatase, creatine kinase, and uric acid. Clinica Chimica Acta, 264: 149-162.
- Mishra, S., J.M. Kataria, K.C. Verma and R.L. Sah, 2000. Response of chickens to infection with Newcastle disease virus isolated from a guinea fowl. Trop. Anim. Health Prod., 32: 277-284.

- Mobini, B., 2012. Histological and histochemical studies on the Harderian gland in native chickens. *Vet. Med.*, 57: 404-409.
- Moss, D.W. and A.R. Handersson, 1999. *Teitz Text Book of Clinical Chemistry*. 3rd Edn., WB Saunders Co., Philadelphia, pp: 617-721.
- Nakamura, K., M. Maeda, Y. Imada, T. Imada and K. Sato, 1985. Pathology of spontaneous colibacillosis in a broiler flock. *Vet. Pathol.*, 22: 592-597.
- Nolan, L.K., S.M. Horne, C.W. Giddings, S.L. Foley, T.J. Johnson, A.M. Lynne and J. Skyberg, 2003. Resistance to serum complement, iss and virulence of avian *Escherichia coli*. *Vet. Res. Commun.*, 27: 101-110.
- Nunoya, T., Y. Otaki, M. Tajima, M. Hiraga and T. Saito, 1992. Occurrence of acute infectious bursal disease with high mortality in Japan and pathogenicity of field isolates in specific-pathogen-free chickens. *Avian Dis.*, 36: 597-609.
- Olah, I., N. Nagy, A. Magyar and V. Palya, 2003. Esophageal tonsil: A novel gut-associated lymphoid organ. *Poult. Sci.*, 82: 767-770.
- Parreira, V.R. and C.L. Gyles, 2003. A novel pathogenicity island integrated adjacent to the ThrW tRNA gene of avian pathogenic *Escherichia coli* encodes a vacuolating autotransporter toxin. *Infect. Immunol.*, 71: 5087-5096.
- Peters, G., 1967. The histology of gumboro disease infected birds. *Berlin. Muench. Tieraertel. Wochschr*, 80: 394-396.
- Riddel, C., 2001. *Avian Histopathology*. 2nd Edn., American Association of Avian Pathologists, Kennett Square, pp: 18-34.
- Rodriguez-Siek, K.E., C.W. Giddings, C. Doetkott, T.J. Johnson and L.K. Nolan, 2005. Characterizing the APEC pathotype. *Vet. Res.*, 36: 241-256.
- Rogers, H.J., 1973. Iron-binding catechols and virulence in *Escherichia coli*. *Infect. Immun.*, 7: 445-456.
- Sabri, M., S. Leveille and C.M. Dozois, 2006. A SitABCD homologue from an avian pathogenic *Escherichia coli* strain mediates transport of iron and manganese and resistance to hydrogen peroxide. *Microbiology*, 152: 745-758.
- Sarojini, B.L. and S. Ramakrishnan, 1991. Enzymes in biofluids for diagnosis of diseases. *Indian J. Clin. Biochem.*, 6: 143-148.
- Shah, I.H., 2009. Pathological and histochemical studies on paratuberculosis in goats. M.Sc. Thesis, Faculty of Postgraduate Studies, Sher-e-Kashmir University of Agricultural Sciences and Technology, Kashmir.
- Sharma, J.M., 1991. Overview of the avian immune system. *Vet. Immunol. Immunopathol.*, 30: 13-17.
- Shibatani, M., T. Suzuki, M. Chujo and K. Nakamura, 1997. Disseminated intravascular coagulation in chickens inoculated with *Erysipelothrix rhusiopathiae*. *J. Comp. Pathol.*, 117: 147-156.
- Skeeles, J.K., M. Slavik, J.N., Beasley, A.H. Brown, C.F. Meinecke, S. Maruca and S. Welch, 1980. An age-related coagulation disorder associated with experimental infection with infectious bursal disease virus. *Am. J. Vet. Res.*, 41: 1458-1461.
- Snedeker, C., F.K. Willis and I.M. Moulthrop, 1966. Some studies on the infectious bursal agent. *Avian Dis.*, 11: 519-528.
- Tanimura, N., K. Tsukamoto, K. Nakamura, M. Narita and M. Maeda, 1995. Association between pathogenicity of infectious bursal disease virus and viral antigen distribution detected by immunohistochemistry. *Avian Dis.*, 39: 9-20.
- Tizard, I.R., 1996. Resistance to viruses. *Vet. Immunol.*, 1: 300-313.
- Truscott, R.B. and W.E. Inniss, 1967. Studies on a lesion-inducing factor of avian strains of *Escherichia coli*. *Can. J. Microbiol.*, 13: 9-15.
- Truscott, R.B., J.L. Alvarez and J.R. Pettit, 1974. Studies of *Escherichia coli* infection in chickens. *Can. J. Comp. Med.*, 38: 160-167.
- Tuli, J.S., H.S. Bali and P.P. Gupta, 1992. Histopathology and Histochemical Studies of intestine in Cestodiasis of poultry. *Ind. J. Comp. Microbiol. Immun. Inf. Dis.*, 13: 100-104.
- Williams, A.E. and T.F. Davidson, 2005. Enhanced immunopathology induced by very virulent infectious bursal disease virus. *Avian Pathol.*, 34: 4-14.
- Winterfield, R.W. and S.B. Hitchner, 1962. Etiology of an infectious nephritis-nephrosis syndrome of chickens. *Am. J. Vet. Res.*, 23: 1273-1278.
- Wolf, A., E.A. Kabat and W. Newman, 1942. Histochemical studies on tissue enzymes. *Am. J. Pathol.*, 19: 423-440.
- Zakeri, A. and P. Kashefi, 2012. A study of programmed cell death in cecal tonsil of infected chickens by infectious Bursal disease virus with using electronic microscope. *Am. Eur. J. Agr. Environ. Sci.*, 12: 733-736.
- Zanella, A., G.L. Alborali, M. Bardotti, P. Candotti, P.F. Guadagnini, P.A. Martino and M. Stonfer, 2000. Severe *Escherichia coli* O111 septicaemia and polyserositis in hens at the start of lay. *Avian Pathol.*, 29: 311-317.