

## Outbreak of *Aeromonas hydrophila* Wound Infections in Siberian Sturgeon (*Acipenser baerii*): Case Study

<sup>1,2</sup>Maryam Azodi, <sup>2</sup>Rahim Paighan, <sup>1</sup>Anabita Rezai, <sup>3</sup>Mina Ahangarzadeh and <sup>4</sup>Hamed Aalamifar

<sup>1</sup>Department of Aquatic Health, Faculty of Veterinary,

<sup>2</sup>Shahid Chamran University, Persian Gulf Institute, University of Persian Gulf, Bushehr, Iran

<sup>3</sup>South Iranian Aquaculture Research Center, Ahwaz, Iran

<sup>4</sup>Department of Aquatic Health of Faculty of Veterinary, Shiraz University, Iran

**Abstract:** In December 2014, a total of 3 Siberian sturgeon were presented to the Aquatic Animal Health Laboratory of Veterinary Hospital of Shahid Chamran University. Iran with infected wounds and pustules distributed over their flanks. All samples were collected from a private fish farm, clinical signs and mortality. The wounds were deep and affected the underlying musculature and kidneys of some samples. Aseptic bacteriologic sampling was performed using TSA and blood agar. After histopathological sampling, the wet smear was taken from the wound to determine possible protozoan infection. Bacteria were isolated from all 3 fish. Gram staining, biochemical tests and PCR analysis confirmed the bacteria as *Aeromonas hydrophila*. Histopathological inspection revealed ulcers, haemorrhagic dermatitis, myositis, suppurative hepatitis and nephritis. According to the signs, pathological changes and bacteriologic samples, *Aeromonas hydrophila* may be regarded as the causative agent of the fish mortality.

**Key words:** Siberian sturgeon, *Aeromonas hydrophila*, PCR, pathology, haemorrhagic, samples

---

### INTRODUCTION

In cultured fish, bacteria are some of the most important causes of fish disease responsible for serious economic loss. Aeromonads are facultative saprophyte organisms in fresh and brackish water that can affect fish, reptiles, amphibians and other cold-blooded animals under non-optimal environmental conditions such as poor water quality, overcrowding and introduction of non-native species (Davis *et al.*, 1978; Semel and Trenholme, 1990; Janda and Abbot, 1998). *Aeromonas hydrophila* is an oxidase-positive, anaerobic unipolar, flagellated Gram-negative bacillus. It can be found in water, sewage, soil, vegetables as well as fish skin, gills and intestine (Gold and Salit, 1993; Janda and Duffy, 1988). This bacterium can cause different symptoms in different fish such as catfish, several species of bass. Many tropical species or ornamental fish with signs of decreased appetite, swimming abnormalities, pale gills, bloated appearance and ulcers on the skin may be infected by *Aeromonas hydrophila* however in the majority of the cases this pathogen causes the disease in three distinct forms, abdominal dropsy, skin ulceration, and generalized bacterial hemorrhagic septicemia (Khatun *et al.*, 2011).

In 2004, Siberian sturgeon (*Acipenser baerii*) were introduced to Iran and since, then attempts have been made to study the physiology, growth and feeding performance of this species under different rearing conditions (Anonymouse, 2008). High growth rates in different types of production systems (Williot *et al.*, 1993) and short sexual maturity in captivity (Ronayi and Peteri, 1990; Ronayi *et al.*, 1990) has made this species a candidate for culture in many countries. This study aimed to investigate the causes of mortality and skin infections in Siberian sturgeon and to the researchers knowledge this is the first report of observation of these kind skin ulcers in this species.

### MATERIALS AND METHODS

**Case presentation:** In August 2014, mortalities were reported in *Acipenser baerii* from a private fish farm. Fish were kept in raceway ponds with DO: 7.1 mg/L, pH: 7.44, stocking density: 35 kg/m<sup>3</sup> and water temperature 18-19°C. The average weight of the fish was 2100 g. At the beginning of the disease, the fish started to exhibit abnormal swimming behavior. There were some abscesses in lateral bony plaques, especially, in posterior part of the body. Additionally, reverse swimming and floating were observed in more than 50% of samples. After necropsy, tissue samples (1×1 cm) of kidney, liver, pyloric caeca,

Table 1: Details of primers used for detection of *Aeromonas sp.* and *Aeromonas hydrophila*

Reference	Size	Characteristic	Nucleotides	Primer
Porteen <i>et al.</i> (2006)	599	<i>Aeromonas sp.</i>	5'-TCA TGG CTC AGA TTG AAC GCT-3'	16 SrRNA F
	599	<i>Aeromonas sp.</i>	5'-CGG GGC TTT CAC ATC TAA CTT ATC-3'	16 SrRNA R
Dorsch <i>et al.</i> (1994)	685	<i>A. hydrophila</i>	5'-GAA AGG TTG ATG CCT AAT ACG TA-3'	16 SrRNA F
	685	<i>A. hydrophila</i>	5'-CGT GCT GGC AAC AAA GGA CAG-3'	16 SrRNA R

muscle and skin were taken and fixed in 10% formalin for pathological study. To detect the bacterial infection of the abscesses in aseptic situation, samples were taken from the kidney and ulcers of fish. The samples were cultured on TSA medium for primary isolation. The medium was incubated at room temperature (23-25°C). After streaking one typical colony on new plates, standard bacteriological methods were used for bacteria identification (e.g., Oxidation/fermentation, methyl red, phenylalanine deaminase, starch hydrolysis, gelatin liquefaction and carbohydrate utilization). PCR was used to confirm the bacterial species.

Genomic DNA was isolated from bacteria using boiling method. For this, typical colony was inoculated into TSA broth and incubated at 37°C overnight and then centrifuged at 5000×g for 10 min supernatant poured in a sterile petriplate. Thereafter, 1 mL PBS was added to the pellet and centrifuged for 10 min at 5000×g. Then, 250 µL distilled sterile water was added to pellet and the suspension boiled at 100×C for 10 min. Finally, the suspension was re-centrifuged for 10 min at 5000×g and 200 µL of supernatant was stored at -20°C until PCR analyses (Nielson *et al.*, 2001; Porteen *et al.*, 2006). The PCR assays were performed as described by Dorsch *et al.*, (1994) with some modification as follows: *Aeromonas sp.* 16 SrRNA (Porteen *et al.*, 2006) and *Aeromonas hydrophila* 16SrRNA primers were used (Table 1). Optimization of the PCR protocol was performed using 12.5 µL of PCR mixture (containing: MgCl<sub>2</sub>, dNTP, Tag Enzyme), 8.5 µL water DEPs, 1 µL of each primer and 2 µL template DNA (final volume of 25 µL). PCR amplification was performed using the following program: 1 cycle denaturation for 5 min at 94°C, 30 cycles of melting at 94°C for 30 sec, annealing at 55°C for 30 sec and elongation at 72°C for 45 sec and a final extension at 72°C for 10 min. Aliquots of 8 µL PCR products, positive control and negative control were electrophoresed in 1.5 agarose gel with safe stain color (Sina gene, Iran) for 1 h at 100 V that was visualized by UV light.

## RESULTS AND DISCUSSION

**Diagnostics and laboratory findings:** Abscesses were round, raised and white. In addition, they were 1.5-3 in diameter (Fig. 1). Inspection of abscesses revealed the

Table 2: Biochemical findings of cultured bacteria, *Aeromonas hydrophila*

Shape	Rod
Motility	Positive
Gram staining	Negative
Indole	Positive
MR	Negative
VP	Positive
Citrate utilization	Positive
Catalase	Positive
Urease	Negative
Oxidase	Positive
Carbohydrate utilization lactose	Positive
Glucose	Positive
Trehalose	Positive
Starch Hydrolysis	Positive
Gelatin Hydrolysis	Positive

existence of blood as well as clots on the muscles. No parasites were observed in the wet smears. Petechial hemorrhages were recorded on the visceral fat. The liver was pale in color (Fig. 2). There were abscesses in kidneys that adhered to the muscles. Black discolorations were also observed in the intestine.

Grown colonies were pure. Colony shape, arrangement, staining characteristics, oxidase and catalase activity revealed the bacterium to belong to the Aeromonaceae family. Characteristics of the bacteria are shown in Table 2.

PCR amplification revealed, bands with 599 bp considered as an *Aeromonas sp.* (Fig. 3) and bands with 685 bp consider as an *Aeromonas hydrophila* (Fig. 4). There was no amplification using these primers with DNA template of *E. coli* and *Pasteurella multocida*.

Microscopic findings of the skin were ulceration, ballooning degeneration and exocytosis of heterophils in the epidermis (Fig. 5). Also, haemorrhagic dermatitis was seen. It was characterized by hyperemia and hemorrhage in the dermis and hypodermis, between muscles and fat cells (Fig. 6). In this area, colonies of bacteria were observed (Fig. 7 and 8). Histopathological study of muscles revealed hemorrhagic myositis. There were diffuse accumulation of erythrocytes and inflammatory cells between striated muscles fibers. These foci were seen beneath the plaques. Additionally, basophilic rod shape bacteria were aggregated. Microscopic examination of liver showed diffuse lipidosis. There were different macro and micro vesicles in hepatocytes. Supportive hepatitis was also detected. Hetrophills were accumulated around vessels (Fig. 9 and 10). Kidney examination



Fig. 1: *Acipenser baerii*; Note to a white abscess on bony plaques (Arrow)

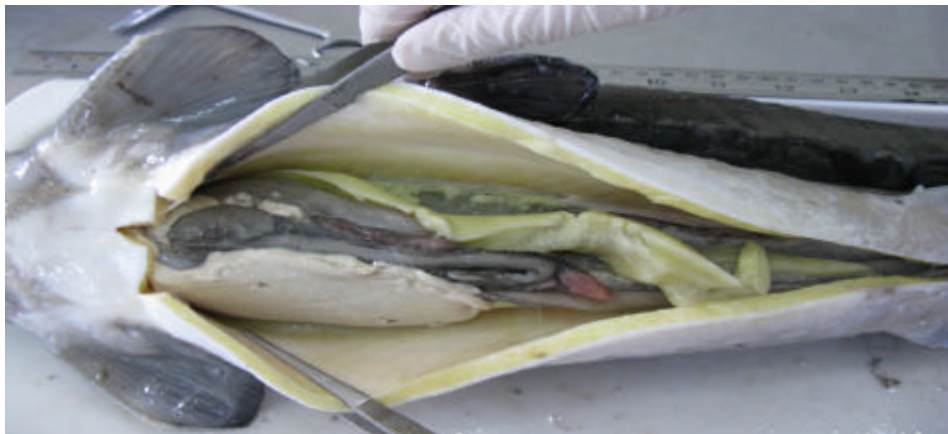


Fig. 2: *Acipenser baerii*; Note to white discoloration of liver

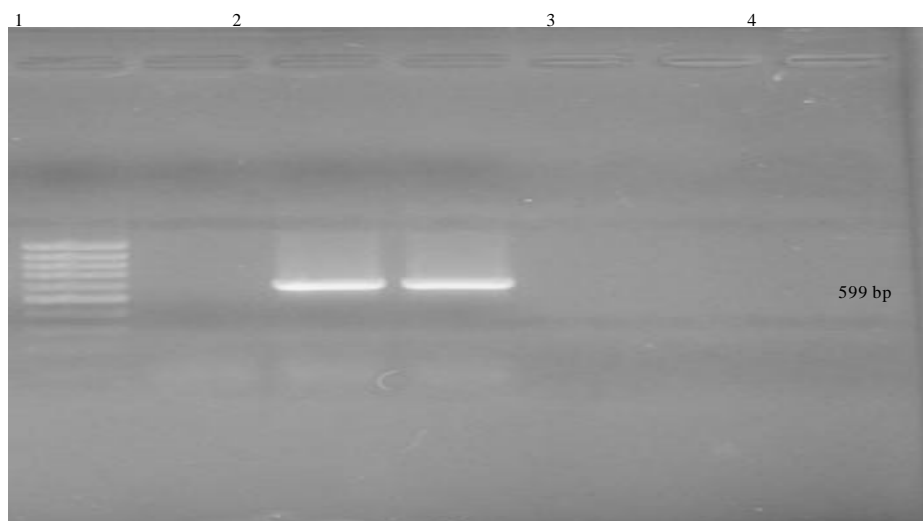


Fig. 3: Agarose specified gene electrophoresis of PCR products of *Aeromonas* genus Lane 1: 100 bp DNA Ladder (M)  
Lane 2: Negative control, Lane 4: Positive control Lane 3: Strains belong to *Aeromonas* genus (599 bp)

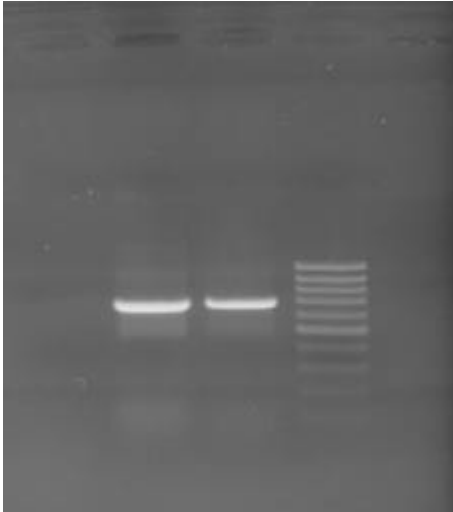


Fig. 4: Agarose 16srRNA gene electrophoresis of PCR products of *Aeromonas hydrophila*, Lane 4: 100 bp DNA Ladder (M) Lane 1: Negative control, Lane 3: Positive control, Lane 2: Strains belong to *Aeromonas hydrophila* (685 bp)

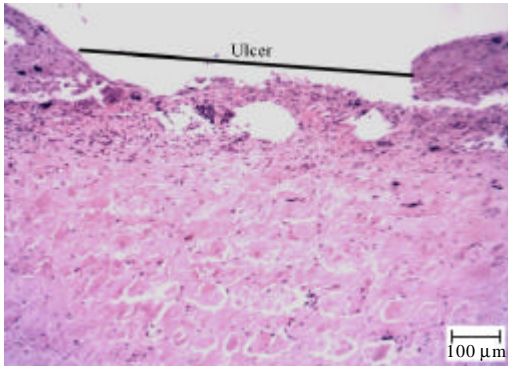


Fig. 5: *Acipenser baerii* skin. Note to desquamation of epidermis which shown with ulcer (H&E)

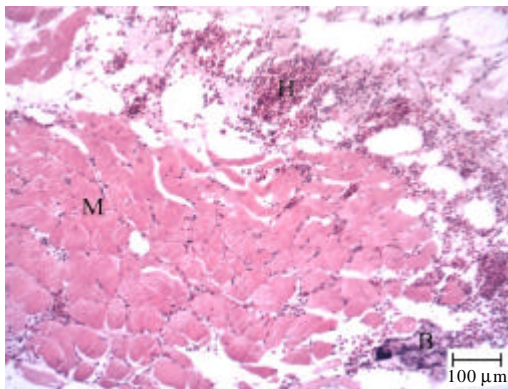


Fig. 6: *Acipenser baerii* skin. Note to Haemorrhage (H) in the dermis and between muscles fiber (M) (H&E)

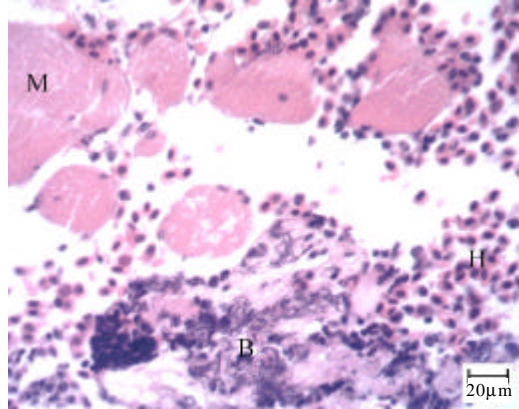


Fig. 7: Part of picture 6 with higher magnification. *Acipenser baerii* skin. Note to bacterial colony (B) and erythrocytes (H) accumulated between muscle fibers (M) (H&E)

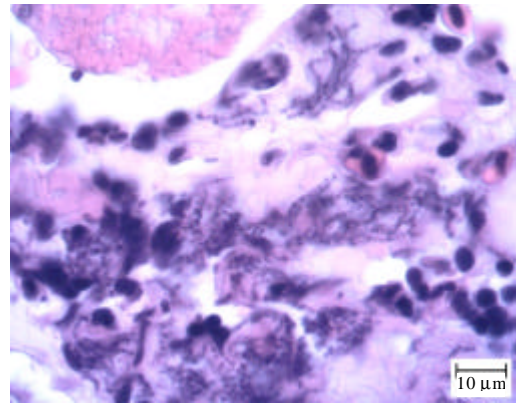


Fig. 8: Part of picture 7 with higher magnification. *Acipenser baerii* skin. Note to basophilic bacteria (H&E)

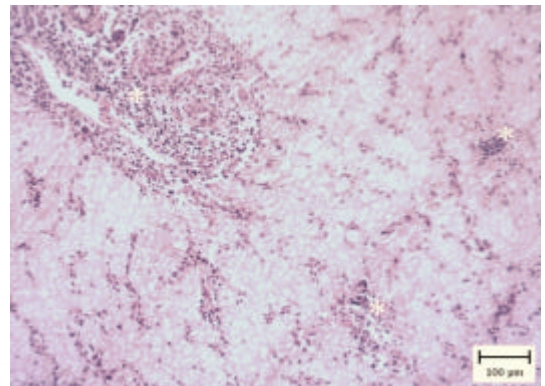


Fig. 9: *Acipenser baerii* liver. Note to vacuolated and clear hepatocytes. Also accumulation of inflammatory cells in portal area and around vessels (asterisks) are obvious (H&E)

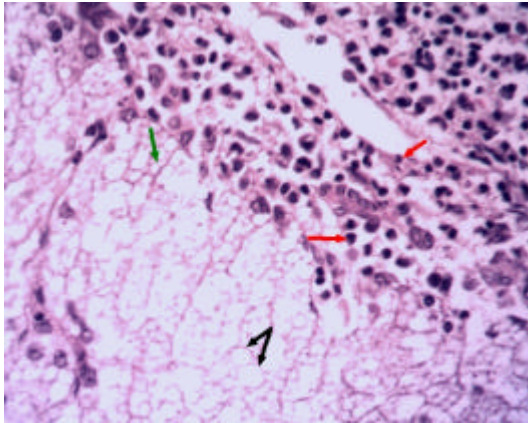


Fig. 10: Part of Fig. 9 with higher magnification. *Acipenser baerii* liver. note to small vacuoles (green arrow) and big vacuoles (dark arrows) in hepatocytes. Also, suppurative hepatitis was characterized by accumulation of different heterophils (red arrows) in portal area (H&E)

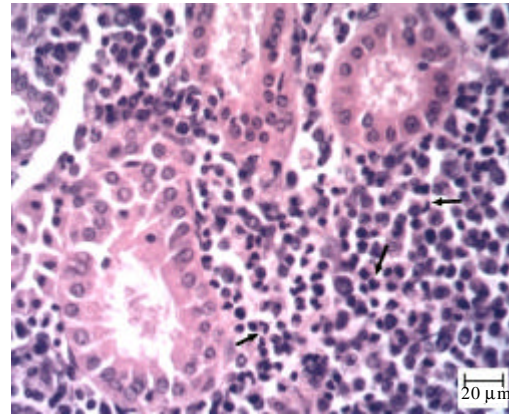


Fig. 12: Part of fig. 11 with higher magnification. *Acipenser baerii* kidney. note to different heterophils (arrows) between tubules (H&E)

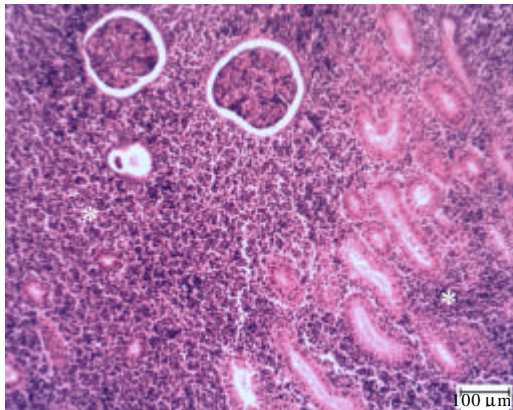


Fig. 11: *Acipenser baerii* kidney. Note to accumulation of inflammatory cells between tubules and glomerulus (asterisks) (H&E)

revealed Glomerulonephritis. Diffuse infiltration of inflammatory cells especially, heterophils were seen between tubules and glomerulus (Fig. 11 and 12).

*Aeromonads* that are present in aquatic environments can be readily isolated from both rich and poor environments (Holmes *et al.*, 1996). *Aeromonas hydrophila* as a fish pathogen, causing infections in carp, catfish and salmonids is associated with small surface lesions, sloughing of scales, local haemorrhage and septicaemia (Austin and Austain, 1987).

This study showed that *Aeromonas hydrophila* was the main causative agent of disease and mortality in

Siberian sturgeon. High prevalence of *Aeromonas hydrophila* could be due to the presence of this bacterium as a facultative organism moreover, this bacterium is a natural part of intestinal microflora and some environmental conditions such as stress can lead to an outbreak of this disease (Trust *et al.*, 1974; Kaper *et al.*, 1980; Len, 1987; Khalil and Mansour, 1997). Raverty and Nikl (1999) demonstrated that the cause of mortality in sturgeons in the Harrison River in British Columbia was *Aeromonas hydrophila*. Lartseva (1999) reported *Aeromonads*, enterobacteria and *Pseudomonads* isolated from sturgeons in the Volga River. These studies are in agreement with our results that *Aeromonas* genus can cause disease in sturgeons.

Common carp challenged with *Aeromonas hydrophila* exhibited pathological changes in the skin and muscle (Erer, 1981). We observed similar results in skin and bony plaques had ulcers, balloons and haemorrhage. Haemorrhage in dermis, hypodermis between muscles and at cells can be due to the production of extra cellular enzymes that have hemolytic and proteolytic activities (Austin and Austin, 1987). Focal haemorrhage and dermal lesions with ulcers were seen in chronic motile *Aeromonad* infection by Huizinga *et al.* (1979).

*Aeromonas hydrophila* putrefaction creates macroscopic and microscopic level depicted a visceral haemorrhagic septicemia in Nile tilapia (Yardiinci and Aydin, 2011) and in this study diffuse infiltration of inflammatory cells were also seen between tubules and glomerulus in kidney.

Yardiinci and Aydin (2011) observed diffuse haemorrhage and lymphocyte infiltration in the liver of Nile tilapia. Similarly, we observed a diffuse lipidosis in

the current study. The reason for lipidosis may be attributed to toxins, hemolysin, protease and elastase that produced by *Aeromonas hydrophila* (Lallier *et al.*, 1984; Khani and Wakabayashi, 1984; Nieto *et al.*, 1991; Rodriguez *et al.*, 1993; Gado, 1998; Afifi *et al.*, 2000). The variation between the results of the different studies can be explained by differences in species (physiological condition, immune responses fish age and size) and experimental conditions or differences in pathogenicity of the bacterium.

### CONCLUSION

Overall, this study is the first to recognize *Aeromonas hydrophila* in *Acipenser baerii* in freshwater ponds. Clinical symptoms are significant signs for detecting *Aeromonas hydrophila* that can result in mortality in fish but more studies are required to find treatments for fish, specifically sturgeons that are valuable cultured fish.

### ACKNOWLEDGEMENTS

The researchers should thanks the veterinary pathology laboratory staff for preparation of histopathologic sections. The Shahid Chamran University grants 2014 also appreciated for funding this study.

### REFERENCES

- Afifi, S.H., S. Al-Thobiati and M.S. Hazaa, 2000. Bacteriological and histopathological studies on *Aeromonas hydrophila* infection of Nile tilapia (*Oreochromis niloticus*) from fish farms in Saudi Arabia. Assiut Vet. Med. J., 84: 195-205.
- Anonymous, 2008. Production reports of International Sturgeon Research. International Sturgeon Research Institute, Rasht, Iran.
- Austin, B. and D.A. Austin, 1987. Bacterial Fish Pathogens: Disease in Farmed and Wild Fish. E. Horwood Publisher, Chichester, England, UK., ISBN:9780853128441, Pages: 364.
- Davis, W.A. II, J.G. Kane and V.F. Garagusi, 1978. Human *Aeromonas* infections: A review of the literature and a case report of endocarditis. Med., 57: 267-277.
- Dorsch, M., N.J. Ashbolt, P.T. Cox and A.E. Goodman, 1994. Rapid identification of *Aeromonas* species using 16S rDNA targeted oligonucleotide primers: A molecular approach based on screening of environmental isolates. J. Appl. Bacteriol., 77: 722-726.
- Erer, H., 1981. The investigation of the pathologic findings of experimental *Aeromonas hydrophila* infection (bacterial haemorrhagic septicaemia) in carp. Ph.D. Thesis, University in Ankara, Turkey.
- Gado, M.S.M., 1998. Studies on the virulence of *Aeromonas hydrophila* in Nile Tilapia (*Oreochromis niloticus*). Assiut Vet. Med. J., 40: 190-200.
- Gold, W.L. and I.E. Salit, 1993. *Aeromonas hydrophila* infections of skin and soft tissue: Report of 11 cases and review. Clin. Infect. Dis., 16: 69-74.
- Holmes, P., L.M. Niccolls and D.P. Sartory, 1996. The Ecology of Mesophilic *Aeromonas* in the Aquatic Environment, In: The Genus *Aeromonas*, Austin, B., M. Altwegg, P.J. Gosling and S. Joseph (Eds.), Wiley and Sons, Chichester, UK., pp: 127-150.
- Huizinga, H.W., G.W. Esch and T.C. Hazen, 1979. Histopathology of red-sore disease (*Aeromonas hydrophila*) in naturally and experimentally infected largemouth bass *Micropterus salmoides* (Lacepede). J. Fish Dis., 2: 263-277.
- Janda, J.M. and P.S. Duffey, 1988. Mesophilic *Aeromonas* in human disease: Current taxonomy, laboratory identification and infectious disease spectrum. Rev. Infect. Dis., 103: 980-997.
- Janda, J.M. and S.L. Abbott, 1998. Evolving concepts regarding the genus *Aeromonas*: An expanding panorama of species, disease presentations and unanswered questions. Clin. Infect. Dis., 27: 332-344.
- Kanai, K. and H. Wakabayashi, 1984. Purification and some properties of protease from *Aeromonas hydrophila*. Bull. Japanese Soc. Sci. Fish, 50: 1367-1374.
- Kaper, J.B., H. Lockman, R.R. Colwell and S.W. Joseph, 1980. *Aeromonas hydrophila*: Ecology and toxigenicity of isolates from an estuary. J. Applied Microbiol., 50: 359-377.
- Khalil, A.H. and E.H. Mansour, 1997. Toxicity of crude extracellular products of *Aeromonas hydrophila* in tilapia, *Tilapia nilotica*. Lett. Applied Microb., 25: 269-273.
- Khatun H., M.D. Hossain. S.N. Jahan and D.A. Khanom, 2011. Bacterial infestation in different fish at Rajshahi. J. Sci. Foundation, 9: 77-84.
- Lallier, R., F. Bernard and G. Lalonde, 1984. Difference in the extracellular products of two strains of *Aeromonas hydrophila* virulent and weakly virulent for fish. Can. J. Microbiol., 30: 900-904.
- Lartseva, L.V., 1999. Microbiological monitoring of sturgeon (*Acipenseridae*) in the Volga delta. J. Appl. Ichthyol., 15: 291-292.
- Len, P.P., 1987. Mesophilic spoilage of marine fish: Bay trout (*Arripis trutta*), Bream (*Acanthopagrus butcheri*) and mullet (*Aldrichetta forsteri*). Food Technol. Aust., 39: 277-282.

- Nielsen, M.E., L. Hoi, A.S. Schmidt, D. Qian and T. Shimada *et al.*, 2001. Is *Aeromonas hydrophila* the dominant motile Aeromonas species that causes disease outbreaks in aquaculture production in the Zhejiang Province of China?. *Dis. Aquat. Org.*, 46: 23-29.
- Nieto, T.P., Y. Santos, L.A. Rodriguez and A.E. Ellis, 1991. An extracellular acetylcholinesterase produced by *Aeromonas hydrophila* is a major lethal toxin for fish. *Microb. Pathogenesis*, 11: 101-110.
- Porteen, K., P.K. Agarwal and K.N. Bhilegaonkar, 2006. PCR-based detection of Aeromonas from milk samples. *J. Food Technol.*, 4: 111-115.
- Raverty, S. and L. Nikl, 1999. Sturgeon mortalities along the Harrison river British Columbia. *Anim. Health Center Newsl. Diagnosis Diary*, 9: 10-11.
- Rodriguez, L.A., A.E. Ellis and T.P. Nieto, 1993. Effects of the acetylcholinesterase toxin of *Aeromonas hydrophila* on the central nervous system of fish. *Microb. Pathogenesis*, 14: 411-415.
- Ronayai, A. and A. Peteri, 1990. Comparison of growth rate of Sterlet (*Acipenser ruthenus* L.) and hybrid of Sterlet x Lena river's sturgeon (*Acipenser ruthenus* L. x *Acipenser baeri stenorhynchus* Nikolsky). *Aquaculture Hungarica*, 6: 185-192.
- Ronayai, A., A. Ruttkay and L. Varadi, 1990. [Growth of Siberian Sturgeon (*Acipenser baeri* B.) and that of its both Hybrids with the Sterlet (*Acipenser ruthenus* L.) in Recycling System]. In: *Acipenser First International Symposium on Sturgeon*, Bordeaux, Patrick, W. (Ed.). Cemagref-Dicova, Buddington, Doroshov, ISBN:978-2853622080, pp: 423-427 (In French).
- Semel, J.D. and G. Trenholme, 1990. *Aeromonas hydrophila* water-associated traumatic wound infections: A review. *J. Trauma*, 30: 324-327.
- Trust, T.J., M.L. Bull, B.R. Currie and J.T. Buckley, 1974. Obligate anaerobic bacteria in the gastrointestinal microflora of the grass carp (*Ctenopharyngodon idella*), goldfish (*Carassius auratus*) and rainbow trout (*Salmo gairdneri*). *J. Fish. Res. Board Can.*, 36: 1174-1179.
- Williot, P., P. Bronzi and G. Arlati, 1993. A very brief survey of status and prospects of freshwater sturgeon farming in Europe. *Eur. Aquaculture Soc.*, 20: 32-36.
- Yardimci, B. and Y. Aydin, 2011. Pathological findings of experimental *Aeromonas hydrophila* infection in Nile tilapia (*Oreochromis niloticus*). *Ankara Univ. Vet. Fak. Derg.*, 58: 47-54.