

# ajava

Asian Journal of Animal and Veterinary Advances



Academic  
Journals Inc.

[www.academicjournals.com](http://www.academicjournals.com)

## Efficacy of Intra-peritoneal Administration of Iranian Honey in Prevention of Post-operative Peritoneal Adhesions

<sup>1</sup>Farnood Shokouhi Sabet Jalali, <sup>2</sup>Amir Abbas Farshid,  
<sup>3</sup>Siamak Saifzadeh and <sup>4</sup>Sara Javanmardi

<sup>1</sup>Department of Clinical Sciences, College of Veterinary Medicine,  
Urmia University, P.O. Box 57153-1177, Urmia, Iran

<sup>2</sup>Department of Pathobiology, College of Veterinary Medicine,  
Urmia University, Urmia, Iran

<sup>3</sup>Department of Clinical Sciences, Veterinary Faculty, Urmia University, Urmia, Iran

<sup>4</sup>College of Veterinary Medicine, Urmia University, Urmia, Iran

---

**Abstract:** The aim of this study was to examine the effectiveness of intra-peritoneal administration of honey in prevention or reduction of post-surgical peritoneal adhesions in dog. The study was conducted with 18 adult, female, mixed breed dogs with mean weight of  $20 \pm 4.25$  kg. A standardized surgical trauma (serosal trauma model) was made in the dogs' descending colon to induce adhesion formation. Control group (n = 9) received saline treatment and in experiment group (n = 9) the lesions were covered with honey. Three weeks after laparotomy, the dogs were sacrificed and the adhesions were graded according to their degree of severity based on Evans scoring system. Overall, 66.66% (n = 6) of the control animals and 22.22% (n = 2) of the experiment animals presented with moderate (grade 2) and severe (grade 3) adhesions. In the control group, there were 3 (33.33%) dogs with grade-0 or grade-1 adhesions but in the experiment group there were 7 (77.77%) dogs with the same grades of adhesions. The difference between two groups was shown to be significant ( $p < 0.05$ ). Based on the results of this study, it was concluded that honey appears to be a useful covering for damaged peritoneal surfaces and had high effectiveness in reducing post-operative adhesions.

**Key words:** Honey, intra-abdominal adhesion, intra-peritoneal

---

## INTRODUCTION

Adhesion formation is considered to be an inevitable result of surgical trauma to the peritoneal surfaces of the abdominal cavity (Menzie and Ellis, 1989; Burns *et al.*, 1996; Rogers *et al.*, 1997). For the development of adhesions between two surfaces inside the peritoneum, there must be peritoneal mesothelial damage on at least one surface (Hellebrekers *et al.*, 2000). Major complications that arise from postoperative peritoneal adhesions include intestinal obstruction, intra-abdominal abscess, ureteral obstruction, infertility and chronic pain (Montz *et al.*, 1991). In human the incidence of adhesion formation after a single abdominal operation is high, with an incidence over a lifetime of 47% after appendectomy and up to 91% after pelvic surgery (Ray *et al.*, 1993; Becker *et al.*, 1996; Burns *et al.*, 1996). With the hope of decreasing postsurgical adhesion formation, investigators have developed a variety of techniques to minimize the surgical trauma and several agents have been

---

**Corresponding Author:** Farnood Shokouhi Sabet Jalali, Department of Clinical Sciences,  
College of Veterinary Medicine, Urmia University, P.O. Box 57153-1177,  
Urmia, Iran Tel: +98 441 2774737/+98 914 341 9072 Fax: +98 441 2777099

introduced to decrease the inflammatory responses of the peritoneum and to solve this very serious problem of abdominal surgery (Ellis, 1982; Douglas *et al.*, 1997; Ustun *et al.*, 1998; Treutner and Schumpelick, 2000). A wide variety of barrier substances have been tested by investigators and biomedical companies to prevent adhesions after open abdominal surgery (Sravelos and Le, 1996; Alponat *et al.*, 1997; Rogers *et al.*, 1997; Treutner and Schumpelick, 2000). Honey has been a valued part of wound treatment for many centuries. It was first documented as a wound treatment by the Egyptians in 2000 BC (Gelbart, 1999; Tovey, 2000). Unlike other antiseptics, honey is said to cause no tissue damage (Molan, 1999). Physical properties of honey (i.e., hygroscopicity, lower pH and hypertonicity) are suggested to be responsible for its wound healing activities (Kaufman *et al.*, 1985; Efem, 1988; Mathews and Binning, 2002). Honey is used in many medical research studies, but it has never previously been tried in preventing post-operative peritoneal adhesion. Since healing of the peritoneal injury is a kind of wound healing process, the aim of this study was to identify whether peritoneal adhesions may be reduced with post-operative intra-peritoneal honey administration.

## MATERIALS AND METHODS

This study was performed on 18 adult, female mixed bred dogs with mean weight of 20±4.25 kg. The animals were selected randomly and divided into two equal groups. Following overnight fasting, all animals were tranquilized with acepromazine maleate (Hoogsrraten, Belgium) (0.05 mg kg<sup>-1</sup>, IM). General anesthesia was induced and maintained by intra-muscular injection of ketamine hydrochloride (alfasan, Woerden, Holland) (20 mg kg<sup>-1</sup>, IM). The dogs were then placed in the supine position and the abdomino-pelvic area was prepared for aseptic surgery. Laparotomy was performed routinely on all animals through a caudal midline abdominal incision of 10 cm length. After the peritoneal cavity was entered, descending colon was isolated with wet sterile gauze. The effects of intra-abdominal administration of honey on postoperative adhesion formation were evaluated using an established model of serosal trauma (Moll *et al.*, 1991; Chase *et al.*, 1996), to induce intra-abdominal adhesions. The descending colon was exposed and 10 cm of its terminal portion at antimesenteric border, just proximal to the pelvic inlet, was isolated. A dry gauze sponge was rubbed 100 times against the colonic serosa at this point, causing an abraded area approximately 3×4 cm. A single 3-0 monofilament nylon suture was then placed through the seromuscular layer of the colon in the center of the abraded area. In the control group only the serosal trauma model was performed and the abraded areas were washed with 0.9% NaCl solution. The same area in the dogs in the experiment group was covered with honey (10 mL). In this study, a local natural, unpasteurised honey was used. This honey was produced in Targaver region of Urmia. The average composition of the honey is given in Table 1. The abdominal incision was then closed in two layers with continuous 0 polyglactine 910 (Vicryl®) (Sherwood Davis and Geck, UK) suture.

Three weeks later, dogs were sacrificed with an IV injection of an overdose of thiopental sodium. The animals were autopsied and the abdominal cavities were entered and adhesions grade were

Table 1: Average composition of Targevar honey

Component	Average (%)
Reductant sugars	70.98
Sucrose	3.12
Fructose/Glucose	0.93
Diastase	+
Commercial glucose	-
Mineral components	0.05
Moisture	17.08
Concentration	82.92
Total acid	12.50
pH	3.96

+ : This honey has diastasis activity; - : This honey has not any commercial glucose

evaluated according to Evans's scoring system: 0 = No adhesion; 1 = spontaneously separating adhesions; 2 = Adhesions separating by traction; 3 = Adhesions separating by dissection (Evans *et al.*, 1993). Biopsy of adhesions was performed in some animals in which moderate and severe adhesions were present. Tissue was removed, fixed in 10% formalin and stained with hematoxylin and eosin. The Mann-Whitney U-test was used to determine differences in adhesion grading between control and experiment groups.  $p < 0.05$  was defined as statistically significant.

## RESULTS

There were 2 dogs (22/22%) in grade 0 and 1 (11/11%) in grade 1 in the control group, but the experiment group contained 3 dogs (33/33%) in grade 0 and 4 (44/44%) in grade 1 (Fig. 1). In the control group, there were 3 dogs (33/33%) in grade 2 and 3 (33/33%) in grade 3 (Fig. 2). In the experiment group there were 1 (11/11%) in grade 2, but 1 dogs (11/11%) in grade 3 (Table 2).

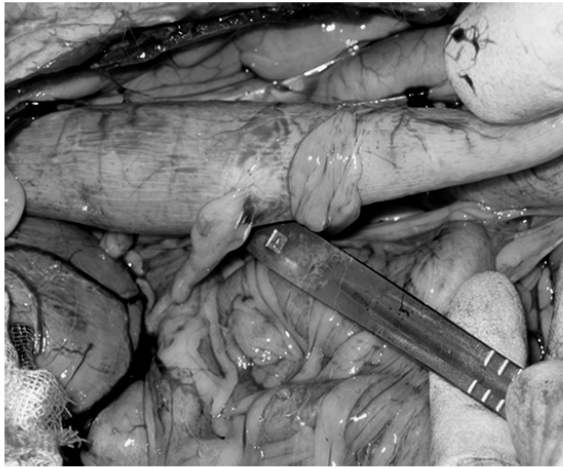


Fig. 1: Peritoneal adhesion formation in experiment group 3 weeks after surgical trauma (Grade 1)

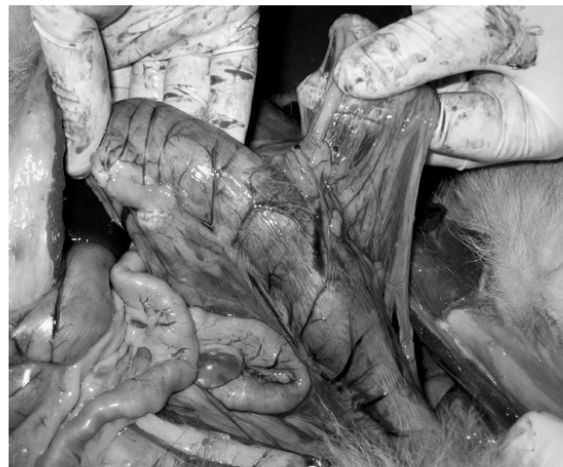

Fig. 2: Peritoneal adhesion formation in control group 3 weeks after surgical trauma (Grade 3)

Table 2: Grading of intra-abdominal adhesions in the studied groups based on Evans's scoring system ( $p < 0.05$  according to Mann-Whitney U-test)

Grade	Group	
	Control	Experiment
0	2 (22.22)	3 (33.33)
1	1 (11.11)	4 (44.44)
2	3 (33.33)	1 (11.11)
3	3 (33.33)	1 (11.11)

The values in parenthesis show percentages

Comparison of the two groups by Mann-Whitney U-test indicated that adhesion severity was significantly less in the experiment group ( $p < 0.05$ ).

Histological analysis revealed that honey did not induce a specific inflammatory reaction and caused a lower fibrotic response compared with the untreated group. The dominant cells in honey group were macrophages and polymorphonuclear neutrophils.

## DISCUSSION

In this experimental study, we attempted to assess the value of honey in prevention of postoperative peritoneal adhesions due to its effects on promotion of wound healing.

Serosal abrasion and intestinal ischemia models have been used to evaluate methods of preventing adhesion formation (Mueller *et al.*, 2000). The serosal abrasion technique requires less anesthesia and surgical time than ischemic models and consistently produces intra-abdominal adhesions (Mueller *et al.*, 2000; Boure *et al.*, 2002). In the present study, 7 of 9 (77.8%) control dogs showed intra-abdominal adhesions. Therefore, similar to previous reports, this model of serosal trauma reliably induced adhesion formation without excessive morbidity and mortality.

Innumerable substances and methods have been used, either locally or systemically in an effort to reduce or prevent post operative adhesion formation, such as prophylactic antibiotics, IP instillation of dextran, corticosteroid (Saravelos and Le, 1996), sodium citrate, heparin, prostigmine, olive oil and antihistamines (Ellis, 1982). Organic (ox peritoneum) or bioabsorbable inorganic (Seprafilm, Genzyme Co., USA) membranes were used in order to apply mechanical separation of the peritoneal surfaces (Alponat *et al.*, 1997). To the best of our knowledge, none of these therapies are ideal and these materials had only limited success in prevention of intra-abdominal adhesion formation.

The use of honey as medicine is mentioned in the most ancient written records.

In the modern medicine, many practitioners have noticed the effectiveness of honey in the healing of various types of wounds, burns and ulcers (Subrahmanyam, 1998).

Honey's high osmolarity, acidic pH, inhibin factor and nutrient content contribute to the inhibition of bacterial growth and the promotion of wound healing (Subrahmanyam, 1991; Philips, 1993).

In the present study, although the mechanism of honey action is obscure, covering the damaged serosal surface of descending colon with honey significantly decreased the development of postoperative peritoneal adhesion. This effect is thought to be due to two reasons: first, an increased healing process of honey is due to physical and chemical properties of this natural material, such as high osmolarity, high acidity, high monosaccharides, low active water and nutrient content and second, mechanical separation of damaged peritoneal surfaces by honey. The latter property of honey is probably related to its high viscosity and hypertonicity and also late absorption of honey.

However more detailed studies are needed to clarify the precise effects of honey on the tissue healing process.

## REFERENCES

- Alponat, A., S.R. Lakshminarasappa, N. Yavuz and P.M. Goh, 1997. Prevention of adhesions by Seprafilm, an absorbable adhesion barrier: An incisional hernia model in rats. *Am. Surg.*, 63: 818-819.
- Becker, J.M., M.T. Dayton, V.W. Fazio, D.E. Beck, S.J. Stryker and S.D. Wexner, 1996. Prevention of postoperative abdominal adhesions by a sodium hyaluronate-based bioresorbable membrane: A prospective, randomized, double-blind multicenter study. *J. Am. Coll. Surg.*, 183: 297-306.
- Boure, L.P., S.G. Pearce, C.L. Kerr, J.L. Lansdown, C.A. Martine, A.L. Hathway and J.L. Caswell, 2002. Evaluation of laparoscopic adhesiolysis for the treatment of experimentally induced adhesions in pony foals. *Am. J. Vet. Res.*, 63: 289-294.
- Burns, J.W., K. Skinner, M.J. Colt, L. Burgess, R. Rose and M.P. Diamond, 1996. A hyaluronate based gel for the prevention of postsurgical adhesions: Evaluation in two animal species. *Fertil. Steril.*, 66: 814-820.
- Chase, J.P., W.L. Beard, A.L. Bertone and K. Goltz, 1996. Open peritoneal drainage in horses with experimentally induced peritonitis. *Vet. Surg.*, 25: 189-194.
- Douglas, B.J., E.R. Kathleen and D.D. William, 1997. Reduction of adhesion formation by postoperative administration of ionically cross-linked hyaluronic acid. *Fertil. Steril.*, 68: 37-42.
- Efem, S., 1988. Clinical observations on the wound healing properties of honey. *Br. J. Surg.*, 75: 679-681.
- Ellis, H., 1982. The causes and prevention of intestinal adhesions. *Br. J. Surg.*, 68: 241-243.
- Evans, D.M., K. Mc Aree and D.P. Guyton, 1993. Dose dependency and wound healing aspects of the use of tissue plasminogen activator in the prevention of intra-abdominal adhesions. *Am. J. Surg.*, 165: 229-232.
- Gelbart, M., 1999. Wounds in Time: The History of Wound Management. In: *Wound Management*. Miller, H. and D. Glover (Eds.), London, NT Press. PP: 304-306
- Hellebrekers, B., T. Trimbos-Kemper, J. Trimbos Emeis and T. Kooistra, 2000. Use of fibrinolytic agents in the prevention of post-operative adhesion formation. *Fertil. Steril.*, 74: 203-212.
- Kaufman, T., E.H. Eichenlaub and M.F. Angel, 1985. Topical acidification promotes healing of experimental partial thickness skin burns: A randomized double-blind preliminary study. *Burns*, 12: 84-90.
- Mathews, K.A. and A.G. Binning, 2002. Wound management using honey. *Compend. Con. Edu.*, 24: 53-59.
- Menzies, D. and H. Ellis, 1989. Intra-abdominal adhesions and their prevention by topical tissue plasminogen activator. *J. R. Soc. Med.*, 82: 534-553.
- Molan, P.C., 1999. The role of honey in the management of wounds. *J. Wound Care*, 8: 415-418.
- Moll, H.D., J. Schumacher, J.C. Wright and J.S. Spano, 1991. Evaluation of sodium carboxymethylcellulose for prevention of experimentally induced abdominal adhesions in ponies. *Am. J. Vet. Res.*, 52: 88-91.
- Montz, F.J., J. Fowler, A.J. Wolff, S.M. Lacey and M. Mohler, 1991. The ability of recombinant tissue plasminogen activator to inhibit post-radical pelvic surgery adhesions in the dog model. *Am. J. Obstet. Gynecol.*, 165: 1539-1541.
- Mueller, P.O., W.P. Hay, B. Harmon and L. Amoroso, 2000. Evaluation of a bioresorbable hyaluronate-carboxymethylcellulose membrane for prevention of experimentally induced abdominal adhesions in horses. *Vet. Surg.*, 29: 48-53.
- Philips, C.E., 1993. Honey for burns. *Gleaning in Bee Culture*, 61: 284.
- Ray, N.F., J.W. Larsen, R.J. Stillman and R.J. Jacobs, 1993. Economic impact of hospitalization for lower abdominal adhesiolysis in the united states in 1988. *Surg. Gynecol. Obstet.*, 176: 271-276.

- Rogers, K.E., B.D. Johns, W. Girgis, J. Campeau and G.S. Di Zerega, 1997. Reduction of adhesion formation with hyaluronic acid after peritoneal surgery in rabbits. *Fertil. Steril.*, 67: 553-558.
- Sravelos, H.G. and T.C. Le, 1996. Physical barrier in adhesion prevention. *J. Reprod. Med.*, 41: 42-51.
- Subrahmanyam, M., 1991. Topical application of honey in treatment of burns. *Br. J. Surg.*, 78: 497-498.
- Subrahmanyam, M., 1998. A prospective randomized clinical and histological study of superficial burn wound healing with honey and silver sulfadiazine. *Burns*, 24: 157-161.
- Tovey, F., 2000. Honey and sugar as a dressing for wounds and ulcers. *Trop. Doctor*, 30: 1.
- Treutner, K.H. and V. Schumpelick, 2000. Adhesion prevention. *Wish Reality Chirug.*, 71: 510-517.
- Ustun, C., F.F. Yanik, I. Kocak, M.A. Canbaz and R. Cayli, 1998. Effects of Ringer's lactae, medroxyprogesterone acetate, gonadotropin-releasing hormone analogue and its diluents on the prevention of postsurgical adhesion formation in rat models. *Gynecol. Obstet. Invest.*, 46: 202-205.