

# ajava

Asian Journal of Animal and Veterinary Advances



Academic  
Journals Inc.

[www.academicjournals.com](http://www.academicjournals.com)

## The First Report of Spring Viraemia of Carp in Some Rainbow Trout Propagation and Breeding by Pathology and Molecular Techniques in Iran

<sup>1</sup>Adel Haghighi Khiabani Asl, <sup>2</sup>Mojgan Bandehpour,  
<sup>2</sup>Zarrin Sharifnia and <sup>2,3</sup>Bahram Kazemi

<sup>1</sup>Department of Pathology, Science and Research Campus, Veterinary Sciences School, Islamic Azad University of Iran, Tehran, Islamic Republic of Iran

<sup>2</sup>Cellular and Molecular Biology Research Center,

<sup>3</sup>Department of Parasitology,  
Shaheed Beheshti University of Medical Sciences, Tehran, Iran

**Abstract:** For consideration of the contamination of rainbow trout propagation and breeding centers in Iran to SVC (Spring Viremia of Carp), we prepared tissue samples from gills and parenchyma's organs. Samples of paranchymatous organs and gills were taken and prepared for Molecular and pathological testing by standard methods. Internal wall of air bladder, kidney, liver, intestinal curves and skeletal muscles of rainbow trout with the symptoms of disease in these centers and considered the prepared samples by both molecular and pathological techniques. Thirty six samples had the typical pathological clinical signs and 14 samples were diagnosed positively by PCR method and 1 sample had doubtful result. The results of this study revealed the frequency of SVC virus in some centers of rainbow trout propagation and breeding in Iran and therefore, the control and diagnosis of disease is necessary. This is the first study of the SVC infection in rainbow trout in propagation and breeding centers in Iran and can be useful for this virus isolation and consideration of the severity of its disorders.

**Key words:** Spring Viremia of Carp (SVC), rainbow trout, pathology, nested-PCR, Iran

### INTRODUCTION

Spring Viraemia of Carp is a contagious viral disease of all varieties of common carp and several other cyprinid species, with very high mortality among infected fishes. High mortality of old age rainbow trout occurred on fish farms in the spring and summer seasons, with clinical and typical symptoms (Wunner and Peters, 1991). The causative agent, Spring Viremia of Carp Virus (SVCV) or *Rhabdovirus carpio*, is a member of the family Rhabdoviridae, genus Vesiculovirus (Wolf, 1988; Wunner and Peters, 1991). The genome of SVCV has been shown to consist of single stranded RNA of approximately 11000 nucleotides with negative polarity (Hofmann *et al.*, 2002). SVC has been diagnosed in Great Britain (Bucke and Finlay, 1979) and Spain (Marcotegui *et al.*, 1972). SVC has been reported in North. Yugoslavia (Fijan, 1972), Czechoslovakia (Macura *et al.*, 1973; Tesar-ik *et al.*, 1977), Germany (Bachmann and Ahne, 1974), America (Goodwin, 2002), France (Baudouy, 1975), Hungary, (Bekesi and Szabo, 1977), Common carp (*cyprinus carpio*) is the main species of fish affected by SVC. Natural outbreaks have been recorded in pike-perch (*Stizosteidon lucioperca*), perch (*Perca fluviatilis*), pike (*Esox lucius*), bighead carp (*Aristichthys nobilis*) (Wunner and Peters, 1991).

**Corresponding Author:** Adel Haghighi Khiabani Asl, Department of Pathology, Science and Research Campus, Veterinary Sciences School, Islamic Azad University of Iran, Tehran, Islamic Republic of Iran

In this study, rate of mortality of old age rainbow trout was detected in the spring and summer seasons in Iran. Rainbow trout is not very sensitive to the SVCV, A variety of clinical signs and histopathological changes may be apparent in fishes infected with SVC virus with clinical symptoms typical for acute septicemia. The spleen was enlarged and marbled in appearance. A certain quantity of red fluid and fibrinous peritonitis were present in the abdominal cavity. The intestinal wall was oedematous, covered with petechial and diffuse bleedings, the lumen distended, filled with yellow mucous fluid. Accumulated fibrin caused adhesion of neighbouring organs or their parts. The viscera were oedematous and petechial haemorrhages occurred in the internal wall of air bladder, kidney, liver, intestines and skeletal muscles. Clinically manifested disease of rainbow trout fry caused by *Rhabdovirus carpio* was described, as well as pathological changes present in the internal organs in experimentally infected carp fry. Clinical and pathological signs of SVC have been catalogued oedema of all internal organs as well as of the wall of swim-bladder (Wunner and Peters, 1991).

## MATERIALS AND METHODS

The research samples were selected among rainbow trout with the symptoms of SVC (kidney swelling, exophthalmia, general petechiae, bronchi mottling, mouth inflammation, ascites, spotting bleeding on adipose tissues, preocular bleeding and coetaneous fissures) under perishing between May 2005 and September 2006, from 100 rainbow trout propagation and breeding in 11 provinces and tissue samples were prepared from gills (bronchi), anterior kidney, liver, spleen, heart, intestine, pancreas and skeletal muscle. Pathologic samples were stored in saline formalin 10% and suffered from tissue cutting stage according to histotechnique standard method. PCR samples were stored in ethanol 20% and transmitted to the Biotechnology (molecular) Laboratory.

### RNA Extraction

Viral RNA extraction was done by RNX<sup>plus</sup> buffer as described by manufacturer (CinnaGen, Iran). Briefly, about 1 cubic mm of fish tissue was transferred to 1.5 mL micro tube, then 200 µL RNX plus buffer was added. The mixture was incubated for 5 min at room temperature and then 50 µL of chloroform was added and centrifuged at 12000 rpm for 15 min at 4°C. Total tissue RNA (include viral RNA) was precipitated by ethanol and then dissolved in 10 µL of diethyl pyrocarbonate treated water (Kazemi *et al.*, 2004).

### Reverse Transcription Reaction

Reverse Transcription (RT) was performed as previously described (Pfeffer, 1998). Briefly, template RNA (1 µg) was incubated in a 20 µL reaction mixture containing: 40 pico mol of specific antisense external primer (SVC R 5'-CAC ACT CAT GCT GTA CAG TCT C-3'), 100 unit of Reverse Transcriptase enzyme (RT) (Fermentas, Lithuania), 20 unit RNasine (Fermentas, Lithuania), 1x RT buffer, 0.2 mM dNTP, for 1 h at 42°C.

### PCR Reaction

A nested-PCR was used to amplify a fragment of viral glycoprotein gene. First PCR reaction mixture was contained 10 µL of synthesized cDNA, 1.5 mM MgCl<sub>2</sub>, 0.1 mM dNTP, 1X PCR buffer, 40 pico mol each forward and reverse primers (Nest I primers: SVC F 5'-CCT ACC AAA CAC GAT GGG TTT G-3' and SVC R 5'-CAC ACT CAT GCT GTA CAG TCT C-3, were amplified 445 bp of viral glycoprotein gene) and 1.25 unit of Taq DNA polymerase (CinnaGen Iran) and was carried out within 30 cycles of: denaturation at 94°C for 30 sec, annealing at 58°C for 30 sec and extension at 72°C for 40 sec 1 µL of PCR product was used as template DNA for second PCR. Second PCR reaction also

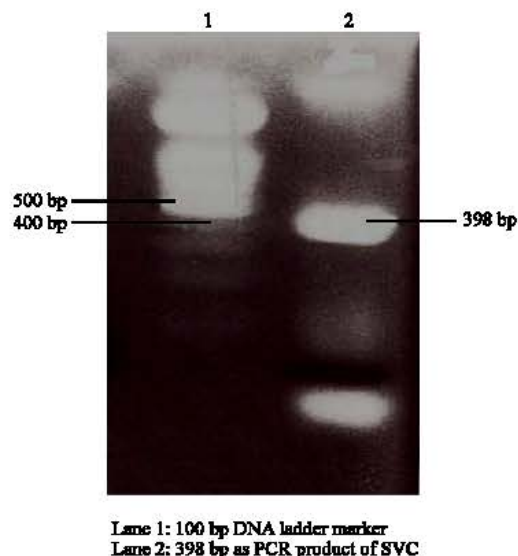


Fig. 1: Agarose gel electrophoresis of 100 bp ladder DNA size marker and 398 bp PCR product related to SVC virus glycoprotein gene

was done like first PCR within 30 cycles (Nest II primers: SVC2 F 5'-TGC CAC CAA ATT GAC AAT AAA-3' and SVC2 R 5'-GTG ATC CAA ATA GAG TGA TTC-3', were amplified 398 bp of viral glycoprotein gene) (Pherson and Moller, 2000).

#### Detection of PCR Product

PCR product was electrophoresed on 2% agarose gel (Fig. 1) stained by ethidium bromide and DNA band was observed by UV light under UV Tranilluminator (Boffey, 1984).

#### Tissue Preparation for Histological Methods (Tissue Processing)

Tissue from live or moribund (but not dead), fish or targeted tissue was fixed in 10% formalin and changed after 24 h Samples prepared in processing set in almost 20 h, then embedded and sectioned at 5-7 micrometer thickness. Slides were stained by haematoxylin and eosin (Roberts, 2001) or Immunohistochemical stained (Haghighi *et al.*, 2007).

## RESULTS AND DISCUSSION

Mortalities of rainbow trout began to first appear in late May, when water temperature rose to 12°C. Affected fish gathered at the pond's edges. Samples were pathologically and molecularly considered. Out of 100 tested samples, 36 samples were positive by pathology and 14 samples were positive by PCR method and 1 sample was doubtful result (Table 1).

Occasionally, positive samples were moribund fish from the water surface. Other external signs included dark coloration, exophthalmos, abdominal distension and haemorrhages in the anterior eye chamber. Internally, blood-tinged ascitic fluid was present in the abdominal cavity. The liver was slightly enlarged, anaemic with petechial haemorrhages (Fig. 3). Histopathological examination showed that the microarchitecture of the hepatic tissue was almost destroyed (Fig. 2). Small parts of healthy tissue were visible in certain places, while the remaining tissue was atrophied due to pressure of the cellular infiltrate. The kidney was congested, oedematous and grey in color. The spleen was enlarged with the loss of sharp edges. The intestine was filled with mucous yellowish fluid.

Table 1: Sampling of Iranian fisheries farmer and frequency of SVC virus positive by PCR or pathological methods

Province	Sample size	Positive			
		Pathology		PCR	
		Frequency	Percent	Frequency	Percent
Mazandaran	12	3	25.00	1	8.33
Ardebil	5	3	60.00	3	60.00
Fars	13	6	46.10	1	7.69
Markazi	6	2	33.30	2	33.30
Razavi Khorasan	7	5	71.40	1	14.28
Zanjan	11	6	54.50	1	9.09
Kohkiloeh va B.	13	3	23.07	1	7.69
Ghom	7	1	14.28	1	14.28
Esfahan (Flavarjan)	9	1	11.11	(- and +)	0.00
Ghazvin	7	4	57.10	1	14.28
Charmah va B.	10	2	20.00	1	10.00
Total	100	36	36.00	14	14.00

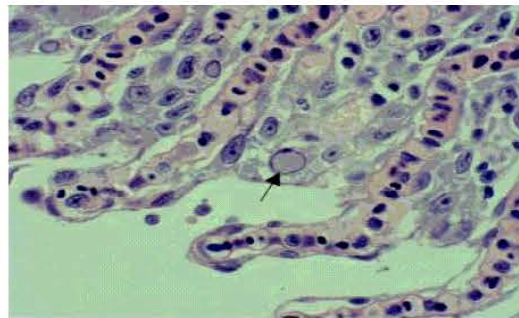


Fig. 2: The histopathological section of gill, staining with H and E technique fusion in secondary lamellar and necrotic fossa in rainbow trout with SVC

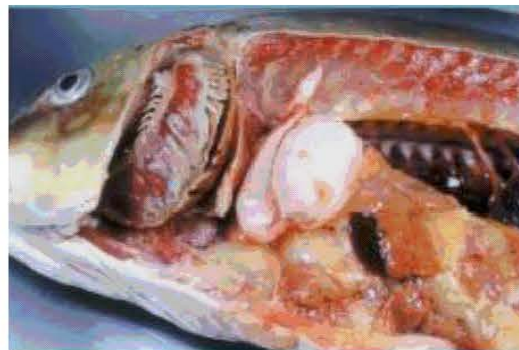

Fig. 3: Dissection of infected tissue with the typical signs as SVC with oedema of all internal organs as well as of the wall of swim-bladder and spleen has enlarged and marbled in appearance and general petechiae, mottling form on bronchi (gills)

The results of this study indicated that the SVC infection can be found in some farms of rainbow trout breeding in Iran. For the study of pathogenicity and isolation of SVC virus and the determination of the severity of disease, the establishment of laboratory with virus culture equipment is necessary. The severity of disease was dependant to the prodromal period of disease, body immunological

resistance of fish, stress and environmental factors related to season, temperature and pH changes (Ahne, 1975). The respect for hygiene rules, control of disease in fish propagation and breeding centers, isolation and quarantining of infected fishes or fishes with abnormal behavior has a major role for the prevention of disease. Of course, one of the most important causes of little incidence of disease and clinical signs is also the weakness of contaminator virus (Haghighi *et al.*, 2007). Therefore, the innovation of sensitive and specific techniques for the diagnosis of disease such as PCR is necessary (OIE, 2006; Naca, 1991). Other techniques such as ELISA and IFAT methods, cell culturing method on RTG-2, EPC and FHM lines and (VN) test (OIE, 2006). Immunohistochemistry (Haghighi *et al.*, 2007) and direct immunofluorescence (IF) (OIE, 2006) were also used. But, because of the cross reaction with other viruses, there is the probability of error.

With the use of PCR technique, the virus genome is recognized and even the virus is in the primary stages of colonization or cellular destruction is occurred caused by cellular damage, reorganization is possible (Haghighi *et al.*, 2007).

### CONCLUSION

This is the first report of SVC in the farms of rainbow trout breeding and propagation in Iran and both PCR and pathological techniques are useful for the diagnosis of disease and these methods have almost perfect agreement.

### ACKNOWLEDGMENTS

This research was supported by Iranian Veterinary Organization (IVO) and was done in Cellular and Molecular Biology Research Center, Authors will pass best regards and thanks to them.

### REFERENCES

- Ahne, W., 1975. A rhabdovirus isolated from grass carp (*Ctenopharyngodon idella* Vat.). *Arch. Virol.*, 48: 181-185.
- Bachmann, P.A. and W. Ahne, 1974. Biological properties and identification of the agent causing swimbladder inflammation in carp. *Arch. Ges Virusforsch.*, 44: 261-269.
- Baudouy, A.M., 1975. Vieremie printaniere de la carpe: Premiers isolement du virus en France. *Bull. Off. Int. Epiz.*, 83: 717-722.
- Bekesi, L. and E. Szabo, 1977. First isolation of *Rhabdovirus carpio* from carp in Hungary. *Magyar Allatovosk Lapja*, 6: 369-371.
- Boffey, S.A., 1984. Agrose Gel Electrophoresis of DNA. In: *Methods in Molecular Biology, Nucleic Acids*, John M. Walker (Ed.). Vol. 2, Homana Press, pp: 43-50.
- Bucke, D. and J. Finlay, 1979. Identification of Spring Viremia in Carp (*Cyprinus carpio* L.) in Great Britain. *Vet. Rec.*, 104 (4): 69-71.
- Fijan, N., 1972. Infectious Dropsy of Carp-a Diseases Complex. *Book of Proceedings. Symp. Zool. Soc.*, London, 30: 35-51.
- Goodwin, E.A., 2002. First report of Spring Viremia of Carp Virus (SVCV) in North America. *J. Aquat. Ann. Health*, 14: 161-164.
- Haghighi, A., M. Soltani, B. Kazemi, I. Sohrabi and I. Sharifpour, 2007. Use of immunohistochemical and PCR methods in diagnosis of infection haematopoietic necrosis disease in some rainbow trout hatcheries in Iran. *Pak. J. Biol. Sci.*, 10 (2): 230-234.
- Hofmann, B., H. Shutze, A. Mettenleiter and C. Thomas, 2002. Determination of the complete genomic sequence and analysis of the gene products of the virus of Spring Viremia of Carp, A fish rhabdovirus. *Vir. Res.*, 84 (1-2): 89-100.

- Kazemi, B., M. Bandehpour, H. Yahyazadeh, M. Roozbehi, N. Seyed, A. Ghotasloo and A. Taherpour, 2004. Comparative study on HCV detection in Iranian patients by RT-PCR and ELISA techniques during 2001-2003. *J. Med. Sci.*, 4 (2): 132-135.
- Macura, B., L. Dedek and J. Tesar-ik, 1973. The positive cytopathic effect from a case of spring viremia of carp. *Bull. VUHR Vodnany*, 9: 7-14.
- Marcotegui, M.A., A. Estepa, D. Frias and J.M. Cooi, 1972. First report of a Rhabdovirus affecting carp in Spain. *Bull. Eur. Ass. Fisch Pathol.*, 12 (2): 50.
- Naca, 1991. Fish health management in Asia-Pacific Report on a Regional study and workshop on fish disease and fish health management ADB Agriculture Department Report series No. 1 Bangkok, Thailand 627 pp. Viral Disease Chapter, pp: 340-355.
- OIE (Office International de Epizooties), 2006. OIE Manual of Diagnostic Tests for Aquatic Animals. Fish, Molluscs and Crustaceans. 5th Edn. Notifiable Disease Chapter 2.1.4-Spring Viraemia of Carp, pp: 469.
- Pfeffer, U., 1998. One-Tube RT-PCR with Sequence-Specific Primers. In: RNA Isolation and Characterization Protocols, Raplay, R. and L. David (Eds.). Manning. Published by Humana Press. Chapter 22, pp: 143-151.
- Pherson, Mc. and M.J. Moller, 2000. PCR. The Basics from Background to Bench. Bios Scientific Publishers. Chapter 2, pp: 9-21.
- Roberts, J.R., 2001. Fish Pathology. 3rd Edn. Harcourt Publishers Limited, WB Saunders, pp: 386-390.
- Tesar-ik, J., B. Macura, L. Dedek, L. Vali-ek and B. Mid, 1977. Isolation and electron microscopy of a Rhabdovirus from the acute form of infectious dropsy of carp (Spring Viraemia of Carp). *Zbl. Vet. Med. B*, 24: 340-343.
- Wolf, K., 1988. Fish Viruses and Fish Viral Diseases. Cornell University Press, Ithaca, N.Y.
- Wunner, W.H. and D. Peters, 1991. The Rhabdoviridae. *Arch. Virol.*, (Suppl 2): 250-262. In: Jeremi Svetlana *et al.*, 2006. *Rhabdovirus carp* as a causative agent of disease in rainbow trout (*Oncorhynchus mykiss-Walbaum*). *Acta Veterinaria (Beograd)*, 56 (5-6): 553-558.