

ajava

Asian Journal of Animal and Veterinary Advances



Academic
Journals Inc.

www.academicjournals.com

Some Histopathological Aspects of Chlorine Toxicity in Rainbow Trout (*Oncorhynchus mykiss*)

¹A.A. Mahjoor and ²R. Loh

¹Department of Pathology, Veterinary Medicine School, Islamic Azad University, Kazeroon Branch, Kazeroon, Iran

²Department of Primary Industries, Water and Environment, Launceston, Tasmania, Australia

Abstract: Eight month old Rainbow trout were found dead ten days after shot down of a fresh water recirculation system. The cause of death was diagnosed as chlorine toxicity. The fish carcasses appeared pale and anemic and had enlarged gall bladders and mild multifocal dermatitis. Histopathological inspection revealed edema and foamy vaculation in the gill epithelium, tubular degeneration and presence of golden pigments and azurophilic bodies within phagocytic cells in the kidney, cytoplasmic vacuolation and hyaline droplets in the hepatocytes, mild epithelial erosion and leucocyte infiltration in the skin and marked erythrophagocytosis in the spleen.

Key words: Chlorine, toxicity, fish

INTRODUCTION

Chloride is added to municipal (tap) water supplies to kill microorganisms (Noga, 1996). Chlorine reacts with the natural organic matter or contaminants in surface waters and produces a complex mixture of Disinfection By-Products (DBPs), some of which have been shown to be carcinogenic, mutagenic and/or teratogenic in animal studies (Ferraris *et al.*, 2005). Like many other toxins in water chlorine is much more toxic to fish than humans (Noga, 1996). Toxicity with discharges of chlorine is common because it is used to disinfect effluents, to control fouling organisms in cooling water system and in industrial process particularly in the food and paper industries (Fisher *et al.*, 2003). Although chlorine toxicity has been frequently reported as a cause of mortality in fish, the pathology changes related to this toxicity is treated rather briefly in literature. Thus, the purpose of this study was to ascertain some of these pathological changes in a naturally occurring toxicity. This case study also illustrates the importance of good history taking and how interrelated fish are with their watery environment.

CASE HISTORY

Eight-month old rainbow trout (*Oncorhynchus mykiss*) were found dead in a freshwater recirculation system in the key center of fish health research center of University of Tasmania, Launceston, Australia. Ten days prior to this incident, the system was shut down during a blackout. Fish were found swimming in a swirling motion or died suddenly. Ten days later mortality rates reached 60%. The fish were immediately fixed in 10% formalin buffer and were sent to DPIWE diagnostic laboratories in Launceston. Investigations revealed that the tanks had been refilled with town water that had variable levels of chlorine and even after sodium thiosulfate was added, chlorine levels were still as high as 0.2 ppm. The type of Chlorine used by the water department was Chloride dioxide and CL 2 (Liquid).

Corresponding Author: Amir Ashkan Mahjoor, 51, Shaghyegh 3, Shaghayegh 20, Rajayeri 29, Farhangshar, Shiraz, Iran Tel: 09173150962

RESULTS

Dead fish had enlarged gall bladders. Mild multifocal dermatitis was observed in the skin. Their carcasses appeared pale and anemic. Wet preparations of skin scrapes and gill biopsies were negative for parasites.

Histopathological examination revealed gill edematosis and foamy vacuolation especially in the proximal part of the secondary lamellae. Gill epithelial cells were swollen. This feature was more prominent in chloride cells. Epithelial lifting and telangiectasis in the secondary lamellae were also found (Fig. 1).

The histopathological features of the kidney consisted of increase in golden pigments and azurophilic bodies within phagocytes and variable, but sometimes extensive erythrophagia. Occasionally renal tubular degeneration was noted. The lumen of degenerated tubules contained copious amounts of sloughed cells.

The histopathological findings in the spleen were similar but with more prominent erythrophagocytosis. The spleen featured depletion of haematopoietic tissue (Fig. 2).

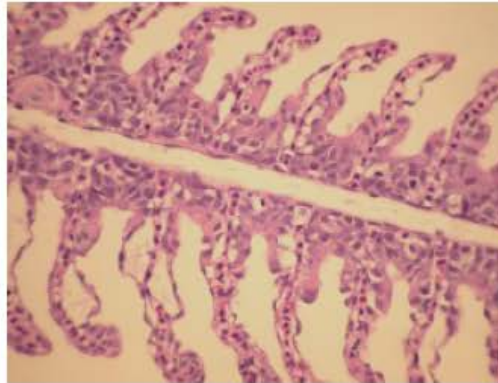


Fig. 1: Rainbow trout. Gill: Chlorine exposed gills featured inter-lamellar epithelial hyperplasia, vacuolation and hypertrophy of chloride cells. Note the epithelial lifting and mild telangiectasis in the secondary lamellae

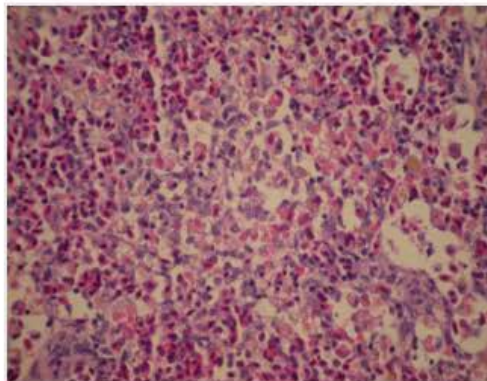


Fig. 2: Rainbow trout. Spleen: Increase in golden pigments, azurophilic bodies and erythrophagocytosis. Note haematopoietic tissue depletion

Variable amounts of colorless cytoplasmic vacuolation and small hyaline droplets were seen in the hepatocytes. Foci of phaged golden pigment were scattered throughout the liver. In the skin mild epithelial erosion accompanied with mild leukocytic transmigration and elevated numbers of melanocytes were recorded. Mild mural reactions in the myocardium were the other histopathological findings in these cases. There were no significant findings in the brain, pyloric caecae and pancreas. The condition appeared to be primarily due to red blood cells destruction and is consistent with the marked anemia that was confirmed by paraclinical examination. History and findings were consistent with met-haemoglobinaemia, which seemed to be related to excess chlorine toxicity.

DISCUSSION

Chlorine toxicity can present as acute to subacute mortality associated to a newly set-up tank or when fresh tap water is used for a water change (Noga, 1996). Sensitivity of trout and other fish to chlorine has been reported and the toxicity of chlorine to freshwater fish has been reviewed by several workers (Youkos *et al.*, 2000; Heath, 1997). Mitz and Giesy (1985) have reported a 100% mortality in channel catfish kept in cage in a sewage effluent biomonitoring study and noted that the mortality was probably due to excessive mean total residual chlorine concentration (0.24 and 0.30 mg L⁻¹). Histopathological study on this fish revealed two or more moderate to severe histopathological damages to the gills, including severe hyperplasia of the epithelial cells, clubbing and fusion of the secondary lamellae, moderate to severe edema in the secondary lamellae and multiple, blood-filled aneurysms and extremely vacuolated livers in 60% of the fish.

Rainbow trout is very sensitive to chemical environmental changes and even have been considered as a good experimental model as an indicator for toxicity in aquatic animals (Ferraris *et al.*, 2005; Kilemade *et al.*, 2002). According to substance toxicity classification accepted for Lithuanian inland waters, chlorine dioxide and chlorite can be referred to substances of 'moderate' toxicity to fish. The acute and chronic toxicity of chlorine dioxide and chlorite to larval and adult rainbow trout was investigated in 96 h to 20 day laboratory exposures. Both chemical compounds induced similar toxic effects in rainbow trout larvae during chronic tests, but chlorine dioxide had a higher toxic potency than chlorite (Svecevicus *et al.*, 2005).

Youkos *et al.* (2000) in an experimental study found that gill epithelium was the primary target tissue affected by chlorine dioxide exposure. Chlorine dioxide exposure produced dose-dependent gill pathology including epithelial lifting, hypertrophy, hyperplasia, lamellar fusion and necrosis in Fat head minnow (*Pimephales promelas*). Chlorite did not produce gill pathology even at a lethal exposure level (304 mg L⁻¹ for 96 h) but did elicit a chronic inflammatory response with a marked increase in circulating and fixed phagocytes within hematopoietic and vascular tissues (Youkos *et al.*, 2000).

The gill histopathology features in our study is same as those reported by other workers and resembles a typical irritant response beginning with epithelial lifting, hypertrophy and hyperplasia. Telangiectasis of secondary lamella is associated with chemical pollution (Roberts, 2001). This can result to lamellar fusion and necrosis that was not seen in our study that can be due to the acute nature of the toxicity in this study.

Lamellar edema of the gills is most frequent following exposure to chemical pollutants such as heavy metals, red tides, certain pesticides and therapeutic formalin or hydrogen peroxide. In gills damaged by the effects of acidification of the water supply due to acid rain and subsequent increase in solubility of soil aluminum, secondary lamellar swelling occurs. This is associated to a degree with lamellar edema and hypertrophy of individual epithelial cells. There is alteration in underlying pillar cell architecture, but the principal factor is significant increase in the numbers of chloride cells. These extend on to the surface of the secondary lamellae and instead of being located in sunken pits, bulge out in the surface (Roberts, 2001).

Toxic organic compounds like chlorinated hydrocarbons herbicides and organophosphate insecticides can cause nephrotoxic lesions like desquamation of tubular epithelium, dilation of lumina and tubular necrosis (Roberts, 2001). Toxic causes of haemolytic anaemia are highly variable, but commonly include chlorine exposure. Not only is there destruction of erythrocytes, but in the presence of nitrogenous wastes chloramines is also formed. These lead to methaemoglobin formation, thereby reducing the oxygen-carrying capacity of the blood (Noga, 1996).

Fish liver is particularly susceptible to chemical damage. Free-radical damage to hepatocytes cell membrane following toxic conditions can cause widespread necrosis and ceroid build up in remaining hepatocytes. Lipid infiltration often is disseminated throughout the liver. In haemolytic anaemias, ferrous iron is stored in the melanomacrophages of the liver (Noga, 1996). The vacuolation observed in our cases can be related to the haemolytic anaemia caused by hypoxia but the other microscopic features noted by other workers were not observed in this study.

Glomerular disease can result in protein leakage into the filtrate, recognized histologically as homogenous eosinophilic deposits within tubular lumens and presumably leading to proteinuria (Ferguson, 1989; Svecevicius *et al.*, 2005). Their significance is unknown, although several authors have noted an association with toxicants and high ammonia levels.

Present findings in the spleen supports other workers finding who suggest that, in acute hemolytic crises, most of the blood pigments accumulate in the spleen rather than the kidney.

REFERENCES

- Ferguson, W.H., 1989. Systemic Pathology of Fish. Iowa State University Press. Ames Iowa.
- Ferraris, M., E. Chiesara, S. Radice, A. Giovana, S. Fregeiro and L. Marabini, 2005. Study of potential toxic effects on rainbow trout hepatocytes of surface water treated with chlorine or alternative disinfectants. *Chemosphere*, 60 (1): 65-73.
- Fisher, D.J., D.T. Burton, L.T. Yonkos, S.D. Turley, G.P. Ziegler and B.S. Turley, 2003. Derivation of acute ecological risk criteria for chlorite in freshwater ecosystems. *Water Res.*, 37 (18): 4359-4368.
- Heath, A.G., 1997. Toxicity of intermittent chlorination to fresh water fish: Influence of temperature and chlorine form. *Hydrobiologia*, 56 (1): 39-47.
- Kilemade, M., M. Lyons-Alcantara, T. Rose, R. Fitzgerald and C. Mothersill, 2002. Rainbow trout primary epidermal cell proliferation as an indicator of aquatic toxicity: An *in vitro/in vivo* exposure comparison. *Aquat. Toxicol.*, 2 (1-2): 43-59.
- Mitz, S.V. and J.P. Giesy, 1985. Sewage effluent biomonitoring. I. Survival, growth and histopathological effects in channel catfish. *Ecotoxicol. Environ. Safety*, 10 (1): 22-39.
- Noga, E.J., 1996. Fish Disease: Diagnosis and Treatment: Mosby-Year Book. St Louis, pp: 226-227.
- Roberts, J.R., 2001. Fish Pathology. Roberts, J.R. (Ed.). 3rd Edn. W.B. Saunders, London, pp: 55-113.
- Svecevicius, G., J. Syvokiene, P. Stasiunaite and L. Mickeniene, 2005. Acute and chronic toxicity of chlorine dioxide (ClO₂) and chlorite (ClO₂⁻) to rainbow trout (*Oncorhynchus mykiss*). *Bull. Environ. Contam. Toxicol.*, 12 (5): 302-305.
- Yonkos, L.T., D.J. Fisher, D.A. Wright and A.S. Kane, 2000. Pathology of fathead minnows (*Pimephales promelas*) exposed to chlorine dioxide and chlorite. *Mar. Environ. Res.*, 50 (1-5): 267-271.