

ajava

Asian Journal of Animal and Veterinary Advances



Academic
Journals Inc.

www.academicjournals.com

Lacrimal Apparatus System in Goat (*Capra aegagrus hircus*): Anatomical and Radiological Study

¹M. Shadkhast, ²A.S. Bigham, ³N. Vajdi and ⁴Z. Shafiei

¹Department of Basic Science, Faculty of Veterinary Medicine, Shahre-Kord University,
Shahre-Kord, P.O. Box 88186-341 41, Iran

²Department of Veterinary Surgery and Radiology, Faculty of Veterinary Medicine,
Shahre-Kord University, P.O. Box 88186-341 41, Shahre-Kord, Iran

³Faculty of Veterinary Medicine, Shahre-Kord University, Shahre-Kord, Iran

⁴School of Veterinary Medicine, Shiraz University, Shiraz, Iran

Abstract: This study was performed to introduce the anatomical location (gross appearance) and radiographic views (dacryocystorhinography) of lacrimal duct in goats. The anatomy of the nasolacrimal duct of twenty goats (*Capra hircus*) studied grossly and radiographically. Dacryocystorhinography was performed on cadaver heads, using a radiographic contrast media. Anatomic casts of the nasolacrimal apparatus were obtained by cannulation of the duct and use of corrosion cast (Rodopas cast) material. Dacryocystorhinography accurately revealed the nasolacrimal apparatus and compared favorably with gross dissection and Rodopas casts. The present study on the lacrimal apparatus of the goat might be useful for differentiation of congenital or clinical cases affecting the lacrimal system area.

Key words: Dacryocystorhinography, nasolacrimal duct, casting, goat

INTRODUCTION

The lacrimal apparatus system provides a passage for tear drainage from the eye to the nasal cavity. The system for each eye in most species consists of dorsal and ventral lacrimal puncta, paired canaliculi, lacrimal sac and the nasolacrimal duct (Prince *et al.*, 1960). The nasolacrimal system of sheep has been studied previously by Gilanpour (1979). There are no reports on the lacrimal apparatus system in the goat. Dacryocystorhinography, the radiographic visualization of the lacrimal apparatus using radiographic contrast media, has been used to study normal anatomy (Gelatt *et al.*, 1972; Shokry *et al.*, 1987) as well as pathologic conditions of the nasolacrimal duct in human beings (Hurwitz and Welham, 1975), dogs (Fowler, 1989), horses (Latimer *et al.*, 1984), sheep (Gilanpour, 1979), cattle (Heider *et al.*, 1975; Wilkie and Rings, 1990), camels (Shokry *et al.*, 1987), cats (Gelatt *et al.*, 1972) and llamas (Sapienza *et al.*, 1992; Mangan *et al.*, 2008). The present study on the lacrimal apparatus of the goat might be useful for differentiation of congenital or clinical cases affecting the lacrimal system area.

MATERIALS AND METHODS

This study was performed in February 2008. Twenty heads (cut above the third cervical vertebra) of adult Lori breed goat were collected from a local slaughterhouse of Shahreh-Kord area of Chahar-Mahale Bakhtiari Province of Iran. In gross observation the dorsal and ventral puncta were found in

Corresponding Author: A.S. Bigham, Department of Veterinary Surgery and Radiology,
Faculty of Veterinary Medicine, Shahre-Kord University, P.O. Box 88186-34141,
Shahre-Kord, Iran Fax: 0098 (381) 4424427

the medial canthus of eyelids that were remarkably small and could not be probed, therefore the distal opening of nasolacrimal duct was found in nasal cavity and was caunulated with a 4-French cut down tube. One milliliters of a sodium and meglumine diatrizoate mixture (Urographin 76%, Schering Company, Germany) were injected into the lacrimal duct in retrograde fashion. Lateral and dorsoventral oblique radiographic views were taken (80 KV and 10 mAs) (Fig. 1). For gross anatomic studies, casting materials was also introduced in retrograde fashion from distal opening of lacrimal duct. Approximately 1-2 milliliter of casting material (Rodopas, Merck Company, Germany) was needed to fill the entire length of the nasolacrimal duct. When the casting materials had solidified, the lacrimal apparatus was examined grossly via exposure of the lateral aspect of the nasal cavity by removing a strip of bone from the lacrimal, zygomatic, maxillary and incisive bones. Medial dissection was facilitated by removal of the ethmoturbinates, ventral conchae and lacrimal bone. Descriptive statistics were done by computer program SPSS, Analytical soft ware, version 15.00.

RESULTS

Anatomic Studies

In gross anatomical studies, the lacrimal puncta were slit-like opening, 0.72 ± 0.19 mm (mean \pm SD) in diameter, located approximately 1 mm from the margin and 2.36 ± 0.41 mm (mean \pm SD) from the medial canthus just within the mucocutaneous junction of the palpebral margin. The paired ventral and dorsal canaliculi were 8 ± 0.79 mm (mean \pm SD) long and converged into a small dilatation, the lacrimal sac, which was located in the orbit on the fossa of the lacrimal bone outside the periorbita. The nasolacrimal duct extended from the lacrimal sac to the nostril in the wall of the nasal cavity (Fig. 2). The proximal portion of the lacrimal duct was in the osseous lacrimal canal and was 77.6 ± 2.3 mm (mean \pm SD) long. The osseous lacrimal canal ran rostrally, with a slight curve at its origin. It passed the lacrimal, zygomatic and maxillary bones-first, lateral to the lacrimal sinus and then, dorsal to the maxillary sinus. The middle portion of the nasolacrimal duct was appeared through the osseous lacrimal canal after crossing the ventral conchal crest. The duct then traversed the nasal cavity in a straight fashion, covered only by nasal mucosa and a thin connective tissue membrane (Fig. 2). The opening of the nasolacrimal duct was 1.7 ± 0.21 mm (mean \pm SD) in diameter and was on the lateral wall of the nostril about 28.8 ± 2.5 mm (mean \pm SD) from the dorsal angle of the nostril. Casting material provided finely tailed casts of the nasolacrimal duct (Fig. 2). Since the Rodopas was fragile, we cannot draw any finding with this technique.

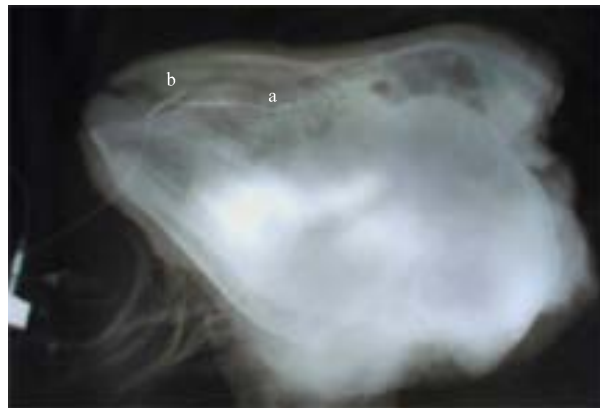

Fig. 1: Lateral contrast media radiographic views. (a) Middle portion of lacrimal duct (b) Distal opening of lacrimal duct

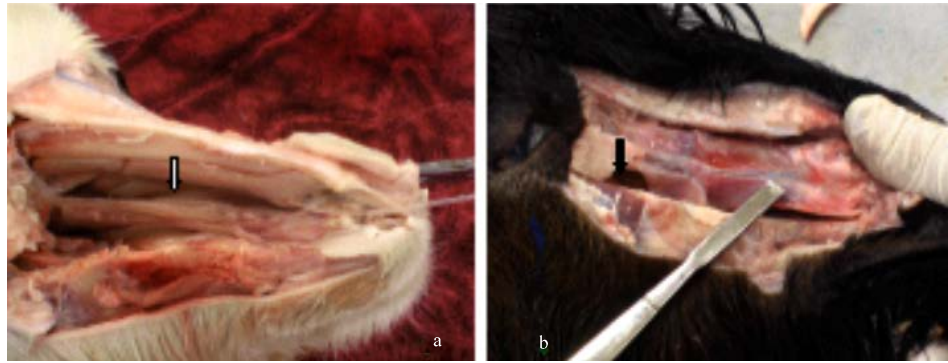


Fig. 2: Lacrimal drainage system of goat exposed in the medial surfaces, white arrow shows the distal of lacrimal duct (a) and on the lateral surface of the nasal cavity, black arrow shows the middle portion of lacrimal duct (b)

Radiographic Study

Positive contrast Dacryocystorhinography provided detailed visualization of the lacrimal apparatus. The nasolacrimal duct continues rostrally in a straight fashion parallel to nasal bone from the orbit to the nasal cavity (Fig. 1). The terminal portion of the nasolacrimal duct tapered to a fine exit, rostral to the nasal processes of the incisive bone. The lateral dacryocystorhinographic view was better than ventrodorsal oblique view for detailed viewing of the course of the nasolacrimal duct (Fig. 1).

DISCUSSION

The nasolacrimal system of various domestic species has been previously described (Abdalla *et al.*, 1970; Gelatt *et al.*, 1972; Gilanpour, 1979; Shokry *et al.*, 1987; Sapienza *et al.*, 1992; Aldana Marcos and Affanni, 2005; Rehorek *et al.*, 2005). Radiographic and gross anatomic description of the lacrimal apparatus in sheep has been published (Gilanpour, 1979) but there is no report about the lacrimal apparatus in goat. Anatomic and radiographic findings in goat of our study were similar to those reported by Gilanpour (1979). The lacrimal apparatus consisted of an orbital part and a nasal cavity part. The orbital lacrimal apparatus consisted of a simple lacrimal sac, paired canaliculi with the dorsal and ventral puncta. The first part generally consists of two lacrimal puncta, two ducts and a lacrimal sac. In some animal such as the pig, a single punctum and a single duct are present (Prince *et al.*, 1960). In the dog, the punctum of the ventral eyelid is occasionally absent; sometimes the duct is also (Gelatt *et al.*, 1972). The nasolacrimal duct coursed rostrally in a straight fashion, quite similar to that observed in sheep (Gilanpour, 1979), however in llamas the nasolacrimal duct coursed rostrally in a sigmoid fashion (Sapienza *et al.*, 1992). The nasolacrimal duct was regular in diameter throughout its entirety, unlike that in horses (Latimer *et al.*, 1984). Dacryocystorhinography accurately revealed the lacrimal apparatus and compared favorably with gross dissections and Rodopas casts. The casts provided fine detail of the nasolacrimal duct, but were fragile and tended to break easily *in situ* (Sapienza *et al.*, 1992). The lateral dacryocystorhinographic view was better than the dorsoventral view for visualization of duct over its entirety (Latimer *et al.*, 1984; Shokry *et al.*, 1987). A dorsoventral oblique view has provided more detailed view than dorsoventral view (Sapienza *et al.*, 1992).

CONCLUSION

Radiography and cannulation via the puncta are techniques that may be useful for detection of obstructions and anomalies of the lacrimal apparatus in goat.

REFERENCES

- Abdalla, O., M.F. Fahmy and I. Arnautovic, 1970. Anatomical study of the lacrimal apparatus of the one-humped camel. *Acta Anat. (Basel)*, 75: 638-650.
- Aldana Marcos, H.J. and J.M. Affanni, 2005. Anatomy, histology, histochemistry and fine structure of the Harderian gland in the South American armadillo *ChaetophRACTUS villosus* (Xenarthra, Mammalia). *Anat Embryol. (Berl)*, 209: 409-424.
- Fowler, M.E., 1989. *Medicine and Surgery of South American Camelids: Llama, Alpaca, Vicuna, Guanaco*. 1st Edn. Iowa State Press. ISBN:0813803977, pp: 317-321.
- Gelatt, K.N., T.H. Cure, M.M. Guffy and C. Jessen, 1972. Dacryocystorhinography in the dog and cat. *J. Small Anim. Pract.*, 13: 381-397.
- Gilanpour, H., 1979. Anatomic and radiographic studies of the lacrimal drainage system in sheep (*Ovis aries*). *Am. J. Vet. Res.*, 40: 1177-1179.
- Heider, L., M. Wyman, J. Burt, C. Root and H. Gardner, 1975. Nasolacrimal duct anatomy in calves. *J. Am. Vet. Med. Assoc.*, 167: 145-147.
- Hurwitz, J.J. and R.A.N. Welham, 1975. The role of dacryocystorhinography in the management of congenital nasolacrimal duct obstruction. *Can. J. Ophthalmol.*, 10: 346-350, ISSN: 0008-4182.
- Latimer, C.A., M. Wyman, C.D. Diesem and J.K. Burt, 1984. Radiographic and gross anatomy of the nasolacrimal duct of the horse. *Am. J. Vet. Res.*, 45: 451-458.
- Mangan, B.G., J.R. Gionfriddo and C.C. Powell, 2008. Bilateral nasolacrimal duct atresia in a cria. *Vet. Ophthalmol.*, 11: 49-54.
- Rehorek, S.J., E.J. Legenzoff, K. Carmody, T.D. Smith and J.C. Sedlmayr, 2005. Alligator tears: A reevaluation of the lacrimal apparatus of the crocodilians. *J. Morphol.*, 266: 298.
- Sapienza, J.S., R. Isaza, R.D. Johnson and T.R. Miller, 1992. Anatomic and radiographic study of the lacrimal apparatus of llamas. *Am. J. Vet. Res.*, 53: 1007-1009.
- Wilkie, D.A. and D.M. Rings, 1990. Repair of anomalous nasolacrimal duct in a bull by use of conjunctivorhinostomy. *J. Am. Vet. Med. Assoc.*, 196: 1647-1650.