

ajava

Asian Journal of Animal and Veterinary Advances



Academic
Journals Inc.

www.academicjournals.com

The Efficacy of *Tarantula cubensis* Extract (Theranekron) in Treatment of Canine Oral Papillomatosis

¹H. Icen, ¹S. Sekin, ¹A. Simsek, ¹A. Kochan and ²S. Tunik

¹Department of Internal Medicine, Faculty of Veterinary Medicine, University of Dicle, 21180-Diyarbakir, Turkey

²Department of Histology and Embryology, Faculty of Medicine, University of Dicle, Diyarbakir, Turkey

Corresponding Author: Dr. Hasan Icen, Department of Internal Medicine, Faculty of Veterinary Medicine, University of Dicle, 21180-Diyarbakir, Turkey Fax: +0412-248 80 21

ABSTRACT

The aim of this study was to investigate the effects of *Tarantula cubensis* extract (Theranekron, Richter Pharma, Austria) applied on canine oral papillomatosis. A total of 10 dogs brought from dogs shelter to the Faculty of Veterinary Medicine, University of Dicle Turkey and aged between 7 and 36 months were used in this study. Diagnosis of the papillomatosis was based on clinical signs and histopathological examinations. Each dog received 2 mL per 10 kg of *Tarantula cubensis* extract subcutaneously two times per week. Regression of papillomas was observed after the beginning of treatment in second week. At the end of the third week 7 dogs recovered. The treatment continued on 3 dogs for two more weeks after which there was complete resolution of the lesion. *Tarantula cubensis* extract applications therefore seemed to be effective in the treatment of canine oral papillomatosis.

Key words: Oral papillomatosis, theranekron, canine, homeopathy

INTRODUCTION

Canine papillomatosis, or warts, is a contagious disease of dogs, which is characterized by the formation of benign tumours involving the skin membrane and caused by Papillomavirus. Transmission is by direct and indirect contact. The infection begins as small papules, which enlarge to form small, cauliflower-like warts which may appear on the lips, tongue, gums, buccal mucosa palate, pharynx, gingiva, inguinal and perineal regions and occasionally the conjunctivae. These lesions slowly progress and regress over eight months period. Infrequently, viral papillomas in dogs may progress to squamous cell carcinomas. Dogs under 4 years of age are most commonly affected. Furthermore, with increasing number of papillomas, food consumption may become a problem (Booney *et al.*, 1980; Lucroy *et al.*, 1998; Teifke *et al.*, 1998; Megid *et al.*, 2001; Nicholls *et al.*, 2001; Campo, 2002; Biricik *et al.*, 2008).

Several protocols are used, but mainly treatment of papillomatosis can be achieved through surgical excision, cryosurgery or crushing of several tumors to stimulate immune response. Also, systemic chemotherapy using vincristine, vinblastine, cyclophosphamide, methotrexate, clorambucil, azithromycin, taurolidine, doxorubicin, or bleomycin, *Propionibacterium acnes* and cimetidine have been attempted with varying degree of success (Nicholls *et al.*, 1999;

Megid *et al.*, 2001; Carmona *et al.*, 2002; Biricik *et al.*, 2008; Yagci *et al.*, 2008). Chemotherapy usually is reserved for persistent papillomas that have failed to regress after more than five months (Arikan *et al.*, 1993; Lucroy *et al.*, 1998; Yagci *et al.*, 2008).

Perhaps due to the limited success of antibiotics, substantial cost associated with adverse effects and antibiotic resistance as a result of overuse and misuse, more attention is now focused on alternative treatments for various diseases. The use of alternative treatments is expanding in human medicine, but information about the extension of such practices to veterinary medicine is limited, as good records of the use of these treatments do not exist (Bademkiran *et al.*, 2009). Homeopathy is a system of medicine that was developed in Germany by Dr. Samuel Hahnemann in the late eighteenth century. The increasing and effective use of homeopathy in veterinary medicine without side-effects demonstrates that many Veterinary surgeon apply this treatment as a natural stimulator of self healing mechanisms in animals. Homeopathy is the selection of a substance to cure a disease by knowing that some substances could cause the symptoms seen in a patient (Gultekin *et al.*, 2007; Beceriklisoy *et al.*, 2008). It was determined that a homeopathic medicine *Tarantula cubensis* extract, a homeopathic medicine known to have antiphlogistic, demercative, necrotizing action, stopping tumor growth in canine mammary tumours by forming demarcation (Koch and Stein, 1980; Gultekin *et al.*, 2007; Sardari *et al.*, 2007). There were no reports of *Tarantula cubensis* extract effects on canine oral papillomatosis thus this study examined the therapeutic effectiveness of the agent on the lesion.

In the present study we aimed to examine the therapeutic effectiveness of *Tarantula cubensis* extract against canine oral papillomatosis.

MATERIALS AND METHODS

A total of 10 crossbred of Akbash and Kangal dogs were used in this study between the ages of 7-36 months. The dogs were brought to the Faculty of Veterinary Medicine of the University of Dicle from dogs shelter between May and September 2008. Three of the dogs were 7-11 month age and 7 were adults, aged between 1-3 years. Diagnosis of the papillomatosis was based on clinical signs and histopathological examinations. Clinical examination revealed wart-like growth were seen as cauliflower in or around the mouth, buccal mucosa, tongue, gingiva, skin near eyes, perineal regions. The warts were measured by compass. The sizes of warts were 0.3 to 20 mm. The dogs were feeding with soft food during study. All dogs were anaesthetized and biopsies of the oral and cutaneous lesions were taken for histopathological examination. Warts specimens were fixed in 10% neutral buffered formalin solution and then embedded in paraffin blocks stained with haemotoxylineosine. The dogs received 2 mL per 10 kg of *Tarantula cubensis* extract (Theranechron, 1:100/D2, 1.0 mg mL⁻¹, Richter Pharma, Austria) subcutaneously two times per week during 3 weeks.

RESULTS

In clinical examination, there were numerous papillomas on the surface of lips, cheeks, buccal mucosa and palate and a few on the mucosa of pharynx on dogs (Fig. 1). Histopathologic examination of the epithelial tissue structure was composed of a very thick squamous epithelium, with hyperkeratosis. Cells of the surface layers had clear cytoplasm with numerous coarse keratohyaline granules of various size; their cytoplasm is of vacuolated or filled with albuminous material. Some of these cells also contained eosinophilic intracytoplasmic protein aggregates (Fig. 2). A quasi-normal appearance of histological section were seen of dorsal aspect of tongue after recovery period is shown in Fig. 3.

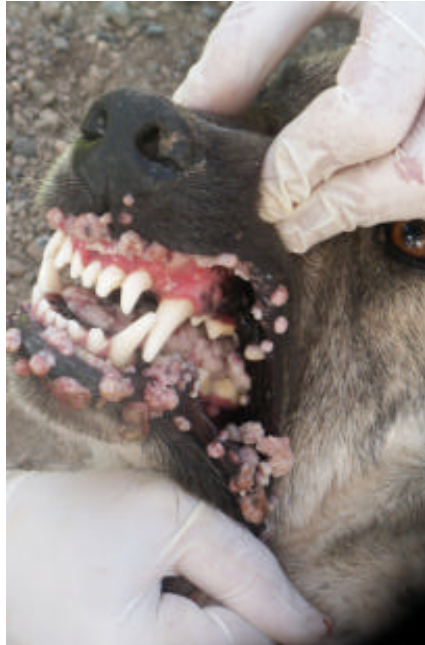

Fig. 1: Multiple crops of papillomas affect the buccal mucosa, tongue and palatine mucosa

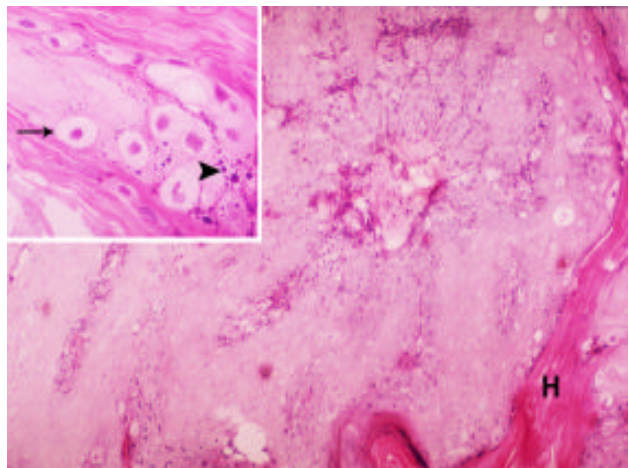


Fig. 2: Epithelium papillomatosis hyperplasia with orthokeratotic hyperkeratosis (H). HE×80 small picture koilocytosis (arrow) and increasing of keratohyalin granules were seen HE×80

After the application of *Tarantula cubensis* extract no changes were observed with palpation or visual inspection in the first week. Papilloma regression was verified in all animals, after the second week of enjection. At the end of third week four adults and three young dogs recovered. In older animals, regression was slower because of more intensive lesion, so the therapeutic protocol was adjusted upward for 2 weeks or more as the case may be. Papillomas regression beginning after the fourth *Tarantula cubensis* extract application; total regression was observed after the tenth application (Fig. 4).

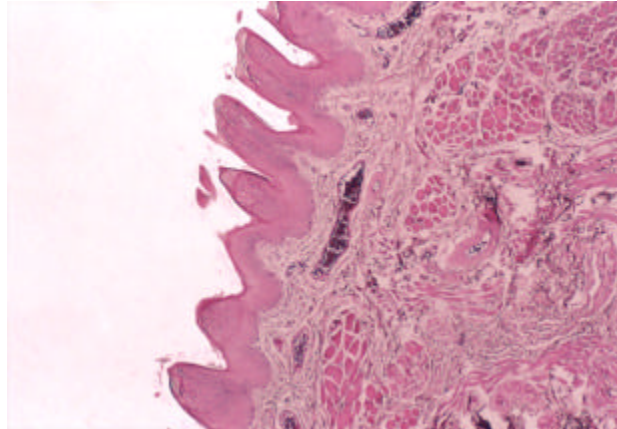


Fig. 3: A quasi-normal appearance of histological section of dorsal aspect of tongue after recovery period. In the section, hemorrhage was observed in some area. (Original magnification, (H-E, X4)

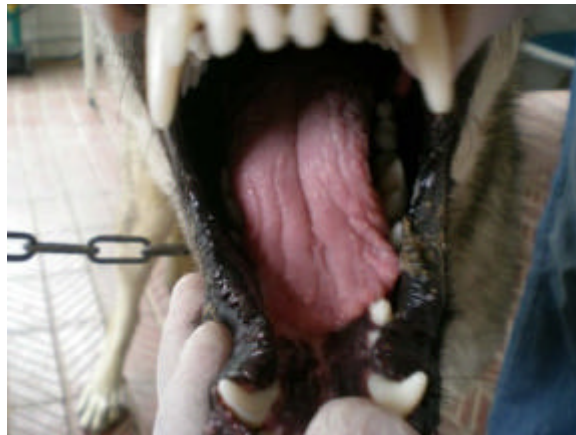


Fig. 4: Post treatment with *Tarantula cubensis* extract (at the end of five weeks)

DISCUSSION

Papillomas are benign tumors of skin origin commonly found in or around the mouth and eyelids. These warty growths may cause discomfort when eating, bleeding in the mouth, or halitosis (Bredal *et al.*, 1996). In papillomas, histopathological examination of hyperkeratotic plaques revealed orthokeratotic hyperkeratosis overlying hyperplastic epithelium on fibrovascular stalks (Greig *et al.*, 1973; Bredal *et al.*, 1996; Lucroy *et al.*, 1998; Nicholls *et al.*, 1999; Biricik *et al.*, 2008; Yagci *et al.*, 2008). Our clinical and histopathological findings are consistent with previous reports using histopathological means to screen for papillomatosis (Sundberg *et al.*, 2000; Schulman *et al.*, 2001; Biricik *et al.*, 2008; Yagci *et al.*, 2008).

Papillomatosis in dogs may be a self-limiting disease, requiring no treatment. However, persistent lesions may be associated with defective cell-mediated immunization (Yagci *et al.*, 2008). Many therapeutic trials for the treatment of oral papillomatosis have been reported, including live papilloma virus vaccine. Other reported treatment options include specific vaccinations,

Propionibacterium acnes and cimetidine; autogenous wart vaccines have been recommended by some, but their efficacy is unknown. If oral tumors interfere with eating, they can be removed surgically. However, no single treatment has been shown to be superior (Raue *et al.*, 2007).

Tarantula cubensis extract ceased tumour growth, improved welfare, made tumour center harder and capsule thicker and created a demarcation area on the surrounding tissue of tumour (Koch and Stein, 1980; Gultekin *et al.*, 2007). In this study, *Tarantula cubensis* extract was found to be effective in decreasing clinical lesion in dogs with oral papillomatosis and the post treatment observations for three months were presented. There were no recurrence in any dogs. The beneficial effect of *Tarantula cubensis* extract is stopped tumour growth by forming demarcation area when used two times per week for three weeks with the dosage of 2 mL per 10 kg on the body weight. It was observed that tumours became smaller, no reoccurrence was determined for three months. In this study, the results were similar with those found in the study of previous reporters (Biricik *et al.*, 2008; Yagci *et al.*, 2008).

In the present study, papillomas regression was verified after the second week, evidenced by papillomas necrosis, detachment and fall. Adverse effects were not observed in any animals treated during the treatment period and several months after the end of treatment.

As a result, *Tarantula cubensis* extract induced tumoral regression in dogs with viral papillomatosis and can be used as alternative to surgical and chemotherapy treatment been absent of adverse effects. Obviously, further studies need to be undertaken for the effect of *Tarantula cubensis* extract in canine oral papillomatosis.

ACKNOWLEDGMENT

We would like to mention the greatly appreciation to Prof. Dr. Yavuz GÜLBAHAR Prof. Dr. Yusuf NERGÝZ and Dr. Serhan TAÐDEMÝR, for their assistance. This study was supported by Dicle University Research Fund, project No. VF-091.

REFERENCES

- Arikan, N., K. Ozer and A. Belge, 1993. Kopeklerde oral papilloma. YYU Vet Fak. Derg, 4: 229-236.
- Bademkiran, S., D. Kurt, B. Yokus and R. Celik, 2009. Comparison of pelargonium sidoides, placebo and antibiotic treatment of chronic endometritis in dairy cows: A field trial. J. Anim. Vet. Adv., 8: 788-793.
- Beceriklisoy, H.B., N. Ozyurtlu, D. Kaya, J. Handler and S. Aslan, 2008. Effectiveness of *Thuja occidentalis* and *Urtica urens* in pseudopregnant bitches. Vet. Med. Aust. Wien. Tierarztl. Mschr. 95: 263-268.
- Biricik, H.S., M. Cabalar and M.Y. Gulbahar, 2008. Oral papillomatosis in a dog and its therapy with taurolidine. Acta Vet. Brno, 77: 373-375.
- Booney, C.H., S.A. Koch, W. Confer and P.F. Dice, 1980. A case report: A conjunctivocorneal papilloma with evidence of viral etiology. J. Small Anim. Pract., 21: 183-188.
- Bredal, W.P., S.I. Thoresen, E. Rimstad, M. Aleksandersen and P.H. Nafstad, 1996. Diagnosis and clinical course of canine oral papillomavirus infection. J. Small Anim. Pract., 37: 138-142.
- Campo, M.S., 2002. Animal models of papillomavirus pathogenesis. Virus Res., 89: 249-261.
- Carmona, J.U., C.E. Giraldo and M.J. Loaiza, 2002. Tratamiento de papilomatosis oral canina con cimetidina: Una nueva alternativa. Med. Vet., 20: 5-10.
- Greig, A.S.C. and K.M. Charlton, 1973. Electron microscopy of the virus Oral papillomatosis in the coyote. J. Wildlife Dis., 9: 359-361.

- Gultekin, N. and M.R. Vural, 2007. The effect of *Tarantula cubensis* extract applied in pre and postoperative period of canine mammary tumors. *JIVS*, 2: 13-23.
- Koch, H. and M. Stein, 1980. Konservative behandlung von neoplasmen der milchdrüse des hundes mit Theranekron. *Praktische Tierarzt*, 61: 424-430.
- Lucroy, M.D., F.I. Hill, P.F. Moore and B.R. Madewell, 1998. *Cutaneous papillomatosis* in a dog with malignant lymphoma following long-term chemotherapy. *J. Vet. Diagn Invest.*, 10: 369-371.
- Megid, J., Jr.J.G. Dias, D.M. Aguiar, Jr.G. Nardi, W.B. Silva and M.G. Ribeiro, 2001. Efficacy of *Canine papillomatosis* treatment using *Propionibacterium acnes* (*P. acnes*). *Arquivo Brasileiro de Med. Vet. Zootecnia*, 53: 574-576.
- Nicholls, P.K., B.A. Klaunberg, R.A. Moore, E.B. Santos, N.R. Parry, G.W. Gough and M.A. Stanley, 1999. Naturally occurring, nonregressing canine oral papillomavirus infection: Host immunity, virus characterization and experimental infection. *Virology*, 265: 365-374.
- Nicholls, P.K., P.F. Moore, D.M. Anderson, R.A. Moore, N.R. Parry, G.W. Gough and M.A. Stanley, 2001. Regression of canine oral papillomas is associated with infiltration of CD4+ and CD8+ lymphocytes. *Virology*, 283: 31-39.
- Raue, M., R. John, M. Marz, R. Raue and H. Muler, 2007. Papillomavirus infectionen beim hund: Übersicht (Papillomavirus infections in dogs: An overview). *Tierarztl Prax*, 35: 41-46.
- Sardari, K., E.G. Kakhki and M. Mohri, 2007. Evaluation of wound contraction and epithelialization after subcutaneous administration of Theranekron in cows. *J. Com. Clin. Path.*, 16: 197-200.
- Schulman, F.Y., A.E. Krafft and T. Janczewski, 2001. Feline cutaneous fibropapillomas: Clinicopathologic findings and association with papillomavirus infection. *Vet. Pathol.*, 38: 291-296.
- Sundberg, J.P., M. van Ranst, R. Montali, B.L. Homer and W.H. Miller *et al.*, 2000. Feline papillomas and papillomaviruses. *Vet. Pathol.*, 37: 1-10.
- Teifke, J.P., C.V. Lohr and H. Shirasawa, 1998. Detection of canine oral papillomavirus-DNA in canine oral squamous cell carcinomas and p53 overexpressing skin papillomas of the dog using the polymerase chain reaction and non-radioactive *in situ* hybridization. *Vet. Microbiol.*, 60: 119-130.
- Yagci, B.B., K. Ural, N. Ocal and A.E. Haydardedeoglu, 2008. Azithromycin therapy of papillomatosis in dogs: A prospective, randomized, double-blinded, placebo-controlled clinical trial. *Vet. Dermatol.*, 19: 194-198.