



Asian Journal of **Biochemistry**

ISSN 1815-9923



Academic
Journals Inc.

www.academicjournals.com

Biochemical, Hematological and Histopathological Effects of *Duranta repens* Stems on Rats

¹F. Nikkon, ¹S. Hasan, ¹M.H. Rahman, ¹M.A. Hoque, ²A. Mosaddik and ²M.E. Haque

¹Department of Biochemistry and Molecular Biology,

²Department of Pharmacy, University of Rajshahi, Rajshahi, 6205, Bangladesh

Abstract: Two triterpenes, β -Amyrin and 12-Oleanene 3 β , 21 β -diol, were isolated as a mixture from the chloroform soluble fraction of an ethanolic extract of *Duranta repens* stem. The structures of these two compounds were confirmed by IR, ¹H and ¹³C-NMR spectral data. In acute toxicity test, the chloroform soluble fraction showed toxic effect on rats but compound 1 (mixture of β -Amyrin and 12-Oleanene 3 β , 21 β -diol) had no toxic effect on rat at 2 mg/kg/day b.wt. Biochemical and hematological profiles of rat's blood of chloroform soluble fraction were found statistically significant. In histopathological experiment, some degenerative changes on cellular structure of liver, heart and kidney except lungs were found in chloroform soluble fraction treated rats.

Key words: *Duranta repens* Linn., chloroform soluble fraction, compound 1, acute toxicity

INTRODUCTION

Duranta repens Linn. (Syn. *Duranta plumieri* Jacq., *D. erecta* Linn. and Eng: Golden dewdrop) is commonly known as pigeon berry and locally called 'Katamehedi' belongs to the family Verbenaceae. It is shrubs, herbs or small tree usually 1 to 3 m in height and also grown as a hedge plant in various parts of our country (David, 1981). The plant is not browsed by cattle and is believed to be poisonous. However, birds feed on the fruits without difficulty (Nelson, 1996; Floridata, 1999). Ethyl acetate and aqueous extracts of leaves showed significant antimalarial activity when administered to mice (Castro *et al.*, 1996). The fruits are used in the treatment of malaria and intestinal worms (Whistler, 2000). The leaves are used in the treatment of abscess (Xiao, 1992). The plant is reported to produce a wide range of steroids (Ahmad *et al.*, 1998), flavonoids (Anis *et al.*, 2001, 2002), glycosides (Takeda *et al.*, 1995), steroidal glycosides (Hiradate *et al.*, 1999) and terpenoids (Ahmad *et al.*, 1998; Makboul and Abdul, 1981). Recently Abou-Setta *et al.* (2007) reported six known compounds along with naringenin, sucrose and raffinose isolated for the first time from this species.

This study described biochemical, hematological and histopathological effect of chloroform soluble fraction and a mixture of two triterpenes as compound 1 (β -Amyrin and 12-Oleanene 3 β , 21 β -diol), isolated from the chloroform soluble fraction of an ethanolic extract of *Duranta repens* stem on rat.

MATERIALS AND METHODS

Plant Collection

Stem of *Duranta repens* Linn. were collected in June 2003 from the adjoining areas of Rajshahi University Campus, Bangladesh and were identified by Professor ATM Nadiruzzaman, Department of Botany, University of Rajshahi, Bangladesh, where a voucher specimen (No. Alam 78, collection date 19.09.1997) of this collection has been deposited.

Corresponding Author: Dr. Farjana Nikkon, Department of Biochemistry and Molecular Biology,
University of Rajshahi, Rajshahi, 6205, Bangladesh
Tel: +88-0721-750041-49/4109 Fax: +88-0721-750064

Chemicals

All organic solvents used in extraction and isolation were analytical grade supplied by Marck, Germany. The PTLC Silica gel-60 plates were collected from Fluka, Switzerland. The ^1H and ^{13}C NMR spectra were recorded at 500 and 125 MHz, respectively with TMS as internal standard using a 500 MHz Bruker Drx NMR instrument. The IR spectra were recorded with a Perkin-Elmer Lambda spectrophotometer. Melting points were determined using a Digital Melting point Apparatus (model IA 8103, Electrothermal Engineering Ltd., Southend-on-Sea, Essex, UK) and are uncorrected.

Animals

Long Evan's rat (100.50-104.25 g) were collected from the Animal Resources Branch of the International Center for Diarrhoeal Research, Dhaka, Bangladesh. The experiment was performed at the Department of Pathology, Rajshahi Medical College. The rats were kept in numbered iron cages for two weeks before treatment. They were fed a balanced diet (Howk *et al.*, 1954) and tap water, under standard conditions of a 12 h dark-light cycle, $60\pm 10\%$ humidity and a temperature of $21.5\pm 1.0^\circ\text{C}$. These protocols were approved by the Institutional Animal Care and Use Committee of UNICAMP which follows the recommendations of the Canadian Council on Animal Care.

Isolation and Purification

Duranta repens stems were sun dried and pulverized into a coarse powder. The ground plant materials (1 kg) were then extracted in cold with ethanol (5.0 L). After concentration, the ethanol extract was fractionated with diethyl ether and chloroform. The solvents were concentrated by rotary evaporator at 40°C under reduced pressure to afforded a semisolid mass of ethanol extract, diethyl ether and chloroform soluble fractions (90.0, 20.8 and 15.6 g), respectively. The chloroform soluble fraction (5 g) of *Duranta repens* was then subjected to a column chromatography over silica gel eluting with n-hexane and ethyl acetate of increasing polarity which gave a total of 33 fractions. Among these, fractions 4-15 eluted with n-hexane and ethyl acetate (2:1) showed similar spots on TLC and were combined. The combined CC fractions were then subjected to PTLC using the solvent system n-hexane-ethyl acetate (5:1). The pink colored band was observed in an edge of the chromatogram by spraying with vanillin- H_2SO_4 reagent and was scrapped off and eluted with ethyl acetate and evaporated off under reduced pressure to afford a compound 1 (480 mg) as amorphous powder. From spectral analysis, compound 1 was found to be a mixture of two compounds, but their separation was not possible due to similar R_f value and used as such for acute toxicity study.

Administration

Vehicles were prepared by dissolving the Tween-20 (5 drops) in distilled water in such a way that makes turbid suspensions. Chloroform soluble fractions (14.525 mg) were measured and dissolved in 5.6 mL of distilled water with the help of Tween-20 in such a way that 0.2 mL contained 5 mg/kg/day b.wt. of chloroform fractions. Again, compound 1 (5.628 mg) was accurately measured and dissolved in distilled water (5.6 mL) with the help of Tween-20, so that 0.2 mL contained 2 mg/kg/day b.wt. of compound 1.

Experimental Procedure

A measured amount of fresh food was supplied daily at 10.00 am and the general well-being and behavior of the animals were observed daily, throughout the study. For the haematological study, blood was drawn from the tail vein of both the control and experimental groups before administration of the normal diet, vehicles, chloroform soluble fractions and compound 1. After the experimental period, we estimate the total RBC (red blood cells), total WBC (white blood cells), differential count of WBC

(neutrophil, lymphocyte, monocyte, eosinophil) and platelet count by smearing blood on glass slides and stained with Leishemen reagent using the standard method. Haemoglobin (%) and ESR (erythrocytes sedimentation rate) were also determined by standard procedure (Schalm *et al.*, 1975). For the biochemical study, blood was collected from each rat sacrificed at day 7 from the jugular veins. Serum glutamic-oxaloacetic transaminase, serum glutamate pyruvate transaminase, serum alkaline phosphatase, urea, bilirubin and creatinine were determined using standard procedures and reagents supplied by Boehringer Mannheim GmbH Diagnostica. Histopathological studies of the liver, kidney, heart and lung were performed using haematoxylin, eosin stain and DPX mounting fluid (Gurr, 1962). The samples were observed under a microscope at the Department of Pathology, Rajshahi Medical College, Rajshahi, Bangladesh.

Statistical Analysis

Results are presented as the Mean±SD. Student's t-test was used for comparison between the experimental and control groups. $p < 0.05$ was considered to be statistically significant.

RESULTS AND DISCUSSION

Characterization of Compound 1

Compound 1 was isolated from the chloroform fraction of ethanol extract of the stem of *Duranta repens* Linn. as white amorphous powder, decomposed between 121-125°C. IR spectrum of compound 1 showed O-H stretching band between 3445-3888 cm^{-1} and C-O-stretching vibration at 1099 cm^{-1} . C-H and $>C=C-H$ stretching vibrations observed between 2877-2924 cm^{-1} and $>C=C<$ stretching showed a strong band at 1689 cm^{-1} . Although the TLC examination of compound 1 showed a single spot, but the NMR data (both ^1H and ^{13}C) suggested that, compound 1 was not a single one. The ^1H -NMR spectrum (500 MHz, CDCl_3) of compound 1 showed two triplets ($J = 3.6$ Hz) at δ_{H} 5.26 and 5.30 which suggested the presence of two oleanene type triterpenes having double bond at $\text{C}_{12}-\text{C}_{13}$. By comparison of ^1H and ^{13}C -NMR data to those published in literature, (Ndom *et al.*, 2001; Rahman, 2002) it was possible to identify these two triterpenes existed in compound 1 as β -Amyrin and 12-Oleanene 3β , 21β -diol (Fig. 1a, b). So far, to our best knowledge, earlier α -amyrin was isolated from this species (Mokboul and Abdul, 1981). But both the isolated compound β -Amyrin and 12-Oleanene 3β , 21β -diol are reported for the first time from this plant.

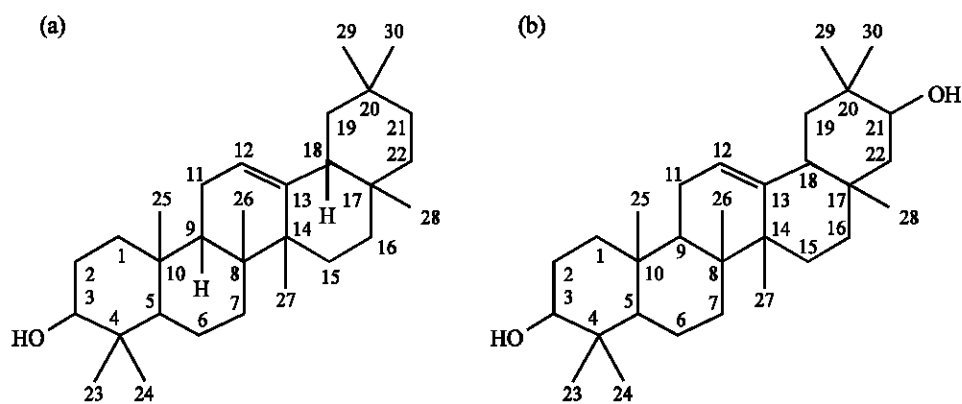


Fig. 1: Structure of Compound 1, (a) β -Amyrin and (b) 12-Oleanene 3β , 21β -diol

Gross General Observation

The controls (both normal diet and vehicle) and compound 1 treated rats did not show any abnormalities and their food intake was also observed to be normal. But chloroform soluble fraction treated rats showed some noticeable signs such as tremor, convulsion and reflex abnormalities, muscular numbness of the hind and fore legs, salivation or diarrhoea.

Body Weight

Table 1 shows the average body weights of all the rats before and after the treatment and the data are presented. The percentage change in body weight of compound 1 treated rat groups (8.7%) were quite normal compare to diet groups (6.3%) and vehicles groups (6.9%) and but in case of chloroform soluble fraction treated rats, the percentage change in body weight was lower (only 1.2%) compared to other groups.

Hematological Profiles

As given in Table 2, the hematological profiles such as total RBC, total WBC, differential count of WBC, platelet, haemoglobin and ESR were observed at 1st and 7th day of treatment. In controls (both normal diet and vehicles) and compound 1 treated rat, almost all hematological parameters were

Table 1: Change of body weights of controls (both normal diet and vehicle) and experimental rats (chloroform soluble fraction and compound 1)

Group of rats	Dose (i.p)	Body weight before experiment (g)	Body weight after experiment (g)	Change (%)
Controls	Normal diet	103.25±0.50	109.75±1.26	6.3
	0.2 mL of vehicle	104.25±0.96	111.50±2.38	6.9
Experimental	5 mg/kg/day chloroform soluble fraction	103.75±4.57	105.00±2.94	1.2
	2 mg/kg/day compound 1	100.50±3.11	109.25±6.50	8.7

Values are expressed as Mean±SD, n = 4

Table 2: Hematological parameters of control (both normal diet and vehicle) and experimental rat (chloroform soluble fraction and compound 1)

Parameters	Control (normal diet)		Control (vehicle)	
	1st day	7th day	1st day	7th day
RBC cells (mL ⁻¹ ×10 ⁶)	5.525±1.50	5.00±0.08	4.80±0.18	5.05±0.06
WBC cells (mL ⁻¹ ×10 ⁶)	6.600±0.18	7.02±0.05	6.77±0.12	7.15±0.12
Neutrophil cells (mL ⁻¹ ×10 ⁶)	54.000±1.83	54.75±2.06	54.50±1.73	56.75±1.50
Lymphocyte cells (mL ⁻¹ ×10 ⁶)	31.500±1.29	31.75±1.26	32.25±1.26	32.75±0.96
Monocyte cells (mL ⁻¹ ×10 ⁶)	4.000±0.82	4.75±0.96	3.75±0.50	4.00±0.82
Eosinophil cells (mL ⁻¹ ×10 ⁶)	1.500±0.58	1.75±0.50	1.75±0.50	1.75±0.50
Platelet cells (mL ⁻¹ ×10 ⁶)	302.500±1.26	305.00±1.00	308.50±9.94	310.00±9.12
Hemoglobin (%)	12.750±0.50	13.25±0.50	13.00±0.00	13.50±0.58
ESR (mm/1st h)	13.750±1.26	14.25±1.26	14.00±0.82	14.75±0.50
	Experimental (Chloroform fraction)		Experimental (compound 1)	
	-----		-----	
Parameters	1st day	7th day	1st day	7th day
RBC cells (mL ⁻¹ ×10 ⁶)	4.825±0.10	3.95±0.060***	4.75±0.130	5.00±0.17
WBC cells (mL ⁻¹ ×10 ⁶)	6.850±0.05	5.95±0.057***	6.87±0.095	7.15±0.12
Neutrophil cells (mL ⁻¹ ×10 ⁶)	55.000±0.82	52.50±0.580*	54.75±0.960	55.00±0.82
Lymphocyte cells (mL ⁻¹ ×10 ⁶)	31.250±1.26	30.50±0.580**	32.50±0.580	32.50±0.58
Monocyte cells (mL ⁻¹ ×10 ⁶)	3.750±0.50	3.25±0.500*	3.50±0.580	4.00±0.82
Eosinophil cells (mL ⁻¹ ×10 ⁶)	1.500±0.58	3.00±0.000***	1.50±0.580	2.00±0.00
Platelet cells (mL ⁻¹ ×10 ⁶)	296.250±4.78	252.50±5.000***	302.50±2.880	305.00±0.00
Hemoglobin (%)	12.500±0.58	12.25±0.500*	12.75±0.500	13.00±0.00
ESR (mm/1st h)	13.750±0.96	13.00±0.000**	13.50±0.580	14.0±0.820

Data are expressed as Mean±SD, *p<0.05, **p<0.01, ***p<0.001 vs control (normal diet), •p<0.05, ••p<0.01, •••p<0.001 Vs control (vehicle)

slightly increased after 7 days and no abnormality was observed. In case of chloroform soluble fraction treated rats almost all hematological parameters were decreased significantly after 7 days. But only the eosinophil value was increased significantly.

Biochemical Parameters of Blood

Table 3 shows that the biochemical parameters such as SGPT, SGOT, SALP, bilirubin and blood urea of chloroform soluble fraction treated rats were increased significantly, but the creatinine value was increased insignificantly. In case of compound 1 treated experimental rats, the values of SGPT and SGOT were increased significantly while the other parameters were changed insignificantly.

Histopathological Observations

A marked detectable histopathological difference among the controls (both normal diet and vehicles) and chloroform soluble fraction treated rats were observed after the experimental period (Fig. 2a, b, 3a, b, 4a, b). The tissues such as liver, heart, lung and kidney of the chloroform soluble

Table 3: Biochemical parameters of control (both normal diet and vehicle) and experimental rat (chloroform soluble fraction and compound 1)

Parameters	Control (normal diet)	Control (vehicle)	Experimental (chloroform fraction)	Experimental (compound 1)
SGPT (IU L ⁻¹)	12.25±0.50	12.50±0.58	18.00±0.82*****	13.50±0.58*
SGOT (IU L ⁻¹)	14.00±0.82	14.25±0.50	19.50±0.58*****	15.50±0.58*
SALP (IU L ⁻¹)	10.00±0.00	10.25±0.50	11.75±0.50*****	10.50±0.58
Bilirubin (mmol dL ⁻¹)	0.37±0.01	0.36±0.01	0.38±0.00*	0.37±0.00
Creatinine (mg dL ⁻¹)	0.59±0.01	0.59±0.05	0.60±0.06	0.57±0.06
Blood urea (mg dL ⁻¹)	17.75±0.96	17.50±2.08	20.50±0.58**	17.50±0.58

Data are expressed as Mean±SD. *p<0.05, **p<0.01, ***p<0.001 Vs control (normal diet), •p<0.05, ••p<0.01, •••p<0.001 Vs control (vehicle)

Table 4: Histopathological examinations of control (both normal diet and vehicle) and experimental rat (chloroform soluble fraction and compound 1)

Group	Dose (i.p)	Histopathological changes observed in tissues of rats			
		Liver	Heart	Lungs	Kidney
Controls	Normal diet	NAD	NAD	NAD	NAD
	0.2 mL of vehicle	NAD	NAD	NAD	NAD
Experimental	5 mg/kg/day chloroform fraction	Hyperplasia	Degenerative change	NAD	Hyperplasia
	2 mg/kg/day compound 1	NAD	NAD	NAD	NAD

NAD indicates no abnormality detected

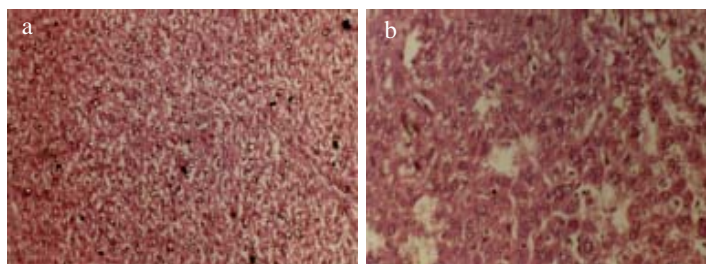


Fig. 2: Microscopic view of liver tissues of (a) control (normal diet) rat after 7 days and (b) experimental rat (chloroform fraction)

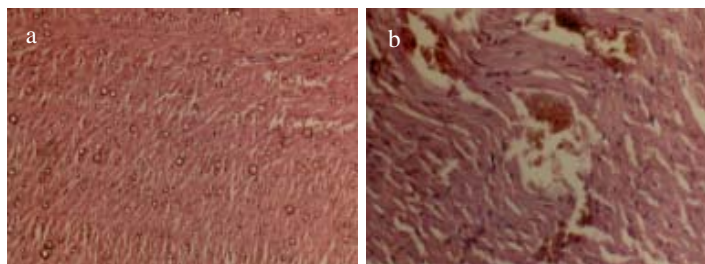


Fig. 3: Microscopic view of heart tissues of (a) control (normal diet) rat after 7 days and (b) experimental rat (chloroform fraction)

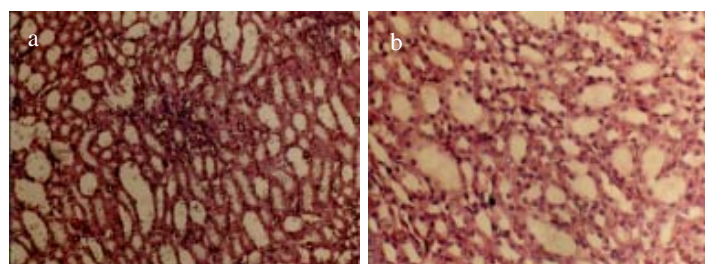


Fig. 4: Microscopic view of kidney tissues of (a) control (normal diet) rat after 7 days and (b) experimental rat (chloroform fraction)

fraction treated rats are shown in Table 4. Although the controls (both normal diet and vehicles) and compound 1 treated rats had no toxic effect in this dose (2 mg/kg/day b.wt.) on cellular structure.

CONCLUSION

From the biochemical, hematological and histopathological examinations, it was confirmed that chloroform soluble fractions (5 mg/kg/day b.wt.) of stem of *Duranta repens* Linn. was found to be toxic. Because all the biochemical parameters such as, SGOT, SGPT, SALP, bilirubin and blood urea were significantly increased compared to those of both normal diet and vehicle treated rats which indicate abnormal status of liver and kidney functions, respectively and it was also confirmed from the histopathological examination where some degenerative changes were occurred on cellular structure of liver, heart and kidney except lung. On the other hand, the isolated compound 1 (mixture of β -amyryn and 12-Oleanene 3 β , 21 β -diol) had no toxic effect at 2 mg/kg/day b.wt.. From the above findings, it can be concluded that the greater toxicity of the chloroform soluble fractions than the isolated compound 1 may be due to the synergic effect of compounds present in the chloroform soluble fraction. But more extensive toxicological studies are needed to understand the mechanism of action of plant extract.

ACKNOWLEDGMENTS

The authors are thankful to Department of Pathology, Rajshahi Medical College and Dr. Md. Anwar Habib, Lecturer, Department of Pharmacology, Rajshahi Medical College for providing laboratory facilities, Apurba Kumar Roy, Assistant Professor of Genetics and Breeding of Rajshahi University for histopathological study and Professor Peter G Waterman, Centre for

Phytochemistry and Pharmacology, Southern Cross University, Lismore, Australia, for running of ^1H and ^{13}C -NMR spectra and Dr. Mukhlesur Rahman, Department of Pharmacy for providing spectral data analysis.

REFERENCES

- Abou-Setta, L.M., N.M. Nazif and A.A. Shahat, 2007. Phytochemical investigation and antiviral activity of *Duranta repens*. *J. Applied Sci. Res.*, 3: 1426-1433.
- Ahmad, S., T.A. Nizami, H.R. Nawaz, A. Malik and N. Afza, 1998. A new steroid from *Duranta repens*. *Fitoterapia*, 69: 448-450.
- Anis, I., F. Anis, S. Ahmed, G. Mustafa and A. Malik *et al.*, 2001. Thrombin inhibitory constituents from *Duranta repens*. *Helv. Chim. Acta*, 84: 649-655.
- Anis, I., S. Ahmed, A. Malik, A. Yasin and M.I. Choudary, 2002. Enzyme inhibitory constituents from *Duranta repens*. *Chem. Pharm. Bull.*, 50: 515-518.
- Castro, O., M. Barrios, M. Chinchilla and O. Guerrero, 1996. Chemical and biological evaluation of the effect of plant extracts against *Plasmodium berghei*. *Rev. De Biol. Trop.*, 44: 361-367.
- David, P., 1981. Bengal plants. Dehradun, India, 2: 822-838.
- Floridata, 1999. *Duranta erecta*. http://floridata.com/ref.d.dra_ere.cfm, 3.
- Gurr, E., 1962. Staining, Animal Tissues. Leonard Hill (Books) Ltd., London, pp: 631.
- Hiradate, S., H. Yada, T. Ishii, N. Nakajima and K.M. Ohnishi *et al.*, 1999. Three plant growth inhibiting saponins from *Duranta repens*. *Phytochemistry*, 52: 1223-1228.
- Howk, B.P., L.B. Oser and H.W. Summerson, 1954. *Practical Physiological Chemistry*. 13th Edn. McGraw Hill Book, Co. Inc., New York, USA.
- Makboul, A.M. and B.A.M. Abdul, 1981. Flavonoids from the leaves of *Duranta plumieri*. *Fitoterapia*, 52: 219-220.
- Ndom, J.C., K.J.C. Vardamides, J.D. Wansi, A.W. Kamdem and J.T. Mobafor *et al.*, 2001. Constituents of *Erythrina sigmoidea*. *Bull. Chem. Soc. Ethiop.*, 15: 151-156.
- Nelson, G., 1996. The shrubs and woody vines of Florida. Pineapple Press Inc., Sarasota, FL., pp: 391.
- Rahman, M.M., 2002. Phytochemical and antimicrobial studies on some species of Bangladeshi Leguminaceae and Rutaceae. Ph.D Thesis, University of Strathclyde, UK., pp: 225-228.
- Schalm, O.W., N.C. Jain and G.H. Carrol, 1975. *Veterinary Haematology*. 3rd Edn., Wadsworth Publication Co. Inc., Belmont, California.
- Takeda, Y., Y. Morimoto, T. Matsumoto, C. Ogimi and E. Hirata *et al.*, 1995. Iridoid glucosides from the leaves and stems of *Duranta erecta*. *Phytochemistry*, 39: 829-833.
- Whistler, W.A., 2000. *Tropical ornamentals a guide*. Timber Press, Inc., Portland, OR., pp: 542. http://www.hear.org/Pier/wra/pacific/mandevilla_x_amabilis_htmlwra.htm.
- Xiao, P., 1992. *A Pictorial Encyclopaedia of Chinese Medical Herbs*. Chuokoron-Sha, Inc., Tokyo, 1: 158.