



# Asian Journal of **Biochemistry**

ISSN 1815-9923



Academic  
Journals Inc.

[www.academicjournals.com](http://www.academicjournals.com)

## Biochemical and Histological Changes Associated with Long Term Consumption of *Gnetum africanum* Welw. Leaves in Rats

<sup>1</sup>Emeka E.J. Iweala, <sup>2</sup>Friday O. Uhegbu and <sup>3</sup>O. Obidoa

<sup>1</sup>Department of Biological Sciences, Biochemistry and Molecular Biology Unit, Covenant University, P.M.B. 1023, Ota, Ogun State, Nigeria

<sup>2</sup>Department of Biochemistry, Abia State University, Uturu, Nigeria

<sup>3</sup>Department of Biochemistry, University of Nigeria, Nsukka, Nigeria

---

**Abstract:** Changes in some biochemical and haematological indices including serum protein, haemoglobin, cholesterol, lipid peroxidation, white blood cells, Glutathione-s-transferase, Superoxide dismutase, Alanine transaminase, Aspartate transaminase and Alkaline phosphatase were investigated in male rats fed with a diet supplemented with leaves of *Gnetum africanum*. The histological changes on the liver, intestines and testes were also examined. The long term feeding of the *Gnetum africanum*-supplemented diet caused significant increases ( $p < 0.05$ ) in weight, haemoglobin and white blood cells. There were also significant increases ( $p < 0.05$ ) in Glutathione-s-transferase and Superoxide dismutase enzymes. However, *Gnetum africanum*-supplemented diet caused a significant reduction ( $p < 0.05$ ) in serum protein and lipid peroxidation. The liver enzymes namely Alanine transaminase, Aspartate transaminase and Alkaline phosphatase were unaffected while the reduction in cholesterol was not significant. Histologically, the liver hepatocytes and hepatic plates were respectively elongated and enlarged while the intestinal mucosa showed elongated villi and enlarged submucosa. There were however no histological changes on the testes.

**Key words:** *Gnetum africanum*, haemoglobin, white blood cells, lipid peroxidation, Glutathione-s-transferase, Superoxide dismutase

---

### INTRODUCTION

*Gnetum africanum* Welw. is one of the green leafy vegetables consumed in Africa, Asia and South America (Watt and Breyer-Brandwijk, 1962). Leafy vegetables contribute to the local diets as staples, flavours, condiments, spices, drinks and beverages in most developing countries especially, Nigeria (Okafor, 1980; Ejiofor *et al.*, 1988). *Gnetum africanum* is a dioecious plant belonging to the family Gnetaceae. *Gnetum africanum* are wild understory lianas that grow on trees in the humid forests of Africa (Mialoundama, 1993). *Gnetum africanum* especially the leaves are the part that is mostly used. It is used in the treatment of enlarged spleen, sore throat and as a cathartic (Burkill, 1994). It is also used to reduce nausea and neutralize some poisons. It can be externally applied to boils and warts and is used to reduce the pain of childbirth. However, *G. africanum* is most prized for its culinary use. The leaves of *G. africanum* can be eaten raw and shredded and used in

---

**Corresponding Author:** Emeka E.J. Iweala, Department of Biological Sciences, Biochemistry and Molecular Biology Unit, Covenant University, P.M.B. 1023, Ota, Ogun State, Nigeria Tel: +234(0)8036738625

preparing soups and stews (Burkill, 1994). The consumption of leaves of *G. africanum* and its medicinal applications in most African countries despite its relative unavailability and high cost indicates its importance as major dietary supplement. Generally there is very scanty information on the biological and histological effects of consumption of leaves of *G. africanum*. This study is aimed at generating information on some biochemical, haematological and histological changes associated with the long term consumption of a diet supplemented with leaves of *G. africanum* in male rats.

## MATERIALS AND METHODS

This study was carried out between October, 2005 to April, 2007 at the Department of Biochemistry, University of Nigeria, Nsukka, South East, Nigeria.

### Processing of *G. africanum* Leaves

Fresh leaves of *G. africanum* were bought from a local market in Nsukka, South-Eastern Nigeria. The leaves were picked, air-dried and ground to a coarse powdered form with a hammermill. The proximate composition of the ground leaves of *G. africanum* was determined according to the procedure of AOAC (1975).

### Formulation of Experimental Diets

Two experimental diets namely Control Diet (CD) and *Gnetum africanum*-supplemented diet (GASD) were formulated. The diets were formulated from commercially available feed grade feedstuffs including maize, corn flour, fish meal, groundnut meal, bone meal and vitamin premix. The result of the proximate composition of the leaves of *G. africanum* was considered in the formulation of an isocaloric and isonitrogenous *Gnetum africanum*-supplemented diet (GASD). The control diet (CD) was formulated without the inclusion of *G. africanum* powder while the *Gnetum africanum*-supplemented diet (GASD) was incorporated with 5% of *G. africanum* powder.

### Experimental Design

Eighteen male albino rats aged four weeks old and with an average weight of 40 g were used for the experiment. The experimental design involved random distribution of the rats into two experimental groups namely Control Group (CG) and *Gnetum africanum* group (GAG) consisting of nine animals each. The animals in CG were fed control diet (CD) while those in GAG were fed *Gnetum africanum*-supplemented diet (GASD) and given water *ad libitum* for 180 days. Weight changes of animals in the two groups were recorded on a monthly basis.

### Preliminary Qualitative Phytochemical Analysis

Preliminary qualitative phytochemical analysis of the leaves of *Gnetum africanum* was carried out as described by Odebiyi and Sofowora (1978) to test for the presence of tannins, phytosterols, glycosides, flavonoids, anthocyanidins, alkaloids and saponins.

### Collection of Blood, Organs and Tissue Samples

At the end of the 180 days of feeding, 6 animals from each group were anesthetized and decapitated. Blood samples were collected in labelled sample bottles with drops of Ethylenediaminetetraacetic acid (EDTA). Serum samples were collected in sample bottles without EDTA and allowed to clot before being centrifuged at 5000 rpm for 10 min.

The liver, intestines and testes were promptly excised soon after decapitation and stored in 10% formyl saline.

### Biochemical Determinations

Total serum protein was determined by the Lowry method (1951). Total and free cholesterol were determined by the method of Searcy and Bergquist (1960). Lipid peroxidation was determined by the method of Wallin *et al.* (1993). Haemoglobin and White Blood Cells (WBC) were determined according to methods described by Dacie and Lewis (1990). Glutathione-s-transferase (GST) was assayed according to the method described by Habig *et al.* (1974). Superoxide Dismutase (SOD) was assayed by the method of Jewett and Rocklin (1993). Aspartate aminotransferase (AST), Alanine aminotransferase (ALT) and Alkaline phosphatase (ALP) were determined using Randox test kits (Reitman and Frankel, 1957).

### Histological Examination

Histological studies on the organs and tissues were done according to procedures described by Disbrey and Rack (1970) and Drury and Wellington (1967).

### Statistical Analysis

Results were expressed as Mean $\pm$ SE of mean (SEM) for triplicate determinations. A one-way Analysis of Variance (ANOVA) for a completely randomized design and Duncan's multiple range tests were used to analyse experimental data. Values were considered significant at  $p < 0.05$ .

## RESULTS

The leaves of *Gnetum africanum* contained all the phytochemicals that were screened including tannins, phytosterols, glycosides, flavonoids, anthocyanidins, alkaloids and saponins as shown in Table 1.

The long term effect of feeding *Gnetum africanum*-supplemented diet (GASD) on weight and some biochemical parameters are presented in Table 2. *Gnetum africanum*-supplemented

Table 1: Qualitative phytochemical constituents of leaves of *Gnetum africanum*

Substances	Presence
Phenolic substances	++
Flavonoids	++
Anthocyanidins	+++
Phytosterols	+
Tannins	++
Saponins	++
Alkaloids	+
Glycosides	++
Cyanogenic glycosides	++
Cardiac glycosides	++

+: Presence

Table 2: Effect of *Gnetum africanum*-supplemented diet (GASD) on some biochemical parameters (n = 6)

Experimental groups (Diet)	Weight (%)	Protein (mg mL <sup>-1</sup> )	Cholesterol (mM L <sup>-1</sup> )	Hemoglobin (g dL <sup>-1</sup> )	WBC (10 <sup>3</sup> mm <sup>-3</sup> )	Lipid peroxidation (mg mL <sup>-1</sup> )
Control diet (CD)	60.0 $\pm$ 7.28	261 $\pm$ 16.4	1.43 $\pm$ 0.18	9.80 $\pm$ 0.50	5.13 $\pm$ 0.29	5.03 $\pm$ 0.23
<i>Gnetum africanum</i> -supplemented diet (GASD)	76.6 $\pm$ 7.05*	234 $\pm$ 9.67*	1.37 $\pm$ 0.09	11.7 $\pm$ 0.87*	5.73 $\pm$ 0.41*	4.45 $\pm$ 1.06*
Experimental groups (Diet)	GST (IU L <sup>-1</sup> )	SOD (U mg <sup>-1</sup> protein)	AST (IU L <sup>-1</sup> )	ALT (IU L <sup>-1</sup> )	ALP (IU L <sup>-1</sup> )	
Control diet (CD)	5.41 $\pm$ 0.82	70.7 $\pm$ 3.68	88.7 $\pm$ 7.41	45.3 $\pm$ 5.3	88.6 $\pm$ 8.96	
<i>Gnetum africanum</i> -supplemented diet (GASD)	7.15 $\pm$ 1.66*	109 $\pm$ 10.7*	69.0 $\pm$ 28.1	47.0 $\pm$ 1.4	85.7 $\pm$ 3.86	

\* $p < 0.05$

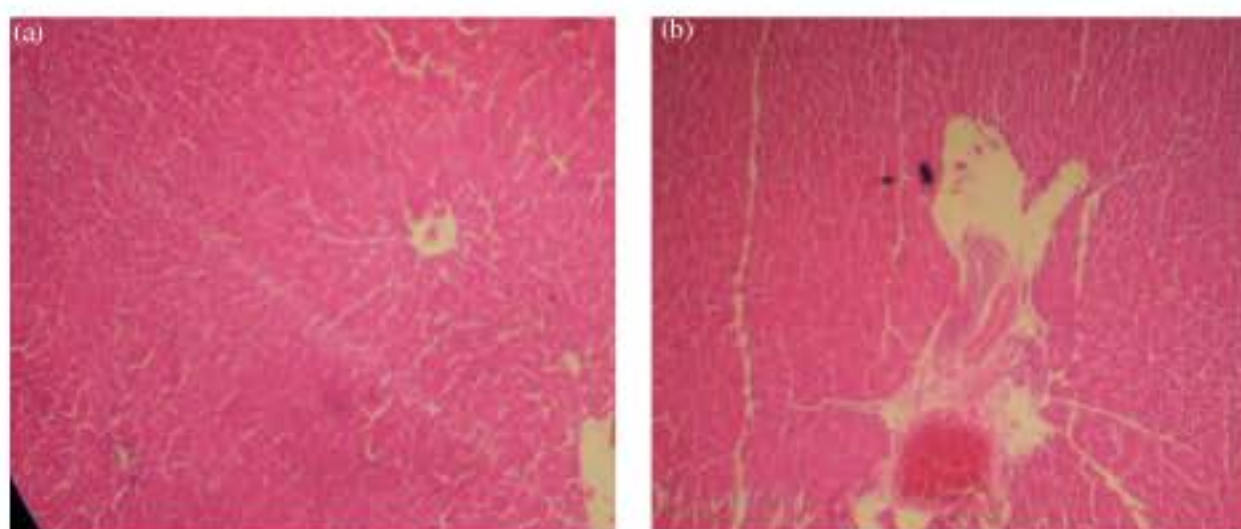


Fig. 1: (a) Photo micrography of a cross section of liver of rats fed with control diet (CD). MAG. x40, (b) Photo micrography of a cross section of liver of rats fed with *Gnetum africanum*-supplemented diet (GASD). MAG. x40

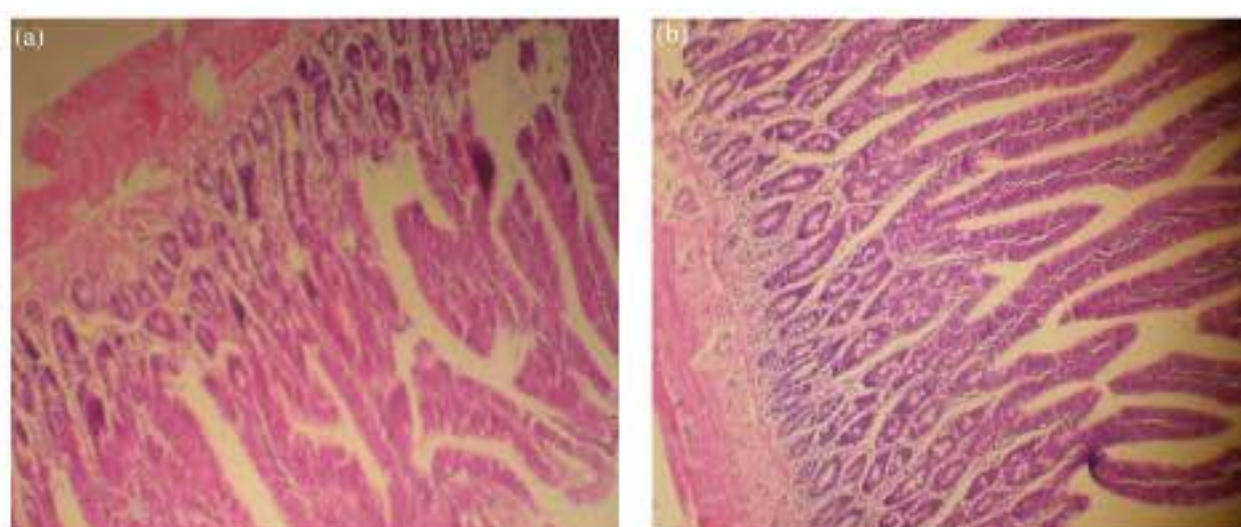


Fig. 2: (a) Photo micrography of a cross section of intestine of rats fed with control diet (CD). MAG.x 40, (b) Photo micrography of a cross section of intestine of rats fed with *Gnetum africanum*-supplemented diet (GASD). MAG. x40

diet caused a significant percentage increase ( $p<0.05$ ) in weight gain when compared to the control. The reduction in the cholesterol level was not statistically significant. The lipid peroxidation level was reduced from  $5.03\pm 0.23$  and  $4.45\pm 1.06$  in animals fed GASD. This reduction in lipid peroxidation was significant ( $p<0.05$ ). Haemoglobin levels were also remarkably increased in the animals fed with GASD. There was a significant reduction ( $p<0.05$ ) in serum protein. White Blood Cells (WBC) count were significantly increased ( $p<0.05$ ) from  $5.13\pm 0.29$  to  $5.73\pm 0.41$ .

The effect of GASD on some enzyme levels showed that there were significant increases ( $p<0.05$ ) in GST and SOD. All the liver enzymes including AST, ALT and ALP did not show any significant changes.

The histological features of the liver of the animals fed control diet (CD) and *Gnetum africanum*-supplemented diet (GASD) are presented in Fig. 1a, b. The hepatocytes of the rats fed GASD were elongated while the portal tracts were enlarged with dilated vessels. Also, there were histological changes in the intestinal mucosa and submucosa of rats fed with GASD when compared to the control as shown in Fig. 2a, b. The mucosa showed elongated villi and enlarged submucosa with dilated vessels. There were no histological changes in the testes of the animals fed with GASD when compared to the control group as presented in Fig. 3a, b.

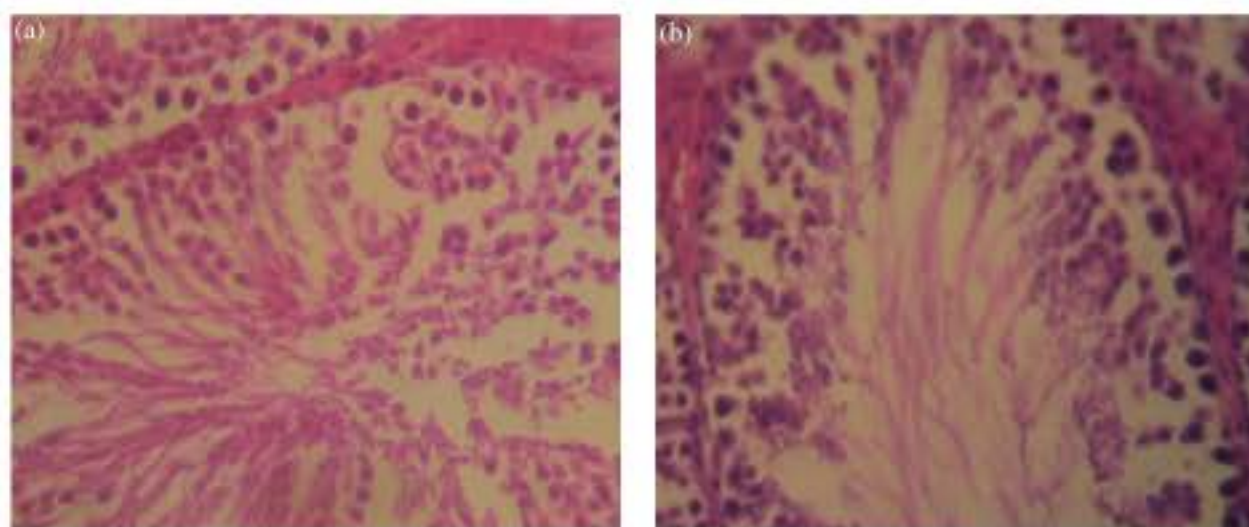


Fig. 3: (a) Photo micrography of a cross section of testes of rats fed with control diet (CD). MAG. x8, (b) Photo micrography of a cross section of testes of rats fed with *Gnetum africanum*-supplemented diet (GASD). MAG. x8

### DISCUSSION

This feeding experiment showed that the long term consumption of the leaves of *Gnetum africanum* significantly increased the weight of animals. The increase in weight is due to high ingestion of the GASD by the animals as a result of its palatability. This observation is similar to the increase in weight of rats fed a diet supplemented with *Telfairia occidentalis* (Iweala and Obidoa, 2009). The leaves of *Gnetum africanum* can be consumed in its raw state without further processing. *Gnetum africanum* is one of the vegetables commonly consumed in Nigeria especially south eastern Nigeria where it is used in preparation of soups and salads because of the belief that its leaves are important source of valuable nutrients (Fasuyi, 2006; Busson, 1965). Increase in weight is associated with high quality nutrients which are commonly found in the leaves of *Gnetum africanum* (Fokou and Domngang, 1989; Mialoundama, 1993). Plant foods such as *Gnetum africanum* have both nutrient and non-nutrient components (Isong *et al.*, 1999; Iwu, 1986). These nutrients especially proteins, carbohydrates and lipids are needed for growth, body repair and maintenance (Davidson *et al.*, 1975). Thus the leaves of *Gnetum africanum* constitute an important source of protein, essential amino acids and mineral elements (Ouabonzi *et al.*, 1983). The serum protein of rats fed with GASD was significantly reduced which is a reflection of the indigestibility and hence unavailability of protein constituent of leaves of *Gnetum africanum*. Reduction in serum protein could have consequences on the overall physiological function of animals. The reduction in cholesterol by the consumption of *Gnetum africanum* was not significant but supports several studies done with plant foods and green leafy vegetables suggesting their possible hypocholesterolemic effects (Hassel, 1998). The levels of haemoglobin and white blood cells were significantly increased with the consumption of *Gnetum africanum*. Most phytochemical constituents of plant foods affect the immune system and other haematological parameters (Kubena and McMurray, 1996). Antioxidant phytochemicals are known to protect lymphocytes and reduce their destruction (Duthie *et al.*, 1996). Flavonoids are known to inhibit platelet aggregation (Formica and Regelson, 1995). Phytosterols modulate immune function through their effect on T-helper cells and natural killer cells (Bouic *et al.*, 1999). In this study, the level of white blood cells (WBC) was used as an index of immune function. The phytochemical constituents of *Gnetum africanum* which include flavonoids and phytosterol are possible candidates that increase white blood cells. The mineral and vitamin contents of *Gnetum africanum* include haematinic

factors such as iron which play major roles in synthesis of haemoglobin (Alada, 2000; Tindal, 1965). This could explain the increase in haemoglobin seen in animals that were fed GASD. Lipid peroxidation which was used to assess the antioxidant capacity of the rats was reduced significantly ( $p < 0.05$ ) in the animals fed GASD. The reduction in lipid peroxidation could be attributed to the presence of antioxidant phytochemicals including flavonoids and anthocyanidins in the *Gnetum africanum* whose phenolic structure favor their reaction with free radicals and Reactive Oxygen Species (ROS). This reaction with ROS protects the lipids from peroxidation and by extension prevents damage to cells. The reduction of lipid peroxidation by flavonoids prevents DNA damage, a critical event in most diseases (Cai *et al.*, 1997). The increase in SOD in animals fed GASD depicts a high generation of ROS by its constituents which may directly or indirectly increase oxidant stress in the animals. Superoxide dismutase (SOD) is a widespread enzyme that protects cells against the deleterious effects of ROS especially the superoxide radical (Petkau *et al.*, 1975). SOD is crucial to limiting ROS formation and controlling lipid peroxidation by dismutation of superoxide radical. The increased activity of SOD may have contributed to the decreased lipid peroxidation seen in animals fed GASD. Glutathione-s-transferase (GST) was significantly increased in animals fed GASD which is ascribed to flavonoid and anthocyanidins present in most plant foods including *Gnetum africanum* (Ross and Kasum, 2002). Increase in GST activity translates to an increased capacity to conjugate and excrete toxic intermediates that can cause diseases, which is critical in the concept of disease prevention (Pantuck *et al.*, 1984). Consumption of GASD did not significantly change any of the liver enzymes including AST, ALT and ALP. This result showed that consumption of leaves of *G. africanum* does not have any apparent toxicity on the liver of rats. Green leafy vegetables are usually associated with hepatoprotective properties (Oboh, 2005; Roy *et al.*, 2006). Further biological effects of consumption of *G. africanum*-supplemented diet (GASD) were reflected in the histological changes in some of the tissues of the animals. The elongation of the hepatocytes and enlargement of portal tracts showed that the liver of the animals fed GASD was actively involved in metabolism of the constituents of *G. africanum*. GASD also caused enlargement and dilation of the intestinal submucosal cells indicating that most of its constituents were highly absorbed in the guts of the rats. This corroborates with the increase in body weight recorded in the animals fed with GASD. This study underlies the importance of *Gnetum africanum* in the nutrition and health of its consumers and hence recent efforts aimed at increased production and domestication of the plant (Augustine and D'Souza, 1997).

## REFERENCES

- Alada, A.R.A., 2000. The haematological effect of *Telfairia occidentalis* diet preparation. Afr. J. Biomed. Res., 3: 185-186.
- AOAC, 1975. Official Methods of Analysis. 12th Edn., Association of Official Agriculture Chemists, Washington, DC, ISBN: 0935584242, pp: 811-817.
- Augustine, A.C. and L. D'Souza, 1997. Somatic embryogenesis in *Gnetum ula* Brongn. (*Gnetum edule*) (Willd) Blume. Plant Cell Report, 16: 354-357.
- Bouic, P.J., A. Clark, J. Lamprecht, M. Freestone and E.J. Pool *et al.*, 1999. The effects of B-sitosterol (BSS) and B-sitosterol glucoside (BSSG) mixture on selected immune parameters of marathon runners: Inhibition of post marathon immune suppression and inflammation. Int. J. Sports Med., 20: 258-262.
- Burkill, H.M., 1994. The Useful Plants of West Tropical Africa. 2nd Edn., Royal Botanic Gardens, Kew, ISBN: 0947643567.

- Busson, F., 1965. Plantes alimentaires de l'Ouest Africain: Etude botanique, biologique et chimique. Marseille: Ministère de la Coopération. [http://database.prota.org/PROTAhtml/Cleome%20rutidosperma\\_En.htm](http://database.prota.org/PROTAhtml/Cleome%20rutidosperma_En.htm).
- Cai, Q., R.O. Rahan and R. Zang, 1997. Dietary flavonoids, quercetin, luteolin and genistein, reduce DNA damage and lipid peroxidation and quench free radicals. *Cancer Lett.*, 119: 99-108.
- Dacie, J.V. and S.M. Lewis, 1990. *Practical Haematology*. 7th Edn., Churchill Livingstone, London, ISBN: 0443039526.
- Davidson, S., R. Passmore, J.F. Brock and A.S. Truswell, 1975. *Human Nutrition and Dietetics*. 6th Edn., Churchill Livingstone, Edinburgh, ISBN: 0443012466 pp: 1-756.
- Disbrey, B.D. and J.H. Rack, 1970. *Histological Laboratory Methods*. Livingstone, Edinburgh, ISBN: 0443006946, pp: 56-128.
- Drury, R.A.B. and E.A. Wallington, 1967. *Carletons Histological Technique*. 4th Edn., Oxford University Press, London, pp: 120-123.
- Duthie S.J., A. Ma, M.A. Ross and A.R. Collins, 1996. Antioxidant supplementation decreases oxidative DNA damage in human lymphocytes. *Cancer Res.*, 56: 1291-1295.
- Ejiofor, M.A.N., O.R. Obiajulu and J.C. Okafor, 1988. Diversifying utilities of African breadfruit (*Treculia africana Decne. subsp africana*) as food and feed. *Int. Tree Crops J.*, 5: 125-134.
- Fasuyi, A.O., 2006. Nutritional potentials of some tropical vegetable leaf meals: Chemical characterization and functional properties. *Afr. J. Biotechnol.*, 5: 49-53.
- Fokou, E. and F. Domngang, 1989. *In vivo* assessment of the nutritive value of proteins *in situ* in the leaves of *Solanum nigrum* L., *Xanthosoma* spp. and *Gnetum africanum* L. *Indian J. Nutr. Dietetics*, 26: 366-373.
- Formica, J.V. and W. Regelson, 1995. Review of the biology of quercetin and related bioflavonoids. *Food Chem. Toxicol.*, 33: 1061-1080.
- Habig, W.H., M.J. Pabst and W.B. Jakoby, 1974. Glutathione S-transferases: The first enzymatic step in mercapturic acid formation. *J. Biol. Chem.*, 249: 7130-7139.
- Hassel, C.A., 1998. Animal models: New cholesterol raising and lowering nutrients. *Curr. Opin. Lipidol.*, 9: 7-10.
- Isong, E.U., S.A.R. Adewusi, E.U. Nkanga, E.E. Umoh and E.E. Offiong, 1999. Nutritional and Phytochemical Studies of Three Varieties of *Gnetum africanum* (Afang). *Food Chem.*, 64: 489-493.
- Iweala, E.J. and O. Obidoa, 2009. Some biochemical, haematological and histological responses to a long term consumption of *Telfairia occidentalis*-supplemented diet in rats. *Pak. J. Nutr.*, 8: 1199-1203.
- Iwu, M.M., 1986. *Empirical Investigation of Dietary Plants Used in Igbo Ethnomedicine*. Nina Etkined Redgroove Publishing Co., New York, pp: 131-150.
- Jewett, S.L. and A.M. Rocklin, 1993. Variation of one unit of activity with oxidation rate of organic substrate in indirect superoxide dismutase assays. *Anal. Biochem.*, 212: 555-559.
- Kubena, K.S. and D.N. McMurray, 1996. Nutrition and the immune system: a review of the nutrient-nutrient interactions. *J. Am. Diet Assoc.*, 96: 1156-64.
- Lowry, O.H., N.J. Rosebrough, A.L. Farr and R.J. Randall, 1951. Protein measurement with the folin phenol reagent. *J. Biol. Chem.*, 193: 265-275.
- Mialoundama, F., 1993. Nutritional and Socio-Economic Value of *Gnetum* Leaves in Central African Forest. In: *Tropical Forests, People and Food: Biocultural Interactions and Applications to Development*, Hladik, C.M. (Ed.). Parthenon Publishing Group, Carnforth, United Kingdom, ISBN: 1850703809.



- Oboh, G., 2005. Hepatoprotective property of ethanolic and aqueous extracts of *Telfairia occidentalis* (Fluted Pumpkin) leaves against garlic-induced oxidative stress. *J. Med. Food*, 8: 560-563.
- Odebiyi, O.O. and E.A. Sofowora, 1978. Phytochemical screening of Nigerian medicinal plants II. *Lloydia*, 41: 234-246.
- Okafor, J.C., 1980. Edible indigenous woody plants in the rural economy of the Nigeria forest zone. *For. Ecol. Manage.*, 3: 45-55.
- Ouabonzi, A., M.L. Bouillant and J. Hapin, 1983. C-Glycosylflvones from *Gnetum buchholzianum* and *Gnetum africanum*. *Phytochemistry*, 22: 2632-2633.
- Pantuck, E.J., C.B. Pantuck, K.E. Anderson, L.W. Wattenberg, A.H. Conney and A. Kappas, 1984. Effect of Brussels sprouts and cabbage on drug conjugation. *Clin. Pharmacol. Therapy*, 35: 161-169.
- Petkau, A., W. Chelack, S. Pleskach, B. Meeker and C. Brady, 1975. Radioprotection of mice by superoxide dismutase. *Biochem. Biophys. Res. Commun.*, 65: 886-886.
- Reitman, S. and S. Frankel, 1957. Determination of *Aspartate* amino transferase activity in blood serum and tissues. *Am. J. Clin. Pathol.*, 25: 56-56.
- Ross, J.A. and C.M. Kasum, 2002. Dietary flavonoids: Bioavailability, metabolic effects and safety. *Annu. Rev. Nutr.*, 22: 19-34.
- Roy, C.K., J.V. Kamath and M. Asad, 2006. Hepatoprotective activity of *Psidium guajava* Linn leaf extract. *Ind. J. Exp. Biol.*, 44: 305-311.
- Searcy, P.I. and L.M. Bergquist, 1960. A new color reaction for the quantatiation of serum cholesterol. *Clin. Chem. Acta*, 5: 192-199.
- Tindal, H.D., 1965. *Friuts and Vegetables of West Africa*. 1st Edn., Food and Agriculture Organization, USA.
- Wallin, B., B. Rosengren, H.G. Shertzer and G. Camejo, 1993. Lipoprotein oxidation and measurement of thiobarbituric acid reacting substances formation in a single microtiter plate: Its use for evaluation of antioxidants. *Anal. Biochem.*, 208: 10-15.
- Watt, J.M. and M.G. Breyer-Brandwijk, 1962. *The Medicinal and Poisonous Plants of Southern and Eastern Africa*. 2nd Edn., Liningstone Ltd., London.