



International Journal of
Cancer Research

ISSN 1811-9727



Academic
Journals Inc.

www.academicjournals.com

Differential Expression of uPA in Chronic Hepatitis B and C, Liver Cirrhosis and Hepatocellular Carcinoma: Comparison with Normal Liver Tissues and Liver Metastatic Tumors

^{1,2}Sepideh Arbabi Bidgoli, ³Mansour Djamali Zaverhei,
⁴Mohamadali Mohagheghi, ¹Bahar Yazdanmehr, ^{3,4}Isa Jahanzad,
⁵Nasser Ebrahimi Daryani and ³Farid Azmoodeh Ardalan
¹Pharmaceutical Sciences Unit, Islamic Azad University, Tehran, Iran
²Pharmaceutical Sciences Research Center, Tehran University of Medical Sciences,
³Department of Pathology, Faculty of Medicine, Tehran University of Medical Sciences,
⁴Cancer Research Center of Cancer Institute, Imam Khomeini Medical Center,
⁵Department of Gastroenterology, Faculty of Medicine,
Tehran University of Medical Sciences, Tehran, Iran

Abstract: The present study investigated the tissue expression of Urokinase-type plasminogen activator in chronic viral hepatitis B; C, liver cirrhosis and Hepatocellular Carcinoma with viral hepatitis background and compare them with normal liver tissues and with liver metastatic tumors as two control groups without viral hepatitis history. Tissue samples of 11 Hepatocellular Carcinoma, 5 chronic hepatitis B, 17 chronic hepatitis C, 17 liver metastatic tumor, 9 liver cirrhosis and 10 normal tissues were selected retrospectively from 2000 to 2004. The samples were analyzed immunohistochemically using primary antibody (Clone 7-18 labvision corporation, USA). Except Hepatocellular Carcinoma cases, Urokinase-type plasminogen activator expression were observed in all normal adjacent tissues without hepatic background, 50% of normal tissues with viral hepatitis background, 40% of chronic hepatitis B cases, 35.3% of chronic hepatitis C cases, 66.6% of liver cirrhosis and 29.4% of liver metastatic tumors. Significant differences were observed in Urokinase-type plasminogen activator expression profile among studied groups ($p = 0.05$). A significant association between sex of patients and hepatic cirrhosis were observed ($p = 0.013$) which was confirmed in a larger group of cirrhotic cases without history of viral hepatitis ($p = 0.019$). A possible protective role of Urokinase-type plasminogen activator in viral liver diseases predisposing for Hepatocellular Carcinoma is suggestive. We also suggest a possible effect of sex hormones on Urokinase-type plasminogen activator expression in hepatic cirrhosis, which should be confirmed by further studies.

Key words: uPA, Liver, chronic hepatitis, cirrhosis, HCC, liver metastatic tumors, IHC

Introduction

Hepatocellular carcinoma is among the most lethal and prevalent cancers in the human population. Despite its significance, there is only an elemental understanding of the molecular, cellular and environmental mechanisms that drive disease pathogenesis and there are only limited therapeutic options, many with negligible clinical benefit (Farazi and DePinho, 2006).

Persistent HBV and HCV are two common global infections which are strongly associated with liver cirrhosis and human Hepatocellular Carcinoma (HCC), but the underlying pathogenic pathways is not well understood (Darius and Blum, 2005). Urokinase-type plasminogen activator (uPA) is a

Corresponding Author: Sepideh Arbabi Bidgoli, Pharmaceutical Sciences Unit, Islamic Azad University, No. 155, Forsat Shirazi St., North Eskandari, Azadi St., Tehran, Postal Code 1419794911, Iran
Tel: +98-21-66592224 Fax: +98-21-66438731

serine protease that converts plasminogen into the active proteinase, plasmin and is implicated in direct or indirect degradation of matrix proteins (Herszenyi, 2000). Hepatic uPA activity increases in the early stage of liver regeneration as a result of an increased expression of its cell surface-binding protein, uPA receptor (uPAR), in hepatocytes (Akao *et al.*, 2002). On the other hand, in the later phase of liver regeneration, plasmin releases latent TGF- β from the matrices and proteolytically activates it, resulting in the growth suppression of hepatocytes (Andreasen *et al.*, 1997). Thus, the uPA/plasmin system exerts bipolar effects on growth of hepatocytes as well as degradation of the extracellular matrix in the early and late phases of hepatic regeneration (De Petro *et al.*, 1998; Chan *et al.*, 2004). uPA overexpression has been reported previously in carcinogen-induced hepatocarcinogenesis in experimental models (Nieto-Rodriguez *et al.*, 2001) but its involvement in viral chronic hepatitis and liver cirrhosis leading to hepatic induced cirrhosis and tumor aggressiveness has not been still determined. We have decided to investigate the expression of uPA in chronic viral hepatitis B, C, liver cirrhosis and HCC with viral hepatitis background and compare them with normal liver tissues and with liver metastatic tumors as two independent control groups. We compared also uPA expression in these precancerous lesions and its clinicopathological significance in each of mentioned liver diseases.

Materials and Methods

Patients

Based on the archival files of the Department of Pathology, Imam Khomeini University hospital, the questionnaires of 69 previously characterized patients were selected in a retrospective fashion from 2000 to 2004. In all, 11 hepatocellular carcinoma, 5 chronic hepatitis B, 17 chronic hepatitis C, 17 liver metastatic tumor as well as their normal adjacent tissues and 9 liver cirrhosis tissue samples were used in this study. In addition to mentioned tissues, corresponding normal liver tissues of 10 chronic hepatitis cases were obtained as controls. Based on designed questionnaires, data were collected using available brief information in the patient's documents. Accessible data was their age at diagnosis, sex, clinical and pathological diagnosis, date of disease initiation, history of addiction, history of blood transfusion and the level of serological markers e.g., ALT, AST and ALP. The accessible data about HBS Ag, HBS Ab, HBV DNA, HBe Ag and HBe Ab were also recorded. According to the registered documents, sera from patients with liver metastases were negative for both HBsAg and HCV. Sera from patients with chronic hepatitis B were positive for HBsAg, Sera from patients with chronic hepatitis C were positive for HCV and all patients with HCC and cirrhosis had confirmed history of HBsAg or HCV or both. Liver biopsy specimens from alcoholic steato-hepatitis patients, autoimmune hepatitis, metabolic hepatic diseases and hepatic cholestasis were excluded from present study. Tissue specimens were confirmed by pathological examinations before starting IHC studies.

Histological Evaluation

Percutaneous liver biopsy was performed in most of the patients other cases underwent total or partial hepatectomy during the years 2000-2004 in Gastroenterology Department of Imam Khomeini University Hospital of Tehran University of Medical Sciences (TUMS). Each biopsy or surgical specimen of chronic hepatitis was evaluated by modified HAI grading and the staging for liver fibrosis and architectural disturbances was performed using a scale of 0-6 (modified staging) (Rosai, 2004). All biopsy specimens were evaluated for presence of hepatic necrosis and fibrosis.

Immunohistochemical Analysis

Immunoperoxidase staining was performed on formalin-fixed, paraffin-embedded tissues cut at 4 μ m and placed on positively charged slides. Tissues were deparaffinized and rehydrated as described before (Arbabi *et al.*, 2005). Following the Tris rinse, antigen retrieval was accomplished by heating

the slides in a 10 mmol L⁻¹ citric acid buffer in a microwave oven for 30 min. The slides were cooled for 20 min before being rinsed in Tris. Following the blocking step, the slides were incubated with Optimal dilutions of primary antibodies (Urokinase-type Plasminogen Activator, Ab-2, Clone 7-18, labvision corporation, USA) at 1:50 dilution for 30 min at room temperature. The results were visualized using the Streptavidine-biotin immunoperoxidase detection kit (LSAB2; Dakocytomation-Denmark) and DAB chromogen (Dakocytomation-Denmark) based on the manufacturer's instruction with necessary modifications. Sections were also counterstained with Meyer's haematoxyline. In each series, a section in which incubation with the primary antibody was omitted used as negative control. As a positive control, a breast adenocarcinoma sample known to positively stain for uPA antibody was included in each staining run. Staining was considered negative only after careful examination of the entire tissue section. Quantization of the intensity and number of positive cells was performed by an independent pathologist (M.D.) blinded to the clinical outcome.

Scoring Method

Liver samples were classified into four categories based on the cytoplasmic expression of uPA. Stained cells were scored as 3+ if they had strong staining (>50%), 2+ if they had moderate staining (25-50%), 1+ if they had mild staining (5-25%) and 0 if staining was <5% or no staining.

Statistical Analysis

Values were expressed as frequency rates or as the mean±standard deviation (SD). For two variable non-parametric Mann-Whitney test and for more than two variables Kruskal Wallis H test was used (Rober and Clarke, 2002). Probability values of <0.05 were considered significant. Statistical analysis was performed with SPSS 10 statistical software. This study was approved by the Ethical Committee of Tehran University of Medical Sciences (TUMS).

Results

In an attempt to investigate whether uPA associate with HCC preclinical lesions, we analyzed the expression of uPA in chronic hepatitis B, C, Liver cirrhosis, HCC and compared each with normal liver and liver metastatic tumors.

uPA Expression in Control Group

Corresponding adjacent tissues of liver metastatic group who had no history of hepatitis were considered as control group. Strong cytoplasmic expression of uPA was observed diffusely in all normal parts of the tissue sections (Fig. 1a).

Corresponding normal tissues of 10 independent chronic hepatitis were obtained also as another control group. The clinicopathological feature of 10 normal cases is showed in Table 1. All of the cases had history of chronic hepatitis B, C or both. Out of 10 normal liver tissues, hepatocytes of 50% of cases were stained with uPA monoclonal antibody. Although the strong expression of uPA was not observed in control cases but mild and moderate staining was found in, two and three cases respectively (Fig. 1b).

uPA expression in Chronic Hepatitis B

Tissue specimens of five chronic hepatitis B were obtained for uPA expression study. The clinicopathological features of mentioned patients are explained in Table 1.

Out of five chronic hepatitis B cases, uPA cytoplasmic expression was found in the hepatocytes of two cases (Fig. 1c).

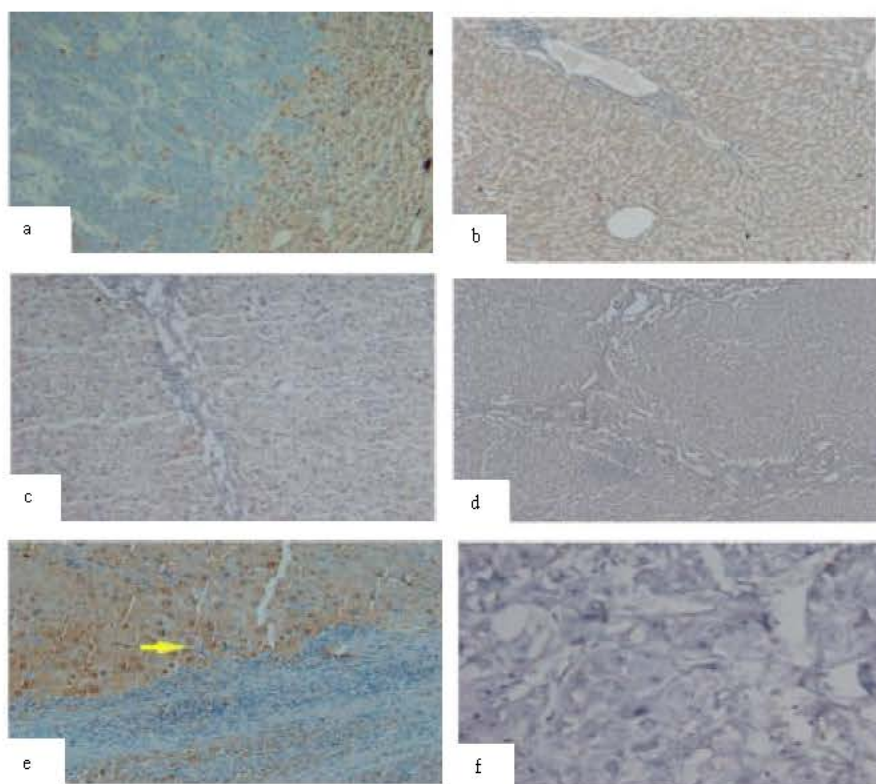


Fig. 1: a) Cytoplasmic uPA expression of adjacent normal tissue of liver metastatic tumor (20x), b) Moderate cytoplasmic expression of uPA in normal liver tissue (20x), c) Mild cytoplasmic expression of uPA in hepatitis B case (20x), d) Mild cytoplasmic expression of uPA in hepatitis C case (10x), e) Strong uPA expression in interface and cirrhotic regions of cirrhotic case with chronic hepatitis C background (20x) and f) Negative expression of uPA in a HCC case (40x)

uPA expression in Chronic Hepatitis C

Tissue specimens of 17 chronic hepatitis C were obtained for uPA expression study. The clinicopathological features of mentioned patients are explained in Table 1.

Out of 17 chronic hepatitis B cases, uPA cytoplasmic expression was found in the hepatocytes of six cases (Fig. 1d). Out of six cases with positive cytoplasmic expression of uPA only one case was found with uPA moderate staining and other cases had mild staining profiles.

uPA Expression in Liver Cirrhosis

Tissue specimens of nine liver cirrhosis cases with chronic hepatitis backgrounds were obtained for uPA expression study. The clinicopathological features of mentioned patients are explained in Table 1.

Out of nine chronic hepatitis B cases, uPA cytoplasmic expression was found in the hepatocytes of 6 (66.6%) of cases (Fig. 1e).

Table 1: Clinicopathological features of six groups of patients

Variables	Control group N = 10	Chronic HBV N = 5	Chronic HCV N = 17	Cirrhotic cases N = 9	HCC N = 11	Liver metastatic tumors N = 17
Age	34.4 year±10.13 (range: 20-53)	27.6 year±5.2 (range: 22-36)	32.8 year±14.7 (range: 15-62)	42.11 year±11.9 (range: 25-62)	59.4 year±13.3 (range 39-79)	50.27 year±15.7 (range 21-74)
Sex						
Male	8(80%)	5(100%)	13(76.5%)	7(77.8%)	4(44.4%)	11(64.7%)
Female	2(20%)		4(23.5%)	2(22.2%)	5(55.6%)	6(35.3%)
Presence of Chronic Hepatitis						
Positive(+)	10(100%)	5(100%)	17(100%)	9(100%)	11(100%)	0
Negative(-)	0	0	0	0	0	17(100%)
Liver disease initiation (mean±SD)	7.2±6.6 (range 0-20)	5.5 year±4.5 (range 0-15)	2.67±2.05 (range 0-15)	8.1 month±0.76 (range 0-2 year)	12±7.5 (range 1-20)	No data
History of Addiction						
Positive(+)	2(20%)	1(20%)	10(58.8%)	3(33.3%)		
Negative(-)	8(80%)	4(80%)	7(41.2%)	6(66.7%)		
History of Blood Transfusion						
Positive(+)	4(40%)	5(100%)	12(70.6%)	6(66.7%)		
Negative(-)	6(60%)	0	5(29.4%)	3(33.3%)		
Hepatic Necrosis						
Positive(+)	3(30%)	4(80%)	12(70.6%)	6(66.7%)		
Negative(-)	7(70%)	1(20%)	5(29.4%)	3(33.3%)		
Hepatic Fibrosis						
Positive(+)	0	1(20%)	7(41.2%)	9(100%)		
Negative(-)	10(100%)	4(80%)	10(58.8%)	0		
HBSAg						
Positive(+)	6(60%)	5(100%)	0	4(44.4%)		
Negative(-)	4(40%)	0	17(100%)	5(55.6%)		
HBV DNA						
Positive(+)	6(60%)	5(100%)	0	6(66.7%)		
Negative(-)	4(40%)	0	17(100%)	3(33.3%)		
HBC Ag						
Positive(+)	6(60%)	0	17(100%)	5(55.6%)		
Negative(-)	4(40%)	5(100%)	0	4(44.4%)		
ALT	81.25±51.9 (range 12-160)	370.5±43.9 (range 60-681)	152±18.3	26.07±22.8 (range 21-681)	(range 3.5-62)	
AST	60.62±48.87 (range 20-160)	434.5±57.4 (range 28-841)	153±23.1	37.9±33.04 (range 27-841)	(range 8-105)	

uPA Expression in HCC

Tissue specimens of 11 moderately differentiated HCC cases with chronic hepatitis backgrounds were obtained for uPA expression study. Out of 11 HCC cases, chronic background hepatitis was the common feature of them and four cases (36.4%) had hepatic cirrhosis background. The clinicopathological features of mentioned patients are showed in Table 1. Considering to the hepatitis background of the HCC cases and despite of repeating the IHC analysis with different technical optimization no uPA expression was observed in present HCC cases (Fig. 1f).

uPA Expression in Liver Metastatic Tumors

Tissue samples of 17 well-differentiated liver metastases from GI cancers were evaluated for the presence of uPA marker. Out of 17 cases, 5 (29.4%) showed uPA mild cytoplasmic staining.

Comparison of uPA Expression Pattern Between Different Liver Diseases

The presence and the expression levels of uPA were compared among all six liver diagnostic groups. Based on Kruskal Wallis H test significant difference was observed among all of 6 groups (p = 0.051).

Table 2 shows uPA Scores in different liver diseases. Each uPA score in each liver disease was compared with uPA score in normal tissue (column P¹), liver cirrhosis (column P²), HCC (column P³) and liver metastatic tumors (column P⁴).

Table 2: Comparison of uPA scores in different liver diseases

Diagnosis	No.	Negative	1(+)	2(+)	3(+)	P ¹	P ²	P ³	P ⁴
Normal liver	10	5(50%)	2(20%)	3(30%)	0				
Chronic hepatitis B	5	3(60%)	1(20%)	1(20%)	0	NS	NS	0.03*	NS
Chronic hepatitis C	17	11(64.7%)	5(29.4%)	1(5.9%)	0	NS	MS	0.03*	NS
Hepatic cirrhosis	9	3(33.3%)	6(66.6%)	0	0	NS	NS	0.002**	NS
HCC	11	11(100%)	0	0	0	NS	NS	0.002**	0.051*
Liver metastatic tumors	17	12(70.6%)	5(29.4%)	0	0	NS	NS	0.051*	

¹: Compared with Normal Liver, ²: Compared with Liver Cirrhosis, ³: Compared with HCC, ⁴: Compared with metastatic tumors, *0.005<p<0.05, **0.0005<p<0.005

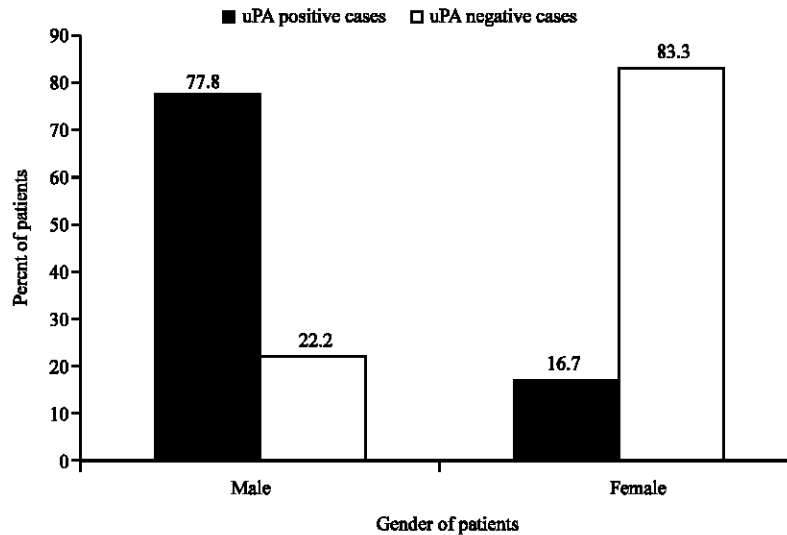


Fig. 2: Association between gender and uPA expression in hepatic cirrhosis patients with history of chronic viral hepatitis

Clinicopathological Significance of uPA in Normal Liver Tissues

Relatively significant association was observed between uPA expression and age of patients in normal cases ($p = 0.075$).

Clinicopathological Significance of uPA in Chronic Hepatitis B and C Cases

No significant association was observed between uPA expression and clinicopathological features of patients.

Clinicopathological Significance of uPA in Hepatic Cirrhosis Cases

Significant association was observed between uPA expression and sex of hepatic cirrhosis cases ($p = 0.03$). This significant association was confirmed by Spearman's Correlation test ($p = 0.013$). The same result were observed when we evaluated uPA expression in a larger group (15 patients) of cirrhotic cases. That means out of six female cirrhotic cases 1 case (16%) showed uPA expression and five (83.3%) had no uPA expression. Additionally out of nine male cirrhotic cases 7(77.8%) showed uPA expression and two cases (22.2%) had uPA negative expression (Fig. 2). In this larger group, six cases had no viral hepatitis background but there was also no association between uPA expression and viral hepatitis background in evaluated liver cirrhosis cases.

Clinicopathological Significance of uPA in HCC Cases

Nuclear or cytoplasmic expression of uPA were not observed in all of HCC cases.

Clinicopathological Significance of uPA in Liver Metastatic Tumors

No significant association was observed between uPA expression and clinicopathological features of all 17 liver metastatic cases.

Discussion

Previous studies showed uPA diverse functions from the beginning of the carcinogen-induced hepatocarcinogenetic process (Akao *et al.*, 2002; Andreasen *et al.*, 1997; De Petro *et al.*, 1998) but its functions in HBV and HCV induced hepatocarcinogenesis is not well understood. It is also suggested that uPA could be involved in a wider range of mechanisms, including tissue remodelling, angiogenesis, wound healing and it is suggested to consider it as a protective factor in GI ulcers (Herszenyi *et al.*, 2000) but its protective effects in liver diseases especially in viral liver background diseases known to be predisposing for HCC is not determined.

Due to clinical values of uPA in hepatocarcinogenesis, tissue remodeling and its antifibrotic potencies on hepatic fibrosis (Lin *et al.*, 2005), a comprehensive study on the clinical significance of uPA in viral chronic hepatitis B and C, hepatitis induced liver cirrhosis and hepatitis induced HCC were done for the first time in this population, which was compared with normal and liver metastatic tumors.

Considering the significant differences between uPA expression in each hepatitis B, C, cirrhosis and liver metastatic tumors as well as uPA negative expression in HCC cases (Table 2) a possible protective role of uPA in viral liver diseases predisposing for HCC is suggestive.

HCC is a typical hypervascular tumor and uPA overexpression is reported in previous studies (De Petro *et al.*, 1998; Chan *et al.*, 2004). There is a wide difference with our results and previous studies which may be related to geographical factors, due to technical differences, sensitivity rates of various molecular techniques used, or the clone of primary antibodies but we want also to suggest the possible role of HBV and HCV in this area because all of our HCC cases had viral hepatitis background and this is the main difference between this study and previous studies. One study reported, uPA as a biomarker for aggressive HCC (Lin *et al.*, 2005). It seems important to confirm this role as a biomarker in HCC cases with viral hepatitis and also this unexpected finding by studying the direct effect of viral hepatitis B or C proteins like HBX on uPA expression profile in HCC cases with confirmed hepatitis background.

According to present results uPA expression were detected in 66.6% of cirrhotic cases and showed significant difference with HCC cases. Previous studies suggests that expression of uPA in cirrhotic livers led to resolution of fibrosis and regeneration of functional hepatocytes and multiple mechanisms were suggested for the induction of hepatocyte proliferation by uPA (Chan *et al.*, 2004; Funakoshi and Nakamura, 2003). This significant difference between mentioned cirrhotic and HCC cases may confirm this hypothesis. As uPA expression led to induction of collagenase expression and reversal of fibrosis with concomitant hepatocyte and improved liver function thus, we think that uPA gene therapy may be an effective strategy for treating cirrhosis and prevention of HCC, which is suggested previously (Salgado *et al.*, 2000; Lin *et al.*, 2005).

The present study reported a significant association between uPA expression and gender of patients in hepatic cirrhosis cases (Fig. 2). Although this is the first report about this association but suggests a possible role of sex-steroid hormones on uPA expression in liver cirrhosis. Although the possible effects of steroid receptors on the expression of uPA and clinical outcome could be concluded from this preliminary *in vivo* study but the evaluation of the coexpression of uPA and steroid receptors is also recommended.

Finally considering the key role of uPA expression in viral liver diseases known to be predisposing for HCC, it could be concluded that groups of patients with uPA negative expression would less likely benefit from collagenase expression and reversal of fibrosis with concomitant

hepatocyte and improved liver function. This result could be confirmed by the lack of uPA expression in present HCC cases who may have poor prognosis in comparison to other evaluated groups. Therefore, it is highly recommended to determine the prognostic and predictive roles of uPA in HCC predisposing conditions, to find more reliable therapeutic targets for this life threatening cancer.

Acknowledgments

This research has been financially supported by Pharmaceutical Sciences Research Center (PSRS), Tehran University of Medical Sciences (TUMS) and Cancer Research Center of the Cancer Institute (CRCI), Imam Khomeini Medical Center.

References

- Akao, M., Y. Hasebe, N. Okumura, H. Hagiwara, T. Seki and Toyohiko, 2002. Plasminogen activator-plasmin system potentiates the proliferation of hepatocytes in primary culture. *Thromb. Res.*, 107: 169-174.
- Andreasen, P.A., L. Kjoller, L. Christensen and M.J. Duffy, 1997. The urokinase-type plasminogen activator system in cancer metastasis: A review. *Int. J. Cancer*, 72: 1-22.
- Arbabi, B.S., B. Minaee, M. Djamali Zavarhei, S. Fouladdel and E. Azizi, 2006. P-glycoprotein and Topoisomerase II alpha expression in advanced gastric cancer patients: Association with clinicopathological findings. *IJP*, 3: 280-285.
- Chan, C.F., T.O. Yau, D.Y. Jin, C.M. Wong, S.T. Fan and I.O. Ng, 2004. Evaluation of nuclear factor-kappa B, urokinase-type plasminogen activator and HBx and their clinicopathological significance in hepatocellular carcinoma. *Clin. Cancer Res.*, 10: 4140-4149.
- Darius, M. and H.E. Blum and E. Hubert, 2005. Pathogenesis of hepatocellular carcinoma. *Eur. J. Gastroenterol. Hepatol.*, 17: 477-483.
- De Petro, G., D. Tavian, A. Copeta, N. Portolani, S.M. Giulini and S. Barlati, 1998. Expression of urokinase-type plasminogen activator (u-PA), u-PA receptor and tissue-type PA messenger RNAs in human hepatocellular carcinoma. *Cancer Res.*, 58: 2234-2239.
- Farazi, P.A. and R.A. DePinho, 2006. Hepatocellular carcinoma pathogenesis: From genes to environment. *Nat. Rev. Cancer*, 6: 674-687.
- Funakoshi, H. and T. Nakamura, 2003. Hepatocyte growth factor: From diagnosis to clinical applications. *Clin. Chim. Acta*, 327: 1-23.
- Herszenyi, L., M. Plebani, P. Carraro, M. De Paoli, G. Roveroni and R. Cardin *et al.*, 2000. Proteases in gastrointestinal neoplastic diseases. *Clin. Chim. Acta*, 291: 171-187.
- Lin, Y., X.F. Xie, Y.X. Chen, X. Zhang, X. Zeng and H. Qiang *et al.*, 2005. Treatment of experimental hepatic fibrosis by combinational delivery of urokinase-type plasminogen activator and hepatocyte growth factor genes. *Liver Int.*, 25: 796-803.
- Nieto-Rodri' Guez, A.A., R.B. He'mandez-Pando, A.D. Kershenobich and C.L. Rodr Guez-Fragoso, 2001. Expression of urokinase-type plasminogen activator in an experimental model of hepatocarcinoma. *Toxicology*, 161: 13-23.
- Rober, F.W. and W.R. Clarke, 2002. *Statistical Methods for the Analysis of Biomedical Data*. 2nd Edn., Wiley Intersciences, 2002.
- Rosai, J., 2004. *Rosai and Ackerman's Surgical Pathology*, 9th Edn., Mosby.
- Salgado, S., J. Garcia, J. Vera, F. Siller, M. Bueno and A. Miranda *et al.*, 2000. Liver cirrhosis is reverted by urokinase-type plasminogen activator gene therapy. *Mol. Ther.*, 6: 545-551.