



International Journal of  
**Zoological  
Research**

ISSN 1811-9778



Academic  
Journals Inc.

[www.academicjournals.com](http://www.academicjournals.com)

## Fatal Aspergillosis in an Ostrich (*Struthio camelus*) Predisposed by Pulmonary Haemangioma in the Kingdom of Saudi Arabia

<sup>1</sup>M.S. Shathele, <sup>1</sup>A. Fadlelmula, <sup>2</sup>F.A. Al-Hizab and <sup>3</sup>M.M. Zaki

<sup>1</sup>Department of Microbiology,

<sup>2</sup>Department of Pathology,

<sup>3</sup>Department of Clinical Studies, King Faisal University, P.O. Box 1757,  
Al-Ahsa 31982, Kingdom of Saudi Arabia

**Abstract:** A laboratory study was carried out to investigate fatal aspergillosis in an ostrich (*Struthio camelus*) predisposed by pulmonary haemangioma in the Kingdom of Saudi Arabia. The examination of Post Mortem (PM) revealed numerous ulcerated (1×0.5 cm) subcutaneous opaque thick masses with turbid materials (exudates) in the cut section together with fibrosis in between air sacs and the thoracic wall. The microscopic appearance indicated the presence of capillary type haemangioma in ostrich. The proliferating cells were highly differentiated, uniform with spindle-shaped nuclei resembling normal vascular endothelia and were arranged in the form of numerous capillaries distended with large amounts of blood erythrocytes and separated by fibrous stroma. However, large vascular spaces lined by a single layer of endothelium were also observed. The superficial parts of the tumour showed hyperkeratosis of the epidermis and diffuse infiltration of lymphocytes in the interstitial areas. In addition, the fibrous stroma was more abundant and dense with more prominent collagen in the peripheral parts of the tumour. On PM, the tiny yellowish white foci were detected on the lung's specimens and yielded *A. fumigatus* in pure culture. The histopathologic examination of the lesions showed fungal hyphae, inflammatory and multinucleate giant cells.

**Key words:** Ostrich, fatal aspergillosis, *A. fumigatus*, pulmonary haemangioma

### INTRODUCTION

Aspergillosis is probably the most common systemic mycoses of birds (Ainsworth and Austwick, 1973; Austwick, 1977; Chute, 1978; Campbell, 1986). Although, aspergillosis was reported in ostriches by the end of the 19th and the beginning of the 20th century (Archibald, 1913; Jowett, 1913), to our best knowledge there are no recent reports of aspergillosis as a flock disease in this bird. *Aspergillus fumigatus* is a common cause of avian aspergillosis in ostrich and was reported from many parts of the world. Generally, it runs an acute course in young birds and inclines to chronicity in mature ones (Ainsworth and Austwick, 1973). Information regarding outbreak of aspergillosis in ostrich is inadequate. *Aspergillus pneumonia* has been described in ostrich (Rousseaux and Dalziel, 1981). *Aspergillus fumigatus* isolates were identified in ostrich by the polymerase chain reaction in five American States (Katz *et al.*, 1996). Yokota *et al.* (2004) reported a fatal *A. fumigatus* infection in an 11 month old female ostrich in Japan.

Ostrich industry of Turkey observed that respiratory mycosis is a problem in young ostriches, particularly when they suffer from debilitating conditions (e.g., malnutrition). At this stage, the immune system can be severely compromised and secondary infections often develop

(Huchzermeyer, 1994). Aspergillosis generally occurs secondary to stress, immuno-suppression, prolonged antibacterial therapy, or overwhelming exposure to the organism (Marks *et al.*, 1994; Fitzgerald and Moisan, 1995). Aspergillosis is notorious for being the major cause of mortality in ostrich farms where the ostrich industry is well developed (Katz *et al.*, 1996). There are major difficulties in the diagnosis and treatment of individual ostriches. There are no reports of successful treatment in ostriches (Huchzermeyer, 1994; Marks *et al.*, 1994). If the bird has been exposed to an improper diet, the eaten material may cause an impaction in the gut. Grit feeding can sometimes cause impactions (Huchzermeyer, 1994; Holle, 2001). Gut impaction is usually a secondary problem as a result of some other initiating problems (Holle, 2001). Sancak and Paracikoglu (2005) isolated aspergillosis from the lungs and air sacs of a 3 month old male, blue-neck ostrich. In postmortem examination, the ingestion of a large amount of gravel was noted. The accumulated gravel had led to an occlusion of the passage between the proventriculus and gizzard. The study appears to be the first report of aspergillosis and gastric impaction developing together and leading to death in an ostrich.

Haemangiomas are localized benign tumours of vascular cells which appear frequently in humans and animals. Mode of induction of such tumours is uncertain. Haemangiomas have been reported in some avian species. Cutaneous haemangiomas in chickens and an outbreak of haemangioma among layers were observed and described by Cerruti *et al.* (1998). Recently, Headley (2005) reported the case of an intrathoracic haemangiosarcoma in an ostrich, while Sledge *et al.* (2006) observed subcutaneous haemangiosarcoma in a cockatiel. Terzich and Vanhooser (1993) observed two aspergillosis and three impaction cases in postmortem examinations of 121 ostriches. Onderka and Doornenbal (1992) isolated *Aspergillus fumigatus* from the lungs and air sacs. However, the presence of fungal hyphae was not observed in histopathological preparations.

Akan *et al.* (2002) reported a case of aspergillosis in a broiler breeder flock having respiratory and nervous system problems caused by *Aspergillus fumigatus* and *Aspergillus niger*. Whereas, dyspnea, hyperpnea, blindness, torticollis, lack of equilibrium and stunting were observed clinically. Perelman and Kuttin (1992) observed a severe case of aspergillosis in a flock of 3 to 8 week old ostriches at a farm in Israel. *A. niger* and *A. flavus* were isolated from the lungs of affected ostriches. A heavy contamination with both fungi was detected in the hatchery, suggesting a brooder borne infection.

## MATERIALS AND METHODS

### Case History

The investigations were carried out at Veterinary Hospital, Agricultural and Veterinary Research Station, King Faisal University, Hofuf Al-Ahsa on a 3 year old female ostrich which gradually started to emaciate with respiratory distress over a period of 10 days during 2006-2007. On arrival, at the laboratory of a Veterinary Teaching Hospital, the bird was dying with gasping and had a difficulty in breathing.

### Microbiological Investigations

The Post Mortem (PM) of the infected bird was carried out and the specimens from respiratory organs were collected in sterile containers for microbiology. The parts of the bird were put in 10% formal saline solution for histopathology. Representative parts were stretched onto blood agar and MacConkey's agar (Oxoid) and incubated at 37°C for bacterial isolation. Sabouraud's agar slants (oxoid) were used to isolate fungi and incubated at 26 and 37°C (Raper and Fennell, 1977). The cultures were examined daily to detect growth.

### Pathogenicity Test

A fungal isolate from the natural infection in ostrich, identified to be *A. fumigatus* was utilized to establish its pathogenicity in fowl chicks. A total of 31 day old chicks were used. They were divided

into three groups with each group of 10 birds. The isolate was sub-cultured on to malt extract agar slants (oxid) and incubated at 26°C for 6 days. A spore suspension was prepared in sterile distilled water and the concentration was adjusted by a counting chamber. The chicks in group 1 were infected via., intranasal route. Each chick was inoculated with  $1.91 \times 10^6$  spores / 0.1 mL. The chick in group 2 were infected by aerosol. The birds were kept in a closed box and spore concentration of  $1.91 \times 10^7$  /10 mL was applied inside the box by aerosol. Whereas, the chicks in group 3 served as a control treatment. Five birds were inoculated intranasally with 0.1 mL sterile distilled water and the remaining five birds were kept in a closed box and 10 mL sterile distilled water was applied by aerosol.

The birds were given water and food at libitation and observed daily for two weeks. After the treatment, the Post Mortem (PM) was done and parts of internal organs were removed for microbiological and histo-pathological investigations.

## RESULTS

The PM examination revealed numerous ulcerated (1x0.5 cm) subcutaneous opaque thick masses with turbid materials (exudates) in the cut section together with fibrosis in between air sacs and the thoracic wall. These masses were also present inside para-bronchi and secondary bronchi left and right. The microscopic appearance indicated the presence capillary type haemangioma in ostrich. The proliferating cells were highly differentiated, uniform with spindle-shaped nuclei resembling normal vascular endothelia. These cells were arranged in the form of numerous capillaries distended with large amounts of blood erythrocytes and separated by fibrous stroma (Fig. 1). The capillaries were almost regular in shape but rather variable in size. However, large vascular spaces lined by a single layer of endothelium were also observed (Fig. 2). The superficial parts of the tumour showed hyperkeratosis of the epidermis and diffuse infiltration of lymphocytes in the interstitial areas (Fig. 3). In addition, the fibrous stroma was more abundant and dense with more prominent collagen in the peripheral parts of the tumour.

### Culture

On Sabouraud's slants, white growth started to appear on the third day at 37°C and then the colour changed to powdery greenish with age. After seven days the growth filled the surface of the

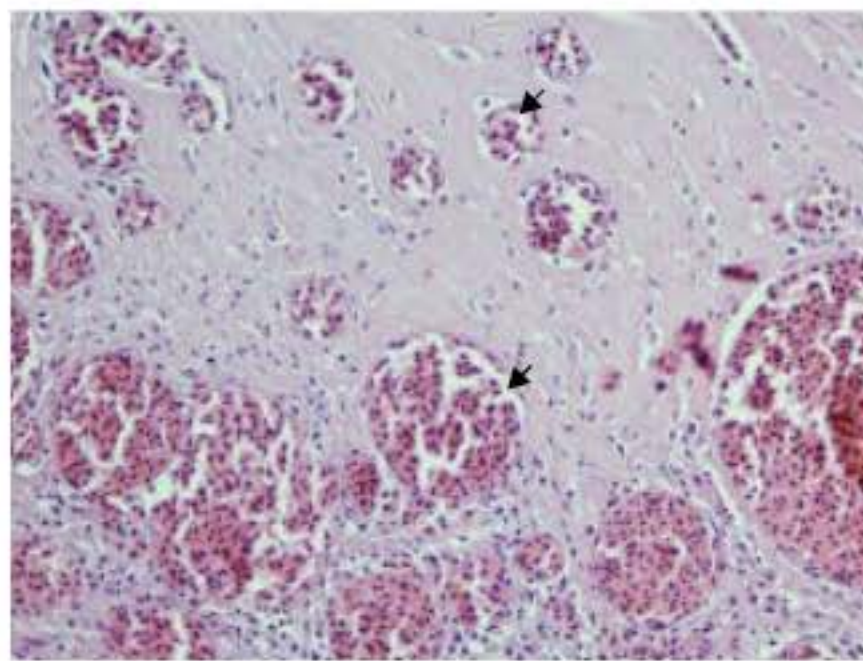


Fig. 1: Lung numerous capillaries distended with large amounts of blood erythrocytes and separated by fibrous stroma. Notice the highly differentiated endothelial-like cells with spindle-shaped nuclei (black arrow head). H and E. x .....

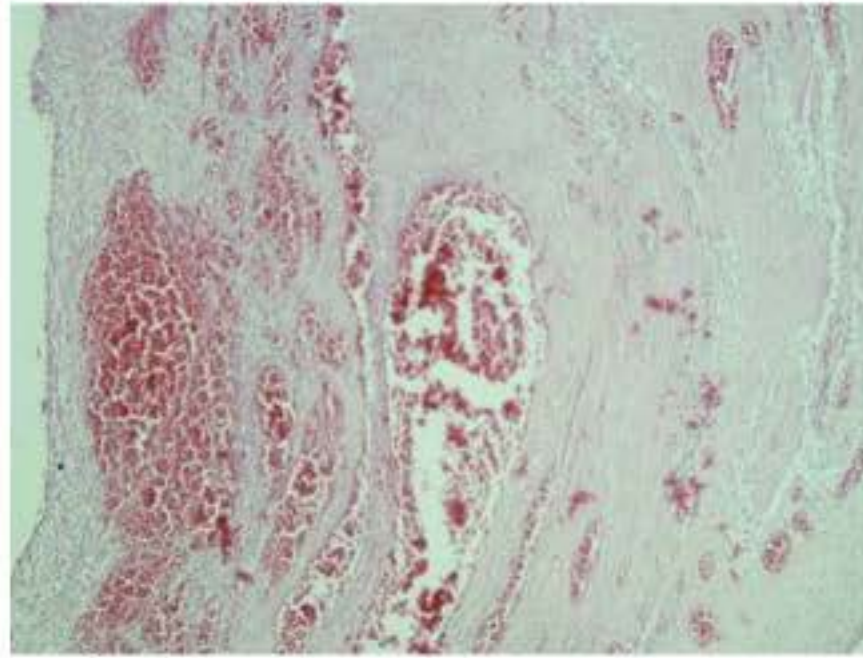


Fig. 2: Slide showing regular-shaped but variable in size capillaries. H and E. x ....

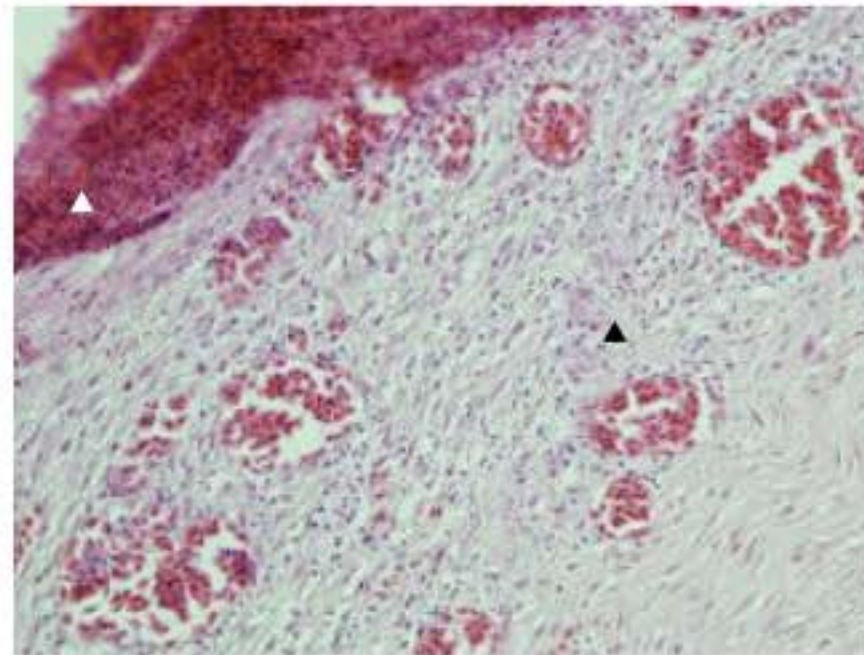


Fig. 3: Lung hyperkeratosis of the epidermis (white arrow head) and diffuse infiltration of lymphocytes (black arrow head) in the interstitial areas. H and E. x

slants. Cultures kept at 26°C showed the same pattern but slower growth. Needle mounts were prepared from the growth and stained with lactophenol cotton-blue. Based on the cultural and microscopic features, the isolate was identified as *A. fumigatus*.

#### Pathogenicity Test

One bird in group 2 died after 18 h of inoculation, but the PM and culture did not suggest the presence of aspergillosis. However, some of the birds in this group started to show signs of respiratory distress. After 3-5 days of inoculation, five birds died in group 2. The PM showed severe congestion in the lungs. All the birds were sacrificed at the end of experimental period. On PM, the tiny yellowish white foci were detected on the lung's specimens and yielded *A. fumigatus* in pure culture. The histopathologic examination of the lesions showed fungal hyphae, inflammatory and multinucleate giant cells.

In group 1, the birds appeared normal clinically till the end of the experimental period. On PM, no significant abnormalities were seen regarding aspergillosis in birds. Out of the total cultured specimens from the respiratory tissues in the control treatment, only one specimen showed signs of *A. fumigatus*, while the others were normal.

## DISCUSSION

A mixed fatal haemangioma and aspergillosis in an ostrich is reported as the first case such affection in the Kingdom of Saudi Arabia. *A. fumigatus* was recovered in pure culture from lesions of the respiratory system. Histopathological examinations indicated capillary type haemangioma in ostrich. The tumor might be a predisposing factor for fungal infection as it is possibly compromised the immune system. This explains the severe course of infection which caused death in ostrich chicks. Whereas, haemangioma in combination with fungal conidia might have resulted in accelerated pulmonary distress and respiratory failure. The histopathological evidence suggests that the tumour induced a sort of chronic inflammatory reaction. For example, it did not elicit multinucleate giant cells which are features of the inflammatory process in *A. fumigatus* infection. The chronic inflammation stressed the respiratory system and exposed it to the fungal burden that shocked the system. Probably, hypersensitivity and toxin release from *A. fumigatus* rather than invasiveness, would explain the severe quick course of the infection that resulted in death. *Aspergillus fumigatus* was reported to secrete many toxic metabolites (Kamei and Watanabe, 2005; Pardo *et al.*, 2006) and hypersensitivity reaction showed in mice challenged by *A. fumigatus* antigen aerosol with lymphocytic infiltration and elevated IgE levels (Müller *et al.*, 2006). Also, it was suggested that *A. fumigatus* could trigger an exaggerated type I hypersensitivity reaction (Slavin *et al.*, 2004). The pathogenicity of the isolate, in the present study, was established in one day old chick. Further, it was shown that the aerosol exposure was superior in establishing pathogenicity to the intranasal route where birds remained refractory to infection.

In a recent study, relatively high concentrations of ergot alkaloids, mycotoxins that adversely affect cardiovascular, nervous, reproductive and immune systems of humans and animals were demonstrated in a respirable form in conidia of *A. fumigatus* (Panaccione and Coyle, 2005). The above stated findings supported present results which demonstrated the lower susceptibility of experimental chicks to intranasal infection route.

Present observations show that aspergillosis can be a severe flock problem in ostriches causing high morbidity and mortality in young chicks. The fact that *A. flavus* and *A. niger* were cultured from all the affected birds and from the hatchery, strongly suggests that this was a brooder borne infection. Most of the cases of aspergillosis in birds are caused by *A. fumigatus* (Campbell, 1986) but the findings in this case indicate that *A. niger* and *A. flavus* can cause a serious disease in ostriches. An interesting point is that, despite the severe gross lesions in the lungs not a single bird showed any clinical sign of respiratory distress. The soft bones observed in the affected birds could be related to the chronic process and anorexia characteristic of a wasting disease. Increasing interest of several countries in the economic potential of the ostrich as a farm animal, makes it necessary to renew and expand the available information regarding different medical problems related to this bird. There exists an excellent potential for future investigations to characterize and differentiate this type of neoplastic cells by using additional advanced techniques such as immunoreactivity (immunohistochemistry) markers CD31 or CD34 and factor VIII-related antigen to support this type diagnosis.

## ACKNOWLEDGMENT

The technical assistance of Mr. Abdulatif Sagar is gratefully acknowledged.

## REFERENCES

- Ainsworth, G.C. and P.K.C. Austwick, 1973. Fungal Diseases of Animals. 2nd Edn., Commonwealth Agricultural Bureau, Slough, Farnham Royal, pp: 37-52.

- Akan, M., R. Haziroglu, Z. Ilhan, B. Sareyyüpoğlu and R. Tunca, 2002. A case of Aspergillosis in a broiler breeder flock. *Avian Dis.*, 46: 497-501.
- Archibald, R.G., 1913. Aspergillosis in the Sudan ostrich. *J. Comp. Pathol. Therap.*, 26: 171-173.
- Austwick, P.K.C., 1977. Pathogenicity. In: *The Genus Aspergillus*, Raper, K.B. and D.I. Fennel (Eds.). Robert E. Krieger Publishing Company, Huntingdon, New York, pp: 82-126.
- Campbell, T.W., 1986. Mycotic Diseases. In: *Clinical Avian Medicine and Surgery*, Harrison, G.J. and L.R. Harrison (Eds.). W.B. Saunders Company, Philadelphia.
- Cerruti, S., B. Borello and M. Castagnaro, 1998. Occurrence of cutaneous haemangiomas in chickens: Morphological aspects. *Avian Pathol.*, 6: 501-527.
- Chute, H.L., 1978. Fungal Infections. In: *Diseases of Poultry*, Hofstad, M.S., B.W. Calnek, C.F. Helmbold, W.M. Reid and H.W. Yoder (Eds.). Iowa State University Press, Ames, pp: 367-373.
- Fitzgerald, S.D. and P.G. Moisan, 1995. Mycotic rhinitis in an ostrich. *Avian Dis.*, 39: 194-196.
- Headley, S.A., 2005. Intrathoracic haemangiosarcoma in an ostrich (*Struthio camelus*). *Vet. Recovery*, 156: 353-354.
- Holle, D., 2001. Ostrich Diagnostic Center. 1st Edn., Blue Mountain Feeds Inc., South Africa.
- Huchzermeyer, F.W., 1994. Ostrich Diseases. Agricultural Research Council, Onderstepoort Veterinary Institute, South Africa.
- Jowett, W., 1913. Pulmonary mycosis in the ostrich. *J. Comp. Pathol. Therap.*, 26: 253-257.
- Kamei, K. and A. Watanabe, 2005. Aspergillus mycotoxins and their effect on the host. *Med. Mycol.*, 43: S95-S99.
- Katz, M.E., S.C. Love, H.S. Gill and B.F. Cheetham, 1996. Development of a method for the identification using the polymerase chain reaction of *Aspergillus fumigatus* isolated from ostriches. *Aust. Vet. J.*, 74: 50-54.
- Marks, S.L., E.H. Stauber and S.B. Ernstrom, 1994. Aspergillosis in an ostrich. *J. Am. Vet. Med. Assoc.*, 204: 784-785.
- Müller, C., S.A. Braag, J.D. Herlihy, C.H. Wasserfall, S.F. Chesrown, H.S. Nick, M.A. Atkinson and T.R. Flotte, 2006. Enhanced IgE allergic response to *Aspergillus fumigatus* in CFTR<sup>-/-</sup> mice. *Lab. Invest.*, 86: 130-140.
- Onderka, D.K. and E.C. Doornenbal, 1992. Mycotic dermatitis in ostriches. *Can. Vet. J.*, 33: 547-548.
- Panaccione, D.G. and C.M. Coyle, 2005. Abundant respirable ergot alkaloids from the common airborne fungus *Aspergillus fumigatus*. *Applied Environ. Microbiol.*, 71: 3606-3111.
- Pardo, J., C. Urban, E.M. Galvez, P.G. Ekert and U. Müller *et al.*, 2006. The mitochondrial protein Bak is pivotal for gliotoxin-induced apoptosis and a critical host factor of *Aspergillus fumigatus* virulence in mice. *J. Cell Biol.*, 174: 509-519.
- Perelman, B. and E.S. Kuttin, 1992. Aspergillosis in ostriches. *Avian Pathol.*, 21: 159-163.
- Raper, K.B. and D.I. Fennell, 1977. *The Genus Aspergillus*. Robert E. Krieger Publishing Company, Huntingdon, New York.
- Rousseaux, C.G. and J.B. Dalziel, 1981. *Aspergillus pneumonia* in an ostrich (*Struthio camelus*). *Aust. Vet. J.*, 57: 151-152.
- Sancak, A.A. and J. Paracikoglu, 2005. Aspergillosis and gastric impaction in an ostrich. *Turk. J. Vet. Anim. Sci.*, 29: 933-935.
- Slavin, R.G., P.S. Hutcheson, B. Chauhan and C.J. Bellone, 2004. An overview of allergic bronchopulmonary aspergillosis with some new insights. *Allergy Asthma Proc.*, 25: 395-399.
- Sledge, D.G., Z.A. Radi and D.L. Miller, 2006. Subcutaneous haemangiosarcoma in a cockatiel (*Nymphicus hollandicus*) *Lynn. J. Vet. Med. Ser. A.*, 53: 293-295.
- Terzich, M. and S. Vanhooser, 1993. Postmortem findings of ostriches submitted to the Oklahoma animal disease diagnostic laboratory. *Avian Discovery*, 37: 1136-1141.
- Yokota, T., T. Shibahara, Y. Wada, R. Hiraki, Y. Ishikawa and K. Kadota, 2004. *Aspergillus fumigatus* infection in an ostrich (*Struthio camelus*). *J. Vet. Med. Sci.*, 66: 201-204.