International Journal of

Zoological Research

ISSN 1811-9778

Academic Journals Inc.

www.academicjournals.com

International Journal of Zoological Research 11 (1): 29-36, 2015
ISSN 1811-9778 / DOI: 10.3923/ijzr.2015.29.36

Histological Changes in the Liver and Kidney of *Clarias gariepinus* Fed *Chrysophyllum albidum* Seedmeal as Maize Replacer

[1]W.A. Jimoh, [2]M.O. Sodamola, [3]M.D. Adebayo, [1]O.T. Banjo, [1]A.A. Ayeloja and [1]A.B. Adeleke

[1]Department of Fisheries Technology, Federal College of Animal Health and Production Technology, Moor Plantation, PMB 5029, Ibadan, Nigeria

[2]Department of Agricultural Technology, Federal College of Agriculture, Moor Plantation, PMB 5029, Ibadan, Nigeria

[3]Department of Animal Health, Federal College of Animal Health and Production Technology, Moor Plantation, PMB 5029, Ibadan, Nigeria

Corresponding Author: W.A. Jimoh, Department of Fisheries Technology, Federal College of Animal Health and Production Technology, Moor Plantation, PMB 5029, Ibadan, Nigeria

ABSTRACT

This study investigates the histological changes of kidney and liver of *Clarias gariepinus* fed diets containing *Chrysophyllum albidum* as maize replacer. Five isonitrogenous diets containing maize which was replaced by *Chrysophyllum albidum* at a rate of 0, 25, 50, 75 and 100% were made. The diets without *Chrysophyllum albidum* seedmeal served as the control. The diets were isonitrogenous and isolipidic. Experimental diets were assigned randomly to the tanks and each group of fish was fed 5% body weight in equal proportion per day. The results of this study showed that there was a marked vacuolation of hepatocytes among the treatments after the experiment which is not dietary treatment related. The experiment showed that it is technically feasible to replace maize with *Chrysophyllum albidum* seedmeal in the diet of *Clarias gariepinus* without adverse effect on the histology of kidney and liver.

Key words: Maize replacer, *Clarias gariepinus*, *Chrysophyllum albidum*

INTRODUCTION

Carbohydrates are the cheapest source of dietary energy not only for fish but all domestic animals (Shiau and Lin, 2001). Fagbenro *et al.* (2003) reported that carbohydrates have the physical function of acting as a binder in the formulation of diets. It is essential to ensure adequate energy level is provided in fish diets so as to realize protein sparing effect so that higher percentage of amino acids in protein are made available for growth and other physiological function (Abu *et al.*, 2009). The digestibility of carbohydrates has been shown to vary with their complexity, treatment and levels of inclusion (Adeparusi and Jimoh, 2002). Olurin *et al.* (2006a) reported that maize is one of the major sources of metabolizable energy in most compounded diets for catfish as it is readily digestible by fish. Moehl and Halwart (2005) reported that insufficient quantities of maize were provided in Nigeria because it is predominantly used for human consumption, that it was illegal to export maize from Nigeria. Thus the increasing prohibitive cost and scarcity of maize has necessitated the need to search for underutilized energy source feed ingredients.

The use of alternative energy source feed ingredients in fish feed is well documented; coffee pulp (Fagbenro and Arowosoge, 1991), sweet potato (Faturoti and Oyelese, 1989), cassava (Olurin *et al*., 2006b; Abu *et al*., 2009), biscuit waste (Aderolu *et al*., 2011).

Chrysophyllum albidum (G. Don) is a tropical edible fruit tree. It belongs to the family Sapotaceae (Ehiagbonare *et al*., 2008). It is a primary forest tree species and its natural occurrence has been reported in diverse ecological zones in Nigeria and other African countries (Oboh *et al*., 2009). The cotyledon from the seeds of *Chrysophyllum albidum* have been said to be an excellent source of carbohydrates, tannin, flavonoids, terpenoids and resin (Akaneme, 2008). However, paucity of information exists on the use of *Chrysophylum albidum* seeds as dietary energy source of fish feed especially the effect it has on the histology of the kidney and the liver. This study, therefore seeks to evaluate the histological changes in the liver and the kidney of *Clarias gariepinus* using diets containing *Chrysophylum albidum*.

MATERIALS AND METHODS

Seed collection and processing: Dried matured *Chrysophyllum albidum* seeds were obtained from Bodija Market, Ibadan Oyo State and they were processed by boiling in water (100°C) for 30 min. They were prepared by grinding the samples in a laboratory mill, then mechanically defatted by the use of locally made screw press and sieved with a 200 mm mesh size sieve and put in polythene bags and stored at 4°C. The cakes therefore were analyzed for their proximate composition (AOAC., 1990). Fish meal, soybean meal and other feedstuffs obtained from commercial sources in Nigeria were separately milled screened to fine particles size and triplicate samples were analyzed for their proximate composition (AOAC., 1990). Based on the nutrient composition of the protein feed stuff (Table 1), a control diet and four test diets (40% crude protein, 12% crude lipid) were formulated. The control diets contained soybean meal, providing 50% of the total protein which was replaced by cooked *Chrysophyllum albidum* seed meal. The rate of substitution was 0, 25, 50, 75 and 100% (Table 2).

Culture condition: *Clarias gariepinus* fingerlings were acclimated to experimental condition for 7 days prior to the feeding trial. Groups of 15 catfish fingerlings were stocked into aquaria comprising 60 L capacity rectangular plastic tanks. Each diet was fed to the catfish in triplicate tanks twice daily (09.00, 16.00 h) at 5% body weight for 56 days. Fish mortality was monitored daily, total fish weight in each tank was determined at two weeks intervals and the amount of diet was adjusted according to the new weight.

Table 1: Proximate composition of the protein feed ingredients

Parameters	Fish meal	Soybean meal	CSM	Corn meal
Moisture	9.75	10.70	9.10	10.48
Crude protein	72.40	45.74	10.95	9.87
Crude lipid	10.45	9.68	2.94	4.28
Crude fibre	-	5.10	3.06	5.78
Ash	8.32	4.48	2.12	6.73
NFE	-	30.00	71.83	62.35

CSM: *Chrysophyllum albidum* seedmeal

Table 2: Gross composition of experimental diets (g/100 g) containing *Chrysophyllum albidum* seedmeal fed to *Clarias gariepinus*

Parameters	D1	D2	D3	D4	D5
Fishmeal (72.4%)	52.78	52.78	52.78	52.78	52.78
Corn meal (10.48%)	20.00	15.00	10.00	5.00	-
CSM(10.95%)	-	4.56	9.13	13.69	18.25
*Vit/min premix	5.00	5.00	5.00	5.00	5.00
Fish oil	5.00	5.00	5.00	5.00	5.00
Starch	17.22	17.66	18.09	18.53	18.97
Total	100.00	100.00	100.00	100.00	100.00

CSM: *Chrysophyllum albidum* seedmeal, *Specification: Each kg contains: Vitamin A: 4,000,000 IU, Vitamin B: 800,000 IU, Vitamin E: 16,000 mg, Vitamin K_3: 800 mg, Vitamin B_1: 600 mg, Vitamin B_2: 2,000 mg, Vitamin B_6: 1,600 mg, Vitamin B_{12}: 8 mg, Niacin: 16,000 mg, Caplan: 4,000 mg, Folic acid: 400 mg, Biotin: 40 mg, Antioxidant: 40,000 mg, Chlorine chloride: 120,000 mg, Manganese: 32,000 mg, Iron: 16,000 mg, Zinc: 24,000 mg, Copper: 32,000 mg, Iodine: 320 mg, Cobalt: 120 mg, Selenium: 800 mg manufactured by DSM Nutritional Products Europe Limited, Basle, Switzerland

Histological examination of test organ: At the end of the experiment, three fish per treatment was sampled for histological analysis; the test organism was killed with a blow on the head, using a mallet and was dissected to remove the kidney and liver. The organs was fixed in 10% formalin for three days after which the tissue was dehydrated in Periodic Acid Schiff's Reagent (PAS) following the method of Huges and Perry (1976), in graded levels of 50, 70, 90 and 100% alcohol for 3 days, to allow paraffin wax to penetrate the tissue during embedding.

The organs were then embedded in malted wax. The tissue was sectioned into thin sections (5-7 μm), by means of a rotatory microtome and was dehydrated and stained with Harris haematoxylin-eosin (H&E) stain (Bancroft and Cook, 1994), using a microtome and each section was cleared by placing it in warm water (38°C), where it was picked with clean slide and oven-dried at 58°C for 30 min to melt the wax. The slide containing sectioned materials/tissue was cleared using xylene and graded levels of 50, 70, 90, 95 and 100% alcohol for 2 min each.

The section was stained in haematoxylin eosin for 10 min. The stained slide was observed under a light microscope at varying X100 magnification, sections was examined and photographed using an Olympus BH2 microscope fitted with photographic attachment (Olympus C35 AD4), a camera (Olympus C40 AB-4) and an automatic light exposure unit (Olympus PM CS5P).

RESULTS

Proximate composition of the experimental diets: Table 3 shows the proximate composition of the experimental diets containing *Chrysophyllum albidum* seed meal fed to *Clarias gariepinus*. It reveals the diets to be isonitrogenous and isolipidic as there was no significant difference ($p>0.05$) in the crude protein and crude lipid content of the diet. The protein and lipid requirement of *Clarias gariepinus* was met by the 40 and 12% provided in the experimental diets. All the fish responded well to the dietary treatment given to them.

Histological changes in the liver and kidney of *Clarias gariepinus* fed diets containing *Chrysophyllum albidum* seed meal: Figure 1 shows the histological changes in the liver and kidney of *Clarias gariepinus* fed diet D1. There are few foci of fatty infiltration in the parenchyma with central vein severely congested while its kidney had severe interstitial congestion. Same observation was recorded in the liver and kidney of *Clarias gariepinus* fed diet D2 as shown in Fig. 2. Figure 3 showed there was mild diffuse hepatic vacuolation in the liver of *Clarias gariepinus*

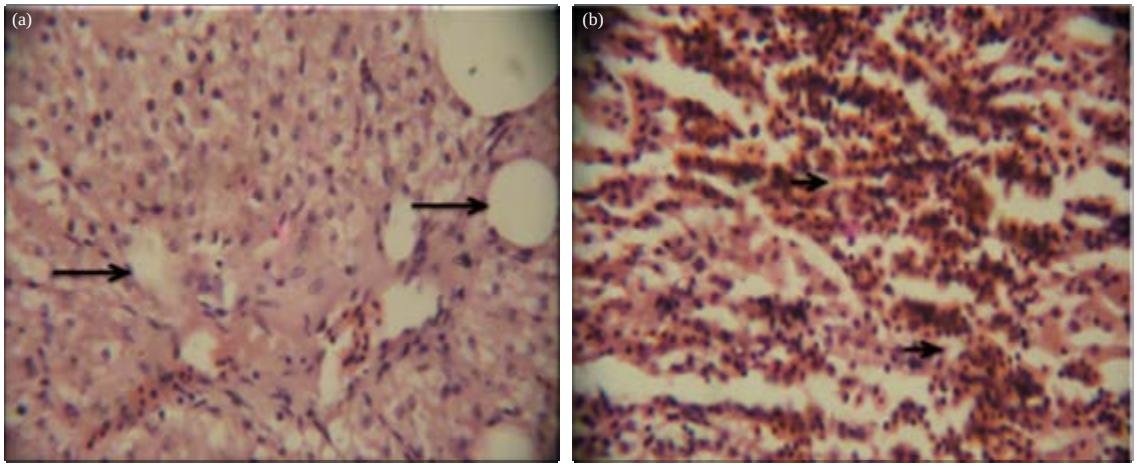

Fig. 1(a-b): Photomicrograph of (a) Liver and (b) Kidney of *C. gariepinus* fed diet D1. Magnification: X400. There are few focl of fatty infiltration in the parenchyma. The central veins are severely congested (liver). There is severe interstitial congestion (kidney)

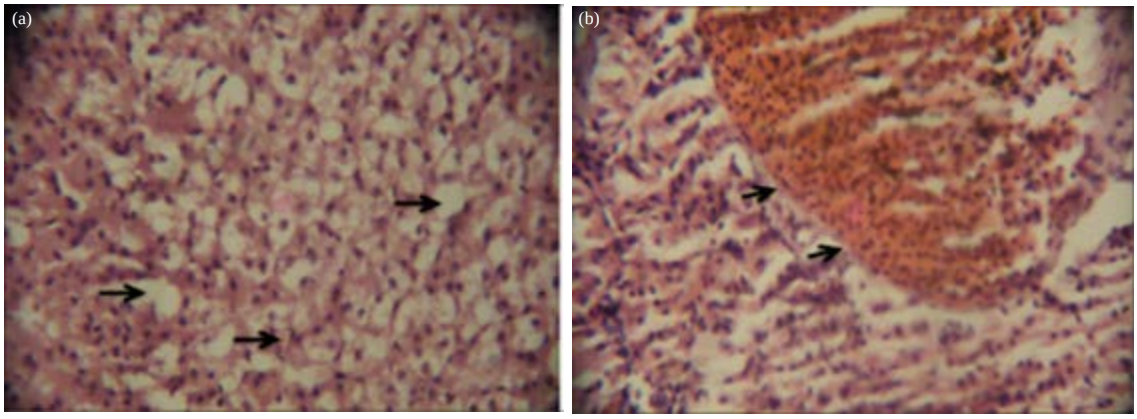

Fig. 2(a-b): Photomicrograph of (a) Liver and (b) Kidney of *C. gariepinus* fed diet D2. Magnification: X400. There are large focal of hepatic vacuolation in the parenchyma (liver). There is severe interstitial congestion (kidney)

Table 3: Proximate composition of experimental diets containing *Chrysophyllum albidum* seed meal fed to *Clarias gariepinus*

Parameters	D1	D2	D3	D4	D5
Moisture	9.24±0.11	9.20±0.03	9.16±0.13	9.12±0.10	9.23±0.06
Crude protein	40.23±0.05	40.20±0.08	40.25±0.15	40.23±0.06	40.20±0.12
Crude lipid	12.17±0.09	12.20±0.05	12.15±0.12	12.16±0.08	12.20±0.13
Crude fibre	4.59±0.45	4.15±0.11	4.16±0.10	4.16±0.05	4.13±0.05
Ash	4.48±0.06	4.60±0.45	4.50±0.32	4.33±0.40	4.37±0.31
NFE	29.29±0.31	29.71±0.51	29.80±0.50	29.10±0.40	29.93±0.30

Row means without superscript are not significantly different ($p>0.05$) from one another

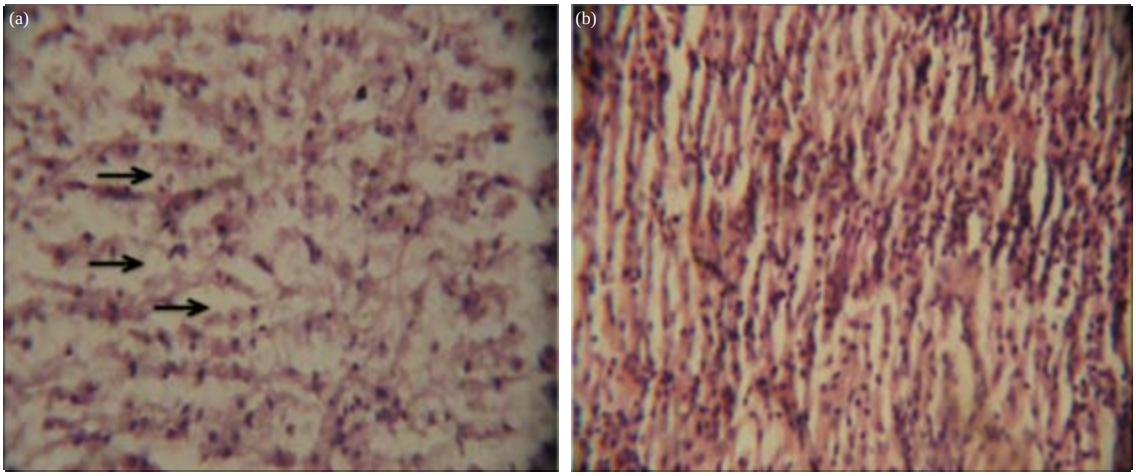

Fig. 3(a-b): Photomicrographs of (a) Liver and (b) Kidney of *Clarias gariepinus* fed diet D3. Magnification: X400. There is mild diffuse hepatic vacuolation (liver). No visible lesions seen (kidney)

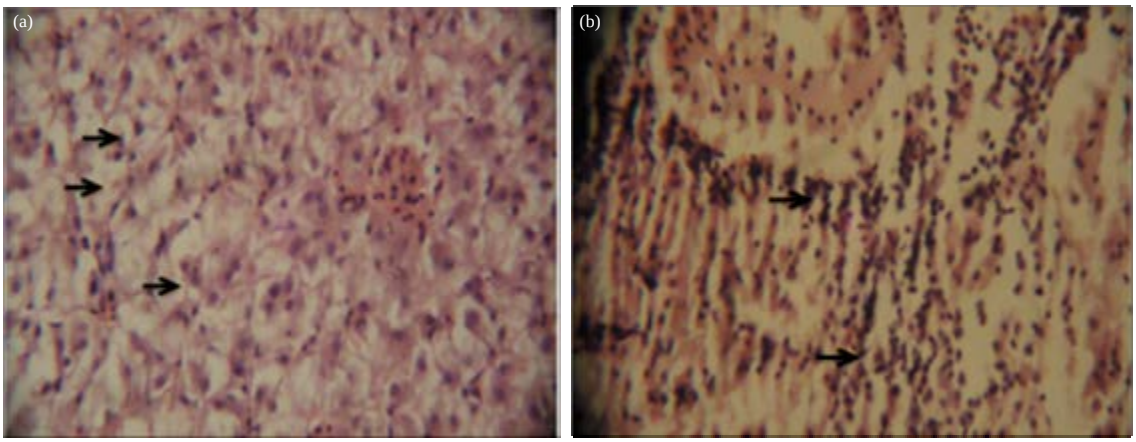

Fig. 4(a-b): Photomicrographs of (a) Liver and (b) Kidney of *C. gariepinus* fed diet D4. Magnification: X400. There are areas of severe congestion and haemorrhage in the hepatic parenchyma. There is also a diffuse vacuolation of hepatocytes (liver). There are few areas of mild interstitial congestion (kidney)

fed diet D3 with no visible lesion in its kidney. Figure 4 showed areas of severe congestion and haemorrhage were seen in the hepatic parenchyma of the liver of *Clarias gariepinus* fed diet D4 with diffuse vacuolation of hepatocyte. Its kidney has few areas of mild interstitial congestion. There are mild diffuse vacuolation of hepatocytes in the liver of fish fed diet D5 as shown in Fig. 5 with no visible lesions seen in the kidney. The changes observed in the liver and kidney of *Clarias gariepinus* under study was not dietary treatment related.

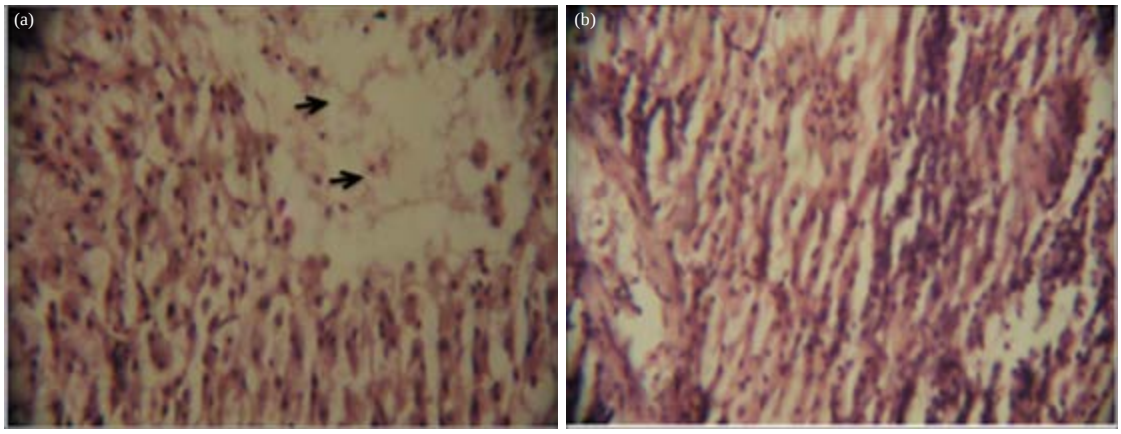

Fig. 5(a-b): Photomicrographs of (a) Liver and (b) Kidney of *C. gariepinus* fed DS. Magnification: X400. There is a very mild diffuse vacuolation of hepatocytes (liver), no visible lesions seen (kidney)

DISCUSSION

The histology of the kidney and the liver of fish fed the diets containing *Chrysophyllum albidum* replacing maize seemed not to be altered by *Chrysophyllum albidum* substitution similar to results reported by Merida *et al.* (2010) and that reported by Pereira *et al.* (2002) in rainbow trout fed diets with a partial substitution of Brassica by-products likewise, Hansen *et al.* (2006). Although, the results of this study showed that there was a marked vacuolation of hepatocytes among the treatments after the experiment which was not dietary treatment related, same observation was made by Olukunle (2011) and Jimoh (2012). The high vacuolation of the liver may be attributed to high lipid content of the organ traceable to high lipid in the diets. Same observation was made by Martins *et al.* (2007), Valente *et al.* (2011) and Gatta *et al.* (2011) that the presence of numerous and voluminous lipid droplets in hepatocytes is physiological response to dietary lipid excess or increased lipogenesis. Olurin *et al.* (2006b) reported that the shrinkage of the hepatic cells can result in the contracting of the blood vessels thereby impeding the portal flow through the liver which negatively affect the normal physiological functioning of the liver. Marchand *et al.* (2009) stated that large numbers of toxicants often induce histological alteration in the liver. Liver is a target organ of different xenobiotic substances (Cabot, 2000). Nero *et al.* (2006) reported that liver tissue damage occur when it is constantly exposed to toxicants. Hence it can be concluded that replacement of maize by cooked *Chrysophyllum albidum* seedmeal left some vacuolation symptoms in the hepatocytes and not much stress is placed on the health of *Clarias gariepinus* fed cooked *Chrysophyllum albidum* seedmeal based diets.

REFERENCES

AOAC., 1990. Official Method of Analysis. 15th Edn., Association of Official Analytical Chemists, Arlington, VA., USA.

Abu, O.M.G., O.L. Sanni, G. Tarawali, M. Akoroda and A. Dixon, 2009. The effect of replacing maize with whole cassava root meal on the nutrient utilization of hybrid cat fish. J. Aquacult. Feed Sci. Nutr., 1: 61-67.

Adeparusi, E.O. and W.A. Jimoh, 2002. Digestibility coefficients of raw and processed lima bean diet for Nile Tilapia, *Oreochromis niloticus*. J. Applied Aquacult., 1: 89-98.

Aderolu, A.Z., O.O. Aarode, A.A. Akonu and W.A. Jimoh, 2011. The effect of substituting maize with graded level of biscuit waste on growth, nutrient utilisation, carcass composition, haematological parameter and economic performance of African catfish (*Clarias gariepinus*). J. Nat. Sci. Eng. Technol., 10: 111-120.

Akaneme, F.I., 2008. Identification and preliminary phytochemical analysis of herbs that can arrest threatened miscarriage in Orba and Nsukka towns of Enugu State. Afr. J. Biotechnol., 7: 6-11.

Bancroft, J.D. and H.C. Cook, 1994. Manual of Histological Techniques and their Diagnostic Application. Churchill Livingstone, London, UK., pp: 289-305.

Cabot, S., 2000. The liver and detoxification. http://nancymarkle.com/liver.txt.

Ehiagbonare, J.E., H.I. Onyibe and E.E. Okoegwale, 2008. Studies on the isolation of normal and abnormal seedlings of *Chrysophyllum albidum*: A step towards sustainable management of the taxon in the 21st century. Sci. Res. Essay, 3: 567-570.

Fagbenro, O.A. and I.A. Arowosoge, 1991. Growth response and nutrient digestibility by *Clarias isheriensis* (Sydenham, 1980) fed varying levels of dietary coffee pulp as replacement for maize in low-cost diets. Bioresour. Technol., 37: 253-258.

Fagbenro, O.A., E. Adeparusi and O. Fapohunda, 2003. Feed stuffs and dietary substitutions for farmed fish in Nigeria. Proceedings of the National Workshop on Fish Feed Development and Feeding Practices in Aquaculture, September 15-19, 2003, New Bussa, Nigeria, pp: 60-65.

Faturoti, E.O. and I. Oyelese, 1989. Digestibility and utilization of yellow maize and sweet potato based diets by *Clarias gariepinus*. Proceedings of the Nigerian Association for Aquatic Sciences, June 12-14, 1989, Ibadan, Nigeria, pp: 158-164.

Gatta, P.P., L. Parma, I. Guarniero, L. Mandrioli, R. Sirri, R. Fontanillas and A. Bonaldo, 2011. Growth, feed utilization and liver histology of juvenile common sole (*Solea solea* L.) fed isoenergetic diets with increasing protein levels. Aquacult. Res., 42: 313-321.

Hansen, A.C., G. Rosenlund, O. Karlsen, P.A. Olsvik and G.I. Hemre, 2006. The inclusion of plant protein in cod diets, its effects on macronutrient digestibility, gut and liver histology and heat shock protein transcription. Aquacult. Res., 37: 773-784.

Huges, G.M. and S.F. Perry, 1976. Morphometric study of trout gills: A light-microscopic method suitable for the evaluation of pollutant action. J. Exp. Biol., 64: 447-460.

Jimoh, W.A., 2012. Nutritive value of sesame (*Sesamum indicum*) or sunflower (*Helianthus annuus*) seed meals as dietary protein sources for African catfish. Ph.D. Thesis, Federal University of Technology, Akure.

Marchand, M.J., J.C. van Dyk, G.M. Pieterse, I.E.J. Barnhoorn and M.S. Bornman, 2009. Histopathological alterations in the liver of the sharptooth catfish *Clarias gariepinus* from polluted aquatic systems in South Africa. Environ. Toxicol., 24: 133-147.

Martins, D.A., L.M.P. Valente and S.P. Lall, 2007. Effects of dietary lipid level on growth and lipid utilization by juvenile Atlantic halibut (*Hippoglossus hippoglossus*, L). Aquaculture, 263: 150-158.

Merida, S.N., A. Tomas-Vidal, S. Martinez-Llorens and M.J. Cerda, 2010. Sunflower meal as a partial substitute in juvenile sharpsnout sea bream (*Diplodus puntazzo*) diets: Amino acid retention, gut and liver histology. Aquaculture, 298: 275-281.

Moehl, J. and M. Halwart, 2005. A synthesis of the formulated animal and aquafeed industry in Sub-Saharan Africa. CIFA Occasional Paper No. 26, Food and Agriculture Organization of the United Nations, Rome, Italy, pp: 1-61.

Nero, V., A. Farwell, A. Lister, G. van der Kraak and L.E. Lee *et al.*, 2006. Gill and liver histopathological changes in yellow perch (*Perca flavescens*) and goldfish (*Carassius auratus*) exposed to oil sands process-affected water. Ecotoxicol. Environ. Saf., 63: 365-377.

Oboh, I.O., E.O. Aluyor and T.O.K. Audu, 2009. Use of *Chrysophyllum albidum* for the removal of metal ions from aqueous solution. Sci. Res. Essays, 4: 632-635.

Olukunle, O., 2011. Evaluation of different dietary oil sources on growth performance and nutrient utilisation of *Clarias gariepinus* juveniles. Niger. J. Fish., 8: 184-196.

Olurin, K.B., E.A.A. Olojo and O.A. Olukoya, 2006a. Growth of African catfish *Clarias gariepinus* fingerlings, fed different levels of cassava. World J. Zool., 1: 54-56.

Olurin, K.B., E.A.A. Olojo, G.O. Mbaka and A.T Akindele, 2006b. Histopathological responses of the gill and liver tissues of Clarias gariepinus fingerlings to the herbicide, glyphosate. Afr. J. Biotechnol., 5: 2480-2487.

Pereira, O., E. Rosa, M.A. Pires and A. Fontainhas-Fernandes, 2002. Brassica by-products in diets of rainbow trout (*Oncorhynchus mykiss*) and their effects on performance, body composition, thyroid status and liver histology. Anim. Feed Sci. Technol., 101: 171-182.

Shiau, S.Y. and Y.H. Lin, 2001. Carbohydrate utilization and its protein-sparing effect in diets for grouper (*Epinephelus malabaricus*). Anim. Sci., 73: 299-304.

Valente, L.M.P., F. Linares, J.L.R. Villanueva, J.M.G. Silva and M. Espe *et al.*, 2011. Dietary protein source or energy levels have no major impact on growth performance, nutrient utilisation or flesh fatty acids composition of market-sized Senegalese sole. Aquaculture, 318: 128-137.