Journal of

Fisheries and Aquatic Science

ISSN 1816-4927

Academic
Journals Inc.

www.academicjournals.com

Journal of Fisheries and Aquatic Science 7 (6): 454-460, 2012
ISSN 1816-4927 / DOI: 10.3923/jfas.2012.454.460

Incidence and Identification of *Klebsiella pneumoniae* in Mucosal Buccal Polyp of *Nemipterus japonicus* of Visakhapatnam Coast, India

T.C. Diana and C. Manjulatha
Department of Zoology, Andhra University, Visakhapatnam, Andhra Pradesh, India

Corresponding Author: T.C. Diana, Department of Zoology, Andhra University, Visakhapatnam, Andhra Pradesh, India

ABSTRACT

Nemipterids are one of the important commercial and demersal resources of Visakhapatnam coast. Most of the *Nemipterus japonicus* caught in this coastal area were found to have lesions over the body surface along with a typical mucosal polyp in the buccal cavity, showing clinical signs of exophthalmia, skin discoloration with deep ulcers, frayed fins, damaged gills, distended abdomen with calcified gonads and hemorrhages. Hence, the present study is aimed to know the aetiological agent causing these lesions and polyps. Therefore, the smears were collected in the form of swabs from these lesions. The smear was examined by Grams method and inoculated into selective media. The organisms isolated and identified by biochemical and microbiological studies. Out of 50 *Nemipterus japonicus*, subjected to the above microbiological studies, *Klebsiella pneumoniae* were isolated from 40 fishes, *Vibrio* species from 5 fishes and *Enterococci* species from the remaining. It is concluded that the disease in these fishes is mainly due to infection by *Klebsiella pneumoniae*.

Key words: Mucosal polyp, buccal cavity, *Klebsiella pneumoniae*, *Nemipterus japonicus*

INTRODUCTION

Environmental awareness around the world in the past years increased interest in the study of fish diseases, mostly caused by bacteria. The bacterial diseases are caused mainly due to contaminated water and sea foods and their associated disease outbreaks affected by toxins, biotoxins and histamines reaching the higher trophic levels (Musa *et al*., 2008; Chen *et al*., 2010).

The threadfin breams of the genus *Nemipterus* have an important commercial value as good protein source. Large number of *N. japonicus* in the coastal area of Visakhapatnam is found to be suffering from buccal polyps and other associated manifestations. This fish is consumed by large number of economy class people and there is a potential risk, if such infected fish are consumed raw or improperly cooked. There is a threat of spreading infection to other species as well as decline of species due to disease (Diana, 2007).

In this area, there are few microbiological reports on *Nemipterus japonicus*. Petersen *et al*. (1993) reported an unidentified microspora infection in *Nemipterus* species from central Philippine water. Singh (1996) isolated *S. typhosa* in *N. japonicus* from Sapthagiri in Maharashtra. Rajapandiyan *et al*. (2009) reported on the prevalence and distribution of *Vibrio vulnificus* in *N. japonicus* from Chennai, Indian Ocean. Diana and Ramulu (2009, 2010) reported biochemical changes in *Nemipterus japonicus* infected with *Klebsiella* species as compared to the normal fish off Visakhapatnam Coast. Many scientists have reported on the *Klebsiella*

infection in different fishes (Cann and Taylor, 1982; Daskalov *et al*., 1998; Rajkumar *et al*., 2007; Choudhury *et al*., 2008; Ogbonna *et al*., 2008; Ravichandran and Ajithkumar, 2008; Abdelhamid *et al*., 2009; Bragadeeswaran and Thangaraj, 2011; Mahin *et al*., 2011; Akinyemi and Buoro, 2011; Ayeloja *et al*., 2011). The present intention was to isolate the pathogenic microflora from mucosal buccal polyp of *N. japonicus*.

MATERIALS AND METHODS

The specimens were collected regularly from the harbour water of Visakhapatnam. The fish were examined for external disease characters for identification like skin ulcers and differentiation is done according as superficial or deep ulcerations. Skin scrapings and gill racker observations were done to identify the external etiology. The samples were brought to the laboratory and subjected to microbiological analysis under sterile conditions. Smears from the buccal polyp were collected by using swabs. These swabs were inoculated directly on Blood Agar, MacConkey agar and EMB agar and incubated at 30-32°C for 2 days. The subcultures were made from single colonies onto peptone water and incubated for 4 h. A wide range of biochemical tests were performed with this young culture to identify the incriminating pathogen.

Smears made from isolated colonies were stained by Grams method, motility was tested by hanging drop method followed by biochemical tests. Catalase production, oxidase, nitrate reduction, urea hydrolysis, Voges-Proskauer test, citrate utilization and gelatinase test were performed. Carbohydrate fermentation tests were done with glucose, lactose, sucrose, D-adonitol, arabinose, inositol, rhamnose, raffinose, salicin, D-sorbitol, trehalose and xylose. Aminoacid utilization tests were also done with arginine, lysine, ornithine and phenlyalanine deaminase as per standard procedures described by Collee *et al*. (2006).

RESULTS

In the present study, a typical mucosal polyp was detected in the buccal cavity of *N. japonicus* (Fig. 1). External aetiology showed exophthalmia, skin discoloration with deep ulcers, frayed fins, damaged gills, distended abdomen with calcified gonads, petechial haemorrhages on skin, mouth, operculum, base of pectoral, pelvic and anal fins over their body surface (Fig. 2, 3).

A total number of 50 *N. japonicus* were examined and subjected to microbiological studies. The direct smears from mucosal buccal polyp revealed thick Gram negative, non-motile bacilli with clear capsular hallows in large numbers. The culture plates were examined after 24 h incubation. On blood agar plates, large mucoid colonies measuring about 3 to 5 mm in size were observed. Mucoid

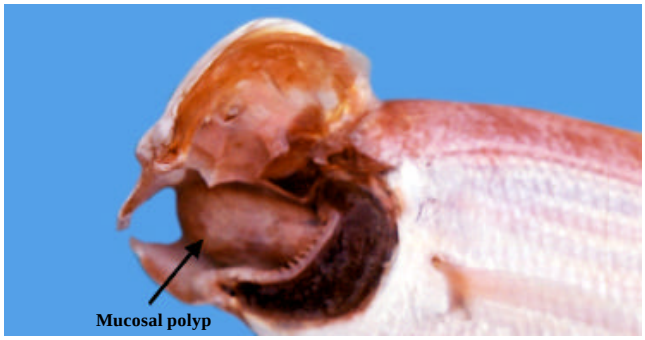

Fig. 1: Polypoidal mass in the buccal cavity



Fig. 2: Diseased skin with pale colouration, Exop: Exophthalmia (pop-eye), SU: Skin ulcer

Fig. 3: The operculum and jaws are hyperemic

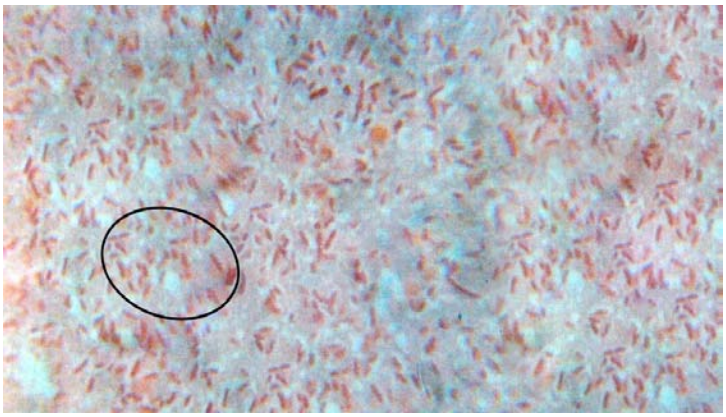

Fig. 4: Encircled area shows Gram negative bacilli capsular with hallows, cultured on MacConkey's agar

nature of the colony was observed by naked eye as well as by demonstration of mucous strings when lifted with a loop. The colonies were non-haemolytic.

On MacConkey's medium, similar type of large mucoid colonies were observed which were pink in colour denoting that they were lactose fermentors. The Gram stained smears from the culture plates are morphologically similar to those seen in the direct smears (Fig. 4).

Table 1: Pathogenic bacterial species isolated from fish

Bacterial pathogens	No. of isolates	Percent
Klebsiella pneumoniae	40	80
Vibrio sp.	5	10
Enterococci sp.	5	10

Table 2: Biochemical characters of *Klebsiella pneumoniae* strains isolated, n = 40

	Species	
Biochemical tests performed	No. of positive	No. of negative
Motility	0	40
Catalase production	40	0
Oxidase	0	40
Nitrate reduction	40	0
Urea hydrolysis	40	0
Voges-Proskauer	40	0
Indole	0	40
Citrate	40	0
Malonate	40	0
Arginine	0	40
Lysine	40	0
Ornithine	0	40
Phenylalanine deaminase	0	40
Gelatinase	0	40
Glucose	40	0
Lactose	40	0
Sucrose	40	0
D-adonitol	40	0
Arabinose	40	0
Inositol	40	0
Rhamnose	40	0
Raffinose	40	0
Salicin	40	0
D-Sorbitol	40	0
Trehalose	40	0
Xylose	40	0

Out of the fifty *N. japonicus* examined, *Klebsiella pneumoniae* strains were isolated from forty specimens, *Vibrio* species from five specimens and *Enterococci* species from the remaining five specimens (Table 1).

All the strains of *Klebsiella pneumoniae* isolated (40) from the lesions, exhibited typical biochemical characters. They were catalase positive, Voges-Proskauer positive and utilised citrate, melanate and lysine, reduced nitrate to nitrites and hydrolysed urea. All the sugars tested were fermented with production of acid and gas. They were non motile, oxidase and indole negative, arginine, ornithine utilisation and phenylalanine deaminase tests were negative (Table 2).

DISCUSSION

Harbour is therefore, a typical example of ecosystem that experiences chronic pollution due to untreated pollutants discharged it. These become stagnant and aggravate heavy loads of

bacteria, resulting in chronic infectious diseases and mass mortality of fish. As Nemipterids are bottom dwellers, these fish are mostly affected by the polluted environment in which they live (Diana, 2007). These demersal species are particularly susceptible to physical abnormalities and diseases, which appear to be associated with contaminated sediments (Stehr *et al*., 1997).

In the present study, heavy bacterial loads have been isolated from the mucosal buccal polyp of *N. japonicus*. Since mucous surfaces are important defense barriers against bacterial infection, mucous layers in fish are related to a number of activities including the prevention of colonization by pathogens. These observations are supported by few scientists. Interaction of bacterial pathogens with subjacent tissues, the gut, the gills and the intestines have been described as possible sites of entry for pathogens into the fish (Chabrillon *et al*., 2003). Success of any pathogen is dependent on its ability to elude host immune responses. Bacteria often overcome physical barriers by secreting enzymes that digest the barrier (Cianciotto, 2005).

In the present study, the fish collected from harbour waters showed high prevalence of ulcers and fin erosion. Microbial studies revealed that *Klebsiella pneumoniae* isolated from forty *N. japonicus* is the most common pathogen causing these lesions. In the other ten fishes tested, *Vibrio* species were isolated in five fishes and *Enterococci* species in the other five fishes. These observations are in correlation with the earlier studies made by several investigators (Cann and Taylor, 1982). Daskalov *et al*. (1998) reported *Klebsiella pneumoniae* causing fin and tail disease in Rainbow trout (*Oncorhynchus mykiss* Walbaum), Rajkumar *et al*. (2007) studied on the secondary infection caused by *Vibrio*, *Salmonella* and *Pseudomonas* loads from *Stolephorus commersonnii*. Choudhury *et al*. (2008) isolated *Vibrio* species along with other histamine bacteria from Indian mackerel fish *Rastrelliger kanagurta*. Ogbonna *et al*. (2008) isolated *Klebsiella* species from gills and intestine of *Tilapia zilli* from creeks around Port Harcourt, Nigeria. Ravichandran and Ajithkumar (2008) observed lesioned spots with heavy load of *Vibrio parahaemolyticus* and *V. anguillarum* in *Ilisha melastoma*. Abdelhamid *et al*. (2009) worked on pathogenic strains of Gram negative bacteria like *Vibrio* species and *Klebsiella* species isolated from African catfish. Bragadeeswaran and Thangaraj (2011) isolated *Vibrio parahaemolyticus*, *Klebsiella pneumonia*, *Klebsiella oxytoca* from skin mucus of eel fish, *Anguilla Anguilla*. Mahin *et al*. (2011) identified *Klebsiella ozaenae*, *Klebsiella edwardsii* from fresh water Mola fish *Amblypharyngodon mola*. Akinyemi and Buoro (2011) reported *Klebsiella* sp. and *Vibrio parahaemolyticus* from gills, skin and buccal cavity of *Lutjanus agennes*, *Pseudotolithus elongatus* and *Sphyraena barracuda* from Lagos Lagoon, Nigeria. Ayeloja *et al*. (2011) isolated *Klebsiella pneumoniae* from smoked African catfish, *Clarias gariepinus*.

In the present study, *Klebsiella pneumoniae* which belong to the family Enterobacteriaceae is the predominant pathogen isolated in most of the fishes examined. These results correlate with many investigators, Taylor *et al*. (1979) isolated histamine-producing *Klebsiella pneumoniae* strain T2 from spoiled Tuna Sashimi. Enteric bacteria have been reported to be the dominant Histamine-Producing Bacteria (HPB) in fish (Taylor and Eitenmiller, 1986). In a previous study, Diana and Ramulu (2009, 2010) observed abnormal variations in biochemical composition in different tissues of *N. japonicus* in relation to *Klebsiella* infection. Hence, the manifestations in the infected fishes with *Klebsiella pneumoniae* may be due to direct affect of endotoxins with associated abnormal immunological responses.

The significance and possible role of these pathogens, in relation to physiological process and immunological response of the fish, sets a platform for further studies in relation to pathology, pollution and stress conditions in fish habitats (natural and polluted environments), prevalent in

the world today. With relation to the other organisms isolated in this study, no conclusion can be drawn since their numbers are too small. Further, wider studies are required to attribute any significance of these organisms in their pathogenic role.

ACKNOWLEDGMENT

The corresponding author is grateful to Department of Science and Technology, Andhra University, Visakhapatnam, Andhra Pradesh, New Delhi, India for financial support of the project.

REFERENCES

Abdelhamid, A.M., A.I. Mehrim, M.I. El-Barbary, S.M. Ibrahim and A.I. Abd El-Wahab, 2009. Evaluation of a New Egyptian probiotic by African catfish fingerlings. J. Environ. Sci. Technol., 2: 133-145.

Akinyemi, A.A. and O.O. Buoro, 2011. Occurrence of bacteria found in gills, skin, buccal cavity of *Lutjanus agennes*, *Pseudotolithus elongatus* and *Sphyraena barracuda* from Lagos Lagoon, Nigeria. J. Fish. Aquat. Sci., 6: 555-562.

Ayeloja, A.A., F.O.A. George, S.O. Obasa and L.O. Sanni, 2011. Effect of Post-slaughter Time Intervals on the Quality of the African Catfish, *Clarias gariepinus* (Burchell, 1822). Am. J. Food Technol., 6: 790-797.

Bragadeeswaran, S. and S. Thangaraj, 2011. Hemolytic and antibacterial studies on skin mucus of eel fish, *Anguilla anguilla* Linnaues, 1758. Asian J. Biol. Sci., 4: 272-276.

Cann, D. and L. Taylor, 1982. An outbreak of botulism in rainbow trout, *Salmo gairdneri* Richardson, farmed in Britain. J. Fish Dis., 5: 393-399.

Chabrillon, M., M.C. Balebona and M.A. Morinigo, 2003. Interactions of fish pathogenic *Vibrio* species with the mucous surface of gilthead seabream (*Sparus aurata*). Recent Res. Dev. Microbiol., 7: 41-53.

Chen, H., L.N. Leey, D. Hwang and Y. Tibal, 2010. Determination of histamine and Bacterial Isolation in Marun Fillets, *Makaira nigricans* implicated in a food borne poisoning. J. Food Saf., 30: 699-710.

Choudhury, M., M.K. Sahu, K. Sivakumar, T. Thangaradjou and L. Kannan, 2008. Inhibition of actinomycetes to histamine producing bacteria associated with Indian mackerel fish (*Rastrelliger kanagurta*, Cuvier, 1816). J. Fish. Aquatic Sci., 3: 126-136.

Cianciotto, N., 2005. Type II secretion: A protein secretion system for all seasons. Trends Microbiol., 13: 581-588.

Collee, J.G., R.S. Miles and B. Watt, 2006. Tests for Identification of Bacteria. In: Mackie and McCartney Practical Medical Microbiology, Collee, J.G., A.G. Fraser, B.P. Marmion and A. Simmons (Eds.). 14th Edn. Elsevier India Pvt. Ltd., India, pp: 131-149.

Daskalov, H., M. Stobie and B. Austin, 1998. *Klebsiella pneumonia*: A pathogen of rainbow trout (*Oncorhynchus mykiss*, Walbaum). Bull. Eur. Assoc. Fish Pathologists, 18: 26-28.

Diana, T.C., 2007. Studies on histological and histopathological aspects of the marine teleost *Nemipterus japonicus* (Bloch) with special reference to diseases. Ph.D. Thesis, Andhra University, Visakhapatnam, India.

Diana, T.C. and K.S. Ramulu, 2009. Observations of carbohydrate levels in liver and intestine of *Nemipterus japonicas* in relation to *Klebsiella* species infection. J. Pure Appllied Microbiol., 3: 715-718.

Diana, T.C. and K.S. Ramulu, 2010. Changes in the protein content of liver and intestine in relation to *Klebsiella* infection in *Nemipterus japonicas* from the coast of Visakhapatnam, India. Asian. J. Anim. Sci., 4: 143-145.

Mahin, A.A., M.G. Sorrowar, M.Z. Hasan, M.M. Haque and H. Rashid, 2011. Effect of low temperature, radiation and their combination treatments on microorganisms associated with fresh water mola fish, *Amblypharyngodon mola* (Hamilton- Buchanan, 1822). Asian J. Biotechnol., 3: 507-518.

Musa, N., L.S. Wei, F. Shaharom and W. Wee, 2008. Surveillance of bacteria species in diseased fresh water ornamental fish from aquarium shop. World Appl. Sci. J., 3: 903-905.

Ogbonna, D.N., T.G. Sokari and G.E. Amaku, 2008. Antibiogram of bacterial flora of *Tilapia zilli* from creeks around port Harcourt, Nigeria. J. Environ. Sci. Technol., 1: 27-33.

Petersen F., H. Palm, H. Moller and M.A. Cuzi, 1993. Flesh parasites of fish from central Philippine waters. Dis. Aquat. Org., 15: 81-86.

Rajapandiyan S., K. Sudha and D.K. Arunachalam, 2009. Prevalence and distribution of *Vibrio vulnificus* in fishes caught off Chennai, Indian Ocean. Afr. J. Microbiol. Res., 3: 622-625.

Rajkumar, M., R. Thavasi, P. Perumal and J.P. Trilles, 2007. Parasite induced vibriosis in *Stolephorus commersonii*. Res. J. Microbiol., 2: 972-977.

Ravichandran, S. and T.T. Ajithkumar, 2008. Secondary microbial infection in *Ilisha melastoma* due to isopod fish parasites. J. Fish. Aquatic Sci., 3: 92-96.

Singh, R.B., 1996. Pathogenic microflora associated with marine fishes of Satpati fishing centre in Maharashtra. Indian J. Fish., 43: 303-306.

Stehr, C.M., M.S. Myers, D.G. Burrows, M.M. Krahn, J.P. Meador, B.B. Mc Cain and U. Varanasi, 1997. Chemical contamination and associated liver diseases in two species from San Francisco bay and bodega bay. Ecotoxicology, 6: 35-65.

Taylor, S.L. and R.R. Eitenmiller, 1986. Histamine food poisoning: Toxicology and clinical aspects. Crit. Rev. Toxicol., 7: 91-128.

Taylor, S.L., Guthertz L.S., M. Leatherwood and E. Lieber, 1979. Histamine production by *Klebsiella pneumonia* and an incident of scombroid fish poisoning. Applied Environ. Microbiol., 37: 274-278.