



Journal of
**Pharmacology and
Toxicology**

ISSN 1816-496X



Academic
Journals Inc.

www.academicjournals.com

Effect of Calcitonin on Acute Hepatic Damage in Rats *in vivo*

¹Omar M.E. Abdel Salam, ¹Amany A. Sleem and ²Nermeen M. Shaffie
¹Department of Pharmacology, ²Department of Pathology,
National Research Centre, Tahrir St., Dokki, Cairo, Egypt

Abstract: This study aimed to investigate the effect of salmon calcitonin on the acute hepatic injury in rats. Hepatotoxicity was induced by CCl₄ orally (2.8 mL kg⁻¹ followed by 1.4 mL kg⁻¹ after one week). Calcitonin at three dose levels (2.25, 4.5 or 9 mg kg⁻¹, s.c.) or silymarin (25 mg kg⁻¹, p.o.) was given daily for 14 days, starting at time of administration of CCl₄. Liver damage was assessed by determining liver serum enzyme activities and by hepatic histopathology. Calcitonin administration decreased the elevations in serum alanine aminotransferase (ALT), aspartate aminotransferase (AST) and alkaline phosphatase (ALP) and also prevented the development of hepatic necrosis caused by CCl₄. The effect of calcitonin was dose-dependent one. Calcitonin given to CCl₄-treated rats at 2.25 mg kg⁻¹ reduced the elevated plasma ALT by 25.5%. Calcitonin administered at doses of 4.5 or 9 mg kg⁻¹ significantly decreased the raised plasma ALT by 49.3 and 72.4%, AST by 51.3 and 61%, ALP by 29.1 and 48.3%, respectively. Silymarin, in comparison, decreased elevated ALT, AST and ALP levels by 72.6, 67.4 and 64.4%, respectively. Histopathologic examination of the livers of rats treated with CCl₄ + calcitonin showed marked restoration of the normal architecture of the liver tissue. It is concluded that administration of calcitonin in liver injury induced by CCl₄ results in less liver damage.

Key words: Calcitonin, hepatic injury, rats, CCl₄

INTRODUCTION

Calcitonin is a 32-amino-acid polypeptide hormone that is involved in calcium homeostasis. Calcitonin is secreted by the parafollicular cells (C cells) in the thyroid gland in response to high blood calcium. The physiological response to circulating levels of calcitonin is an increase in calcium excretion from the kidney and a decrease in osteoclast-mediated bone resorption (Doftos, 1993). Calcitonin inhibits bone resorption by a direct action on osteoclasts through an action at specific receptors on osteoclasts to inhibit activity (Holloway *et al.*, 1997) and therefore is widely used to treat metabolic bone disorders characterised by excessive bone resorption, such as Paget's disease of bone, malignancy associated hypercalcemia and osteoporosis (Martin, 1999). Calcitonin has in addition distinct effects in the central nervous system, where the administration of calcitonin can induce analgesia, appetite suppression (Eiden *et al.*, 2002), modulation of hormone release (Sexton, 1991) and inhibition of gastric acid secretion (Morley *et al.*, 1981; Guglietta *et al.*, 1988).

Little is known, however, regarding the effect of this hormone on the liver function in the presence of hepatic injury, but in rat hepatocytes, calcitonin has been reported to prevent CCl₄-induced hydroperoxide generation and cytotoxicity Chen *et al.* (1996). In several studies, another related peptide, that is calcitonin gene-related peptide (CGRP), which is formed by alternative transcription of the calcitonin/alpha-CGRP gene, which also gives rise to calcitonin, displayed hepatic protective effects (Harada *et al.*, 2005, 2006; Kamiyoshi *et al.*, 2006).

In view of the structural similarity between CGRP and calcitonin and since calcitonin constitutes an important part in the management of osteoporosis and also as an effective analgesic in those with

vertebral fractures (Martin, 1999; Blau, 2003) and because these patients might also have concomitant liver disease, it looked pertinent to examine the effect of calcitonin administration in the presence of liver damage. The effect of calcitonin was evaluated both on biochemical markers as well as by histological techniques and compared to that of silymarin, a standardized extract of the milk thistle (*Silybum marianum*) that is used in the management of chronic hepatitis in view of the antioxidant and cellular membrane permeability reducing properties of the flavonoid compounds silibinin, silychristine and silydianin it contains (Valenzuela and Garrido, 1994).

MATERIALS AND METHODS

Animals

Adult Sprague-Dawley rats of either sex, weighing 150-160 g of body weight were used throughout the experiments. They were fed with standard laboratory chow and water provided *ad libitum*. All animal procedures were performed according to approved protocols and in accordance with the recommendations for the proper care and use of laboratory animals.

Drugs and Chemicals

Carbon tetrachloride (BDH Chemicals, England), synthetic salmon calcitonin (Miacalcin, Novartis) were used in the experiments. Salmon calcitonin was dissolved in saline to obtain the necessary doses. The doses employed were based upon the human dose after conversion to rat doses according to Paget and Barnes (1964).

The Carbon Tetrachloride Model of Hepatic Damage

Liver damage was induced by CCl₄-olive oil given orally (1:1, 2.8 mL kg⁻¹ followed by 1.4 mL kg⁻¹ after one week). Starting on the time of the first dose of CCl₄ administration, rats (n = 6/group) also received either calcitonin (at three dose levels of 2.25, 4.5 or 9 mg kg⁻¹) subcutaneously daily or silymarin (25 mg kg⁻¹) orally daily, for 14 days. Control rats were treated with olive oil (2.8 mL kg⁻¹ followed by 1.4 mL kg⁻¹ one week later) (n = 6). Two more groups (n = 6 each) received either saline or the higher dose of calcitonin (9 mg kg⁻¹, S.c.) but no CCl₄ daily for 14 days. The animals were killed on day 15 after the first dose of CCl₄ or olive oil administration. Rats had free access to food and drinking water during the study.

Biochemical Assessment

At the end of the experiments, blood samples were obtained from the retro-orbital vein plexuses, under ether anaesthesia. ALT and AST activities in serum were measured according to Reitman-Frankel colorimetric transaminase procedure (Crowley, 1976), whereas colorimetric determination of ALP activity was done according to the method of Belfield and Goldberg (1971), using commercially available kits (BioMérieux, France).

Histopathological Studies

After the end of the treatment period, rats were killed, livers were excised and fixed in 10% formalin saline. Sections were prepared and stained with hematoxylin and eosin (H and E) for histological investigation.

Statistical Analysis

All results are expressed as means±SE. Comparison of the values before and after CCl₄ was made by paired Student's t-test. Multiple group comparisons were performed by ANOVA followed by Duncan test. p<0.05 was considered statistically significant.

RESULTS

Biochemical Results

In rats treated with CCl₄, the levels of alanine aminotransferase (ALT), aspartate aminotransferase (AST) and alkaline phosphatase (ALP) in plasma were markedly raised by 341.8, 215.8 and 174.7% indicating the severity of hepatic injury and congestion caused by CCl₄ (Table 1). Calcitonin given to saline-treated (normal rats) at 9 mg kg⁻¹ had no significant effects on plasma levels of ALT, AST or ALP enzymes. Meanwhile, calcitonin given to CCl₄ treated rats at 2.25 mg kg⁻¹ reduced the elevated plasma ALT by 25.5%, but was without effect on plasma AST and ALP. Calcitonin at doses of 4.5 or 9 mg kg⁻¹ significantly decreased the raised plasma ALT by 49.3 and 72.4%, AST by 51.3 and 61%, ALP by 29.2 and 48.3%, respectively. In comparison, silymarin administered at the dose of 25 mg kg⁻¹ resulted in a marked and significant decrease of elevated ALT, AST and ALP levels by 72.6, 67.4 and 64.4%, respectively (Table 1).

Histopathological Results

The liver of saline control rats revealed the characteristic hepatic architecture (Fig. 1 and 2). The liver of rats subjected to CCl₄ showed distortion of the normal architecture of the liver tissue, vasodilatation, patchy areas of necrosis and hepatocyte degeneration, fibrosis (Fig. 3 and 4). Treatment of rats with calcitonin resulted in a dose-dependent protective effect. In rats given 2.25 mg kg⁻¹

Table 1 Effect of salmon calcitonin and silymarin on serum alanine Aminotransferase (ALT), Aspartate Aminotransferase (AST) and Alkaline Phosphatase (ALP) in CCl₄-treated rats

Treatments	ALT (IU L ⁻¹)	AST (IU L ⁻¹)	ALP (IU L ⁻¹)
Saline control	51.0±3.1*	70.4±2.5*	52.0±1.9*
+ Calcitonin 9 mg kg ⁻¹	54.8±2.1*	69.7±3.2*	50.8±2.6*
CCl ₄ control	225.3±9.0	222.3±3.0	142.6±6.8
+ Calcitonin 2.25 mg kg ⁻¹	167.9±5.5**	217.2±4.5	135.0±2.5
+ Calcitonin 4.5 mg kg ⁻¹	114.2±4.4**	108.3±4.1**	101.0±3.4**
+ Calcitonin 9.0 mg kg ⁻¹	62.1±5.7**	87.0±2.6**	73.7±8.1**
+ Silymarin 25 mg kg ⁻¹	61.6±3.4**	72.5±2.5**	50.8±2.6**

Results are means±S.E. Data were analyzed by one way ANOVA and means of different groups were compared by Duncan's multiple range test *p<0.05 compared with the CCl₄ control group +p<0.05 compared with calcitonin 2.25 mg kg⁻¹, treated group Rats treated with calcitonin 9 mg kg⁻¹ or silymarin showed significantly less ALT, AST and ALP values compared with the calcitonin 4.5 mg kg⁻¹, treated group

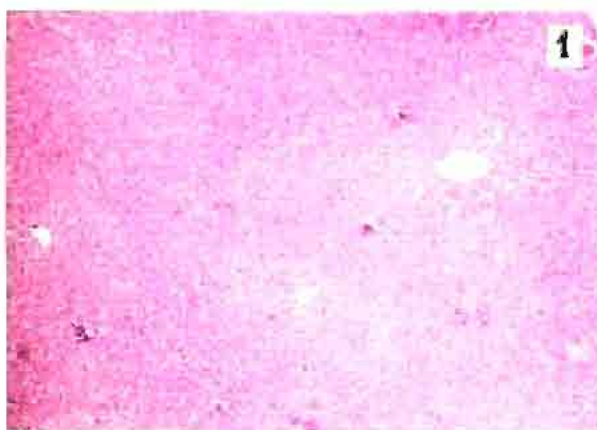


Fig. 1: A photomicrograph of a section of liver tissue of a control rat showing the central vein and the hepatocytes arranged in cords radiating from the central vein in an anastomosing manner to form a sponge-work or labyrinth. These cords are separated from each other by blood sinusoids, which are nearly equal in size. (Hx. and EX 60)

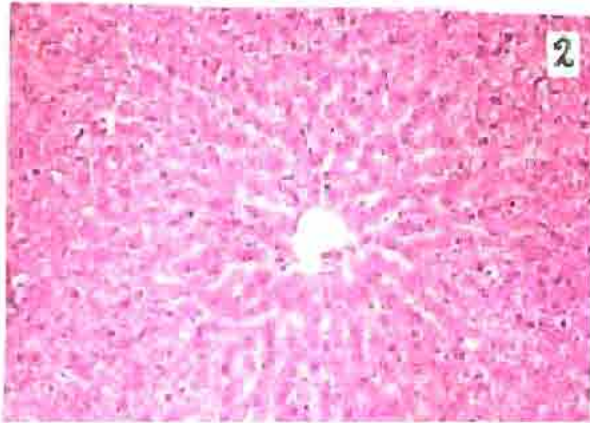


Fig. 2: A magnified photomicrograph of a liver section of a control rat showing the normal appearance of hepatocytes arranged in a series of branching and anastomosing perforated plates. The hepatocytes appear polyhedral in shape with clearly defined cell membranes. Their acidophilic cytoplasm takes a lace-like or granular appearance with clumps of basophilic material. The nuclei are large rounded or ovoid in shape. They are of the vesicular type with well-defined one or two nucleoli (Hx. and E. X 150)

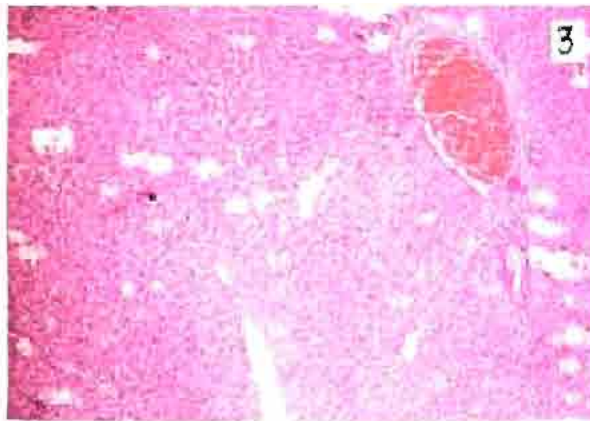


Fig. 3: A photomicrograph of a section of liver tissue of a rat given carbon tetrachloride showing distortion of the normal architecture of the liver tissue. There is severe dilatation of a blood vessel, which appeared congested with thickening of its wall. The liver parenchyma shows patchy areas of necrosis and hepatocyte degeneration. Fibrous strands begin to appear extending from the congested blood vessel in between the hepatocytes (Hx. and E. X 60)

calcitonin, some disturbance of the architecture of the liver tissue is still seen with marked dilatation of central vein, hepatic arteries and portal veins (Fig. 5 and 6). When rats were treated with calcitonin 4.5 mg kg^{-1} , there was restoration of the normal architecture of the liver tissue to a great extent with no dilatation of central veins (Fig. 7 and 8). Calcitonin administered at 9 mg kg^{-1} with CCl_4 , resulted in marked improvement in liver architecture (Fig. 9 and 10). No pathological changes could be noticed in liver sections from rats treated with calcitonin (9 mg kg^{-1}) alone (Fig. 11 and 12).

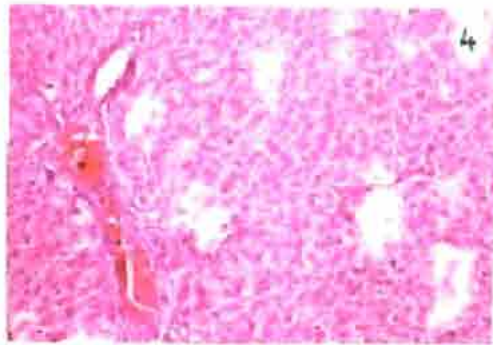


Fig 4 A magnified photomicrograph of the previous section showing dilated blood vessel. There is stagnation of blood in its lumen and thickening of its wall with some lymphocytic infiltration in this thickened wall. Multiple necrotic foci and fibrous bands appear among the parenchyma of the liver, although many hepatic cells are still having their normal appearance (Hx and E X 150)

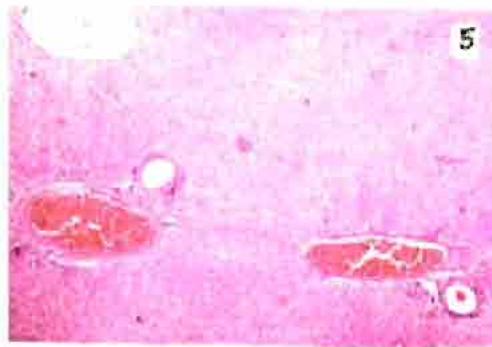


Fig 5 A photomicrograph of a section of liver tissue of a rat given carbon tetrachloride and calcitonin 2.25 mg kg^{-1} showing some disturbance of the architecture of the liver tissue, severe dilatation of central vein, severe dilatation in hepatic arteries and portal veins with congestion in portal veins (Hx and E X 60)

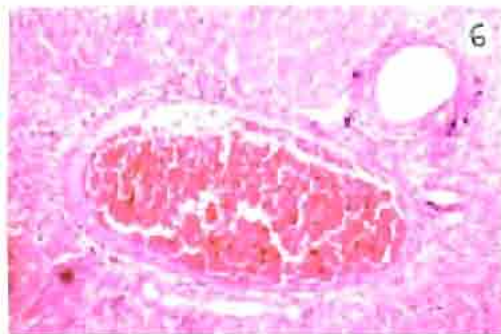


Fig 6 A magnified photomicrograph of the previous section showing a severely dilated portal vein with lymphocytic infiltration in its wall and stagnation of blood in its lumen. The hepatocytes around suffer from considerable membrane damage and fatty infiltration. The hepatic artery also shows dilatation (Hx and E X 150)

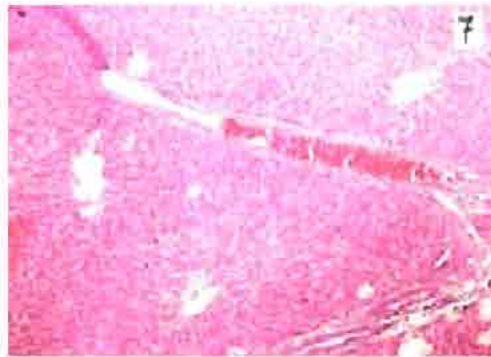


Fig 7 A photomicrograph of a section of liver tissue of a rat given carbon tetrachloride and calcitonin 4.5 mg kg^{-1} showing restoration of the normal architecture of the liver tissue to a great extent with no dilatation of central veins. However, marked fibrosis is seen in the right bottom of the photo with the formation of fibro-vascular membrane (abnormal fibrous band containing blood vessel, that is also dilated and congested with blood) (Hx. And E X 60)

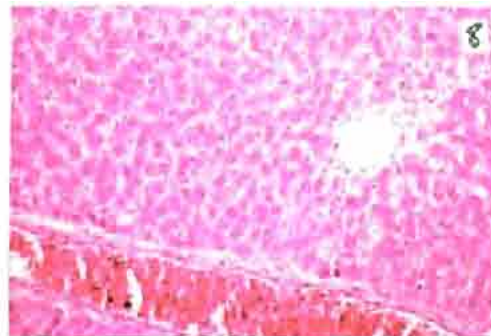


Fig 8 A magnified photomicrograph of the previous section showing a central vein of normal size, but with some lymphocytic infiltration around. At the bottom appear the collagen fibers, fibroblasts (arrow) and the blood vessel forming the fibro-vascular membrane. The hepatocytes restore their lace-like eosinophilic cytoplasm and their well-defined vesicular nuclei with prominent nucleoli. Very little number of cells are still suffering from fatty infiltration (Hx and E X 150)



Fig 9 A photomicrograph of a section of liver tissue of a rat given carbon tetrachloride and calcitonin 9 mg kg^{-1} showing more or less normal appearance of liver architecture and portal tract areas. A central vein which is slightly dilated, congested and having slightly thick wall is also seen. A regeneration nodule is seen at the right side (Hx. and E X 60)

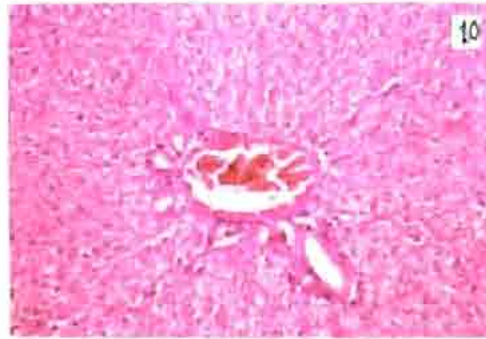


Fig 10 A magnified photomicrograph of the previous section showing a central vein that is slightly dilated, congested with slightly thickened wall. Remnants of fibro-vascular membranes are still present around the central vein. Most of the hepatocytes appear normal in size and shape, although some of them are still suffering from fatty degeneration (Hx and E X 150)

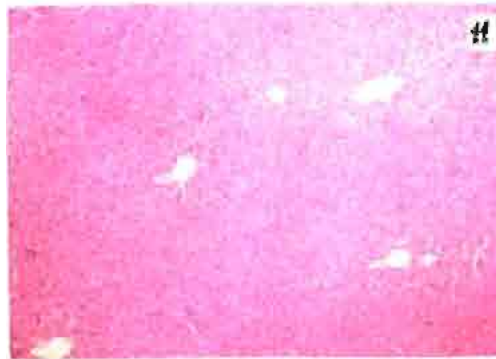

Fig 11 A photomicrograph of a section of liver tissue of a rat given calcitonin 9 mg kg^{-1} only without CCl_4 showing central veins that are nearly of normal size, from the plates of hepatocytes radiate. These plates are separated by fine blood sinusoids. Neither lymphocytic infiltration nor fibrosis is seen (Hx and E X 60)

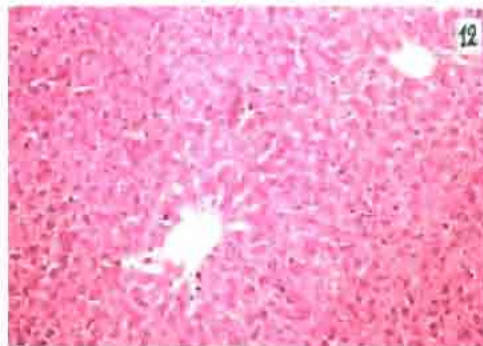


Fig 12 A magnified photomicrograph of the previous section showing a completely normal appearance of liver tissue. The blood vessels are of normal size, the hepatocytes have a lace-like appearance of eosinophilic cytoplasm and vesicular nuclei with well distinct nucleoli. The blood sinusoids are very fine in between the cells (Hx and E X 150)

DISCUSSION

Calcitonin is used in the management of a number of bone diseases characterised by excessive bone resorption. In patients with osteoporosis or vertebral fractures, calcitonin constitutes an important part in the management of these disease conditions. The present study was designed to investigate the effect of this hormone in a model of acute hepatic damage caused by the administration of the hepatotoxin CCl₄ to rats *in vivo*. The study demonstrated that the administration of calcitonin substantially protected the liver against damage induced by CCl₄. The effect of calcitonin was dose-dependent and evidenced by a significant decrease in the plasma levels of liver enzymes as well as by marked improvement in the liver architecture seen on histology.

Calcitonin shares structural similarities with calcitonin gene-related peptide (CGRP), adrenomedullin and amylin, forming a family of structurally and biologically related polypeptides. The calcitonin family of peptides are characterised by N-terminal ring structure linked by a disulfide bridge and an amidated C-terminus. Calcitonin gene-related peptide (CGRP) that is formed by alternative transcription of the calcitonin/alpha-CGRP gene, which also gives rise to calcitonin, is a neuromodulator that is involved in neurogenic inflammation, potent vasodilator (Brain *et al.*, 1985, 1986) and an inhibitor of gastric acid secretion (Morley *et al.*, 1981; Guglietta *et al.*, 1988). Amylin on the other hand, increases hepatic glucose output, inhibits insulin-stimulated glucose uptake and glycogen synthesis in skeletal muscle (Edwards and Morley, 1992). The calcitonin family of peptides, exhibits overlapping pharmacological actions. Adrenomedullin and amylin elicits vasodilator responses *in vivo* (Brain and Grant, 2004). Amylin mimics calcitonin in that it inhibits bone resorption, but in addition stimulates bone formation (Alam *et al.*, 1993; Cornish *et al.*, 1998).

Several lines of evidence link both calcitonin and CGRP to haemodynamic changes in liver disease. The levels of circulating calcitonin are increased in patients with liver cirrhosis most likely due to over expression of the calcitonin/alpha-CGRP gene and this latter accounts for elevated arterial compliance in cirrhosis. These changes seems to be related to the severity of disease (Henriksen *et al.*, 1999, 2000, 2001).

In experimental models of hepatic injury, CGRP released from sensory nerve terminals or administered via systemic routes protected the liver from a variety of insults. Thus, increasing hepatic tissue levels of CGRP, has been suggested to account for the hepatic protective effect of antithrombin against ischemia/reperfusion-induced liver injury through increased hepatic blood flow and a reduction in hepatic levels of tumor necrosis factor and myeloperoxidase activity (Harada *et al.*, 2005, 2006). The peptide inhibits local acute inflammation by inhibiting macrophage activation and neutrophil migration (Gomes *et al.*, 2005). In addition, CGRP has been shown to mediate hepatic cytoprotection induced by intracisternal TRH analog, since both systemic capsaicin pretreatment and intravenous administration of CGRP receptor antagonist, human CGRP-(8-37), completely abolished the protective effect of intracisternal TRH analog against CCl₄-induced acute liver injury (Yoneda *et al.*, 2003). On the other hand, hepatitis induced in alphaCGRP^{-/-}-mice by concanavalin A, was reduced by the administration of alpha-CGRP, which decreased the incidence of apoptosis among hepatocytes and endothelial cells (Kamiyoshi *et al.*, 2006).

Calcitonin gene-related peptides is a potent vasodilator in most vascular beds including the hepatic vascular bed (Brain *et al.*, 1986; Marshall *et al.*, 1988; Shimamura *et al.*, 2000; Hogestatt *et al.*, 2000). Calcitonin also has vasodilator properties (Moore *et al.*, 1986). Studies suggested that early vascular events were suggested to have a role in liver damage caused by CCl₄ (Tanaka *et al.*, 1999) and increased hepatic arterial blood flow may act to lessen CCl₄-induced acute hepatic injury (Tanaka *et al.*, 1999; Hsu *et al.*, 1993). Thus, by maintaining proper hepatic microcirculation through its vasodilator properties, CGRP or calcitonin most likely ameliorate microcirculatory perturbations in the liver induced by CCl₄.

REFERENCES

- Alam, A.S., B.S. Moonga, P.J. Bevis, C.L. Huang and M. Zaidi, 1993. Amylin inhibits bone resorption by a direct effect on the motility of rat osteoclasts. *Exp. Physiol.*, 78: 183-196.
- Belfield, A. and D.M. Goldberg, 1971. Revised assay for serum phenyl phosphatase activity using 4-amino-antipyrine. *Enzyme*, 12: 561-573.
- Blau, L.A., 2003. Analgesic efficacy of calcitonin for vertebral fracture pain. *Annal. Pharmacother.*, 37: 564-570.
- Brain, S.D., J.R. Tippins, H.R. Morris H.R.I. MacIntyre and T.J. Williams, 1986. Potent vasodilator activity of calcitonin gene-related peptide in human skin. *J. Invest. Dermatol.*, 87: 533-536.
- Brain, S.D., T.J. Williams, J.R. Tippins, H.R. Morris and I. MacIntyre, 1995. Calcitonin gene-related peptide is a potent vasodilator. *Nature*, 313: 54-56.
- Brain, S.D. and A.D. Grant, 2004. Vascular actions of calcitonin gene-related peptide and adrenomedullin. *Physiol. Rev.*, 84: 903-934.
- Chen, S., S. Morimoto, M. Tamatani, K. Fukuo, T. Nakahashi, A. Nishibe, B. Jiang and T. Ogihara, 1996. Calcitonin prevents CCl₄-induced hydroperoxide generation and cytotoxicity possibly through C1b receptor in rat hepatocytes. *Biochem. Biophys. Res. Commun.*, 218: 865-871.
- Cornish, J., K.E. Callon, C.Q.X. Lin, C.L. Xiao, T.B. Mulvey, D.H. Coy, G.J.S. Cooper and I.R. Reid, 1998. Dissociation of the effects of amylin on osteoblast proliferation and bone resorption. *Am. J. Physiol., Endocrinol. Metab.*, 274: E827-E833.
- Crowley, L.V., 1967. The Reitman-Frankel colorimetric transaminase procedure in suspected myocardial infarction. *Clin. Chem.*, 13: 482-487.
- Doftos, L.J., 1993. Calcitonin. In: *Primer on the Metabolic Bone Diseases and Disorders of Mineral Metabolism*. Favus, M.J. (Ed.), 2nd Edn., Raven Press, New York, pp: 70-76.
- Edwards, B.J. and J.E. Morley, 1992. Amylin. *Life Sci.*, 51: 1899-1912.
- Eiden, S., C. Daniel, A. Steinbrueck, I. Schmidt and E. Simon, 2002. Salmon calcitonin-a potent inhibitor of food intake in states of impaired leptin signalling in laboratory rodents. *J. Physiol.*, 541: 1041-1048.
- Gomes, R.N., H.C. Castro-Faria-Neto, P.T. Bozza, M.B. Soares, C.B. Shoemaker, J.R. David and M.T. Bozza, 2005. Calcitonin gene-related peptide inhibits local acute inflammation and protects mice against lethal endotoxemia. *Shock*, 24: 590-594.
- Guglietta, A., B.J. Irons and L.H. Lazarus, 1988. Effect of bombesin, dermorphin and salmon calcitonin on gastric acid secretion in rats. *Methods. Find. Exp. Clin. Pharmacol.*, 10: 481-485.
- Harada, N., K. Okajima, M. Yuksel and H. Isobe, 2005. Contribution of capsaicin-sensitive sensory neurons to antithrombin-induced reduction of ischemia/reperfusion-induced liver injury in rats. *Thromb. Haemost.*, 93: 48-56.
- Harada, N., K. Okajima, M. Uchiba, H. Kurihara and N. Nakagata, 2006. Antithrombin reduces reperfusion-induced liver injury in mice by enhancing sensory neuron activation. *Thromb. Haemost.*, 95: 788-795.
- Henriksen, J.H., S. Moller, S. Schifter and F. Bendtsen, 1999. Increased arterial compliance in decompensated cirrhosis. *J. Hepatol.*, 31: 712-718.
- Henriksen, J.H., S. Schifter, S. Moller and F. Bendtsen, 2000. Increased circulating calcitonin in cirrhosis. Relation to severity of disease and calcitonin gene-related peptide. *Metabolism*, 49: 47-52.
- Henriksen, J.H., S. Moller, S. Schifter, J. Abrahamsen and U. Becker, 2001. High arterial compliance in cirrhosis is related to low adrenaline and elevated circulating calcitonin gene related peptide but not to activated vasoconstrictor systems. *Gut*, 49: 112-118.

- Hogestatt, E.D., R. Johansson D.A. andersson and P.M. Zygmunt, 2000. Involvement of sensory nerves in vasodilator responses to acetylcholine and potassium ions in rat hepatic artery. *Br. J. Pharmacol.*, 130: 27-32.
- Holloway, W.R., F.M. Collier, R.E. Herbst, J.M. Hodge and G.C. Nicholson, 1997. Complex shape changes in isolated rat osteoclasts: Involvement of protein kinase C in the response to calcitonin. *Calcif. Tissue Int.*, 61: 306-312.
- Hsu, C.T., K. Schichijo, M. Ito and I. Sekine, 1993. The effect of chemical sympathectomy on acute liver injury induced by carbon tetrachloride in spontaneously hypertensive rats. *J. Auton. Nerv. Syst.*, 43: 91-96.
- Kamiyoshi, A., T. Sakurai, Y. Ichikawa-Shindo, J. Fukuchi, H. Kawate, S. Muto, Y. Tagawa and T. Shindo, 2006. Endogenous alphaCGRP protects against concanavalin A-induced hepatitis in mice. *Biochem. Biophys. Res. Commun.*, 343: 152-158.
- Marshall, I., S.J. Al-Kazwini, J.J. Holman and R.K. Craig, 1988. Human alpha-calcitonin gene-related peptide (CGRP) is a potent vasodilator in human mesenteric vasculature. *Br. J. Clin. Pharmacol.*, 26: 691-695.
- Martin, T.J., 1999. Calcitonin. An update. *Bone*, 24: 63S-65S.
- Moore, P.L., M.L. Strickland and M.F. Crass, 1986. Vasoactive characteristics of calcitonin in coronary and hepatic circulations. *J. Hypertens. Suppl.*, 4: S186-188.
- Morley, J.E., A.S. Levine and S.E. Silvis, 1981. Intraventricular calcitonin inhibits gastric acid secretion. *Science*, 214: 671-673.
- Paget, G.E. and J.M. Barnes, 1964. Toxicity Tests. In: *Evaluation of Drug Activities Pharmacometrics*. Laurence, D.R. and A.L. Bacharach (Eds.), London and New York: Academic Press, pp: 1-135.
- Sexton, P.M., 1991. Central nervous system binding sites for calcitonin and calcitonin gene-related peptide. *Mol. Neurobiol.*, 5: 251-273.
- Shimamura, K.K., Yamamoto, F. Sekiguchi, S. Sunano, S. Kimura and H. Saito, 2000. Transmural field stimulation-induced relaxation in the rat common hepatic artery. *J. Smooth. Muscle. Res.*, 36: 137-144.
- Tanaka, N., K. Tanaka, Y. Nagashima, M. Kondo and H. Sekihara, 1999. Nitric oxide increases hepatic arterial blood flow in rats with carbon tetrachloride-induced acute hepatic injury. *Gastroenterology*, 117: 173-180.
- Valenzuela, A. and A. Garrido, 1994. Biochemical bases of the pharmacological action of the flavonoid silymarin and of its structural isomer silibinin. *Biol. Res.*, 27: 105-112.
- Yoneda, M., Y. Sato, K. Nakamura, S. Yokohama, T. Kono, H. Watanobe and A. Terano, 2003. Involvement of calcitonin gene-related peptide and capsaicin-sensitive afferents in central thyrotropin-releasing hormone-induced hepatic cytoprotection. *Eur. J. Pharmacol.*, 478: 173-177.