



Journal of
**Pharmacology and
Toxicology**

ISSN 1816-496X



Academic
Journals Inc.

www.academicjournals.com

Effect of Combined Paracetamol and *Cuminum cyminum* or *Nigella sativa* Use in Wistar Rats

Einass M. Elhabib, M.M.A. Homeida and S.E.I. Adam
The Academy of Medical Sciences and Technology, P.O. Box 12810, Khartoum, Sudan

Abstract: *Cuminum cyminum* fruit or *Nigella sativa* seed, a traditional medicine for treatment of various disorders, was fed to male Wistar rats at 6% of standard rat diet for 4 weeks. A 6% *C. cyminum* fruit or 6% *N. sativa* seed diet was not toxic to rats. Depression in growth, hepatotoxicity and nephrotoxicity were observed in rats that had been given paracetamol at 500 mg kg⁻¹ per os for 4 weeks. These findings were accompanied by leucopenia, macrocytic normochromic anemia and alterations of serum aspartate aminotransferase (AST), alanine aminotransferase (ALT) and alkaline phosphatase (ALP) activities and concentrations of cholesterol, urea and other serum constituents. Serum bilirubin did not change. In rats given the mixture of paracetamol 500 mg kg⁻¹ plus 6% *C. cyminum* fruit or 6% *N. sativa* seed for 4 weeks, the recovery of paracetamol hepatotoxicity was evidenced by increase in body weight, absence of hepatocellular fatty vacuolation and significant improvement of serbiochemical and hematological parameters. There was no evidence of any antinephrotoxic activity of plants used.

Key words: *Cuminum cyminum*, *Nigella sativa*, antihepatotoxic activity

INTRODUCTION

Paracetamol (acetaminophen, N-acetyl-p-aminophenol) has been used increasingly as a substitute for other analgesics such as aspirin and phenacetin and its sales have in many countries exceeded those of aspirin. However, much publicity has been given to paracetamol poisoning in which the major target organ is the liver and the primary lesion is centrilobular hepatocellular necrosis (Mitchell, 1977; Prescott, 1983). Other reported complications of paracetamol poisoning include oliguric renal failure (Cobden *et al.*, 1982), pancreatitis and myocarditis (Wakeel *et al.*, 1987).

Severe hepatic necrosis was induced in mice, hamsters, cats and other species by paracetamol but species differences in susceptibility were observed and related to the extent of metabolic activation of the drug (Tee *et al.*, 1987). It has been found that paracetamol is converted by cytochrome P450 dependent mixed function oxidase to a reactive arylating metabolite, known as N-acetyl-p-benzoquinone imine (NAPQI) that may cause hepatic necrosis (Dahlin *et al.*, 1984) and a depletion of both mitochondrial and cytosolic pools of reduced glutathione (Tirmenstein and Nelson, 1989).

Cuminum cyminum L., a member of the family Umbelliferae, is locally known as Kamoon and its fruit is used in Sudan and other countries as antipyretic, antiseptic, antispasmodic, carminative, diuretic and emmenagogue and for the treatment of leprosy, leukoderma and scorpion stings due to the presence of volatile oil, flavonoids, monoterpenes, sesquiterpenes and probably other constituents (Haroun *et al.*, 2002; Ishikawa *et al.*, 2002).

Nigella sativa L. (Ranunculaceae) is also a multipurpose medicinal plant locally known as Black seed or Habat Al-Barakah and is used in traditional medicine as antiarthritic, antihelminthic, antiseptic, antispasmodic, appetizer, emmenagogue and nerve tonic and for the treatment of ascites, asthma and pustular dermatitis due to its content of alkaloid, volatile oil, saponins, sterols and quinones

(Al-Yahya, 1986; Daba and Abdel Rahman, 1998). *Nigella sativa* seed was fed to 7 day old Hibro broiler chicks at 2 and 10% of standard diet for 7 weeks and was not found to adversely affect growth (Al-Homidan *et al.*, 2002).

It is well known that a drug or plant may interact with another drug or plant and as a consequence modification in activity and/or toxicity can be observed. For example, the hepatoprotective effect of Kulthi, *Dolichos biflorus* on paracetamol induced liver toxicity was described in rats (Laskar *et al.*, 1998). On the other hand, chronic administration of ethanol to mice and hamsters was found to enhance the hepatotoxic effect of paracetamol (Zimmerman, 1986).

Because of the common use of *C. cyminum* fruit and *N.sativa* seed in the treatment of various ailments as well as the lack of information on their possible interactions with paracetamol we investigated the effect of paracetamol alone or combined with low levels of dietary *C. cyminum* fruit or *N.sativa* seed on the growth, organ pathology, hematological and serochemical parameters of Wistar rats.

MATERIALS AND METHODS

Paracetamol and Plant Material

Paracetamol produced by Amipharma Laboratories, Sudan, was purchased in a local pharmacy in Khartoum and used in this study.

Cuminum cyminum fruits and *Nigella sativa* seeds were purchased in a local market, ground separately to a fine powder and then mixed into a normal rat diet.

Study Design

Forty two 12 week old male Wistar rats were housed within the premises of the Medicinal and Aromatic Plants Research Institute, National Center for Research, Khartoum, under light/dark cycle with feed and drinking water provided *ad libitum*.

The rats were randomly allotted to 7 groups of 6 rats each. Rats in group1 were the controls and given untreated diet and water. Groups 2 and 3 received drinking water containing paracetamol at 500 mg L⁻¹ or diet containing paracetamol at 500 mg kg⁻¹, respectively. Groups 4 and 5 received diet containing 6% (w/w) of *C. cyminum* fruit or 6% (w/w) *N. sativa* seed, respectively. Groups 6 and 7 received a diet that contained a mixture of paracetamol at 500 mg kg⁻¹ and 6% (w/w) of *C. cyminum* fruit or paracetamol at 500 mg kg⁻¹ and 6% (w/w) of *N. sativa* seed, respectively.

Average body weight and body weight gain were estimated weekly for each group. After 2 weeks of treatment, 3 randomly selected rats from each group were killed under diethyl ether anesthesia. The remaining 3 rats/group were similarly killed after 4 weeks of treatment. Blood samples were collected from each of the killed rats for hematology and serum chemistry.

Blood Analyses

Erythrocytes (RBC), leukocytes (WBC), differential WBC counts, hemoglobin (Hb) concentration, Packed Cell Volume (PCV), Mean Corpuscular Volume (MCV), Mean Corpuscular Hemoglobin (MCH) and Mean Corpuscular Hemoglobin Concentration (MCHC) were evaluated (Schalm *et al.*, 1975). Serum samples were analyzed for the activities of aspartate aminotransferase (AST), alanine aminotransferase (ALT) and alkaline phosphatase (ALP) and concentrations of total protein, albumin, cholesterol, bilirubin and urea by commercial kits (Linear Chemicals, Barcelona, Spain). Serum globulin was estimated by subtracting albumin from total protein concentration.

Pathological Examinations

Post-mortem findings were recorded for all rats and specimens of intestines, liver, spleen, kidneys and heart were fixed in 10% neutral buffered formalin, embedded in paraffin wax, sectioned at 5 µm and stained with hematoxylin and eosin (H and E).

Statistical Analysis

The significance of differences between means was compared at each time point using Duncan's multiple range tests after ANOVA for one-way classified data (Snedecor and Cochran, 1989).

RESULTS

Changes in Growth

The rats given paracetamol in drinking water at 500 mg L⁻¹ (group 2) or in the diet at 500 mg kg⁻¹ (group 3) had the lowest (p<0.05) body weight but none of the rats died during the 4-week period. The rats fed diets containing mixture of paracetamol at 500 mg kg⁻¹ plus 6% *C. cyminum* (group 6) or paracetamol at 500 mg kg⁻¹ plus 6% *N. sativa* (group 7) had the highest (p<0.05) body weight.

Pathological Changes

After 2 weeks of treatment, no macroscopic or microscopic changes were observed in the vital organs of the rats on the 6% *C. cyminum* (group 4), 6% *N. sativa* (group 5), paracetamol at 500 mg kg⁻¹ plus 6% *C. cyminum* (group 6) and paracetamol at 500 mg kg⁻¹ plus 6% *N. sativa* (group 7) or the control rats (group 1). Individual cell necrosis and small fatty vacuoles in the centrilobular hepatocytes and degeneration of the epithelial cells of scattered proximal convoluted tubules of the rats on paracetamol in drinking water at 500 mg L⁻¹ (group 2) or paracetamol at 500 mg kg⁻¹ diet (group 3).

In groups 2 and 3, the main lesions observed at 4 weeks of treatment were necrosis and cytoplasmic fatty vacuolation of the centrilobular hepatocytes (Fig. 1), dilatation or necrosis of the renal proximal convoluted tubules (Fig. 2) and congestion of the cardiac blood vessels. Neither the spleen nor the intestine showed significant changes. No lesions were detected in the liver, heart, spleen, intestines or kidneys of groups 4 and 5. In groups 6 and 7, necrosis of the centrilobular hepatocytes was not seen and the intensity of cytoplasmic fatty vacuolation of the liver cell was reduced in some of the rats. In these groups, the renal lesions persisted and other vital organs showed no abnormality.

Hematological Changes

These data are summarized in Table 1. In the rats given paracetamol in drinking water at 500 mg L⁻¹ (group 2) or at similar concentration in the diet (group 3) for 2 weeks, there were decreases

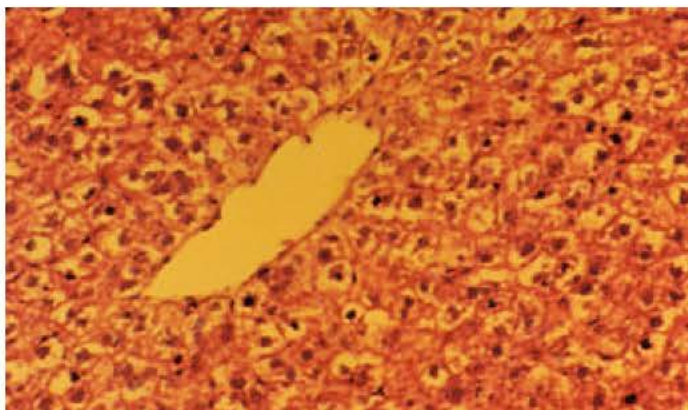


Fig. 1: Fatty vacuolation and necrosis of the centrilobular hepatocytes in a rat given paracetamol at 500 mg kg⁻¹ diet for 4 weeks. H and E X200

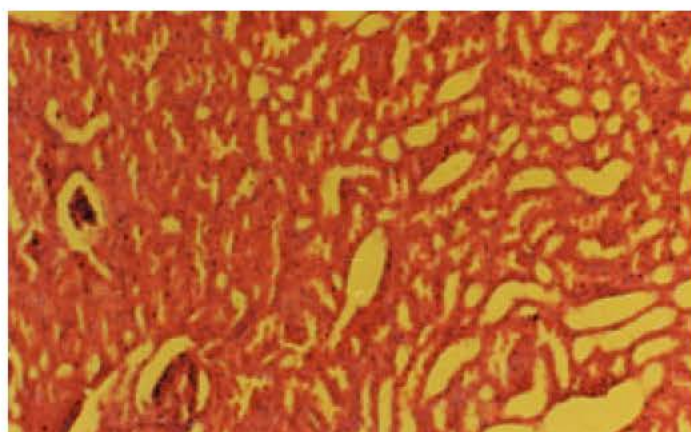


Fig. 2: Dilatation of the proximal convoluted tubules and packing of the glomerular tufts in a rat given paracetamol at 500 mg kg⁻¹ diet for 4 weeks. H and E X100

Table 1: Hematologic changes in rats given paracetamol alone or combined with *C. cyminum* fruit or *N. sativa* seed for 4 weeks

Parameters	Groups						
	1 Control	2 Paracetamol 500 mg L ⁻¹	3 Paracetamol 500 mg kg ⁻¹	4 <i>C. cyminum</i> 6%	5 <i>N. sativa</i> 6%	6 <i>C. cyminum</i> 500 mg kg ⁻¹ 6%+Paracetamol	7 <i>N. sativa</i> 500 mg kg ⁻¹ 6%+Paracetamol
Two weeks							
RBC (x10 ⁶ mm ³)	7.5±0.9a	6.5±0.4b	6.2±0.3b	6.9±0.5ab	6.3±0.3b	6.9±0.6ab	6.7±0.5ab
PCV (%)	34.5±0.3a	23.7±0.2b	27.5±0.4ab	33.0±0.5a	29.5±0.4ab	34.5±0.4a	33.3±0.3a
Hb (g dL ⁻¹)	11.5±0.7a	10.1±0.6ab	9.1±0.3b	11.0±0.7a	9.8±0.6ab	11.5±0.5a	11.1±0.8a
MCV (m ³)	47.9±1.5ab	36.5±2.3c	44.4±1.7b	47.8±2.1ab	46.8±1.4ab	50.0±2.3a	49.7±1.6a
MCHC (%)	33.3±0.9b	42.6±0.8a	33.1±1.3b	33.3±1.5b	33.7±1.9b	33.3±1.6b	33.3±0.9b
MCH (pg)	15.9±0.3a	15.5±0.5ab	14.7±0.6b	15.9±1.9ab	15.6±1.5ab	16.7±0.8a	16.6±0.3a
WBC (x10 ³ mm ³)	8.4±0.8ab	9.5±1.1a	10.5±0.7a	9.3±1.6a	8.6±1.2ab	7.7±0.9b	8.5±0.8ab
Neuts (%)	41.3±2.1a	38.2±1.3ab	36.5±0.9b	39.6±0.7a	40.3±1.1a	39.3±0.6a	37.2±1.2ab
Lymphs (%)	58.7±2.3b	61.8±0.9a	63.5±2.1a	60.4±1.9ab	59.7±1.2ab	60.7±1.2ab	62.8±2.1a
Four weeks							
RBC (x10 ⁶ mm ³)	7.9±0.9a	6.2±0.3b	6.3±0.4b	7.6±0.8a	7.5±0.6a	6.9±0.6ab	7.6±0.7a
PCV (%)	37.5±0.4a	35.3±0.3b	38.0±0.5a	36.6±0.3ab	36.3±0.3ab	37.0±0.3a	37.3±0.4a
Hb (g dL ⁻¹)	12.5±1.3a	11.8±0.9a	12.7±1.2a	12.2±1.5a	12.1±0.8a	12.4±0.7a	12.3±0.7a
MCV (m ³)	47.5±2.1b	56.9±1.9ab	60.3±2.2a	48.2±0.9b	48.4±0.8b	53.6±1.2ab	49.1±1.2b
MCHC (%)	33.3±0.9a	33.4±1a	33.4±0.9a	33.2±0.4a	33.3±0.9a	33.5±0.6a	33.0±0.7a
MCH (pg)	15.8±0.3b	17.8±0.5a	18.9±0.5a	16.1±0.4ab	16.1±0.4ab	17.9±0.6a	16.2±0.5ab
WBC (x10 ³ mm ³)	8.4±0.9a	6.5±0.8ab	5.9±0.6b	7.9±1.1a	8.1±0.8a	7.8±0.9a	8.1±0.8a
Neuts (%)	44.1±2.1a	36.0±1.9ab	28.2±0.9b	45.0±2.2a	39.8±1.3ab	28.0±1.2b	34.0±0.9ab
Lymphs (%)	55.9±1.6b	64.0±1.9ab	71.8±2.1a	55.0±1.4b	60.2±1.8ab	72.0±2.2a	66.0±1.8ab

Values are means±SE. Means within rows with no common letter(s) are significantly different (p<0.05)

in RBC, PCV and neutrophils and increases in MCV, WBC and lymphocytes. After 4 weeks of treatment, the change in erythrocytic series persisted but WBC and neutrophils decreased and those of MCHC did not change. There were no adverse effects on the blood parameters of the rats fed diets containing 6% *C. cyminum* fruit (group 4) or 6% *N. sativa* seed (group 5) for 2 or 4 weeks. Although lymphocytosis was seen, no significant changes were observed in the rats fed the mixture of paracetamol at 500 mg kg⁻¹ and 6% *C. cyminum* fruit (group 6) or of paracetamol at 500 mg kg⁻¹ and 6% *N. sativa* seed diets (group 7) for 2 or 4 weeks. The control rats showed no hematologic changes.

Table 2: Serobiochemical changes in rats given paracetamol alone or combined with *C. cyminum* fruit or *N. sativa* seed for 4week

Parameters	Groups						
	1	2	3	4	5	6	7
	Control	Paracetamol mg L ⁻¹	Paracetamol 500 mg kg ⁻¹	<i>C. cyminum</i> 6%	<i>N. sativa</i> 6%	Paracetamol+ <i>C. cyminum</i> 500 mg kg ⁻¹ +6%	Paracetamol+ <i>N. sativa</i> 500 mg kg ⁻¹ +6%
Two weeks							
ALT (iu)	27.0±3.2b	45.0±1.9a	48.0±1.8a	24.5±2.1b	26.0±2.2b	28.0±1.9b	30.0±0.9ab
AST (iu)	21.0±2.9b	35.0±0.7a	45.0±0.5a	23.0±1.7b	24.0±1.8b	30.0±0.9ab	28.0±1.8ab
ALP (iu)	68.0±1.7b	82.5±1.2a	99.0±1.7a	65.0±3.2b	69.0±2.1b	65.0±3.1b	81.0±0.7ab
T. protein (g dL ⁻¹)	8.5±0.4a	7.6±0.3ab	7.3±0.3b	8.3±0.4a	7.9±0.3a	8.2±0.3a	7.3±0.4b
Albumin (g dL ⁻¹)	5.2±0.2a	4.6±0.9b	4.5±0.2b	4.8±0.4a	4.6±0.1b	4.4±0.1b	4.5±0.2b
Globulin (g dL ⁻¹)	3.3±0.1ab	3.0±0.1ab	2.8±0.1b	3.5±0.2a	3.3±0.1ab	3.8±0.1a	2.8±0.1b
Cholesterol (mg dL ⁻¹)	135.0±2.1b	149.0±0.8ab	160.0±0.9a	140.0±2.3b	133.0±3.1b	149.0±2.1ab	152.0±3.1ab
Bilirubin (mg dL ⁻¹)	0.2±0.01b	0.5±0.01a	0.6±0.02a	0.3±0.01b	0.2±0.01b	0.4±0.2ab	0.4±0.02ab
Urea (mg dL ⁻¹)	27.0±2.8b	39.6±0.9 ab	45.0±1.2a	25.3±3.1b	29.3±3.3b	36.0±0.6a	33.0±2.8b
Four weeks							
ALT (iu)	23.4±2.6c	68.6±1.9ab	108.0±2.1a	30.0±1.2a	35.0±1.1b	46.0±1.2b	41.0±1.4b
AST (iu)	20.0±1.2c	46.5±1.4ab	92.0±2.1a	33.0±1.7b	28.0±1.4b	50.0±2.1ab	56.0±1.9ab
ALP (iu)	70.0±1.9b	92.0±1.1ab	105.0±1.8a	69.0±2.2b	75.0±0.2b	89.0±1.3ab	79.0±2.2b
T. protein (g dL ⁻¹)	8.7±0.3a	6.6±0.2b	5.4±0.1a	6.9±0.2b	7.6±0.2ab	7.5±0.3ab	7.9±0.4ab
Albumin (g dL ⁻¹)	5.4±0.2a	4.1±0.1ab	2.9±0.1b	3.0±0.2b	3.6±0.3ab	4.1±0.2ab	3.9±0.3ab
Globulin (g dL ⁻¹)	3.3±0.2ab	2.5±0.1b	2.5±0.1b	3.9±0.3a	4.0±0.3a	3.4±0.2ab	4.0±0.4a
Cholesterol (mg dL ⁻¹)	130.0±1.9b	164.0±1.9a	148.0±1.1ab	134.0±1.2b	126.0±2.1b	142.0±1.2ab	145.0±1.9ab
Bilirubin (mg dL ⁻¹)	0.3±0.1b	0.7±0.02a	0.6±0.02a	0.3±0.01b	0.3±0.01b	0.3±0.01b	0.3±0.01b
Urea (mg dL ⁻¹)	29.5±1.7b	49.0±1.3a	52.0±2.1a	33.0±1.2b	29.4±1.7b	36.0±1.6ab	39.5±1.4ab

Values are means±SE. Means within rows with no common letter(s) are significantly different (p<0.05)

Serobiochemical Changes

These data are presented in Table 2. In groups 2 and 3, there were increases in the activities of serum AST, ALT and ALP and in concentrations of cholesterol and urea and decreases in the levels of total protein and albumin over the 4-week period. Bilirubin concentration did not change. No significant changes in serum constituents of rats in groups 4 and 5 were observed after 4 weeks of treatment. In groups 6 and 7 there were increases in enzyme activities, urea and cholesterol concentrations without bilirubinemia during the 4-week period. No significant serobiochemical changes were observed in the control (group 1).

DISCUSSION

The 7 day pre-trial period was aimed at achieving body weight uniformity, acclimatizing rats to the Medicinal and Aromatic Plants Research Institute environment and allowing unhealthy ones to be eliminated before the commencement of the experiment.

It is well known that the susceptibility of animals to feeding plant materials is dependent, at least, on the type of the active constituents and concentration in the amount added to the diet as well as on the rate of their metabolic conversion in the liver to metabolites and consequent excretion. For rats, the dietary levels (2 and 10%) represented non-toxic concentrations of plants exemplified by *Thymus vulgaris* (Haroun *et al.*, 2002) and similarly for chickens by *N. sativa* (Al-Homidan *et al.*, 2002). On the other hand, levels of 2% or more of dietary *Francoeuria crispa*, *Artemisia abyssinica* and *Ammi visnaga* have been toxic to rodents and chickens (Adam, 1998; Adam *et al.*, 2000; Ibrahim *et al.*, 2004).

In the present study, the differences in mean body weights between the rats on 6% *C. cyminum* and 6% *N. sativa* diets as compared to controls became larger with time over the 4 week period. The higher growth rate of *C. cyminum* and *N. sativa*-fed rats was most likely to have been due to the absence of adverse effects but may have been associated with a high protein and fat content of the plant materials. However, further work would be required to determine the amino acid and fatty acid profiles of the plant tissues.

The fact that body weights were decreased in rats given paracetamol alone suggests the impairment of growth and decrease in its rate of excretion by the injured liver and kidneys. The elevated activity of serum ALT, AST and ALP and cholesterol level and hypoproteinemia along with liver lesions, indicate paracetamol hepatotoxicity in rats. Nephrotoxicity was a feature of paracetamol toxicity in rats as evidenced by the presence of renal lesions and of an increase in urea concentration in serum. Hepatonephrotoxicity may account for the reduced growth rate in rats given paracetamol singly. Centrilobular hepatocellular necrosis produced by paracetamol in laboratory rodents was described by Wynne *et al.* (1987).

The damage to the centrilobular hepatocytes without significant bilirubinemia or icterus was observed in rats which had been fed *Francoeuria crispa* (Adam, 1998) or *Artemisia abyssinica* (Adam *et al.*, 2000). On the other hand, bilirubinemia or icterus followed by damage to the periportal hepatocytes and proliferation of the bile ducts was detected in the rats on *Rhazya stricta* diet (Adam, 1999).

The increased MCV without effect on MCHC indicate macrocytic normochromic anemia. Previous studies showed macrocytic anemia in rats fed 10% *A. abyssinica* (Adam *et al.*, 2000) and chicks fed 10% *Cassia italica* (Bakhiet and Adam, 1996). These findings suggest the involvement of plant constituents in derangement of the haematopoietic process. Leukopenia notable in the rats given paracetamol singly was due to neutropenia.

The centrilobular hepatocellular necrosis was less marked or unobservable in the rats given the mixture of paracetamol plus *C. cyminum* fruits or *N. sativa* seeds for 4 weeks. In some instances, cytoplasmic fatty vacuolation of the centrilobular hepatocytes was depicted in rats given the mixture of paracetamol plus *C. cyminum* fruits or *N. sativa* seeds for similar periods. Research would be required to verify the role in the antihepatotoxic activity of *C. cyminum* fruits or *N. sativa* seeds.

Although serum urea concentration was decreased, histopathological examination did not provide evidence of an antinephrotoxic effect of the plants. Laskar *et al.* (1998) described antihepatotoxic activity of the plant, *Dolichos biflorus*, against paracetamol induced hepatotoxicity in rats and suggested that biotransformation of paracetamol into a nephrotoxic compound, p-aminophenol, is responsible for elevation of blood urea nitrogen.

We conclude that the seeds of *N. sativa* and the fruits of *C. cyminum* were not toxic to Wistar rats at the concentration used in the test diets.

The hepatotoxicity of paracetamol in rats was evidenced by consistently lowered body weights, pathological changes and significant serobiochemical and hematological alterations. Nephrotoxicity of paracetamol was described in rats.

Antihepatotoxic activity of *N. sativa* seed and *C. cyminum* fruits against paracetamol hepatotoxicity was supported by improvement of body weights, less intense hepatocellular damage and correlation with serobiochemical and hematological changes.

Further investigations into the appropriate isolation, characterization and concentration of the active constituents in *C. cyminum* fruit and *N. sativa* seed are deemed necessary for elucidating their antihepatotoxic activity against paracetamol hepatotoxicity in rats.

REFERENCES

- Adam, S.E.I., 1998. Toxic effects of *Francoeuria crispa* in rats. *Phytother. Res.*, 12: 476-479.
- Adam, S.E.I., 1999. Experimental *Rhazya stricta* toxicosis in rats. *Vet. Hum. Toxicol.*, 41: 5-8.
- Adam, S.E.I., A.A. Al-Qarawi and E.A. Elhag, 2000. Effects of various levels of dietary *Artemisia abyssinica* leaves on rats. *Lab. Animal*, 34: 307-312.
- Al-Homidan, A., A.A. Al-Qarawi, S.A. Al-Waily and S.E.I. Adam, 2002. Response of broiler chicks to dietary *Rhazya stricta* and *Nigella sativa*. *Br. Poult. Sci.*, 43: 291-296.

- Al-Yahya, M.A., 1986. Phytochemical studies of the plants used in traditional medicine of Saudi Arabia. *Fitoterapia*, 57: 179-182.
- Bakhiet, A.O. and S.E.I. Adam, 1996. Toxicity to *Bovans chicks* of *Cassia italica* seeds. *Phytother. Res.*, 10: 156-160.
- Cobden, I., C.O. Record, M.K. Ward and D.N.S. Kerr, 1982. Paracetamol-induced acute renal failure in the absence of fulminant liver damage. *Br. Med. J.*, 284: 21-22.
- Daba, B. and M. Abdel Rahman, 1998. Hepatoprotective activity of thymoquinone in isolated rat hepatocytes. *Toxicol. Lett.*, 95: 23-29.
- Dahlin, D.C., G.T. Miwa, A.Y.H. Lu and S.D. Nelson, 1984. N-acetyl- p- benzoquinone imine: A cytochrome P-450 mediated oxidation product of acetaminophen. *Proc. Natl. Acad. Sci. (USA)*, 81: 1327-1331.
- Haroun, E.M., O.M. Mahmoud and S.E.I Adam, 2002. Effects of feeding *Cuminum cyminum* fruits, *Thymus vulgaris* leaves or their mixture to rats. *Vet. Hum. Toxicol.*, 44: 67-69.
- Ibrahim, I.A., S.M.A. El-Badawi, W.S. Abdel Gadir, A.O. Bakhiet, S.O. Yagoub and S.E.I Adam, 2004. Susceptibility of Bovans chicks to low dietary levels of *Ammi visnaga* and *Artemisia herba-alba*. *Vet. Hum. Toxicol.*, 46: 67-69.
- Ishikawa, T., T. Takatanagi and J. Kitajima, 2002. Water-soluble constituents of Cumin: Monoterpenoid glycosides. *Chem. Pharm. Bull.*, 50: 1471-1478.
- Laskar, S., U.K. Bhattacharyya, A. Sinhababu and B.K.C. Basak, 1998. Anti-hepatotoxic activity of Kulthi (*Dolichos biflorus*) seed in rats. *Fitoterapia*, 69: 401-402.
- Mitchell, J.R., 1977. Host susceptibility and acetaminophen liver injury. *Ann. Intl. Med.*, 87: 377-388.
- Prescott, L.F., 1983. Paracetamol overdose: Pharmacological considerations and clinical management. *Drugs*, 25: 290-314.
- Schalm, O.W., N.C. Jain and G.H. Carroll, 1975. *Veterinary Hematology*, 3rd Edn., Lea and Febiger, Philadelphia.
- Snedecor, G.W. and W.C. Cochran, 1989. *Statistical Methods*, 8th Edn., Iowa State University Press, Ames, Iowa.
- Tee, L.B.G., D.S. Davies, C.E. Seddon and A.R. Boobis, 1987. Species differences in the hepatotoxicity of paracetamol are due to differences in the rate of conversion to its cytotoxic metabolite. *Biochem. Pharmacol.*, 36: 1041-1052.
- Tirmenstein, M.A. and S.D. Nelson, 1989. Subcellular binding and effects on calcium homeostasis produced by acetaminophen and a non-hepatotoxic regioisomer, 3-hydroxyacetanilide in mouse liver. *J. Biol. Chem.*, 264: 9814-9819.
- Wakeel, R.A., H.T. Davies and J.D. Williams, 1987. Toxic myocarditis in paracetamol poisoning. *Br. Med. J.*, 295: 1097.
- Wynne, H., D.N. Bateman, F. Hassanyeh, M.D. Rawlins and K.W. Woodhouse, 1987. Age and self-poisoning: The epidemiology in Newcastle-upon-Tyne. *Hum. Toxicol.*, 6: 511-515.
- Zimmerman, H.J., 1986. Effects of alcohol on other hepatotoxins. *Alcoholism: Clin. Exp. Res.*, 10: 3-15.