



Journal of
**Pharmacology and
Toxicology**

ISSN 1816-496X



Academic
Journals Inc.

www.academicjournals.com

Anti-arthritic Effects of an Ethanolic Extract of *Capparis erythrocarpos* Isert Roots in Freund's Adjuvant-induced Arthritis in Rats

Cynthia Amaning Danquah, Eric Woode and Eric Boakye-Gyasi

Department of Pharmacology, Faculty of Pharmacy and Pharmaceutical Sciences, College of Health Sciences, Kwame Nkrumah University of Science and Technology, Kumasi, Ghana

*Corresponding Author: Eric Woode, Department of Pharmacology, Faculty of Pharmacy and Pharmaceutical Sciences, College of Health Sciences, Kwame Nkrumah University of Science and Technology, Kumasi, Ghana
Tel: +233 244 589793*

ABSTRACT

Capparis erythrocarpos (Capparaceae) is a medicinal plant used traditionally in Ghana and other parts of Africa for the management of various inflammatory and pain conditions without any scientific validation. The aim of this study, therefore was to provide scientific evidence for the use of this plant as an anti-arthritic agent using the Freund's Adjuvant-induced arthritis in rats, a chronic inflammatory model which mimics rheumatoid arthritis in humans. Arthritis was induced by injection of Complete Freund's Adjuvant into the right paw of Sprague-Dawley rats and paw volume was measured by water displacement plethysmography. Dexamethasone and methotrexate were used as reference drugs. The results obtained show that treatment with the extract (30 mg kg⁻¹; p.o.) significantly suppressed adjuvant-induced arthritis with maximal inhibitions of 34.19±15.73% and also significantly prevented the spread of arthritis from the ipsilateral to the contralateral paw. Higher doses of the extract (100 and 300 mg kg⁻¹; p.o.) did not show significant inhibition of arthritis. Methotrexate (0.1-1.0 mg kg⁻¹) and dexamethasone (0.3-3 mg kg⁻¹) significantly and dose-dependently inhibited polyarthritis and completely prevented the spread of arthritis to the contralateral paws. Adjuvant-induced arthritis was ameliorated by the combined effect of *C. erythrocarpos* (100 mg kg⁻¹; p.o.) and dexamethasone (1 mg kg⁻¹; i.p.) as well as *C. erythrocarpos* (100 mg kg⁻¹; p.o.) and methotrexate (0.3 mg kg⁻¹; i.p.). From the results, *C. erythrocarpos* had anti-arthritic effect and the effect shown is comparable to that of methotrexate. This provides a validation for the traditional use of the plant in managing rheumatoid arthritis.

Key words: Inflammation, Complete Freund's Adjuvant, synovitis, plethysmograph

INTRODUCTION

The inflammatory response forms the basis of several pathological and pathophysiological processes including wound healing, rheumatoid arthritis, atherosclerosis and neurodegenerative disorders (Kapoor *et al.*, 2005). The processes that underlie the phenomenon of inflammation are now better understood and so are the modes of action of drugs that are used to treat it.

Acute and chronic inflammatory processes are a major threat to human health and play an important role in the development of various diseases. Natural compounds or compounds derived from natural leads can be used for treatment of inflammatory processes and there are records from traditional medical systems of plants being used for such purposes (Balunas and Kinghorn, 2005).

Acute inflammation is a rapid response to an injurious agent that serves to deliver mediators of host defense to the site of injury. Its main characteristics are the exudation of fluid and plasma proteins (oedema) and the emigration of leukocytes predominantly neutrophils (Hurley and Willoughby, 1973; Pulichino *et al.*, 2006). Acute inflammatory reactions are triggered by a variety of stimuli such as infections (Bacterial, viral, parasitic and microbial toxins); physical and chemical agents (burns, irradiation and environmental chemicals acute inflammatory reactions, in contrast to chronic inflammatory reactions, are usually self-limiting and resolve (Willoughby *et al.*, 1969).

Chronic inflammation occurs when acute inflammation remains unresolved. It is the reaction arising when the acute response is insufficient to eliminate the pro-inflammatory agents. It is of longer duration and is associated histologically with the presence of lymphocytes and macrophages, the proliferation of blood vessels, fibrosis and tissue necrosis (Agarwal and Brenner, 2006). Chronic inflammation occurs in the following settings: Persistent infections by certain microorganisms (e.g., tubercle bacilli, virus, fungi and parasites); prolonged exposure to potentially toxic agents and auto immunity (Mullazehi *et al.*, 2007).

Rheumatoid Arthritis (RA) is an autoimmune, chronic inflammatory disorder characterized by joint swelling, synovial inflammation and joint destruction (Feldmann *et al.*, 2005; Campo *et al.*, 2003; Pakozdi *et al.*, 2006). It usually causes pain, swelling, stiffness and loss of function in the joints. In many patients, the disease is relentlessly progressive, resulting ultimately in joint destruction, leading to significant disability (Zhao *et al.*, 2006; Meyer *et al.*, 2006). The inflammatory response in rheumatoid arthritis is manifested by an acute inflammatory exudate of neutrophils into the synovial space and chronic inflammation of the synovial tissues; leucocytes are attracted into the synovial space to phagocytose the antigen-antibody-complement complexes and in doing so they liberate lysosomal enzymes that damage tissues including cartilage (Fairhurst *et al.*, 2007). Macrophages in the hypertrophied synovial tissue are stimulated to produce proteases and collagenases which contribute further to the destruction of collagen and bone (Bonnet *et al.*, 1993). RA develops as a result of interaction of many factors which include genetic (inherited) factors, environmental (viral or bacterial) factors and hormonal factors (Weissmann, 2006; Akaogi *et al.*, 2006). A variety of tools are used to diagnose RA and these include; medical history, physical examination, laboratory test (rheumatoid factor, white blood cell count and erythrocyte sedimentation rate, measurement of C-reactive proteins) and X-rays (Caspi *et al.*, 2006; Reinhart, 2006; Bradbeer *et al.*, 1996; Wu *et al.*, 2007). The goals of managing arthritis are basically the same no matter what treatment approach is chosen; these are to relieve pain, reduce inflammation, slow down or stop joint damage and improve a sense of well-being and ability to function (Smolen *et al.*, 2005; Atzeni and Sarzi-Puttini, 2007).

Capparis erythrocarpos (Capparaceae) is used by traditional medical practitioners in treating inflammatory conditions in Ghana. It is an indigenous plant which forms a dense impenetrable bush and is commonly called salt bush or capers. Locally it is known in Ashanti as woresentakyiame (salute me when passing), Ewe *aggo* (thorns), Fante okyerabran (giant catcher), Ga *agmagma*, Twi *apana* (Irvine, 1961; Mshana *et al.*, 2000).

Capparis erythrocarpos has multiple traditional uses mostly related to inflammation and pain. The dried root powder is added to beverage or soup and taken once or twice daily for treating rheumatoid arthritis, rheumatism and swellings of the joint, the core of the root is macerated and the liquid used for conjunctivitis, blurred vision, otitis and ear pain. It is also used to treat urinogenital pain and mastitis (Abbiw, 1990). Scientific information on this plant species is scarce. Woode *et al.* (2009a) reported on the antinociceptive effect of *Capparis erythrocarpos* isert roots.

However, other medicinal plants that are being used traditionally have been validated scientifically to have anti-arthritic effects (Abotsi *et al.*, 2010; Woode *et al.*, 2008, 2009a, b).

The fact that traditional health care and the use of medicinal plants is familiar, affordable and available at the local level is enough evidence to suggest that it will continue to play an important role in national healthcare delivery of most countries well into the twenty-first century. This study reports on the anti-arthritic effect of the ethanolic root extract using a curative protocol (i.e., effect of drug on established arthritis), prophylactic protocol (pre-emptive) and combination therapy in Freund's adjuvant-induced arthritis model.

MATERIALS AND METHODS

Plant material and extraction: Roots of the plant *C. erythrocarpos* were obtained and authenticated at the Centre for Scientific Research into Plant Medicine (CSRPM), Mampong-Akwapim, Ghana and a voucher specimen (No. FP /08/024) was kept in the Faculty of Pharmacy herbarium. Chopped roots were sun-dried for 4 days and powdered using a hammer mill. The root powder (5 kg) was cold macerated with 70% (v/v) ethanol over a period of 6 days and the filtrate was concentrated under reduced pressure and low temperature of 60°C in a rotary evaporator to obtain a brown syrupy mass which was air-dried at room temperature (29°C) for 24 h producing a dark brown semi-solid. The final yield was (450 g; 9% w/w). This was kept in a desiccator and is subsequently referred to as CEE or the extract.

Animals: Sprague-Dawley rats of both sexes (120-200 g) were purchased from Noguchi Memorial Institute for Medical Research, University of Ghana, Legon, in August, 2007 and housed in the animal facility in the Department of Pharmacology, Kwame Nkrumah University of Science and Technology (KNUST), Kumasi. The animals were housed in groups of six in stainless steel cages (34×47×18 cm) with soft wood shavings as bedding, fed with normal commercial pellet diet (GAFCO, Tema) and given water ad libitum and maintained under laboratory conditions (temperature 24-28°C, relative humidity 60-70% and 12 h light-dark cycle). All procedures and techniques used in this study were in accordance with the National Institute of Health Guidelines for the Care and Use of Laboratory Animals (NIH, Department of Health and Human Services publication No. 85-23, revised 1985) and were approved by the Departmental Ethics Committee (reference No. P/col/C12^B). The entire study was conducted in the Department of Pharmacology, Kwame Nkrumah University of Science and Technology (KNUST), Kumasi, between April 2007 and October 2008.

Drugs: Methotrexate sodium was purchased from Dabur Pharma, India and dexamethasone sodium phosphate from Pharm-Inter, Brussels Belgium.

Phytochemical analysis: The presence of saponins, tannins, alkaloids, triterpenes, flavonoids, glycosides and reducing sugars were tested by simple qualitative methods of Trease and Evans (1989) and Sofowara (1993).

Induction of arthritis: Adjuvant arthritis was induced as previously described by Pearson (1956) and Woode *et al.* (2008). Briefly, animals were injected intraplantar with 0.1 mL of complete Freund's adjuvant (CFA) into the right hind paw of each rat. The CFA was prepared using a suspension of 5 mg mL⁻¹ of heat-killed *Mycobacterium tuberculosis* [strains C, DT and PN (mixed) obtained from the Ministry of Agriculture, Fisheries and Food, UK] in paraffin oil. Animals were assigned to groups of five animals. Arthritic control group received only intraplantar injection of

CFA, whilst non-arthritic control/IFA group received only intraplantar injection of 0.1 mL incomplete Freund's adjuvant (IFA) (sterile paraffin oil).

Capparis erythrocarpos extract (30, 100 and 300 mg kg⁻¹), dexamethasone (0.3, 1.0 and 3 mg kg⁻¹) and methotrexate (0.1, 0.3 and 1 mg kg⁻¹) were administered to rats in the various groups, respectively.

Foot volume was measured by water displacement plethysmography (Fereidoni *et al.*, 2000) for both the ipsilateral (injected paw) and the contralateral paw (non-injected paw) before intraplantar injection of CFA (day 0) and every other day (day 2, 4, 6, 8,...28). The oedema component of inflammation was quantified by measuring the difference in foot volume between day 0 and the various days.

Effect of extract and reference drugs on adjuvant-induced oedema: Three sets of experiments were carried out to study the effect of:

- The test drugs on established arthritis (curative protocol)
- Test drugs when given before inducing arthritis (prophylactic protocol)
- Combining dexamethasone or methotrexate with extract (combination therapy)

In the curative protocol, intraplantar injection of 0.1 mL CFA was followed by drug administration on day 9 with the onset of arthritis.

The animals were grouped as follows:

- Group 1:** Arthritic control/CFA (intraplantar injection of 0.1 mL CFA)
Group 2: Non-arthritic control/IFA (intraplantar injection of 0.1 mL of IFA)
Groups 3-5: Dexamethasone (0.3, 1.0 and 3 mg kg⁻¹ i.p.) from day 9 and administered every other day
Group 6-8: Methotrexate (0.1, 0.3 and 1 mg kg⁻¹ i.p.) from day 9 and administered every 4 days
Group 9-11: *Capparis erythrocarpos* extract (30, 100 and 300 mg kg⁻¹ p.o.) from day 9 and administered every day

In the prophylactic protocol, drugs were administered on day 0 and CFA was injected intraplantar 24 h later. Based on preliminary studies done in the laboratory the median dose was selected for the extract as well as the standard drugs. The animals were grouped as follows:

- Group 1:** Arthritic control/CFA (intraplantar injection of 0.1 mL of CFA)
Group 2: Non-arthritic control/IFA (intraplantar injection of 0.1 mL of IFA)
Group 3: Dexamethasone 1.0 mg kg⁻¹ i.p. administered from day 0
Group 4: Methotrexate 0.3 mg kg⁻¹ i.p. administered from day 0
Group 5: *C. erythrocarpos* extract 100 mg kg⁻¹ p.o. administered from day 0

The combination groups were as follows:

- Group 6:** Dexamethasone 1 mg kg⁻¹ + *C. erythrocarpos* 100 mg kg⁻¹
Group 7: Methotrexate 0.3 mg kg⁻¹ + *C. erythrocarpos* 100 mg kg⁻¹
Group 8: Dexamethasone 1 mg kg⁻¹ + methotrexate 0.3 mg kg⁻¹

Raw scores for ipsilateral and contralateral paw volumes were individually normalized as percentage of change from their values at day 0 and then averaged for each treatment group. The extract was suspended in 2% tragacanth mucilage, whilst the reference drugs were dissolved in normal saline. All drugs were freshly prepared and test drugs were prepared such that doses were administered in volumes not exceeding 10 mL kg⁻¹.

Arthritis score: The arthritis score was evaluated blindly by the same person in all the rats on day 29. The severity of arthritis of each paw was scored as described by Kinne *et al.* (1995) according to the extent of erythema, oedema of the periarticular tissues, as well as deformity of the joints using a scale of 0-4. The arthritis score of each rat on day 0 was determined to be 0.

Photographs: Photographs of the affected hind limbs were taken on day 29 using a digital camera (Sony DCR-DVD 705E, Tokyo Japan).

Radiography: Radiographs of the hind limbs were obtained from all the animals on day 29. The animals were anaesthetized with chloroform. Radiographs were taken with a UMB type 2 x-ray unit (Softex Ltd., Tokyo, Japan) and industrial x-ray film (Fuji Photo Film, Tokyo, Japan). The x-ray apparatus was operated at 30 kV peak and 10-s exposure with a 45 cm tube-to-film distance for lateral projections. The severity of bone and joint destruction was scored blindly by the same person for each hind limb, according to the extent of osteoporosis, osteophytes, joint spaces and joint structure, as described by Pohlers *et al.* (2007). The severity of bone destruction of each paw was scored using a scale of 0-4. The radiological score for normal control rats was determined to be 0 and the average score from each group was determined.

The hind paw volume and the average arthritis score from each group of five rats were used as the measurement parameters of inflammation.

Analysis of data: Data was presented as the effect of drugs on the time course and the total oedema response of adjuvant-induced arthritis for the 28 day period. A sample size of five (n = 5) was used in all the experiments. The time-course curves for paw volume were subjected to two-way (treatment×time) repeated measures analysis of variance with Bonferroni's post hoc t test.

Total foot volume for each treatment was calculated in arbitrary unit as the Area Under the Curve (AUC) and to determine the percentage inhibition for each treatment, Eq. 1 below was used:

$$\% \text{ inhibition of oedema} = \left(\frac{\text{AUC}_{\text{control}} - \text{AUC}_{\text{treatment}}}{\text{AUC}_{\text{control}}} \right) \times 100 \quad (1)$$

Differences in AUCs were analyzed by ANOVA followed by Student-Newman-Keuls' post hoc test. Dose responsible for 50% of the maximal effect (ED₅₀) for each drug was determined using an iterative computer least squares method, with the following nonlinear regression (three-parameter logistic) (Eq. 2):

$$Y = \frac{a + (b - a)}{\left(1 + 10^{(\text{LogED}_{50} - X)} \right)} \quad (2)$$

where, X is the logarithm of dose and Y is the response. Y starts at a (the bottom) and goes to b (the top) with a sigmoid shape.

The fitted midpoints (ED_{50} s) of the curves were compared statistically using F test (Miller, 2003; Motulsky and Christopoulos, 2003). GraphPad Prism for Windows version 4.03 (GraphPad Software, San Diego, CA, USA) was used for all statistical analysis and ED_{50} determinations. The $p < 0.05$ was considered statistically significant.

RESULTS AND DISCUSSION

Phytochemical analysis: Phytochemical screening revealed the presence of alkaloids and flavonoids as predominant chemical constituents in the crude extract.

Effect of drugs on adjuvant-induced arthritis: Intraplantar injection of CFA into the right paw of rat produced a biphasic response; an acute phase characterized by unilateral inflammatory oedema of the ipsilateral (injected) paw from days 0-6, followed by subsequent polyarthritic/chronic phase response which began around day 10 characterized by inflammatory oedema of the contralateral paw. Throughout the experiment there was no significant change in the paw volume of the non-inflamed control group which received only intraplantar injection of IFA.

Two-way ANOVA (treatment x time) showed a significant effect of drug treatment. Total oedema produced by each treatment is expressed in arbitrary as AUC of the time-course curves.

Curative protocol: In the curative protocol, CEE (30-300 mg kg^{-1}) modified the time course of adjuvant-induced arthritis. Treatment with CEE 30 mg kg^{-1} showed marked anti-arthritic effect; it significantly ($F_{3,16} = 4.25$, $p = 0.02$) suppressed paw swelling in the polyarthritic phase and elicited the highest inhibition of $34.19 \pm 15.73\%$ (Fig. 1a). The extract, 30 mg kg^{-1} , also significantly ($F_{3,16} = 4.28$, $p = 0.02$) prevented the spread of the oedema from the ipsilateral to the contralateral paw however, CEE 300 mg kg^{-1} did not exhibit significant anti-arthritic effect ($p > 0.05$) (Fig. 1b).

Dexamethasone (0.3-3 mg kg^{-1}), significantly ($F_{3,16} = 96.91$, $p < 0.0001$) and dose-dependently inhibited polyarthritis with a maximal inhibition of $91.59 \pm 2.06\%$ (Fig. 1c). It also completely wiped out the spread of the arthritis from the ipsilateral to the contralateral paws of the treated animals (Fig. 1d).

Methotrexate (0.1-1.0 mg kg^{-1}), dose-dependently reduced the oedema in the ipsilateral paw (Fig. 1e) and also completely prevented the spread of the arthritis with a high level of significance ($F_{3,16} = 21.57$, $p < 0.0001$) (Fig. 1f).

From the dose response curves (Fig. 2) and the ED_{50} values (Table 1), CEE was approximately 86.8 times less potent than methotrexate and 323.5 times less potent than dexamethasone. This means that dexamethasone showed the greatest potency followed by methotrexate and the extract.

Prophylactic protocol: The effect of CEE (100 mg kg^{-1}), dexamethasone (1 mg kg^{-1}) and methotrexate (0.3 mg kg^{-1}) is shown in (Fig. 3a-d). CEE alone did not have significant effect in both the acute ($p > 0.05$) and the polyarthritic ($p > 0.05$) phase. Methotrexate alone did not show significant effect in both the acute ($p > 0.05$) and the polyarthritic phase ($p > 0.05$); dexamethasone however, exhibited some significant effect in the polyarthritic phase ($p < 0.001$).

Combination protocol: Results from the combination therapy suggest that, there was significant amelioration of AIA by CEE + dexamethasone and CEE + methotrexate as compared to

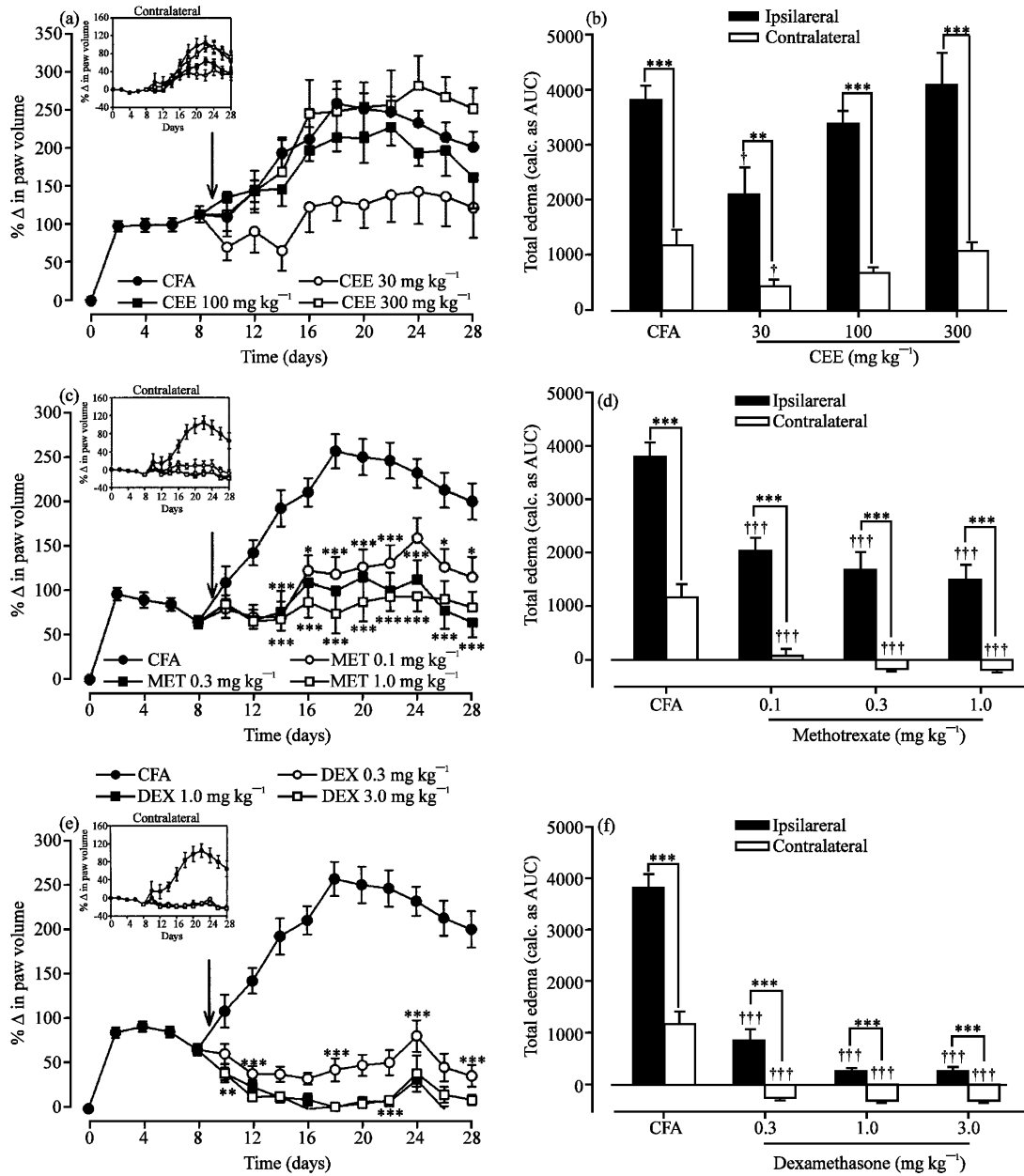


Fig. 1: Time course effects of CEE (30-300 mg kg⁻¹), dexamethasone (0.3-3.0 mg kg⁻¹)¹ and methotrexate (0.1-1.0 mg kg⁻¹) on CFA-induced increase in the ipsilateral paw volume (a, c and e), increase in the contralateral paw volume (insert) and the AUC (total oedema) (b, d and f), respectively, for 28 days. Each point and column represents the mean±SEM (n = 5). ***p<0.001; **p<0.01; *p<0.05 compared to vehicle-treated group (Two-way ANOVA followed by Bonferroni's post hoc test). †p<0.05; ††p<0.01; †††p<0.001 compared to vehicle-treated group (One-way ANOVA followed by Neuman-Keul's post hoc test)

administration of CEE alone. There was a significant inhibition of arthritis in both the acute (p<0.05) and the polyarthritis (p<0.001) phase when the extract was combined with dexamethasone. In combination with methotrexate, there was no significant effect in the acute

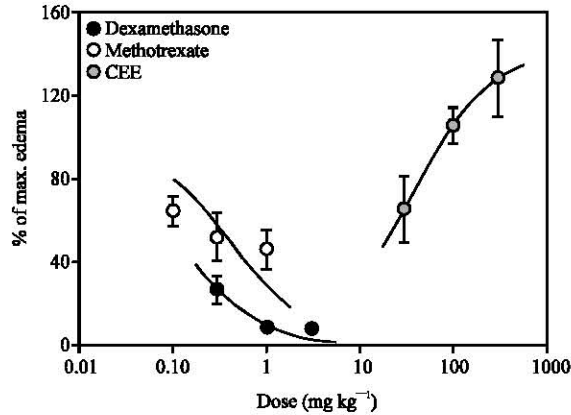


Fig. 2: Dose response curves for CEE, dexamethasone and methotrexate on CFA-induced arthritis. Each point represents the Mean±SEM (n = 5)

Table 1: ED₅₀ values for Adjuvant-induced arthritis

Drugs	ED ₅₀ (mg kg ⁻¹)
Dexamethasone	0.11±0.02
Methotrexate	0.41±0.14
<i>C. erythrocarpos</i>	35.59±15.73

Table 2: Arthritic scores of rats treated with CFA/arthritis control, IFA/non arthritic control, *C. erythrocarpos* (30-300) mg kg⁻¹, methotrexate (0.1-1.0) mg kg⁻¹ and dexamethasone (0.3-3) mg kg⁻¹ using the curative protocol

Groups	Pictures		X-Ray	
	Ipsilateral	Contralateral	Ipsilateral	Contralateral
IFA	0.6±0.2***	0.2±0.2***	0.6±0.2***	0.2±0.2***
CFA	4.0±0.0 ^{ns}	3.6±0.2 ^{ns}	4.0±0.0 ^{ns}	3.6±0.2 ^{ns}
<i>C. erythrocarpos</i> extract				
30 mg kg ⁻¹	1.4±0.2***	1.2±0.2***	1.4±0.2***	1.2±0.2***
100 mg kg ⁻¹	2.6±0.2**	1.6±0.2***	2.6±0.2**	1.6±0.2***
300 mg kg ⁻¹	3.8±0.2 ^{ns}	2.8±0.2*	3.8±0.2 ^{ns}	2.8±0.2*
Methotrexate				
0.1 mg kg ⁻¹	2.0±0.0***	1.2±0.2***	2.0±0.0***	1.2±0.2***
0.3 mg kg ⁻¹	1.4±0.2***	1.2±0.2***	1.4±0.2***	1.2±0.2***
1.0 mg kg ⁻¹	0.6±0.2***	0.6±0.2***	0.6±0.2***	0.6±0.2***
Dexamethasone				
0.30 mg kg ⁻¹	1.2±0.2***	0.4±0.2***	1.2±0.2***	0.4±0.2***
1.0 mg kg ⁻¹	0.2±0.2***	0.2±0.2***	0.2±0.2***	0.2±0.2***
3.0 mg kg ⁻¹	0.0±0.0***	0.0±0.0***	0.0±0.0***	0.0±0.0***

Each point represents the Mean±SEM (n = 5). ***p<0.001, **p<0.01, *p<0.05 compared to vehicle-treated group (One-way ANOVA followed by Bonferroni's post hoc test)

phase (p>0.05) but significant inhibition (p<0.05) occurred in the polyarthritic phase. Dexamethasone in combination with methotrexate gave the greatest inhibition in the acute (F_{3,16} = 4.274, p = 0.02) and the polyarthritic phase (F_{3,16} = 17.43, p<0.0001) which were extremely significant (Fig. 3a-d).

Arthritic scores from pictures: Results of the arthritic score for the curative protocol (Table 2) and the prophylactic protocol (Table 3) showed significant ($p < 0.001$, $p < 0.01$, $p < 0.05$) scores for the arthritic groups with wide spread erythema and increased hind paw swelling particularly for the extract (300 mg kg^{-1}) as well as CFA group and lower scores for the anti-arthritic groups (i.e., extract 30 mg kg^{-1} , dexamethasone, methotrexate and IFA) (Table 2). Combination of the extract with dexamethasone and methotrexate also recorded lower scores than when the extract and

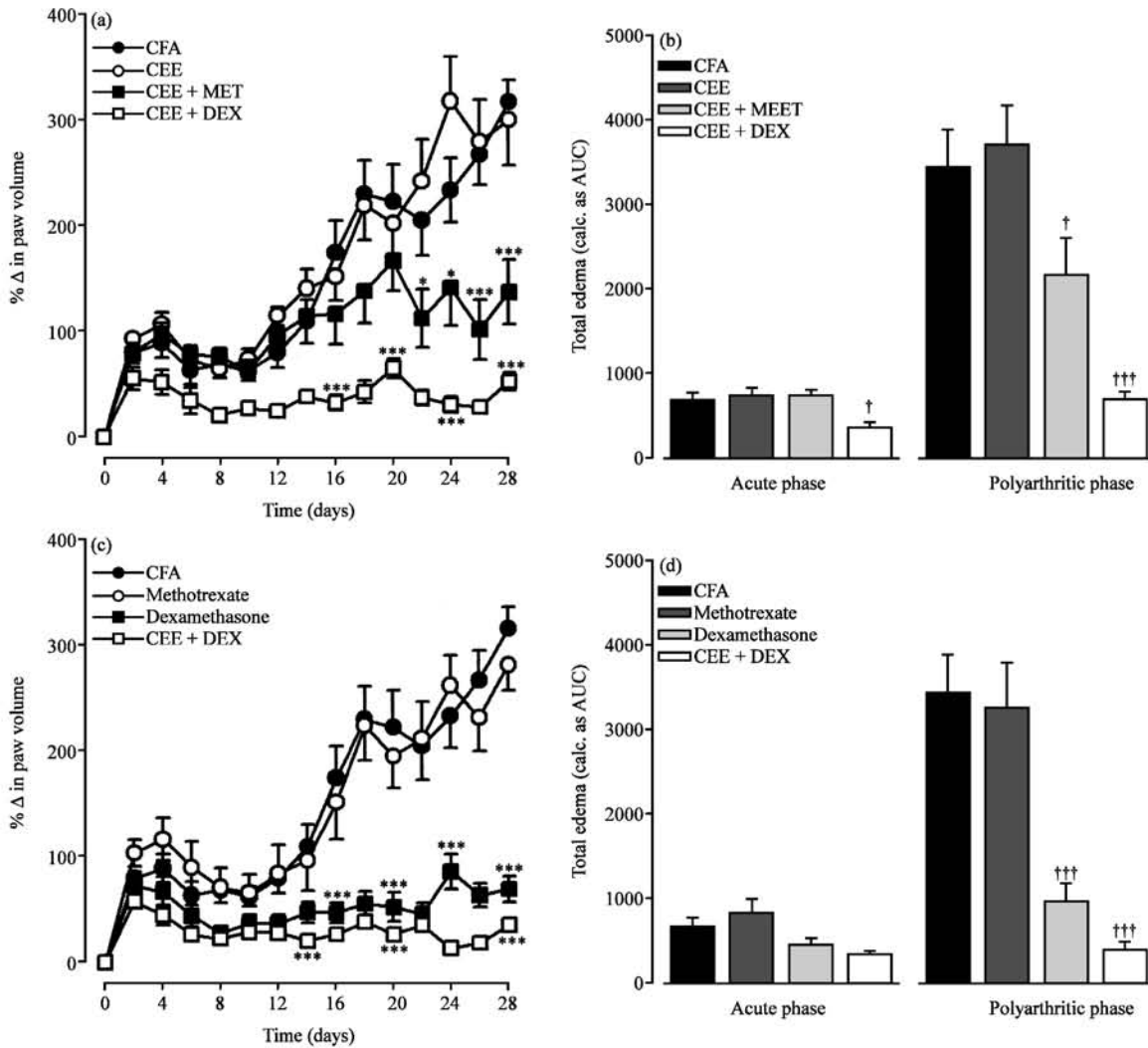


Fig. 3: Time course effects of *C. erythrocarpos* 100 mg kg^{-1} , *C. erythrocarpos* 100 mg kg^{-1} + methotrexate 0.3 mg kg^{-1} and *C. erythrocarpos* 100 mg kg^{-1} + dexamethasone 1.0 mg kg^{-1} (a) methotrexate 0.3 mg kg^{-1} , dexamethasone 1.0 mg kg^{-1} and methotrexate 0.3 mg kg^{-1} + dexamethasone 1.0 mg kg^{-1} (c) on CFA induced increase in the ipsilateral paw volume and the AUC (total oedema) (b and d) for 28 days in the acute and polyarthritic phase. Each point in (a and c) and column in (b and d) represents the Mean \pm SEM ($n = 5$). *** $p < 0.001$, ** $p < 0.01$, * $p < 0.05$ compared to vehicle-treated group (Two-way ANOVA followed by Bonferroni's post hoc test). ††† $p < 0.001$; † $p < 0.05$ compared to vehicle-treated group (One-way ANOVA followed by Neuman-Keul's post hoc test)

Table 3: Arthritic scores of rats pre treated with *C. erythrocarpos* 100 mg kg⁻¹, Methotrexate 0.3 mg kg⁻¹ and Dexamethasone 1 mg kg⁻¹ using the prophylactic and combination protocol

Groups	Pictures		X-Ray	
	Ipsilateral	Contralateral	Ipsilateral	Contralateral
IFA	0.6±0.2***	0.2±0.2***	0.6±0.2***	0.2±0.2***
CFA	3.8±0.2 ^{ns}	3.8±0.2 ^{ns}	3.8±0.2 ^{ns}	3.8±0.2 ^{ns}
<i>C. erythrocarpos</i> 100 mg kg ⁻¹	3.6±0.2 ^{ns}	2.4±0.2**	3.6±0.2 ^{ns}	2.4±0.2**
Methotrexate 0.3 mg kg ⁻¹	2.6±0.2*	1.0±0.32***	2.6±0.2*	1.0±0.32***
Dexamethasone 1 mg kg ⁻¹	0.8±0.2***	0.0±0.0***	0.8±0.2***	0.0±0.0***
Methotrexate 0.3 mg kg ⁻¹ + dexamethasone 1 mg kg ⁻¹	0.4±0.2***	0.2±0.2***	0.4±0.2***	0.2±0.2***
Methotrexate 0.3 mg kg ⁻¹ + <i>C. erythrocarpos</i> 100 mg kg ⁻¹	0.6±0.2***	0.6±0.2***	0.6±0.2***	0.6±0.2***
Dexamethasone 1 mg kg ⁻¹ + <i>C. erythrocarpos</i> 100 mg kg ⁻¹	0.8±0.2***	1.0±0.0***	0.8±0.2***	1.0±0.0***

Each point represents the Mean±SEM (n = 5). ***p<0.001, **p<0.01, *p<0.05 compared to vehicle-treated group (One-way ANOVA followed by Bonferroni's post hoc test)

reference drugs were administered alone (Table 3). This is clearly depicted by the photographs of the representative from each group (Fig. 4a-h).

Radiographs: Representative radiographs of the hind paws from each group are shown in (Fig. 5a-e). For CEE (30 mg kg⁻¹) and IFA/non arthritic all the bones were intact whilst there was reduced bone density, excessive bone resorption and bone loss for CEE (300 mg kg⁻¹) and CFA/arthritic control. Dexamethasone and methotrexate in combination with the extract suppressed the pathological changes seen in AIA in a dose-dependent manner.

Adjuvant-Induced Arthritis (AIA) in rats is suggested as a convenient model for preclinical studies of drugs affecting human arthritis as well as non-steroidal anti-inflammatory drugs and disease-modifying anti-rheumatic drugs (Pearson, 1956; Whitehouse, 2007) and has often been used to study the mechanism of action and preventive effects of a number of disease-modifying anti-rheumatic drugs (Hoffmann *et al.*, 1997). The development of rat adjuvant-induced arthritis can be divided into three phases just like human rheumatoid arthritis starting with the induction phase without evidence of synovitis, followed by early synovitis and finally late synovitis with progressive joint destruction (Malaviya, 2006; Narendhirakannan *et al.*, 2007; Pine *et al.*, 2007). A good anti-rheumatic agent should be able to suppress one or more of these phases.

This study has demonstrated that oral treatment of rats with ethanolic extract of *Capparis erythrocarpos* roots exhibit potent anti-arthritic properties in adjuvant-induced arthritis when administered curatively, prophylactically or in combination with standard anti-rheumatic drugs. *C. erythrocarpos* (30 mg kg⁻¹) suppressed joint inflammation and also prevented the systemic spread of arthritis and ultimately reduced the destruction of the joints. Joint protection plus suppression of synovitis are known to be the ultimate goals of a better rheumatoid arthritis treatment (Atzeni and Sarzi-Puttini, 2007; Hoffmann *et al.*, 1997) and the extract achieved these goals. Pro-inflammatory activity was however exhibited by the highest dose of *C. erythrocarpos* (300 mg kg⁻¹) and this could be attributed to the presence of other compounds in the crude extract which possibly masked the anti-inflammatory activity.

In Rheumatoid Arthritis (RA), combination therapy gives a better remission of disease than monotherapy (Capell *et al.*, 2007; Mottonen *et al.*, 2006; Sokka *et al.*, 2005). A number of disease modifying anti rheumatic drugs in monotherapy often have unexpected side effects and combined

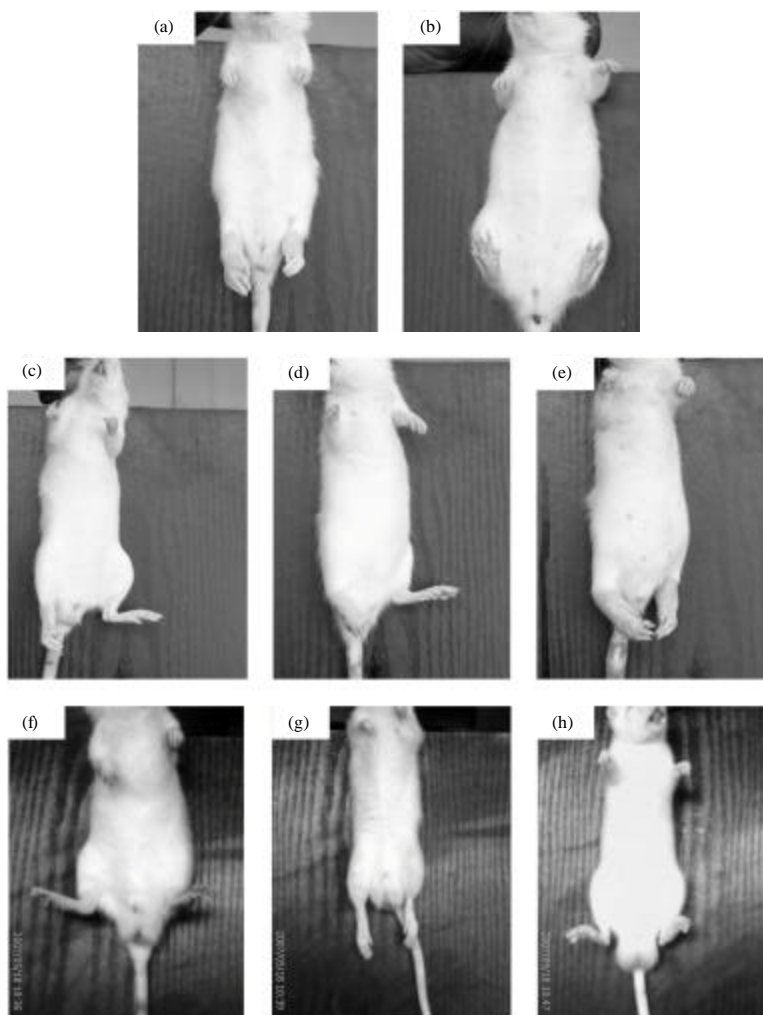


Fig. 4: Photograph of rats treated with CFA/arthritis control (a), IFA/non arthritic (b), *C. erythrocarpos* extract (30, 100 and 300 mg kg⁻¹) (c, d and e) in the curative protocol and rats pre treated with a combination of *C. erythrocarpos* + dexamethasone, *C. erythrocarpos* + methotrexate and dexamethasone + methotrexate (f, g and h), respectively

treatment at lower doses are necessary in order to expand the margin between efficacy and toxicity (Hisadome *et al.*, 2004; Kimel *et al.*, 2008; Makinen *et al.*, 2007). Hence, the increased interest in developing new agents from natural sources which can conveniently be used in combination with other anti rheumatic drugs and will be less toxic and at the same time effective for preventing joint destruction as well as synovial inflammation thus increasing efficacy of the treatment for patients with RA. Interestingly, *C. erythrocarpos* in combination with dexamethasone or methotrexate had strong inhibitory effect on arthritis in rats; it synergistically suppressed the increase in hind paw volume and joint destruction and produced a better remission of AIA than when the extract alone was administered. *Capparis erythrocarpos* as seen from this study can be a useful and better agent for rheumatoid arthritis when used in combination therapy.

In agreement with already existing data, both dexamethasone and methotrexate inhibited AIA and completely wiped out the spread of arthritis (Issekutz and Issekutz, 1991; Ochaion *et al.*, 2006;

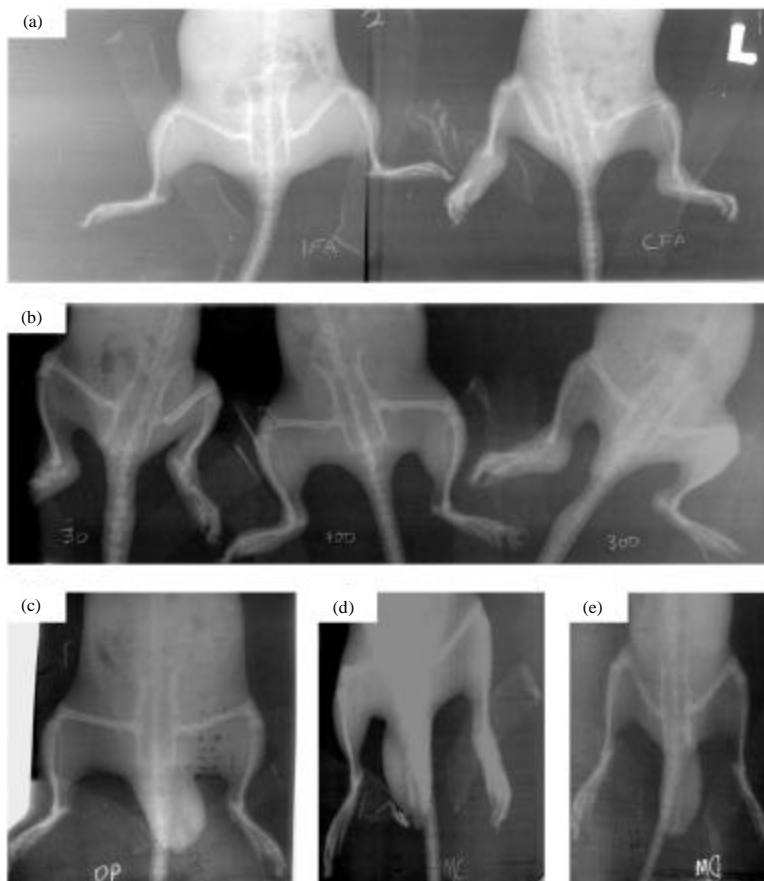


Fig. 5: Radiograph of rats treated with IFA/non arthritic control and CFA/arthritic (a), *C. erythrocarpos* extract (30, 100 and 300 mg kg⁻¹) (b) in the curative protocol and rats pre treated with a combination of *C. erythrocarpos* + dexamethasone, *C. erythrocarpos*+methotrexate and dexamethasone+methotrexate (c, d and e), respectively

Swierkot and Szechinski, 2006). Dexamethasone is known to inhibit the release of pro-inflammatory cytokines (tissue necrosis factor- α and interleukin-1 β), which are known to play a central role in the propagation of the disease process in RA thus being able to arrest the oedema produced (Issekutz and Issekutz, 1991). Methotrexate, a disease modifying anti rheumatic drug and immunosuppressant was used for comparison because it is a commonly prescribed front-line treatment for rheumatoid arthritis (Swierkot and Szechinski, 2006). Low dose methotrexate is the most widely used anti rheumatic drug and it is the gold standard against which other systemic medications are compared (Ochaion *et al.*, 2006). Methotrexate is often preferred by rheumatologists because if it does not control arthritis on its own then it works well in combination with many other drugs (Hisadome *et al.*, 2004). Dexamethasone combined with methotrexate synergistically suppressed arthritic progression which was extremely significant; confirming the fact that dexamethasone, a first line and fast acting agent reduces pain and inflammation, while methotrexate, a second line, slow acting agent promotes disease remission and prevents progressive joint destruction that can result from uncontrolled inflammation (Brown *et al.*, 2006).

The effect of the extract is comparable to that of methotrexate because when combined, both drugs did not show a significant effect on the acute phase of inflammation but they significantly

retarded disease progression in the poly arthritic phase, indicating that both drugs may be suppressing a similar stage of the inflammatory process in arthritic rats. On the other hand, the extract combined with dexamethasone significantly suppressed both phases of arthritis than the extract or dexamethasone alone. It is therefore possible that the extract and dexamethasone suppressed a completely different stage of the inflammatory process in arthritic rats thus their combined effect gave a better remission.

Radiographs are necessary to determine true remission of disease and for accurate evaluation of disease status. The measurement of paw or joint swelling only gives an indication of oedematous changes in this region; however, the actual damage takes place in the tibiotarsals joint (Escandell *et al.*, 2007). Reduced bone formation and increased resorption are the causes of bone loss in adjuvant-induced arthritis in rats (Aota *et al.*, 1996; Findlay and Haynes, 2005; Makinen *et al.*, 2007). The x-rays clearly show that *C. erythrocarpos* decreased bone loss and therefore in addition to suppressing joint inflammation and retard disease progression, the extract also reduced bone degradation in arthritis.

The ethanolic root extract of *C. erythrocarpos* contained flavonoids and alkaloids and these phytochemicals may be responsible for some of its pharmacological properties. As have been reported by several authors, the presence of many biologically active phytochemicals such as triterpenes, flavonoids, alkaloids, steroids, tannins and glycosides in various plant extracts may be responsible for their respective pharmacological properties (Agarwal and Rangari, 2003; Liu *et al.*, 1996; Mbagwu *et al.*, 2007; Narendhirakannan *et al.*, 2007; Singh *et al.*, 2002). Phytochemicals from *Alstonia boonei* root bark (Kweifio-Okai *et al.*, 1995) and leaf extract of *Palisota hirsuta* (Woode *et al.*, 2009a, b) have been shown to have anti-arthritic effect in rodents. Even though the exact mechanism involved in the anti-arthritic effect of *C. erythrocarpos* is not known it could be speculated that one or more of these plant metabolites could probably be responsible for this particular pharmacological effect.

CONCLUSION

The roots of *Capparis erythrocarpos* have anti-arthritic effect in Adjuvant induced Arthritis model and this validates its traditional use.

ACKNOWLEDGMENT

The authors are grateful for the technical assistance offered by Mr. Thomas Ansah and Mr. George Ofei of the Department of Pharmacology, Faculty of Pharmacy and Pharmaceutical Sciences, KNUST, Kumasi.

REFERENCES

- Abbiw, D.K., 1990. Useful Plants of Ghana. 1st Edn., Intermediate Technology Publications and Royal Botanic Gardens Kew, London, ISBN: 1-85339-043-7, pp: 337.
- Abotsi, W.M.K., E. Woode, G.K. Ainooson, A. Amo-Barimah and E. Boakye-Gyasi, 2010. Antiarthritic and antioxidant effects of the leaf extract of *Ficus exasperata* P. Beauv. (Moraceae). Pharmacogn. Res., 2: 89-97.
- Agarwal, R.B. and V.D. Rangari, 2003. Phytochemical investigation and evaluation of anti-inflammatory and anti-arthritic activities of essential oil of *Strobilanthus ixiocephala* Benth. Indian J. Exp. Biol., 41: 890-894.
- Agarwal, S.K. and M.B. Brenner, 2006. Role of adhesion molecules in synovial inflammation. Curr. Opin. Rheumatol., 18: 268-276.

- Akaogi, J., T. Nozaki, M. Satoh and H. Yamada, 2006. Role of PGE2 and EP receptors in the pathogenesis of rheumatoid arthritis and as a novel therapeutic strategy. *Endocr. Metab. Immune Disord. Drug Targets*, 6: 383-394.
- Aota, S., T. Nakamura, K. Suzuki, Y. Tanaka, Y. Okazaki, Y. Segawa, M. Miura and S. Kikuchi, 1996. Effects of indomethacin administration on bone turnover and bone mass in adjuvant-induced arthritis in rats. *Calcif. Tissue Int.*, 59: 385-391.
- Atzeni, F. and P. Sarzi-Puttini, 2007. Early rheumatoid arthritis. *Reumatismo*, 59: 100-117.
- Balunas, M.J. and A.D. Kinghorn, 2005. Drug discovery from medicinal plants. *Life Sci.*, 78: 431-441.
- Bonnet, J., E. Zerath, N. Picaud, C. Lesur and A. Mattio *et al.*, 1993. Bone morphometric changes in adjuvant-induced polyarthritic osteopenia in rats: evidence for an early bone formation defect. *J. Bone Miner Res.*, 8: 659-668.
- Bradbeer, J.N., R.D. Kapadia, S.K. Sarkar, H. Zhao and G.B. Stroup *et al.*, 1996. Disease-modifying activity of SK&F 106615 in rat adjuvant-induced arthritis. Multiparameter analysis of disease magnetic resonance imaging and bone mineral density measurements. *Arthritis Rheum.*, 39: 504-514.
- Brown, A.K., M.A. Quinn, Z. Karim, P.G. Conaghan and C.G. Peterfy *et al.*, 2006. Presence of significant synovitis in rheumatoid arthritis patients with disease-modifying antirheumatic drug-induced clinical remission: evidence from an imaging study may explain structural progression. *Arth. Rheum.*, 54: 3761-3773.
- Campo, G.M., A. Avenoso, S. Campo, A.M. Ferlazzo, D. Altavilla and A. Calatroni, 2003. Efficacy of treatment with glycosaminoglycans on experimental collagen-induced arthritis in rats. *Arthritis Res. Ther.*, 5: R122-R131.
- Capell, H.A., R. Madhok, D.R. Porter, R.A.L. Munro, I.B. McInnes and J.A. Hunter *et al.*, 2007. Combination therapy with sulfasalazine and methotrexate is more effective than either drug alone in patients rheumatoid arthritis with a suboptimal response to sulfasalazine: Results from the double-blind placebo-controlled MASCOT study. *Ann. Rheum. Dis.*, 66: 235-241.
- Caspi, D., M. Anouk, I. Golan, D. Paran and I. Kaufman *et al.*, 2006. Synovial fluid levels of anti-cyclic citrullinated peptide antibodies and IgA rheumatoid factor in rheumatoid arthritis, psoriatic arthritis and osteoarthritis. *Arthritis Rheum.*, 55: 53-56.
- Escandell, J.M., M.C. Recio, S. Manez, R.M. Giner, M. Cerda-Nicolas and J.L. Rios, 2007. Cucurbitacin R reduces the inflammation and bone damage associated with adjuvant arthritis in lewis rats by suppression of tumor necrosis factor-alpha in T lymphocytes and macrophages. *J. Pharmacol. Exp. Ther.*, 320: 581-590.
- Fairhurst, A.M., P.K. Wallace, A.S. Jawad and N.J. Goulding, 2007. Rheumatoid peripheral blood phagocytes are primed for activation but have impaired Fc-mediated generation of reactive oxygen species. *Arthritis Res. Ther.*, 9: R29-R29.
- Feldmann, M., F.M. Brennan, B.M. Foxwell, P.C. Taylor, R.O. Williams and R.N. Maini, 2005. Anti-TNF therapy: Where have we got to in 2005. *J. Autoimmun.*, 25: 26-28.
- Fereidoni, M., A. Ahmadiani, S. Semnanian and M. Javan, 2000. An accurate and simple method for measurement of paw edema. *J. Pharmacol. Toxicol. Methods*, 43: 11-14.
- Findlay, D.M. and D.R. Haynes, 2005. Mechanisms of bone loss in rheumatoid arthritis. *Mod. Rheumatol.*, 15: 232-240.
- Hisadome, M., T. Fukuda, K. Adachi and H. Komatsu, 2004. Combination benefit of a pyrimidylpiperazine derivative (Y-40138) and methotrexate in arthritic rats. *Eur. J. Pharmacol.*, 497: 351-359.

- Hoffmann, J.C., C. Herklotz, H. Zeidler, B. Bayer, H. Rosenthal and J. Westermann, 1997. Initiation and perpetuation of rat adjuvant arthritis is inhibited by the anti-CD2 monoclonal antibody (mAb) OX34. *Ann. Rheum. Dis.*, 56: 716-722.
- Hurley, J.V. and D.A. Willoughby, 1973. Acute inflammation: A combined topographical and electron microscopic study of the mode of action of carrageenan. *Pathology*, 5: 9-21.
- Irvine, F.R., 1961. *Woody Plants of Ghana*. 1st Edn., Oxford University Press, London.
- Issekutz, A.C. and T.B. Issekutz, 1991. Quantitation and kinetics of polymorphonuclear leukocyte and lymphocyte accumulation in joints during adjuvant arthritis in the rat. *Lab. Invest.*, 64: 656-663.
- Kapoor, M., O. Shaw and I. Appleton, 2005. Possible anti-inflammatory role of COX-2-derived prostaglandins: Implications for inflammation research. *Curr. Opin. Invest. Drugs*, 6: 461-466.
- Kimel, M., M. Cifaldi, N. Chen and D. Revicki, 2008. Adalimumab plus methotrexate improved sf-36 scores and reduced the effect of Rheumatoid Arthritis (RA) on work activity for patients with early RA. *J. Rheumatol.*, 35: 206-215.
- Kinne, R.W., C.B. Schmidt-Weber, R. Hoppe, E. Buchner, E. Palombo-Kinne, E. Nurnberg and F. Emmrich, 1995. Long-term amelioration of rat adjuvant arthritis following systemic elimination of macrophages by clodronate-containing liposomes. *Arth. Rheum.*, 38: 1777-1790.
- Kweifio-Okai, G., D. Bird, B. Field, R. Ambrose, A.R. Carroll, P. Smith and R. Valdes, 1995. Antiinflammatory activity of a Ghanaian antiarthritic herbal preparation: III. *J. Ethnopharmacol.*, 46: 7-15.
- Liu, L., E. Buchner, D. Beitz, C.B.S. Weber, V. Kaefer, F. Emmrich and R.W. Kinne, 1996. Amelioration of rat experimental arthritides by treatment with the alkaloid sinomenine. *Int. J. Immunopharmacol.*, 18: 529-543.
- Makinen, H., H. Kautiainen, P. Hannonen, T. Mottonen and M. Leirisalo-Repo *et al.*, 2007. Sustained remission and reduced radiographic progression with combination disease modifying antirheumatic drugs in early rheumatoid arthritis. *J. Rheumatol.*, 34: 316-321.
- Malaviya, A.M., 2006. Cytokine network and its manipulation in rheumatoid arthritis. *J. Assoc. Physicians India*, 54: 15-18.
- Mbagwu, H.O., R.A. Anene and O.O. Adeyemi, 2007. Analgesic, antipyretic and anti-inflammatory properties of *Mezoneuron benthamianum* Baill. *Nig. Q. J. Hosp. Med.*, 17: 35-41.
- Meyer, L.H., L. Franssen and T. Pap, 2006. The role of mesenchymal cells in the pathophysiology of inflammatory arthritis. *Best Pract Res. Clin. Rheumatol.*, 20: 969-981.
- Miller, J.R., 2003. *GraphPad: Version 4.0. Step-by-Step Examples*. 1st Edn., GraphPad Software Inc., San Diego, CA.
- Mottonen, T., P. Hannonen, M. Leirisalo-Repo, M. Korpela, M. Hakala and H. Kautiainen, 2006. Efficacy of combination therapy in rheumatoid arthritis: Comment on the review by Smolen *et al.* *Arth. Rheum.*, 54: 2032-2034.
- Motulsky, H.J. and A. Christopoulos, 2003. *Fitting Model to Biological Data using Linear and Nonlinear Regression a Practical Guide to Curve Fitting*. 1st Edn., GraphPad Software Inc., San Diego, CA.
- Mshana, N.R., D.K. Abbiw, I. Addae-Mensah, E. Adjanohoun and M.R.A. Ahyi *et al.*, 2000. *Traditional Medicine and Pharmacopoeia: Contribution to the Revision of Ethnobotanical and Floristic Studies in Ghana*. Organization of African Unity/Scientific, Technical and Research Commission, Nairobi, Kenya, ISBN: 978-2453-66-2.

- Mullazehi, M., L. Mathsson, J. Lampa and J. Ronnelid, 2007. High anti-collagen type-II antibody levels and induction of proinflammatory cytokines by anti-collagen antibody-containing immune complexes *in vitro* characterise a distinct rheumatoid arthritis phenotype associated with acute inflammation at the time of disease onset. *Ann. Rheum. Dis.*, 66: 537-541.
- Narendhirakannan, R.T., S. Subramanian and M. Kandaswamy, 2007. Anti-inflammatory and lysosomal stability actions of *Cleome gynandra* L. studied in adjuvant induced arthritic rats. *Food Chem. Toxicol.*, 45: 1001-1012.
- Ochaion, A., S. Bar-Yehuda, S. Cohn, L. del Valle and G. Perez-Liz *et al.*, 2006. Methotrexate enhances the anti-inflammatory effect of CF101 via up-regulation of the A3 adenosine receptor expression. *Arthritis Res. Ther.*, 8: R169-R169.
- Pakozdi, A., M.A. Amin, C.S. Haas, R.J. Martinez and G.K. Haines 3rd *et al.*, 2006. Macrophage migration inhibitory factor: A mediator of matrix metalloproteinase-2 production in rheumatoid arthritis. *Arthritis Res. Ther.*, 8: R132-R132.
- Pearson, C.M., 1956. Development of arthritis, peri-arthritis and periostitis in rats given adjuvants. *Proc. Soc. Exp. Biol. Med.*, 91: 95-101.
- Pine, P.R., B. Chang, N. Schoettler, M.L. Banquerigo and S. Wang *et al.*, 2007. Inflammation and bone erosion are suppressed in models of rheumatoid arthritis following treatment with a novel *Syk inhibitor*. *Clin. Immunol.*, 124: 244-257.
- Pohlers, D., A. Beyer, D. Koczan, T. Wilhelm, H.J. Thiesen and R.W. Kinne, 2007. Constitutive upregulation of the transforming growth factor-beta pathway in rheumatoid arthritis synovial fibroblasts. *Arth. Res. Ther.*, 9: R59-R59.
- Pulichino, A.M., S. Rowland, T. Wu, P. Clark and D. Xu *et al.*, 2006. Prostacyclin antagonism reduces pain and inflammation in rodent models of hyperalgesia and chronic arthritis. *J. Pharmacol. Exp. Ther.*, 319: 1043-1050.
- Reinhart, W.H., 2006. Erythrocyte sedimentation rate-more than an old fashion. *Ther. Umsch.*, 63: 108-112.
- Singh, B., P.M. Sahu and M.K. Sharma, 2002. Anti-inflammatory and antimicrobial activities of triterpenoids from *Strobilanthes callosus* nees. *Phytomedicine*, 9: 355-359.
- Smolen, J.S., K. Redlich, J. Zwerina, D. Aletaha, G. Steiner and G. Schett, 2005. Pro-inflammatory cytokines in rheumatoid arthritis: Pathogenetic and therapeutic aspects. *Clin. Rev. Allergy Immunol.*, 28: 239-248.
- Sofowara, A., 1993. Medicinal Plants and Traditional Medicine in Africa. Spectrum Books Ltd., Ibadan, Nigeria, pp: 289.
- Sokka, T., P. Hannonen and T. Mottonen, 2005. Conventional disease-modifying antirheumatic drugs in early arthritis. *Rheum. Dis. Clin. North Am.*, 31: 729-744.
- Swierkot, J. and J. Szechinski, 2006. Methotrexate in rheumatoid arthritis. *Pharmacol. Rep.*, 58: 473-492.
- Trease, E. and W.C. Evans, 1989. A Text Book of Pharmacognosy. 13th Edn., Billiare Tindall, London, pp: 61-62.
- Weissmann, G., 2006. The pathogenesis of rheumatoid arthritis. *Bull. NYU Hosp. J. Dis.*, 64: 12-15.
- Whitehouse, M.W., 2007. Adjuvant arthritis 50 years on: The impact of the 1956 article by C.M. Pearson, Development of arthritis, peri-arthritis and periostitis in rats given adjuvants. *Inflamm. Res.*, 56: 133-138.
- Willoughby, D.A., E. Coote and J.L. Turk, 1969. Complement in acute inflammation. *J. Pathol.*, 97: 295-305.

- Woode, E., G.K. Ainooson, E. Boakye-Gyasi, C. Ansah and D.D. Obiri *et al.*, 2008. Anti-arthritic and antioxidant properties of the ethanolic stem bark extract of *Newbouldia laevis* (P. Beauv.) Seaman ex Bureau (Bignoniaceae). *J. Med. Plants Res.*, 2: 180-188.
- Woode, E., C.A. Danquah, E. Boakye-Gyasi, C. Ansah and G. Ainooson, 2009a. Antinociceptive effects of an ethanolic extract of *Capparis erythrocarpos* Isert roots in the mice formalin test. *Int. J. Pharmacol.*, 5: 354-361.
- Woode, E., E. Boakye-Gyasi, C.A. Danquah, C. Ansah and M. Duwiejua, 2009b. Anti-arthritic effects of *Palisota hirsuta* K. Schum. leaf extract in freund's adjuvant-induced arthritis in rats. *Int. J. Pharmacol.*, 5: 181-190.
- Wu, J.F., Y.H. Yang, L.C. Wang, J.H. Lee, E.Y. Shen and B.L. Chiang, 2007. Comparative usefulness of C-reactive protein and erythrocyte sedimentation rate in juvenile rheumatoid arthritis. *Clin. Exp. Rheumatol.*, 25: 782-785.
- Zhao, H., S. Liu, D. Huang, Q. Xu, T. Shuto and Y. Iwamoto, 2006. The protective effects of incadronate on inflammation and joint destruction in established rat adjuvant arthritis. *Rheumatol. Int.*, 26: 732-740.