



Journal of
**Pharmacology and
Toxicology**

ISSN 1816-496X



Academic
Journals Inc.

www.academicjournals.com

Anti-fertility Effects of *Carica papaya* Linn: Methanol Leaf Extracts in Male Wistar Rats

¹Udeh E. Nkeiruka and ²Nwaehujor O. Chinaka

¹Department of Veterinary Physiology and Pharmacology, Michael Okpara University of Agriculture, Umudike, Abia State, Nigeria

²Department of Biochemistry, Faculty of Basic Medical Sciences, University of Calabar, P.M.B. 1115, Calabar, Nigeria

Corresponding Author: Nwaehujor O. Chinaka, Department of Biochemistry, Faculty of Basic Medical Sciences, University of Calabar, P.M.B. 1115, Calabar, Nigeria Tel: +2348035450300

ABSTRACT

Carica papaya methanol leaf extract (CPMLE) is used widely in West Africa as anti-malarial and antimicrobial. The aim of this experiment was to study the effects of (CPMLE) on fertility in male Wistar rats using sperm counts and percentage of defective sperm cells as markers. Acute toxicity test was performed. Thirty-two male Wistar rats were divided into 4 groups and treated orally with 100, 200 and 400 mg kg⁻¹ b.wt., respectively with the extract. Group 4 served as control (10 mL kg⁻¹ distilled water). After 28 days of treatment, serum biochemical parameters including Aspartate aminotransferase (AST), Blood Urea Nitrogen (BUN), Total Bilirubin (TB), alkaline phosphatase (ALP), alanine aminotransferase (ALT), gamma glutamyltransferase (GGT), triglycerides, total protein and albumin and histopathological study of the testes, kidney, heart and liver were assayed. Acute toxicity results showed that CPMLE produced no mortalities at the dose of 1500 mg kg⁻¹. However, there were CNS signs as well as diuresis. CPMLE significantly (p<0.01) produced dose dependent decreases in sperm counts and increased the percentage of defective sperm cells. There were significant (p<0.05) increases in AST and BUN. Histopathological studies showed mild kidney and cardiac hyperaemia, slight hepatic degeneration and severe necrosis of the germinal epithelium of the testes. These show that CPMLE can produce some defects to fertility and may be used to control birth rate.

Key words: Antifertility, *Carica papaya* methanol leaf extract, birth control, sperm count, gamma glutamyltransferase (GGT)

INTRODUCTION

Carica papaya, the sole species in the genus *Carica* of the plant family Caricaceae. Originally from Southern Mexico, the papaya is now cultivated in most countries with tropical climate like Nigeria (Akinloye and Morayo, 2010). *C. papaya* is known as okwulu bekee by the Igbo, Ibepe by the Yoruba and kawuse by the Hausa tribes of Nigeria.

Carica papaya contains many biologically active compounds. There have been claims of isolation of two important compounds-chymopapain and papain, which are supposed to aid in digestion. (Brocklehurst *et al.*, 1985). The plant parts have been used as a meat tenderizer due to the presence of proteolytic enzymes in the sap, as a haemostat and antidote against venoms and rabies and for treatment of diabetes, due to its diuretic activity (Burkill, 1985).

Also, the leaves and roots of *Carica papaya* are known to contain cyanogenic glucosides which form cyanide (Bennett *et al.*, 1997, Ayoola and Adeyeye, 2010). *C. papaya* latex has been shown to have activity against *Candida albicans* (Giordani *et al.*, 1996) *Heligmosomoides polygyrus* (Satrija *et al.*, 1995) *Ascaris suum* and *Ascaridia galli* (Satrija *et al.*, 1994). Aqueous extract of *C. papaya* leaves have shown potential activity in management of dengue fever (Ahmad *et al.*, 2011), anti tumor and immunomodulatory activities (Otsuki *et al.*, 2010).

In reproduction, various extracts of *C. papaya* seed have been shown to have antifertility activity in male (Chinoy and Padman, 1996) and female rats (Chinoy *et al.*, 1997). It is also reported to be an abortifacient and lactogenic (Burkill, 1985). Aqueous extract of *C. papaya* leaf caused reduction in mean values of andrological parameters as a result of lesion of the seminiferous tubule epithelium (Akinloye and Morayo, 2010). The present study therefore was to determine the effects of methanol leaf extract of *C. papaya* on some male reproductive, biochemical and histopathological parameters in rats.

MATERIALS AND METHODS

Adult male Wistar rats weighing between 175-215 g were used for the study. They were kept in the animal house of the Faculty of Veterinary Medicine, University of Nigeria, Nsukka under a well-ventilated environment. The animals were allowed free access to feed and water *ad libitum*.

Preparation of the extract: Fresh *Carica papaya* (Linn) leaves were obtained from Nsukka urban region and authenticated by Mr. A. Ozioko, a taxonomist with the Biodiversity Development Centre Program (BDGP), Nsukka. The leaves were air dried on the bench, pulverized into coarse powder and kept in polythene bags at room temperature (23-25°C), ready for extraction.

Plant extraction: One thousand grams of the dried pulverized leaves were extracted with 80% methanol in water for 72 h with intermittent shaking every 2 h. This was filtered with Whatman No. 1 filter paper. The filtrates were concentrated using a rotary evaporator at 40°C.

Acute toxicity studies: Acute toxicity study was carried out according to the method described by Miller and Tainter (1944). Rats were divided into five groups (A-E) consisting of 6 rats per group. Group A was given distilled water (10 mL kg⁻¹) while groups B, C, D and E were separately given 100, 500, 1000 and 1500 mg kg⁻¹ of the extract, respectively. Treatments were administered by gastric intubation. The animals were observed for 48 h post treatment for signs of toxicity and death.

Experimental procedures: Thirty-two adult male albino rats were allocated into four groups (A-D) of 8 rats in each group. Groups A, B and C were given daily graded oral doses (100, 200 and 400 mg kg⁻¹ b.wt.) of the extract, respectively for 28 days and group D (control) served as control (distilled water, 10 mL kg⁻¹). After 28 days, blood sample from each rat was collected through the eye under light ether anaesthesia. The blood samples were centrifuged at 1000 rpm and serum was collected for biochemical analysis. Serum biochemical parameters including Aspartate aminotransferase (AST), Blood Urea Nitrogen (BUN), total bilirubin, alkaline phosphatase (ALP), alkaline aminotransferase (ALT), Gamma Glutamyl Transferase (GGT), triglycerides, total protein and albumin were determined using standard techniques (Tietz, 1986). Animals were humanely sacrificed by cervical dislocation and their testes, kidney and liver were removed. Sperm samples were collected from caudal epididymis for sperm count and defect studies.

Histopathology: Tissue samples from liver, kidney and testis were fixed in 10% formal-saline for a minimum of 24 h. The samples were dehydrated by washing in ascending grades of ethanol, cleared with xylene, embedded in paraffin wax, sectioned with a microtome, stained with Hematoxylin and Eosin (H and E) and mounted on Canada balsam. All sections were examined under light microscope (x10, x20 and x40) magnification. Photographs of the lesions were taken with an Olympus photo microscope for observation and documentation of histopathologic lesions.

Statistical analysis: The data collected were statistically analyzed using one-way Analysis of variance (ANOVA) and Duncan New multiple range *post hoc* test, mean differences at $p < 0.05$ were considered significant.

RESULTS

Extraction of the plant material: *Carica papaya* methanol leaf extract gave a yield of 22.1% w/w dry extract.

Acute toxicity: *Carica papaya* methanol leaf extract was safe in rats at the tested oral doses (100-1500 mg kg⁻¹), there was no mortality within the study period. However, there were behavioral changes such as depression, reduced motor activity and ataxia. There was also a slight increase in urine output.

Serum biochemical analysis: The extract at 200 and 400 mg kg⁻¹ significantly ($p < 0.05$) decreased aspartate aminotransferase (AST) values (18.7±4.4 and 24.6±4.3, respectively) when compared with control (26.7±4.3). CPMLE also induced significant ($p < 0.05$) increase in Blood Urea Nitrogen (BUN) at 400 mg kg⁻¹ (55.3±7.7). There was no significant ($p > 0.05$) difference in total bilirubin, alkaline phosphatase (ALP), alkaline amino transferase (Alt), Gamma Glutamyl Transferase (GGT) and triglycerides in rats that were given different doses of the extract and control (Table 1). There were also no significant ($p > 0.05$) changes in total protein and albumin values between extract-treated and normal rats.

Sperm count and spermatozoa defects: High doses (200 and 400 mg kg⁻¹ b.wt.) of *C. papaya* methanol leaf extract induced a highly significant ($p < 0.01$) decrease in rat sperm count compared to the control (CPMLE 200 mg kg⁻¹ b.wt. = 35.8±5.2; CPMLE 400 mg kg⁻¹ b.wt. = 17.3±2.3 and control = 81.5±2.8). There were greater percentage sperm defects which ranged from tailless head, headless tail, rudimentary tail, bent tail, curved tail, curved midpiece to bent midpiece with 100 and 200 mg kg⁻¹ b.wt. of the extract in contrast to sperm cells from untreated control rats (Table 2).

Table 1: Effect of *Carica papaya* methanol leaf extract on serum biochemical parameters in rats

Treatment	Dose (mg kg ⁻¹)	TB (mg dL ⁻¹)	ALP (IU L ⁻¹)	AST (IU L ⁻¹)	ALT (IU L ⁻¹)	GGT (IU L ⁻¹)	BUN (mg dL ⁻¹)	TRIG (mg dL ⁻¹)
CPMLE	100	0.4±0.10	114.2±11.4	12.3±4.7	26.2±3.1	95.8±12.1	45.2±5.1	60.7±6.1
CPMLE	200	0.3±0.08	111.8±13.5	18.7±4.4*	26.6±7.3	96.2±13.8	47.9±6.8	62.2±2.1
CPMLE	400	0.3±0.11	109.7±18.7	24.6±4.3*	24.6±4.3*	97.7±15.4	55.3±7.7*	63.4±6.7
Dist H ₂ O		0.4±0.07	110.6±14.8	26.7±4.3	26.7±4.3	95.3±11.9	46.1±9.1	62.4±5.7

Values are expressed as Mean±SE for each group, *Indicates significant difference at $p < 0.05$ compared to control

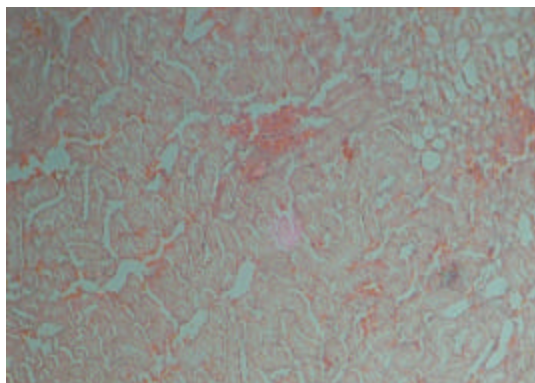


Fig. 1: Kidney with mild hyperemia of glomerular and medullary vessels (staining H and E, magnification x100)

Table 2: Effect of CPMLE on spermatozoa counts and percentage abnormal sperm

Treatment	Dose	n	Sperm count ($\times 10^6$ cell mL^{-1})	Abnormal sperm (cell mL^{-1})
CPMLE	100 mg kg^{-1}	8	77.4 \pm 2.7	65
CPMLE	200 mg kg^{-1}	8	35.8 \pm 5.2**	68
CPMLE	400 mg kg^{-1}	8	17.3 \pm 2.3**	96
Control	10 mL kg^{-1}	8	81.5 \pm 2.8	48

**Indicate significant differences at $p < 0.01$ compared to control group, n: Number of animals

Histopathological changes: *Carica papaya* methanol leaf extract at doses below 400 mg kg^{-1} did not induce histopathological changes in kidney, liver, heart and testis within the study period. However, the high dose (400 mg kg^{-1} b.wt.) produced moderate hyperaemia in the kidney and heart muscles, slight degenerative changes in the liver and severe necrotic lesions with sloughing off of the germinal epithelium in the testis (Fig. 1).

DISCUSSION

Carica papaya methanol leaf extract was safe in rats up to 1500 mg kg^{-1} ; there was no mortality. This is in line with the findings of Halim *et al.* (2011), who reported no mortalities using aqueous extract. However, the behavioral changes seen such as depression, reduced motor activity, ataxia, could be due to the presence of cyanogenic glycosides in *C. papaya* (Bennett *et al.*, 1997; Ayoola and Adeyeye, 2010). These glycosides have been known to have deleterious effects on the brain due to cytotoxic hypoxia, leading to various degrees of nervous signs (Braide and Anika, 2007). This may be related to the folkloric use of the plant as a muscle relaxant and sedative (Ellingwood 1919), which has been validated (Gupta *et al.*, 1990). *C. papaya* leaves has been reported to be used in cases of oedema and as a diuretic (Burkill, 1985). This could explain the slight increase in urine output seen in the rats.

The extract increased the levels of AST and BUN in the rats. An increase in BUN is often associated with dehydration (Tennant and Center, 2008) which can be caused by the diuresis observed in rats during the acute toxicity test. Increase in BUN could also be caused by excessive protein catabolism. This is because *C. papaya* contains proteolytic enzymes papain and chymopapain (Brocklehurst *et al.*, 1985); which cause increase proteolysis, resulting in the release

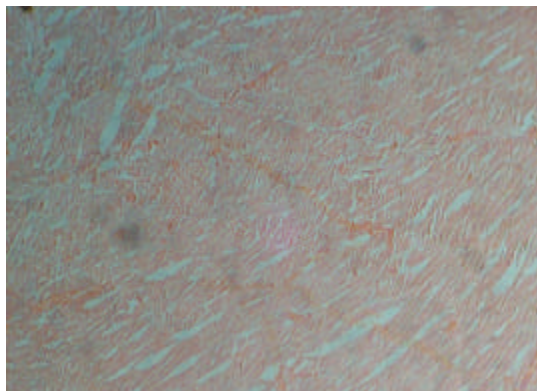


Fig. 2: A mildly hyperemic muscle of the heart stained with H and E, magnification is x100

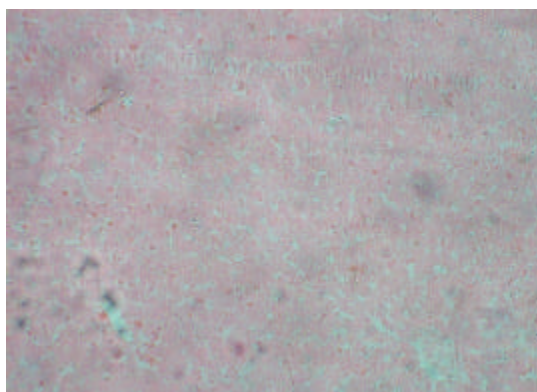


Fig. 3: Normal liver stained with H and E

of free amino acids as well as nitrogen and urea. AST activity is usually high in the liver of all domestic animals and the serum activity is used routinely in all for evaluation of liver cell injury. However, AST activity is also high in the kidney, heart and skeletal muscle, so elevations in serum AST are considered less specific for liver diseases than ALT (Tennant and Center, 2008). Thus, the increased level of AST cannot be safely attributed to a hepatic injury only. This is the reason for histopathological study of the heart (Fig. 2) and kidney (Fig. 1) which showed some mild hyperemia, while that of the liver (Fig. 3) showed mild hepatic degeneration. This explains the lack of significant difference in other liver function markers between rats given CPMLE and the control. Previous study Halim *et al.* (2011) using aqueous extract of *Carica papaya* did not bring about any significant changes in liver enzymes. *C. papaya* leaf extract, therefore, may not have deleterious effects on the liver, heart and kidney.

CPMLE produced significant ($p < 0.01$) reduction in spermatozoa count of rats and increased the percentage of sperm cells that are defective when compared to the control. Histopathological study of testes showed marked necrotic lesions and sloughing off of the germinal epithelium in rats given the highest dose of 400 mg kg^{-1} (Fig. 4). This may have been responsible for the low sperm count and the high percentage of defective sperm cells seen in rats in this group as compared to other groups.



Fig. 4: Testis having sloughing-off germinal epithelium

It has been found out that anti malarial remedies usually have anti fertility effects. Some of these compounds include chloroquine (Adeeko and Dada, 1998); *Azadirachta indica*, (Raji *et al.*, 2004) *Alstonia boonei* (Oze *et al.*, 2007) and dihydroartemisinin (Nwanjo *et al.*, 2007). *C. papaya* has been known to be used in the treatment of malaria (Titanji *et al.*, 2008; Arise *et al.*, 2012). Thus, there is a possible relationship between its antimalarial and anti fertility activities. Aqueous extract of *C. papaya* leaves have been reported to produce similar anti fertility effects on male rats (Akinloye and Morayo, 2010). The exact mechanism by which of *C. papaya* leaves reduce sperm count is not known, but it has been suggested that the compound papain may cross the blood testis barrier to exert harmful effects on the seminiferous tubules of the testes (Akinloye and Morayo, 2010). Many researches have reported presence of proteins in both the sperm as well as the semen. Edwards *et al.* (1981) reported the presence of serum proteins (albumin, lactoferrin), glycoproteins, a kinase and prostatic.

These proteins nourish the sperm cell. In rats given CPMLE, the increased percentage of defective sperm cell could be due to the proteolytic action of the proteases in *C. papaya*: papain and chymopapain. These enzymes may have hydrolysed the semen proteins, making them unavailable for use by the sperm cells, thereby leading to malnutrition and defects seen in the cells.

CONCLUSION

The results obtained from this study calls for some level of caution in the use of these leaves in folkloric therapy of diseases. On the other hand, it could be a good source of drug for birth control. Further work will be conducted on *C. papaya* leaves to determine the exact mechanism of action for the changes seen in the semen as well as to identify the actual fractions of the extract that possesses these antifertility properties.

REFERENCES

- Adeeko, A.O. and O.A. Dada, 1998. Chloroquine reduces fertilizing capacity of epididyma sperm in rats. *Afr. J. Med. Sci.*, 27: 63-64.
- Ahmad, N., H. Fazal, M. Ayaz, B.H. Abbasi, I. Mohammad and L. Fazal, 2011. Dengue fever treatment with *Carica papaya* leaves extracts. *Asian Pac. J. Trop. Biomed.*, 1: 330-333.
- Akinloye, O.O. and O.M. Morayo, 2010. Evaluation of andrological indices and testicular histology following chronic administration of aqueous extract of *Carica papaya* leaf in Wistar rat. *Afr. J. Pharm. Pharmacol.*, 4: 252-255.
- Arise R.O., S.O. Malomo and M.M. Lawal, 2012. Comparative antimalarial and toxicological effects of artemisinin with methanolic extract of *Carica papaya* leaves and bark of *Alstonia boonei* in animal models. *Adv. Natural Applied Sci.*, 6: 116-123.
- Ayoola, P.B. and A. Adeyeye, 2010. Phytochemical and nutrient evaluation of *Carica papaya* (pawpaw) leaves. *Int. J. Res. Rev. Applied Sci.*, 5: 325-328.

- Bennett, R.N., G. Kiddle and R.M. Wallsgrov, 1997. Biosynthesis of benzylglucosinolate, cyanogenic glucosides and phenylpropanoids in *Carica papaya*. *Phytochem*, 45: 59-66.
- Braide, V.B. and S.M. Anika, 2007. *Environmental Toxicology*. Snaap Press Ltd., USA., pp: 31-34.
- Brocklehurst, K., E. Salih, R. McKee and H. Smith, 1985. Fresh non-fruit latex of *Carica papaya* contains papain, multiple forms of chymopapain A and papaya proteinase omega. *Biochem. J.*, 228: 525-527.
- Burkill, H.M., 1985. *The Useful Plants of Tropical West Africa*. Vol. 1, Royal Botanic Gardens Kew, Sydney, pp: 604.
- Chinoy, N.I. and P. Padman, 1996. Antifertility investigations on the benzene extract of *Carica papaya* seeds in male albino rats. *J. Med. Aromatic Plant Sci.*, 18: 489-494.
- Chinoy, N.J., J. Harsha and G. Shilpa, 1997. Antifertility investigations of alcoholic papaya seed extract in female rats. *J. Med. Aromatic Plant Sci.*, 19: 422-427.
- Edwards, J.J., S.L. Tollaksen and N.G. Andersom, 1981. Proteins of human semen. I. Two-dimensional mapping of human seminal fluid. *Clin. Chem.*, 27: 1335-1340.
- Ellingwood, F., 1919. *The American Materia Medica, Therapeutics and Pharmacognosy*. Ellingwoods' Therapeutist, USA.
- Giordani, R., M.L. Cardenas, J. Moulin-Traffort and P. Regli, 1996. Fungicidal activity of latex sap from *Carica papaya* and antifungal effect of D(+)-glucosamine on *Candida albicans* growth. *Mycoses*, 39: 103-110.
- Gupta, A., C.O. Wambebe and D.L. Parsons, 1990. Central and cardiovascular effects of the alcoholic extract of the leaves of *Carica papaya*. *Pharm. Biol.*, 28: 257-266.
- Halim, S.Z., N.R. Abdullah, A. Afzan1, B.A. Abdul Rashid, I. Jantan and Z. Ismail, 2011. Study of acute toxicity of *Carica papaya* leaf extract in Sprague Dawley rats. *J. Med. Plant Res.*, 5: 1867-1872.
- Miller, L.C. and M.C. Tainter, 1944. Estimation of the LD₅₀ and its errors by means of the logarithmic-probit graph paper. *Proc. Soc. Exp. Biol. Med.*, 57: 261-264.
- Nwanjo, H.U., I.N. Iroagba, I.N. Nnatuanya and N.A. Eze, 2007. Antifertility activity of dihydroartemisinin in male albino rats. *Internet J. Endocrinol.*, Vol. 4
- Otsuki, N., N.H. Dang, E. Kumagai, A. Kondo, S. Iwata and C. Morimoto, 2010. Aqueous extract of *Carica papaya* leaves exhibits anti-tumor activity and immunomodulatory effects. *J. Ethnopharmacol.*, 127: 760-767.
- Oze, G., H. Nwanjo, R. Oze, E. Akubugwo, E. Orisakwe and P. Aka, 2007. Reproductive impairment associated with the Ethanolic extract of *Alstonia boonei* (De-wild) stems bark in male rats. *Int. J. Lab. Med.*, Vol. 3 10.5580/1e9c
- Raji, Y., I.A. Ogunwande, C.A. Osadebe and G. John, 2004. Effects of *Azadirachta indica* extract on gastric ulceration and acid secretion in rats. *J. Ethnopharmacol.*, 90: 167-170.
- Satrija, F., P. Nansen, H. Bjorn, S. Murtini and S. He, 1994. Effect of papaya latex against *Ascaris suum* in naturally infected pigs. *J. Helminthol.*, 68: 343-346.
- Satrija, F., P. Nansen, S. Murtini and S. He, 1995. Anthelmintic activity of papaya latex against patent *Heligmosomoides polygyrus* infections in mice. *J. Ethnopharmacol.*, 48: 161-164.
- Tennant, B.C. and S.A. Center, 2008. Hepatic Function. In: *Clinical Biochemistry of Domestic Animals*, Kaneko, J.J., J.W. Harvey and M.L. Bruss (Eds.). 6th Edn. Elsevier Publication, USA., pp: 379-412.
- Tietz, N.W., 1986. *Textbook of Clinical Chemistry*. W.B. Saunders, Philadelphia, pp: 1373-1430.
- Titanji, V.P.K., D. Zofou and M.N. Ngemenya, 2008. The antimalarial potential of medicinal plants used for the treatment of malaria in cameroonian folk medicine. *Afr. J. Trad. Complimentary Alternative Med.*, 5: 302-321.