



Asian Journal of Clinical Nutrition

ISSN 1992-1470

science
alert

ANSI*net*
an open access publisher
<http://ansinet.com>

Hepatoprotective Effect of Feeding Celery Leaves Mixed with Chicory Leaves and Barley Grains to Hypercholesterolemic Rats

Nehal M. Belal

Department of Nutrition and Food Science, Faculty of Home Economics, Helwan University, Egypt

ABSTRACT

Celery, Chicory leaves and Barley grains are valuable in weight loss diets and regulate lipid metabolism. They may reduce risk of fatty liver. The present study aimed to investigate the effect of diet supplementation with celery, chicory and barley powder on liver enzymes and blood lipids in rats fed cholesterol enriched diet. In this study used four groups of rats fed 3% cholesterol were supplemented diet to induce hypercholesterolemia and one group was fed on cholesterol free basal diet. The dry powder of celery leaves, chicory leaves and barley grains was separately added to the basal diet at 10% concentration or in combination of three plants at 15% for four weeks. Biochemical analyses of serum liver enzymes and blood lipids as well as histopathological examination of liver were performed. Feeding of diet supplemented lowered the elevated serum level of liver enzymes and blood lipids in rats. While, feeding plant combination of celery, chicory and barley at 15% concentration (5% from each) was more effective in decreased the elevating of liver enzymes (AST, ALT and ALP), lowered blood lipids. The histopathological lesions seen in the livers of hypercholesterolemic rats were ameliorated by feeding this plant mixture. This study recommends that dietary intake of plant mixture concentration can be beneficial to patients suffering from hypercholesterolemia and liver diseases.

Key words: Celery, chicory, barley, biochemical analysis, hypercholesterolemia

INTRODUCTION

Celery (*Apium graveolens*, Family Apiaceae) is an excellent source of Vitamin C. It is a very good source of dietary fiber, potassium, folate, manganese and Vitamin B6. Celery is also a good source of calcium, Vitamin B1, Vitamin B2, magnesium, Vitamin A, phosphorus and iron. (Mitra *et al.*, 2001) Celery, *Apium graveolens* L. is a plant from the family of Apiaceae that has been used as food and as medicine. A review of the literature indicates that celery has been cultivated for the last 3.000 years (Momin and Nair, 2001). *Apium graveolens* has been used in traditional medicine primarily as a diuretic and to treat bronchitis, asthma, liver and spleen diseases (Singh and Handa, 1995). Also, it is known that celery in combination with other plants can help lower blood pressure (Chevallier, 1998). *A. graveolens* has been extensively studied for its biological activities. Aqueous extract of celery caused significant reduction in serum total cholesterol level in hypercholesterolemic rats (Tsi and Tan, 2000). Recently, dietary fiber have been paid more and more attention due to the physiological functions (Geng *et al.*, 2005) Also, medicinal plants are increasingly being used as herbs in most part of the world today (Abolaji *et al.*, 2007).

Chicory (*Chicorium intybus*, Family Asteraceae) leaves is a vegetable whose green leafy part is often used in cooking. Previous studies on chicory extracts and/or formulations containing the roots or leaves revealed that they produce hepatoprotective (Ahmed *et al.*, 2003;

Krylova *et al.*, 2006) and antioxidant effects. (Sarawathy and Devi, 2001; Rossetto *et al.*, 2005). Antioxidants are compounds that dispose, scavenge and suppress the formation of free radicals, or oppose their actions (Iribhogbe *et al.*, 2011). Recently, Urias-Silvas *et al.* (2007) concluded that inulin (fructans) extracted from chicory regulate appetite and lipid/glucose metabolism. It has also promising effects on the body weight and fat mass development. In particular, increases in the amount of fat in the diet have been shown to be associated with the risk of obesity and hyperlipidemia in human and rodents by altering cholesterol and triglyceride levels in plasma and tissues (Abdel-Rahman *et al.*, 2009). Hyperlipidemia is known to enhance the risk of coronary heart disease, fatty liver disease and carcinogenesis which is associated with reactive oxygen species formation (Roberts *et al.*, 2006). In recent years, many studies have focused on the bioavailability of phenolic compounds in the prevention and treatment of obesity. Phenolic compounds and flavonoids have pharmacological properties such as antioxidant, antimutagenic, antithrombotic, anti-inflammatory, anticancer and antihyperlipidemic. They are widely distributed in plants and form part of the human diet (Son and Lewis, 2002).

Previous studies on chicory extracts and formulations containing its roots or leaves revealed that they produce hepatoprotective (Mitra *et al.*, 2001; Ahmed *et al.*, 2003; Krylova *et al.*, 2006); antihyperglycemic (Petlevski *et al.*, 2003) and antioxidant effects (Sarawathy and Devi, 2001; Rossetto *et al.*, 2005). Furthermore, Urias-Silvas *et al.* (2007) concluded that inulin-type fructans extracted from chicory regulate appetite and lipid/glucose metabolism. It has also promising effects on the body weight and fat mass development.

Barley (*Hordeum vulgare* L. Family Poaceae) is an annual cereal grain which serves as a major animal feed crop. Barley makes a natural choice for healthful benefits as it is rich in protein, carbohydrates, dietary fibers, chromium, fat and it is cholesterol free (Mahmoud, 2002).

Moreover, Jenkins *et al.* (2003) concluded that barley may be used as a part of vegetarian diet, because it decreases total lipids and reduces the risk of developing liver disease as fatty liver (Jenkins *et al.*, 2003).

The present study is initiated in an effort to clarify the variation in the amount of fiber from celery, chicory and barley sources on serum liver enzymes and blood lipid profile in hypercholesterolemic rats.

MATERIALS AND METHODS

Materials

Plants: In 2009, Celery leaves and Chicory leaves were obtained from a local market of Herbs and Medicinal plants, Cairo Egypt. Barley grains (Giza 128 variety) was obtained from Agricultural Research Center, Giza, Egypt. The selected plant materials were air-dried, grinded in an electrical blender into a fine powder which was packed in air-tight plastic bags till use for basal diet supplementation.

The chemical composition of plants used is shown in Table 1.

Cholesterol: It was purchased from El-Gomhuryia Company for Chemical Industries; Cairo.

Rats: Adult male albino rats of Sprague Dawley strain weighing 150-160 g body weight were used in this study.

Methods

Preparation of basal diet: Basal diet was prepared according to Reeves *et al.* (1993).

Table 1: Chemical composition per 100 g of edible plants

| Nutrient | Amount in plants | | |
|-------------------------|------------------|----------|-----------|
| | Chicory | Barley | Celery |
| Energy | 15 kcal | 350 kcal | 12 |
| kcalCarbohydrate | 4 g | 73.7 g | 3.6 g |
| Protein | 0.0 g | 9.9 g | 0.84 |
| Dietary fiber | 1.0 g | 14.9 g | 2.04 g |
| Fats | 0.0 g | 1.2 g | 0.24 |
| Vitamin C | 200.0 mg | 0.0 mg | 8.40 mg |
| Folate | Traces | 23 µg | 33.60 mcg |
| Vitamin B6 (pyridoxine) | Traces | 0.3 mg | 0.10 mg |
| Vitamin B1 (thiamin) | Traces | 0.2 mg | 0.06 mg |
| Vitamin B2 (riboflavin) | Traces | 0.1 mg | 0.05 mg |
| Vitamin A | Traces | Traces | 160.80 IU |
| Vitamin K | Traces | Traces | 35.26 mcg |
| Potassium | 136 mg | 280 mg | 344.4 mg |
| Manganese | Traces | Traces | 0.12 mg |
| Calcium | 200.0 mg | 29.0 mg | 48.00 mg |
| Phosphorus | Traces | 221 mg | 30.00 mg |
| Magnesium | Traces | 79.0 mg | 13.20 mg |
| Iron | Traces | 2.5 mg | 0.48 mg |

Determination of the nutritional value in the Agricultural Research Center, Giza, Egypt. Percent daily values are based on a 2000 calorie diet

Induction of hypercholesterolemia: It was induced by feeding rats on basal diet supplemented with 3% cholesterol for four weeks before start of the experiment. After feeding period, a random blood sample was withdrawn from the orbital sinus of the eye and serum total cholesterol was measured to insure that hypercholesterolemia was induced (Shinnick *et al.*, 1990).

Experiments and grouping of rats: Forty two male albino rats were used in this experiment. Rats were divided into 6 equal groups of 7 animals each. Group (1) was fed on the basal diet as a negative control group while the other groups were fed on 2% cholesterol supplemented diet for four weeks for induction of hypercholesterolemia. Group (2) was left as a positive control (hypercholesterolemic), while groups (3, 4, 5) and (6) were fed on experimental diets containing 10% celery, 10% chicory, 10% barley and 15% mixture (5% from each) of celery (5% celery = 22,7 g edible weight) , chicory (5% chicory =18,5 g edible weight) and barley respectively for four weeks. During the feeding period body weight gains and food efficiency ratios were calculated according to Chapman *et al.* (1959).

At the end of experimental period, the rats were anaesthetized by ether and blood samples were collected. Blood samples were centrifuged for 20 min at 3000 rpm to separate the serum which was kept at-10°C till biochemical analysis of liver enzymes, total cholesterol, triglycerides and lipoprotein fractions. Livers of the sacrificed rats were removed and preserved in 10% neutral formalin solution till histopathological examination.

Biochemical analyses: The collected serum samples were used for estimation of aspartate and alanine aminotransferases (AST and ALT) enzymes according to the method described by

Bergmeyer *et al.* (1978) and alkaline phosphatase (ALP) according to the method described by King (1965).

Serum total cholesterol and triglycerides were calorimetrically determined (Allain *et al.*, 1974; Wahlefeld, 1974).

High density lipoprotein cholesterol (HDL-c) was calorimetrically determined, very low density lipoprotein cholesterol (VLDL-c) and low density lipoprotein cholesterol (LDL-c) was mathematically calculated (Richmond, 1973).

Histopathological examination: Livers of the scarified rats were dissected, removed and fixed in 10% formalin solution. The fixed specimens were then trimmed, washed and dehydrated in ascending grades of alcohol. These specimens were cleared in xylene, embedded in paraffin, sectioned at 4-6 microns thickness and stained with Hematoxylen and Eosin (H and E) then examined microscopically (Carleton, 1980).

Statistical analysis: Results are expressed as mean values with their standard deviation of the mean (Snedecor and Cochran, 1986).

RESULTS

As shown in Table 2, feeding normal rats on basal diet supplemented with cholesterol for four weeks significantly increased Body Weight Gain (BWG%) and Food Efficiency Ratio (FER). Feeding hypercholesterolemic rats on diet supplemented with 10% celery significantly decreased BWG% and FER while diets supplemented with 10% chicory or 10% barley or 15% mixture of the three plants caused significant increases in BWG% and FER.

It is clear from Table 3 that feeding of diet supplemented with celery, chicory and barley plant powder, alone and combined, for four weeks to hypercholesterolemic rats significantly decreased the levels of AST, ALT and ALP enzymes in the serum, compared to the control positive group.

Table 2: Effect of diet supplementation with celery, chicory or barley and their combination on food intake (FI), body weight gain (BWG %) and food efficiency ratio (FER) in hypercholesterolemic rats (n =7)

| Groups | FI (g) | BWG (%) | FER |
|----------------------|------------------------|------------------------|--------------------|
| Negative control | 9.3±0.40 ^a | 10.2±0.25 ^a | 1.09 ^a |
| Positive control | 13.2±0.50 ^c | 16.9±0.32 ^c | 1.28 ^{bc} |
| Celery (10%) | 11.2±0.10 ^b | 12.2±0.13 ^b | 1.08 ^a |
| Chicory (10%) | 13.9±0.80 ^d | 17.0±0.13 ^c | 1.22 ^b |
| Barley (10%) | 14.4±0.20 ^d | 18.1±0.41 ^d | 1.25 ^b |
| Mixture of all (15%) | 14.5±0.10 ^d | 18.9±0.32 ^d | 1.30 ^c |

Values are Mean±SD. Values in the same column sharing the same superscript letters are not significantly different

Table 3: Effect of diet supplementation with celery, chicory or barley and their combination on serum aspartate aminotransferase (AST), alanine aminotransferase (ALT) and alkaline phosphatase (ALP) enzymes in hypercholesterolemic rats (n =7)

| Groups | AST (U L ⁻¹) | ALT (U L ⁻¹) | ALP (U L ⁻¹) |
|----------------------|--------------------------|--------------------------|--------------------------|
| Negative control | 63.5±2.6 ^a | 26.5±1.6 ^a | 90.98±1.4 ^a |
| Positive control | 75.4±3.2 ^d | 37.5±2.2 ^c | 104.95±1.6 ^d |
| Celery (10 %) | 72.6±2.4 ^{bc} | 34.5±3.3 ^b | 100.97±1.8 ^c |
| Chicory (10 %) | 71.3±2.3 ^b | 33.7±3.6 ^b | 98.90±1.2 ^{bc} |
| Barley (10%) | 66.9±3.8 ^{ab} | 32.1±3.9 ^b | 96.16±1.3 ^b |
| Mixture of all (15%) | 64.5±2.8 ^a | 28.1±3.9 ^{ab} | 92.00±1.5 ^a |

Values are Mean±SD. Values in the same column sharing the same superscript letters are not significantly different

As demonstrated in Table 4, feeding experimental diets supplemented with celery, chicory and barley plant powder, alone and combined, for four weeks to hypercholesterolemic rats significantly decreased levels of total cholesterol and triglycerides in the serum, as compared to the control positive group. Feeding hypercholesterolemic rats on diets supplemented with celery, chicory and barley plant powder, caused a significant decrease in serum level of LDLc and VLDLc but significantly increased the levels of HDLc. As it is well known that LDLc is bad cholesterol so these plant material when added to basal diet improved lipid profile.

Histopathological examination: The biochemical observations reported in this study were supplemented by histopathological examination of liver sections of hypercholesterolemic rats. The obtained results showed that examination of livers of the normal (negative control ve) rats fed on the basal diet had normal histological picture of hepatic lobule that consists of central vein surrounded by normal hepatocytes Fig. 1. Examination of liver of hypercholesterolemic rats showed severe fatty degeneration of the hepatocytes and infiltration of leucocytes in hepatic sinusoid (Fig. 2). Livers of hypercholesterolemic rats fed on diet containing celery 10% showed little vacuolar degeneration of hepatocytes and mild fatty degeneration of hepatocytes as shown in Fig. 3. Examination of livers of hypercholesterolemic rats fed on diet supplemented with chicory 10% showed only mild fatty degeneration of the hepatocytes as illustrated in Fig. 4. Hypercholesterolemic rats fed on experimental diet containing barley 10% showed little vacuolar degeneration of hepatocytes and mild leucocytic infiltration around central vein (Fig. 5).

Table 4: Effect of diet supplementation with celery, chicory or barley and their combination on serum lipoprotein fractions, total cholesterol and triglyceride in hypercholesterolemic rats (n =7)

| Groups | Lipoproteins (mg dL ⁻¹) | | | Total cholesterol (mg dL ⁻¹) | Triglycerides (mg dL ⁻¹) |
|----------------------|-------------------------------------|-------------------------|--------------------------|--|--------------------------------------|
| | HDL-c | LDL-c | VLDL-c | | |
| Negative Control | 46.60±0.19 ^e | 38.20±0.21 ^a | 9.48±0.52 ^a | 94.28±0.15 ^a | 47.40±0.15 ^a |
| Positive Control | 31.30±0.67 ^a | 68.50±0.75 ^d | 16.90±0.86 ^c | 116.70±0.92 ^c | 84.50±0.86 ^c |
| Celery (10%) | 33.30±0.82 ^a | 54.60±0.61 ^c | 14.10±0.76 ^b | 102.00±0.85 ^b | 70.50±0.62 ^b |
| Chicory(10%) | 35.30±0.92 ^{ab} | 48.60±0.61 ^b | 15.10±0.15 ^{bc} | 99.00±0.85 ^b | 75.50±0.62 ^b |
| Barley (10%) | 39.10±0.51 ^b | 45.20±0.75 ^b | 14.92±0.35 ^b | 99.22±0.95 ^b | 74.60±0.33 ^b |
| Mixture of all (15%) | 40.20±0.79 ^b | 41.60±0.88 ^a | 14.76±0.52 ^b | 96.56±0.57 ^{ab} | 73.80±0.16 ^b |

HDL-c: High density lipoprotein cholesterol, LDL-c: Low density lipoprotein cholesterol, VLDL-c: Very low density lipoprotein cholesterol, Values are mean ±SD. Values in the same column sharing the same superscript letters are not significantly different

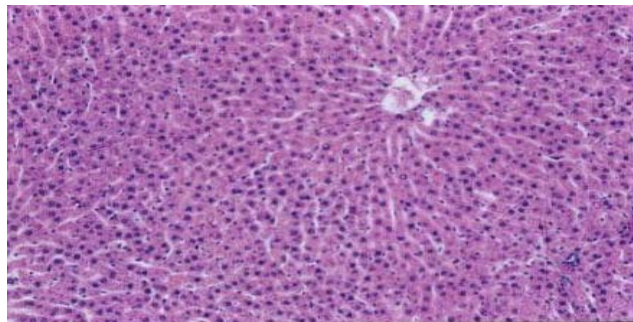


Fig. 1: Liver of control C-ve (normal) rats showing normal histology of hepatic lobule. H and E X 100)

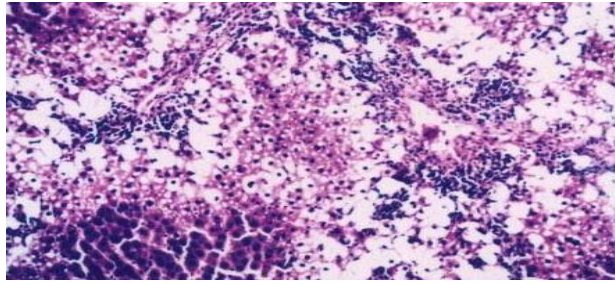


Fig. 2: Liver of hypercholesterolemic (control C+ ve) rats showing severe fatty degeneration of hepatocytes and infiltration of leucocytes in hepatic sinusoid (H and E X 100)

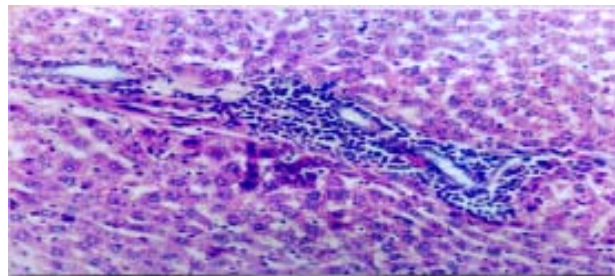


Fig. 3: Liver of rats fed on basal diet containing 10% celery powder showing little vacuolar degeneration of hepatocytes mild fatty degeneration of hepatocytes (H and E X 100)

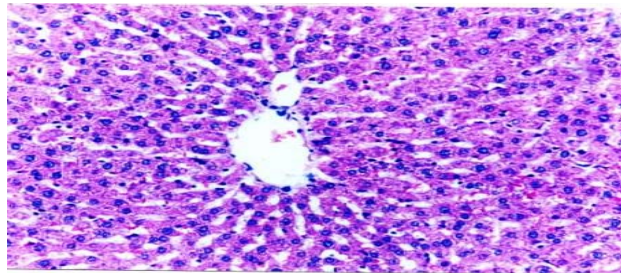


Fig. 4: Liver of rats fed on basal diet containing 10% chicory powder showing only mild fatty degeneration of hepatocytes (H and E X 100)

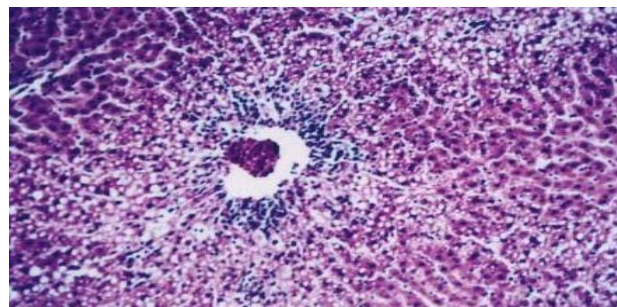


Fig. 5: Liver of rats fed on basal diet containing 10% barley powder showing little vacuolar degeneration of hepatocytes and mild leucocytic infiltration around central vein (H and E X 100)

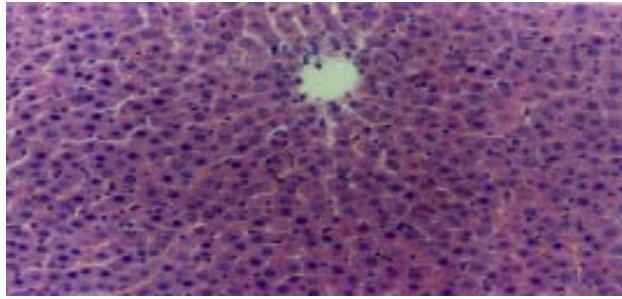


Fig. 6: Liver of rats fed on basal diet containing 15% mixture of the three plant materials showing almost normal histology of hepatic lobule (H and E X 100)

Examination of livers obtained from hypercholesterolemic rats fed on diet supplemented with a mixture of celery, chicory and barley at 15% revealed almost normal hepatic lobules as illustrated in Fig. 6.

DISCUSSION

The finding results of Table 2 was similar to that reported by Urias-Silvas *et al.* (2007) who concluded that inulin (fructans) extracted from chicory regulate appetite and has a promising effect on the body weight.

From Table 3 finding that effect of dietary fiber supplementation was similar to that reported by Tsi and Tan (2000) for celery extracts and by increasing bile acid secretion (Ahmed *et al.*, 2003; Shima, 2008).

For chicory leaves and barley grains. The previous studies reported that different extracts of celery leaves or chicory leaves or barley grains effectively lower the elevated serum levels of AST, ALT and ALP enzymes (Yang *et al.*, 2003).

From Table 4 finding that, the cholesterol lowering effect of celery reported in this study was similar to that previously reported by Tsi and Tan (2000). Moreover; the same concluded that the mechanism underlying the hypocholesterolemic activity of celery extracts (aqueous and butanol) could be possibly due to presence of sugar or amino acid side chains (s) compounds. Also, celery contains Vitamin C which is a known immune system booster and reduce the free radicals in the body. Also reduce the risk of asthma, osteoarthritis and rheumatoid arthritis. To top it off, the Vitamin is also thought to increase heart health.

The results of the present study about the effective of celery agreed with Kamal *et al.* (2009) who demonstrated that the lipid lowering action of this natural product may be mediated through inhibition of hepatic cholesterol biosynthesis, increased fecal bile acids excretion and enhanced plasma lecithin: Cholesterol acyltransferase activity and reduction of lipid absorption in the intestine.

The potassium and sodium in celery juice helps to regulate body fluid and stimulate urine production, making it an important help to rid the body of excess fluid (Nilsson, 2009).

Ni and Dom (2009) is suggested that the rich presence of tanins in chicory can keep the level of LDL (harmful) cholesterol in check. This can keep our heart healthy.

In addition, the chicory has been used in the folk medicine of Pakistan for treating liver disease and hepatic system related disorders. A group of clinical researchers recently isolated a phenolic compound called esculetin, from the extracts of the chicory and they further confirmed that is a

hepatoprotectant compound. The compound showed liver protecting activity in mice with hepatic damage induced by paracetamol and carbon tetrachloride. This extract inhibited the oxidative degradation of DNA in tissue debris of mice liver. In addition, high content of soluble fiber, inulin, chicory can reduce strain on liver by removing extra water and toxin (Kim and Shin, 1998). Inulin is soluble in water and not hydrolyzed by human digestive enzymes, it is expected to behave like a soluble fiber and to have a hypolipidemic effect. This might treat jaundice, hepatitis, hepatic congestion, etc. Also by stimulating the flow of bile, chicory is considered to treat gallstones, biliary insufficiency, gastritis and splenomegaly (Ahmed *et al.*, 2003; Krylova *et al.*, 2006). Insulin lowers serum cholesterol when added to the diet of rats, may decrease cholesterol synthesis by inhibiting hydroxymethylglutaryl-CoA reductase. A mechanism of action of oligofructose was associated with the modulation of *de novo* cholesterol synthesis by short chain fatty acids produced by the gut microflora during the fermentation process (Brosnahan and Mony, 2009). Concerning barley, barley may be used as a part of the vegetarian diet because it decreases serum total lipids. Moreover, whole-grain barley is lower in fat, protein and calories, and higher in total dietary fiber that increasing whole-grain consumption can reduce the risk of coronary heart disease and can help with weight maintenance (Jenkins *et al.*, 2003). The results of the present work about the effective of barley agreed with Ahmad *et al.* (2009) who demonstrated that barley have a concentration of soluble fibers called β -glucan. These effects are associated with increased excretion of bile acids and neutral sterols, increased catabolism of cholesterol and reduced absorption of cholesterol and fat (Talati *et al.*, 2009; Kamaljit *et al.*, 2011).

This finding is in agreement, to some extent, for celery and for chicory in rats. Chicory is purported to have several health benefits, The short-chain fatty acids produced through the fermentation of soluble fiber in the large intestine serve to stabilize blood glucose levels, lower Low-Density Lipoproteins (LDL) or "bad" cholesterol in the blood, increase the production of immune cells, the concentrated barley beta-glucan in hypercholesterolemic men and women (Behall *et al.*, 2004; Keenan *et al.*, 2007).

Histopathological examination of liver sections of hypercholesterolemic rats was nearly similar histopathological findings were obtained in CCl₄-hepatotoxic rats when given orally chicory extracts. No available literatures on the effects of celery and barley on the histology of liver could be obtained (Popovic *et al.*, 2006).

In conclusion, dietary intake of plant mixture of celery, chicory and barley at 15% for four weeks may be beneficial for patients suffering from hypercholesterolemia and liver disease as it lowers the elevated serum liver enzymes, total cholesterol and triglycerides, improves lipid profile in cholesterol fed rats.

RECOMMENDATIONS

Diet supplementation with this plant mixture produces an excellent effect on the histology of liver as it ameliorates the hepatic damage seen in the liver of hypercholesterolemia.

ACKNOWLEDGMENT

My grateful appreciation is extended to. Dr. M. A. Shalaby for his reviewing this work.

REFERENCES

- Abdel-Rahman, M.K., E.M. Mahmoud, A.R. Abdel-Moemin and G.A. Omnia Rafaat, 2009. Re-evaluation of individual and combined garlic and flaxseed diets on hyperlipidemic rats. Pak. J. Nutr., 8: 1-8.

- Abolaji, A.O., A.H. Adebayo and O.S. Odesanmi, 2007. Effects of ethanolic fruit extract of *Parinari polyandra* (Rosaceae) on serum lipid profile and some electrolytes in pregnant rabbits. *Res. J. Med. Plant*, 1: 121-127.
- Ahmed, B., T.A. Al-Hoiriny and A.B. Siddiqui, 2003. Antihepatotoxic activity of seeds of *Cichorium intybus*. *J. Ethanopharmacol.*, 87: 237-240.
- Ahmad, A., F.M. Anjum, T. Zahoor and H. Nawaz, 2009. Extraction of β -glucan from oat and its interaction with glucose and lipoprotein profile. *Pak. J. Nutr.*, 8: 1486-1492.
- Allain, C.C., L.S. Poon, C.S.G. Chan, W. Richmond and P.C. Fu, 1974. Enzymatic determination of serum cholesterol. *Clin. Chem.*, 20: 470-475.
- Behall, K., D. Scholfield and J. Hallfrisch, 2004. Diets containing barley significantly reduce lipids in mildly hypercholesterolemic men and women. *Am. J. Clin. Nutr.*, 80: 1185-1193.
- Bergmeyer, H.U., P. Scheibe and A.W. Wahlefeld, 1978. Optimization of methods for aspartate aminotransferase and alanine aminotransferase. *Clin. Chem.*, 24: 58-73.
- Brosnahan, G. and F. Mony, 2009. Chronic kidney disease: Whom to screen and how to treat, part 1: Definition, epidemiology and laboratory testing. *Pharmacogn. Mag.*, 5: 301-305.
- Carleton, H., 1980. *Histological Techniques*. 4th Edn., Oxford University Press, London, New York, USA.
- Chapman, D.G., R. Gastilla and J.A. Campbell, 1959. Evaluation of protein in foods: 1-A Method for the determination of protein efficiency ratio. *Can. J. Biochem. Phys.*, 37: 679-686.
- Chevallier, A., 1998. *The Encyclopedia of Medicinal Plants*. DK Publishing Inc., New York, pp: 11-16.
- Geng, X., W. Xiaokun, E. Yukari and S. Hiroo, 2005. Effect of different molecular weight fragments from corn bran hemicellulose on d-galactosamine-induced hepatitis in rats in relation to intestinal degradation. *Biotechnology*, 4: 173-181.
- Iribhogbe, O.I., A. Aigbiremolen, U. Akpamu, J.E. Emordi and E.O. Nwoke, 2011. Effects of selected antioxidant Vitamins on lipid profile in early pregnancy. *Asian J. Sci. Res.*, 4: 62-70.
- Jenkins, D.J., C.C.W. Kendel, A. Marchie, J. Anderson and L.S.A. Augustin *et al.*, 2003. Type 2 diabetes and vegetarian diet 1,2,3,4. *Am. J. Clin. Nutr.*, 7: 610-616.
- Kamal, M., A.M. Abushoffa, A. Disi and T. Aburjai, 2009. Hypolipidemic effects of seed extract of celery (*Apium graveolens*) in rats. *Pharmacogn. Mag.*, 5: 301-305.
- Kamaljit, K., K. Amarjeet and S.T. Pal, 2011. Analysis of ingredients, functionality, formulation optimization and shelf life evaluation of high fiber bread. *Am. J. Food Technol.*, 6: 306-313.
- Keenan, J.M., M. Goulson, T. Shamliyan, N. Knutson, L. Kolberg and L. Curry, 2007. The effects of barley β -glucan on blood lipids in population of hypercholesterolemic men and woman. *Br. J. Nutr.*, 9: 1162-1168.
- Kim, M. and H.K. Shin, 1998. The water soluble extract of chicory influences serum and liver lipid concentrations, short chain fatty acids and fecal lipid excretion in rats. *J. Nutr.*, 128: 1731-1736.
- King, J., 1965. *The Hydrolases-Acid and Alkaline Phosphatases*. In: *Practical Clinical Enzymology*, Van, D. (Ed.). Nostrand Company Limited, London, pp: 191-208.
- Krylova, S.G., L.A. Efimova and E.P. Zueva, 2006. The effect of cichorium root extract on the morphofunctional state of liver in rats with CCL4 induced hepatitis model. *Eksp. Klin. Farmacol.*, 69: 34-36.
- Mahmoud, E.S.S., 2002. Effect of barley wheat bread on blood lipids and blood glucose in experimental rats. M.Sc. Thesis, Women's Collage, Ain Shams University, Egypt.

- Mitra, S.K., M.V. Venkataranganna, S. Gopumadhavn, S.D. Anturlikar, S. Seshadri and U.V. Udupa, 2001. The protective effect of HD-03 in CCL4-induced hepatic encephalopathy in rats. *Phytother. Res.*, 15: 493-496.
- Momin, R.A. and G. Nair, 2001. Mosquitocidal, nematocidal and antifungal compounds from *Apium graveolens* L. Seeds. *J. Agric. Food Chem.*, 49: 142-145.
- Ni, M. and L. Dom, 2009. Anti-aging secrets from china liven up your meals and live longer. Yo San University. September 1, 2009. http://www.bottomlinesecrets.com/article.html?article_id=49566.
- Nilsson, A., 2009. Effects of GI and content of indigestible carbohydrates of cereal-based evening meals on glucose tolerance at a subsequent standardised breakfast. *Eur. J. Clin. Nutr.*, 60: 1092-1099.
- Petlevski, R., M. Hadzija, M. Slijepcevic, D. Juretic and J. Petrik, 2003. Glutathione S-transferase and malondialdehyde in the liver of NOD mice after short term treatment with plant mixture extract P-9801091. *Phytother. Res.*, 17: 311-314.
- Popovic, M., B. Kaurinovic, S. Trivic, N.N. Mimica-Dukic and M. Bursac, 2006. Effect of celery (*A. graveolens*) extracts on some biochemical parameters of oxidative stress in mice treated with carbon tetrachloride. *Phytother. Res.*, 20: 531-537.
- Reeves, P.G., F.H. Nielson and G.C. Fahmy, 1993. Reports of the American Institute of Nutrition, adhoc wiling committee on reformulation of the AIN 93. rodent diet. *J. Nutr.*, 123: 1939-1951.
- Richmond, N., 1973. Colorimetric determination of total cholesterol and high density lipoprotein cholesterol (HDL-c). *Clin. Chem.*, 19: 1350-1356.
- Roberts, C.K., J. Barnard, R.K. Sindhu, M. Jurczak, A. Ehdaie and N.D. Vaziri, 2006. Oxidative stress and dysregulation of NADPH oxidase and antioxidant enzymes in diet-induced metabolic syndrome. *Metabolism*, 55: 928-934.
- Rossetto, M., A. Lante, P. Vanzani, P. Spettoli, M. Scarpa and A. Rigo, 2005. Red chicories as potent scavenger of highly reactive radicals: A study on their phenolics composition and peroxy radical trapping capacity and efficiency. *J. Agric. Food Chem.*, 53: 8169-8175.
- Sarawathy, S.D. and C.S. Devi, 2001. Modulating effect of Liv. 100, an ayurvedic formulation on antituberculosis drug-induced alterations in rat liver microsomes. *Phytother. Res.*, 15: 501-505.
- Shimaa, Z.I., 2008. Hepatoprotective effect of some Egyptian plants against CCl4-hepatotoxicity in rats. Master Thesis, Faculty of Home Economic, Al-Azhar University.
- Shinnick, F.L., S.L. Ink and J.A. Marie, 1990. Dose response to a dietary oat bran fraction in cholesterol-fed rats. *J. Nutr.*, 120: 561-568.
- Singh, A. and S.S. Handa, 1995. Hepatoprotective activity of *Apium graveolens* and *Hygrophila auriculata* against paracetamol and thioacetamide intoxication in rats. *J. Ethnopharmacol.*, 49: 119-126.
- Snedecor, G.W. and W.G. Cochran, 1986. *Statistical Methods*. 4th Edn., Iowa State University Press, Ames, Iowa, USA., pp: 91.
- Son, S. and B.A. Lewis, 2002. Free radical scavenging and antioxidative activity of caffeic amide and ester analogues: Structure-activity relationship. *J. Agric. Food Chem.*, 50: 468-472.
- Talati, R., W.L. Baker, M.S. Pabilonia, C.M. White and C.I. Coleman, 2009. The effects of barley-derived soluble fiber on serum lipids. *Ann. Family Med.*, 7: 157-163.
- Tsi, D. and B.K. Tan, 2000. The mechanism underling the hypocholesterolemic activity of celery extracts (aqueous and butanol extracts) in genetically hypercholesterolemic (RICO) rats. *Life Sci.*, 14: 755-767.

- Urias-Silvas, J.E., P.D. Cani, E. Delmee, A. Neyrinck, M.G. Lopez and M.N. Delzenne, 2007. Physiological effects of dietary fructans extracted from *Agaves tequilana* and *Dasyilirion* spp. *Br. J. Nutr.*, 99: 254-261.
- Wahlefeld, A.W., 1974. *Methods of Enzymatic Analysis*. Chapt. 5, Academic Press, New York, pp: 1831-1835.
- Yang, J.L., Y.H. Kim, H.S. Lee, M.S. Lee and Y.K. Moon, 2003. Barley β -glucan lowers serum cholesterol based on the up-regulation of cholesterol 7-hydroxylase activity and mRNA abundance in cholesterol fed rats. *J. Nutr. Sci.*, 49: 381-387.