

ISSN 1996-3424

Asian Journal of
Dermatology

<http://knowledgiascientific.com>

Knowledgia
SCIENTIFIC
A Place to Publish Outstanding Research

Tinea Capitis in North Gaza Strip-Palestine

¹E.K. Abou El-Khair, ²M.H. Taleb, ²I. Albasyony and ²N. Khoder

¹Department of Biology, Faculty of Science, Al Azhar University, Gaza, Palestine

²Faculty of Pharmacy, Al Azhar University, Gaza, Palestine

Corresponding Author: E.K. Abou El-Khair, Department of Biology, Faculty of Science, Al Azhar University, Gaza, Palestine

ABSTRACT

Dermatophyte infections constitute an important public health problem in different parts of the world. Dermatophytosis, commonly referred to as ringworm, is a superficial fungal infection caused by filamentous fungal species belonging to three anamorphic genera, *Trichophyton*, *Microsporum* and *Epidermophyton*. Dermatophytes choose areas of safety for their growth, such as superficial keratinous tissues, to escape from host defense mechanisms. Although, dermatophytes can be isolated worldwide, many species are only encountered in geographically restricted areas. This study was carried out to identify the etiological agents of tinea capitis in north Gaza strip Palestine and its mode of transmission. This study was carried out for three years from September 2009 to August 2012. A total of 100 samples of suspected tinea capitis were collected heads (scalp), primarily diagnosed by the dermatologists in three primary health care centers in North Gaza strip. Cultural characteristics, morphological characteristics and physiological tests (e.g., urease test, NaCl 3% test, hair perforation test, rice grain test) were used for the identification of the causative dermatophytes. The present results revealed that the most common dermatophytes caused tinea capitis in North Gaza strip were *Microsporum canis* (92.5%) and *Trichophyton mentagrophytes* (7.5%). The domestic animals played an important role in transporting the disease which resulted in prevalence of tinea capitis in North Gaza strip compared to the neighboring countries.

Key words: Tinea capitis, *Microsporum canis*, *Trichophyton mentagrophytes*, Gaza strip

INTRODUCTION

The dermatophytes are a group of a closely related fungi that have the ability to invade the stratum corneum of the epidermis and keratinized tissues derived from it, such as skin, nail and hair of humans and animals (Dobrowolska *et al.*, 2006). Tinea capitis is a highly transmissible infection of the scalp and hair caused by dermatophytes. It infects all age groups especially the children. It is endemic in some of the poorest countries (Gonzalez-Juanatey *et al.*, 2004). Tinea capitis is uncommon after puberty. The mechanism of defense are mainly the interaction between dermatophytes and local defense mechanisms such as unsaturated transferrin, the migration of polymorphonuclear leucocytes into the area of infection and T lymphocyte activation (Hay *et al.*, 2004). Though a few dermatophyte species are endemic to certain areas and absent altogether in others, most dermatophytoses worldwide are caused by only a half-dozen species (Aly, 1994). There are around 30 species, which act as etiologic agents of dermatophytosis. From these, *Trichophyton rubrum* constitutes the majority of isolates causing dermatophytosis. *Trichophyton mentagrophytes* var. *interdigitale*, *Trichophyton tonsurans*, *Microsporum canis*, *Microsporum gypseum* and *Epidermophyton floccosum* are also known as representative species of

this infection (Das *et al.*, 2007). *Microsporum canis* is a dermatophyte, causing ringworm of the scalp and skin in children and occasionally reported as the cause of nail infection (Summerbell *et al.*, 2007). Some patients with *Microsporum* infections may require longer courses of treatment depending on clinical and mycological findings, sometimes for as long as 12 weeks (Al Sogair and Hay, 2000).

An epidemiological study of tinea capitis was carried out in 1996 among 7,525 primary school children in the Nablus strip in Palestine (Ali-Shtayeh *et al.*, 1998). In Palestinian territories, *M. canis* was first reported in 1975 (Alteras *et al.*, 1979). Since then, this dermatophyte has spread throughout the country becoming an important cause of scalp ringworm (Alteras *et al.*, 1986).

In Egypt, *Trichophyton violaceum* are dominant and accounted for most (71.1%) of recovered dermatophytes, followed by *Microsporum canis* (21.09%), *Trichophyton rubrum* (6.2%) and *Microsporum boullardii* (0.49%), both *Epidermophyton floccosum* and *Trichophyton tonsurans* were rarely isolated (0.24%) (Zaki *et al.*, 2008). In Mexico, *Trichophyton rubrum* is the main agent causing dermatophytosis (Arenas 2002).

This study was carried out to identify the etiological agents of tinea capitis in north Gaza strip Palestine and its mode of transmission.

MATERIALS AND METHODS

Samples selection: Samples were selected from clinically diagnosed children in primary health care centers of North Gaza strip (Beit Hanoun clinic, Jabalia clinic and El-Sheimaa primary health center). Samples were obtained before any local or systemic antifungal treatment. A total of 300 children, aged 1-14 years, were checked for tinea capitis infections comprising 192 males and 108 females that checked into 3 primary clinics in North Gaza strip. Only one hundred samples were diagnosed as tinea capitis by the dermatologists in these clinics. The selected primary health clinics represent different hygienic conditions, habitats and socioeconomic backgrounds (i.e., urban area, refugee camp and rural area). Data of age, sex, parents' profession, family size, number of home rooms and presence of animal pets or domestic animals in the child's environment were taken in all cases.

Samples collection and transportation: The infected areas in children's heads were rubbed for 30 sec using sterile cotton swabs then the swabs were pressed onto plates containing Sabouraud's dextrose agar plus chloramphenicol and cyclohexamide (Friedlander *et al.*, 2009). Specimens were covered tightly, wrapped in sterile brown paper packets and transported to the laboratory.

Samples cultivation: The petri plates were incubated at 25°C up to 2 weeks (after 5 days, the plates were inspected for growth daily).

Identification of tinea capitis causing dermatophytes: One hundred isolates were collected over three years period (2009-2012). All isolates were identified by standard methods, which included identification based on the cultural characteristics and morphological characteristics of the colonies (Larone, 1993; Kane *et al.*, 1999). Additional tests included the ability to produce urease, as well as the hair perforation test were performed (Larone, 1993).

Morphological characteristics: Each sample collected was divided into two portions. One portion was used for direct microscopic examination and the second portion was cultured on Sabouraud's dextrose agar, incubated at 28°C for 2 weeks and examined for the colony formation.

Microscopic examination for positive fungi cultures was done using the lacto phenol cotton blue wet mount method.

Cultural characteristics: Identification of the samples after 2 weeks of incubation at 28°C in the microbiology research laboratory carried out according to Rebell and Taplin (1979).

Physiological characteristics

Biochemical reactions (Urease test): Urease test applied on all the collected samples after growing of cultures, incubating for 5-7 days at 27°C, urea is splitted into ammonia, resulting in a pH change to alkaline and therefore in the change of the color of the phenol red containing medium from a straw yellow to pink fuschia after 6 days on Christensen's agar of incubation at 27°C.

Confirmatory tests (Rice grain test): With a long handled inoculating needle, a small portion of the isolated colony was transferred to be tested on a vial containing sterile rice grains. The flasks were incubated at 30°C and inspected for growth for 10 days.

***In vitro* hair perforation test:** Short strands of disinfected hair are deposited on a fragment of the studied culture, in Petri dishes with 25 mL of sterile distilled water containing 3 drops of 10% dermatophyte extract (De Hoog *et al.*, 2002). After two weeks of incubation at 25°C, the hair strands covered by mycelium were examined under microscope by mounting in chloral-lacto phenol. The perpendicular to the long axis of the hair was as special character for hair perforation test.

NaCl tolerance test: Sabouraud's glucose agar supplemented with 3% NaCl was used to detect species salt tolerance, as well as the stimulation of macroconidia formation (Summerbell and Kane, 1999). All isolates were subcultured on 3% NaCl and incubated at 25°C for 8 days.

RESULTS

Identification of isolated dermatophytes: Identification of dermatophyte species is essentially based on cultural and morphological characteristic.

Morphological characteristics

Direct microscopical examination: Eighty samples out of the total (100 samples) were KOH positive; showing clear hyphae and characterized mycelium. The results showed that only 80% of the samples examined by direct microscopic examination were positive for fungi (Fig. 1).

Indirect microscopical examination: According to the indirect microscopical examination, 74 samples of the eighty samples (KOH positive) produced septate hyphae, macroconidia and few microconidia. Macroconidia were typically long spindle-shaped, with 5-15 cells, verrucose, thick-walled and often had a terminal knob, its diameter between 8.9-12 µm (Fig. 2). The septal walls were thin, microconidia were rare, unicellular and clavate to pyriform in shape, nodular bodies and chlamydospores were present, these characters of the isolated dermatophytes which are shown in Fig. 3-7 were indicated to a degree for presence of *M. canis*.

The present study revealed that the obvious difference in the microscopical features of macroconidia of *M. canis* according to the time of sporulation e.g., the terminal knob, length of macroconidia, number of cells and thickness of wall (Fig. 7). As shown in Fig. 8-9 morphological

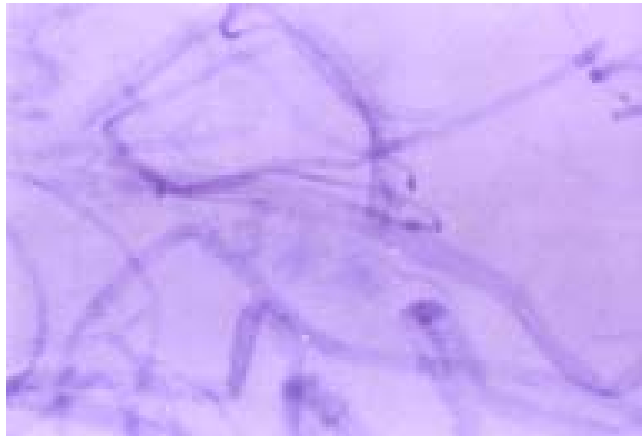


Fig. 1: Septate hyphae with KOH test characteristic for the fungi

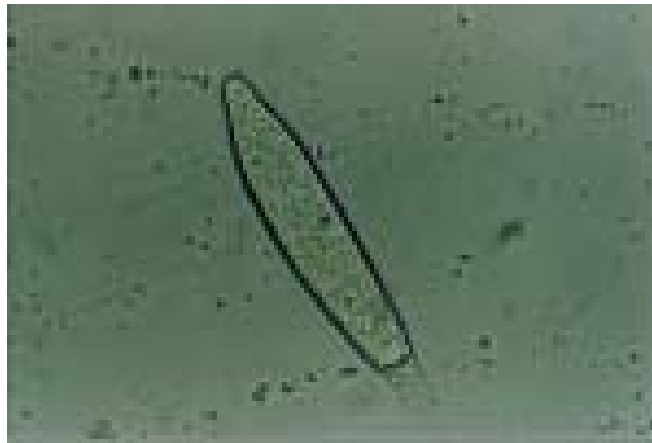


Fig. 2: Morphological characteristics for spindle macroconidia with endy knob of 11 cells with diameter 8.9 μm characterizing for *M. canis* (400x)

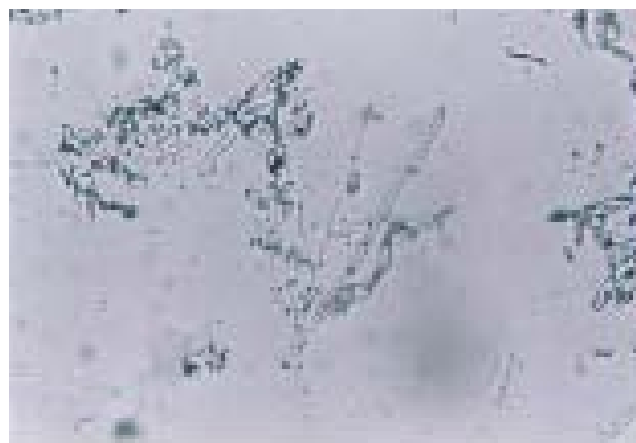

Fig. 3: Morphological characteristic for microconidia, pyriform to round with a long hyphae characterizing for *M. canis* (1000x)

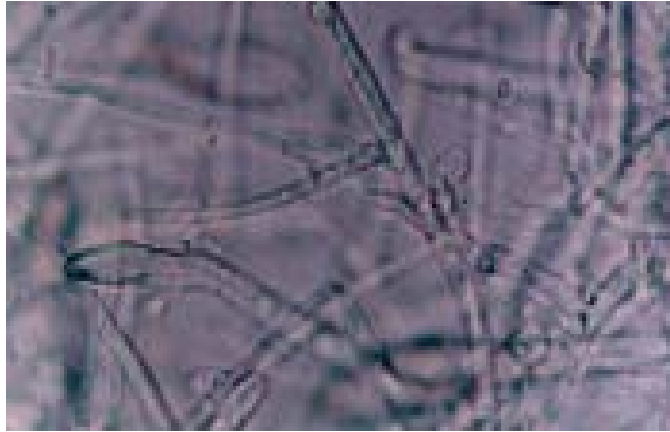


Fig. 4: Morphological features for microconidia, pyriform to round with a long hyphae characterizing for *M. canis* (1000x)



Fig. 5: Multimacroconidia with spindle shape and thin septal walls, characterizing for *M. canis* (400x)

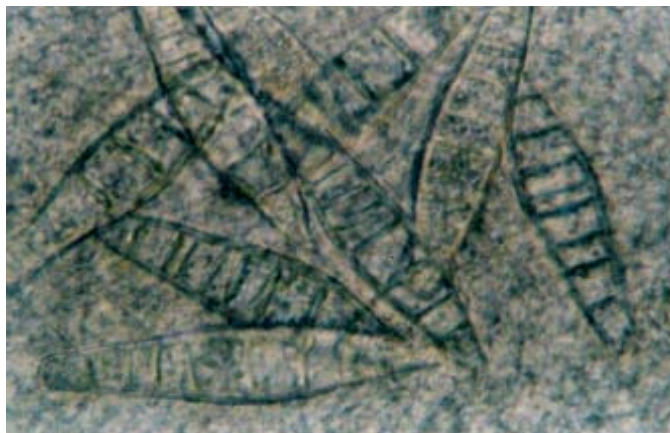


Fig. 6: Multimacroconidia of spindle shape from (7-12 cells) characterizing for *M. canis* (1000x)

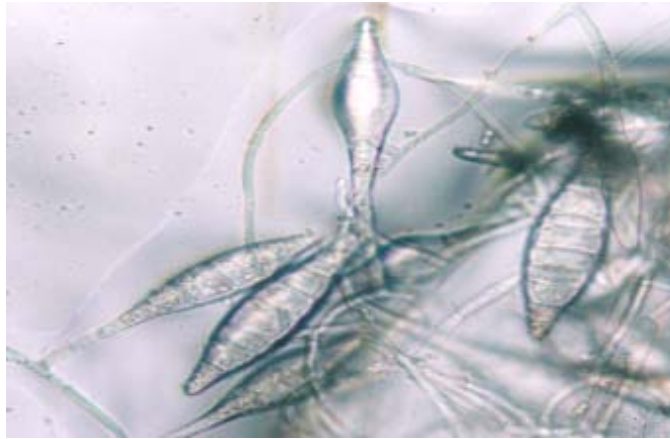


Fig. 7: Multimacroconidia with spindle shape and terminal knob, characterizing for *M. canis* (400x)

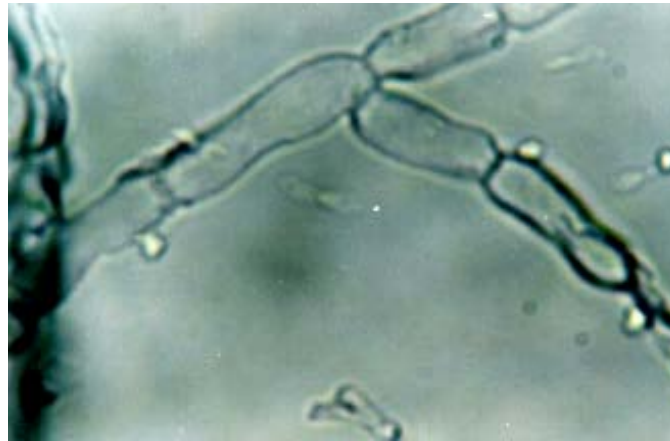

Fig. 8: Morphological characteristics of unicellular macroconidia and clavate to pyriform in shape characterizing for *T. mentagrophytes* (1000x)

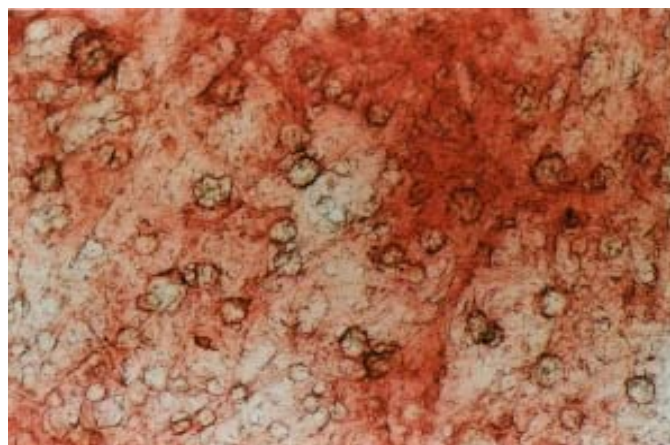


Fig. 9: Morphological characteristics of microconidia arranged in grape-like clusters (engrappe) characterizing for *T. mentagrophytes* (400x)

characteristics of three samples were dissimilar visibly of the total samples. The macroconidial and microconidial form of these isolates, which recognized presence of another species of isolated dermatophytes. As in Fig. 8 and 9, morphologically the most consistent feature of these isolates was the production of globose microaleuriospores arranged in grape-like clusters.

The present work showed thin walled macroaleuriospores, smooth and variable in shape. The current work showed (Fig. 8) cigar-shaped macroconidia with a narrow attachment at the base. These spores measured 20-50×4-8 μm and they had three to five cells. The typical features of these samples are numerous microaleuriospores, some macroaleuriospores and several spiral or coiled hyphae.

The present study also revealed that macroconidia and microconidia are produced on primary isolation media, without needing for subculturing on media to stimulate sporulation and the morphological characteristics of macroconidia differentiated according to the examination of colony age.

Cultural characteristics of dermatophytes: Cultural characteristics of the colonies of the eighty isolates in Table 1 showed that seventy-four samples produced whitish, cottony surface growth with a golden yellow reverse pigment, additionally to presence of considerable variation between growing colonies in its cultural characteristics from deep yellow to golden yellow cottony surface. On the other hand, three samples developed red-pigmented, granular colonies.

Microsporum canis matures within 6 to 10 days produced colonies that were flat, spreading, white to cream colored, with a dense cottony, granular to coarsely fluffy to hairy surface (Fig. 10a, b) which showed some radial grooves (Fig. 11a, b).

On the other hand, as in Fig. 12 and 13, three samples developed red-pigmented, granular colonies. Growth rate of these colonies is moderate, had 8-10 days for complete growing, its texture is deep and cottony.

The present observations showed that the colonies had a red white to white creamy in the first week of incubation (Fig. 12a, b). On the contrast of *M. canis*, noted no changes in growth rate and in the second week of incubation of culture colonies and the diameter of the growing colonies were constant in all (Fig. 13a, b). In agreement of the current observation in Fig. 13a, b, no halos until the tenth day of incubation, this indicates to presence of *T. mentagrophytes*.

Physiological characteristics

Biochemical reactions

Urease test: In the present study, colonies with a golden - yellow reverse pigment were urease positive, also colonies with flat rapidly growing granular cream, reddish-brown in color were urease positive; however, the later colonies consumed shorter time to appear the fuchsia color.

Figure 14 and 15 showed considerable differences in cultural characteristics after incubation in urease media in spite of the result of test e.g. all of collected samples in the current study produced positive urease test either the thirty seven samples as yellow cottony colonies or the three

Table 1: Cultural characteristics of dermatophytes

Sample No.	Cultural characteristics	Incubation period (days)
74	Whitish, cottony colony a golden-yellow with prominent grooves reverse pigment	5-14
6	Red-pigmented, granular colony, buff to tan colony	5-14

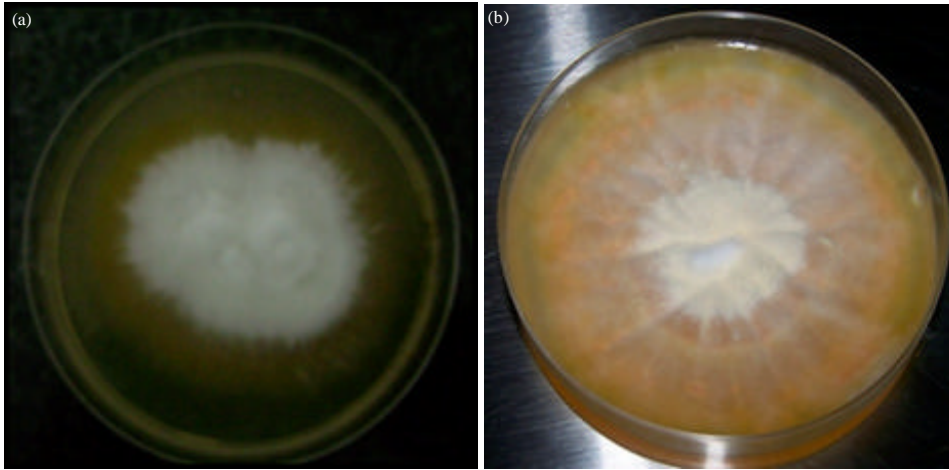


Fig. 10(a-b): (a) Seventh-day-old, white to deep yellow cottony colony of *Microsporum canis* on Sabouraud's dextrose agar, its diameter 8.7 cm and (b) Eighth-day-old, white to deep yellow powdery colony of *Microsporum canis* on Sabouraud's dextrose agar

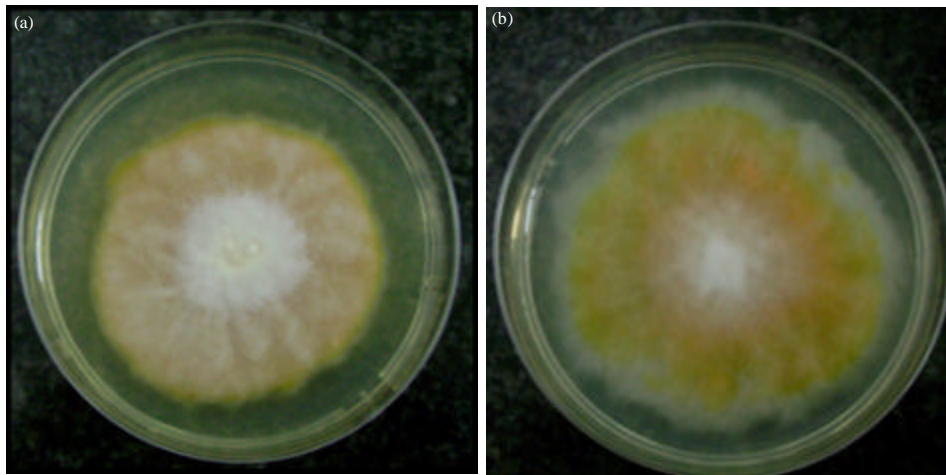


Fig. 11(a-b): (a) Tenth-day-old, white to deep golden yellow colony of *Microsporum canis* on Sabouraud's dextrose agar and (b) Ninth-day-old, white to deep yellow powdery colony of *Microsporum canis* on Sabouraud's dextrose agar

samples as flat white puff colony. Figure 16 showed that the difference in period of appearing of result of test between *T. mentagrophytes* and *M. canis*. Hydrolysis of urea on urea agar reported that high percent of *T. mentagrophytes* strains were urease positive in less than 10 days.

Confirmatory tests

Rice grain test: All isolated samples in the study were typically produce a bright yellow pigment, which revert to typical colony on rice grains as showed in Fig. 17a-c. Rice grain test was applied to differentiate between *M. canis* and *M. audouinii* to confirm the presence of *M. canis* in most of collected isolates.

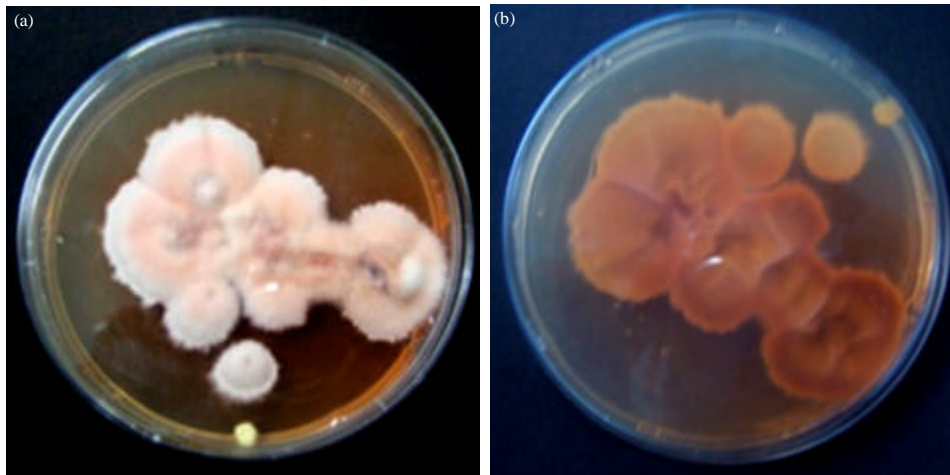


Fig. 12(a-b): (a) Seventh-day-old, red to white to cream-colored powdery colony characteristic for *T. mentagrophytes* on Sabouraud's dextrose agar and (b) The reverse of seventh day old *T. mentagrophytes* colony on Sabouraud's dextrose agar

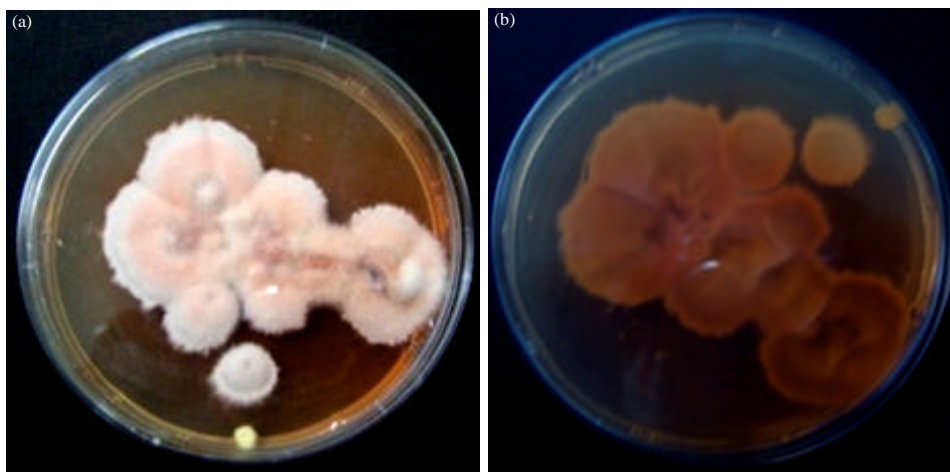


Fig. 13(a-b): (a) Tenth-day-old, red to white to cream-colored powdery colony characteristic for *T. mentagrophytes* on Sabouraud's dextrose agar and (b) The reverse of tenth day old *T. mentagrophytes* colony on Sabouraud's dextrose agar

***In vitro* hair perforation test:** The present study showed perforation for the most samples in 8-15 days (Fig. 18). It was used for the distinction between atypical strains of *M. canis* (positive test) and *M. audouinii* or *M. equinum* (negative test).

NaCl tolerance test: All the collected samples produced negative test with Sabouraud's dextrose agar supplemented with 3% NaCl (Fig. 19).

The identified dermatophyte caused tinea capitis in north Gaza strip: Table 2 represented the physiological characteristics for isolated dermatophytes. Seventy four samples were positive for

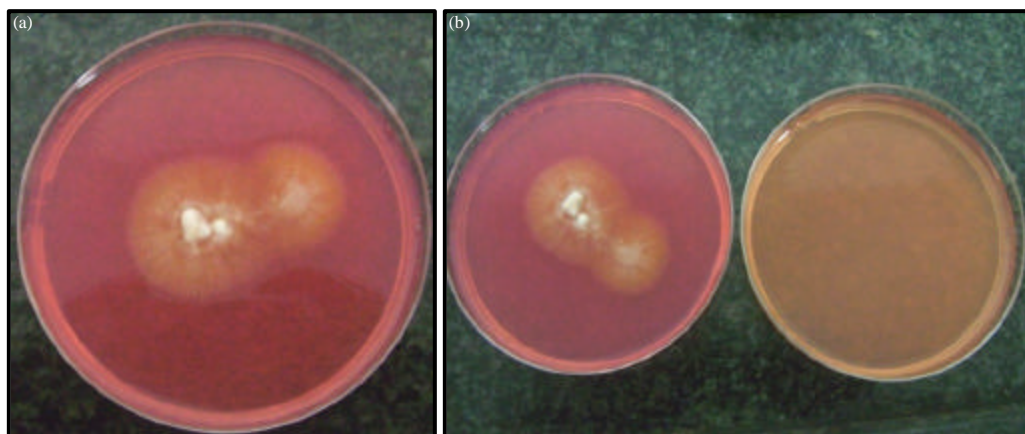


Fig. 14(a-b): Urease test of characterized colony of *M. canis*, change color from yellow to fuchsia pinkish after 10 days (slow positive test)




Fig. 15(a-b): Urease test of characterized colony of *T. mentagrophytes*, change color from yellow to fuschia pinkish after 5 days (rapid positive test)

Table 2: Physiological characteristics for isolated dermatophytes

No. of samples	Urease test	Rice grain test	NaCl 3% test	Hair perforation test
74	Positive	Positive	Negative	Positive within 14 days
6	Slow positive	Positive	Negative	Positive within 14 days

Table 3: Period of maturation of isolated dermatophytes

Isolated dermatophyte	No. of examined samples	Period of maturation (days)
<i>M. canis</i>	74	5- 10
<i>T. mentagrophytes</i>	6	5-10

urease and rice grain tests and negative for growth in 3% NaCl supplemented medium meanwhile 6 samples were negative for urease and rice grain tests but able to grow at 3% NaCl supplemented medium.

Table 3 represented the period of maturation for the isolated dermatophytes which also confirm the identification of the isolated dermatophytes.

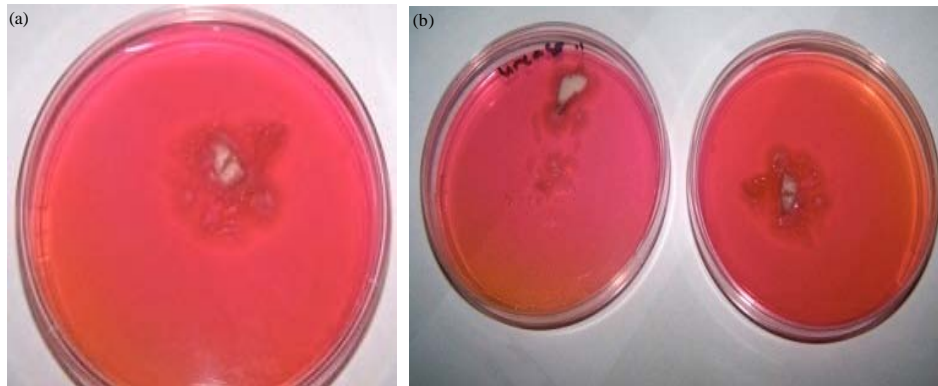


Fig. 16(a-b): (a) Seventh-day-old colony of *M. canis* on urease media and (b) Fifth day-old colony of *T. mentagrophytes* on urease media

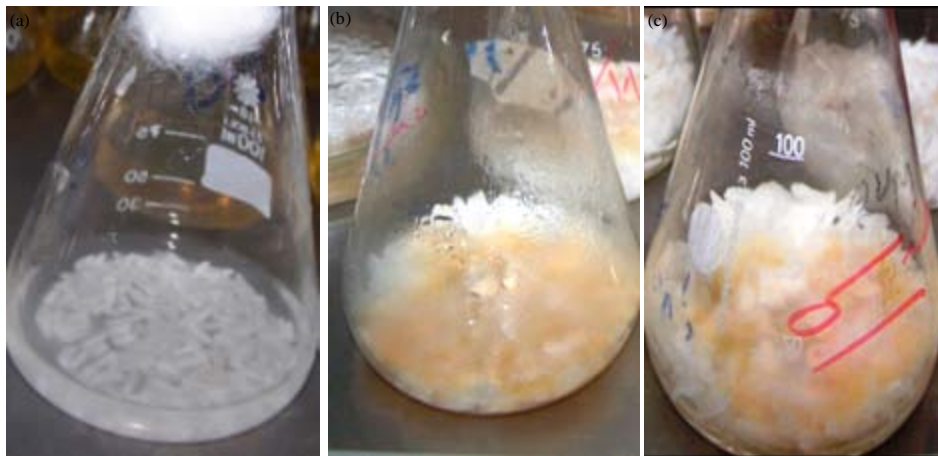


Fig. 17(a-c): Rice grains with isolated samples of (a) *M. canis* before incubation, (b) *M. canis* after ten days of incubation and (c) *T. mentagrophytes* after ten days of incubation



Fig. 18: Hair perforation by the isolated *M. canis* after 2 weeks of incubation



Fig. 19: No growth on 3% NaCl supplemented SDA after 8 days of incubation

The present study revealed that, *M. canis* was the main causative agent of tinea capitis in North Gaza district (92.5%).

The present work revealed that most of infections were due to *M. canis*, thus agreed that contact with domestic animals is probably the most important factor affecting the rapid spread of tinea capitis.

Mode of transmission of *T. mentagrophytes* mostly by human-to-human (anthropophilic) or rarely rodents or rabbits (zoophilic) according to the strain. *T. mentagrophytes* was ranked second in frequency at 7.5% (3 cases).

DISCUSSION

The dermatophytes are a group of a closely related fungi that have the ability to invade the skin, nail and hair of humans and animals (Dobrowolska *et al.*, 2006).

Tinea capitis is dermatophytosis of the scalp hair follicles, generally producing inflammatory or noninflammatory alopecia. Infection occurs predominantly in prepubertal children older than 6 months, although infection can occur in all age groups. Tinea capitis is one of the most common infectious conditions in children and it occurs worldwide (Elewski, 1996). In the period 99-01 represented 8.4% of the reasons for registering the first consultation 37% of cases in children, in whom it predominated tinea capitis (50%). This is a pathology own childhood and puberty is no tendency for spontaneous regression and healing due to changes in the lipid composition of the scalp. While cases are described in adulthood these are exceptional (Navarrete *et al.*, 1999). Elewski (2000) reported that the predominant organisms vary according to the geographic region and it is often difficult to determine the precise distribution of a particular dermatophyte. Consequently, the causative agents in tinea capitis have not been investigated in many parts of the world and the agents responsible for dermatophytosis tend only to be identified in regions where there are laboratories to perform the mycologic studies.

Identification of dermatophyte species is essentially based on cultural and morphological characteristic. However, the identification is complicated and laborious due to the morphological similarity, variability and polymorphism shown by dermatophytes (Toshio, 2008).

Direct microscopic examination of potassium hydroxide (KOH)-prepared specimens is the simplest, cheapest method used for the diagnosis of mycotic infections of the skin (Panasiti *et al.*, 2006).

The results showed that only 80% of the samples examined by direct microscopic examination were positive for fungi.

According to the indirect microscopical examination, 74 samples of the eighty samples were indicated to a degree for presence of *M. canis* in agreement with keys identification of (Rebell and Taplin, 1970).

In the current study, cultural characteristics of the colonies of the eighty isolates showed that 74 samples produced whitish, cottony surface growth with a golden yellow reverse pigment (*M. canis*). Meanwhile, 3 samples developed red-pigmented, granular colonies (*T. mentagrophytes*).

Colonies with a golden-yellow reverse pigment were urease positive, also colonies with flat rapidly growing granular cream, reddish-brown in color were urease positive; however, the later colonies consumed shorter time to appear the fuchsia color. There is a considerable differences in cultural characteristics after incubation in urease media in spite of the result of test e.g., the difference in period of appearing of result of test between *T. mentagrophytes* and *M. canis*.

All the collected samples produced negative test with Sabouraud's dextrose agar supplemented with 3% NaCl. In agreement with Kane *et al.* (1999) who reported that *T. rubrum* strains had strong, restricted growth on 3% NaCl-supplemented Sabouraud's dextrose agar and produced no conidia. This test revealed that no presence of *T. rubrum* between isolates. The growth in NaCl concentrations was found to be statistically significant for 3% NaCl.

Rice grain test was applied to differentiate between *M. canis* and *M. audouinii* to confirm the presence of *M. canis* in most of collected isolates (Larone, 2002; Summerbell *et al.*, 2007). The present study also showed hair perforation for the most samples in 8-15 days. It was used for the distinction between atypical strains of *M. canis* (positive test) and *M. audouinii* or *M. equinum* (negative test) (Padhye *et al.*, 1980).

The period of maturation for the isolated dermatophytes also confirm the identification of the isolated dermatophytes.

The present study revealed that most of infections were due to *M. canis*, thus agreed that contact with domestic animals is probably the most important factor affecting the rapid spread of tinea capitis. The causative agent varies between continents and from one country to another. For instance, *Microsporum canis* is the predominant pathogen worldwide, while *Trichophyton tonsurans* is the main causative agent in the USA (Fitzpatrick, 2003).

Another work done over a period of 8 years and stated that dermatophytes were recovered from 12 animal species in the North Island of New Zealand. A total of 552 dermatophytes were isolated and belonged to the *Microsporum* (6 species) and *Trichophyton* (6 species) genera (Carman *et al.*, 1979).

The present study revealed that, *M. canis* was the main causative agent of tinea capitis in North Gaza district (92.5%); this in agreement with Jhangir *et al.* (1999) they reported that *M. canis* is predominant in Iran. In occupied Palestinian land, *M. canis* was first reported in 1975 (Alteras *et al.*, 1979).

T. violaceum and *M. canis* were also reported to be the predominant scalp ringworm pathogens in many countries of the Near East, including Saudi Arabia (Venugopal and Venugopal, 1993), Kuwait (Al-Fouzan *et al.*, 1992) and Iran (Khosravi *et al.*, 1994).

The results on etiological agents of tinea capitis from the current work revealed that the zoophile dermatophyte, *M. canis* continued to be the predominant etiological agent of tinea capitis in North of Gaza strip. 92.5% of total isolates and this may attributed to presence of much domestic animals such as cats (the major reservoir in *M. canis*) and dogs. As shown in the current work,

T. mentagrophytes as a causative agent of tinea capitis, with very low percentage indicated that the peoples had a good idea about the dealing with the infected patients.

Therefore, to safeguard the children and other vulnerable people from being infected, it is mandatory to control of keeping household animals (e.g., cats, dogs, rodents) the main cause of transmission of tinea capitis in North Gaza strip. Starting in treatment of the infected cases to avoid transmission of disease from human to human. Considering of cascade of identification used in study as sharp decision for incognito cases and recommended the ministry of health to consider the KOH test for identifying the fungi is insensitive test.

The results of this pilot study justifies the necessity for further large scale study that address the topics comprehensively.

REFERENCES

- Al Sogair, S. and R.J. Hay, 2000. Fungal infection in children: *Tinea capitis*. Clin. Dermatol., 18: 679-685.
- Al-Fouzan, A.S., A. Nanda and K. Kubec, 1992. Dermatophytosis of children in Kuwait: Aprospective survey. Int. J. Dermatol., 32: 798-801.
- Ali-Shtayeh, M.S., H.M. Arda and S.I. Abu-Ghdeib, 1998. Epidemiological study of tinea capitis in schoolchildren in the Nablus area (West Bank). Mycoses, 41: 243-248.
- Alteras, I., E.J. Feuerman, M. David, B. Shohat and E. Livni, 1979. Widely disseminated cutaneous candidosis in adults. Sabouraudia, 17: 383-388.
- Alteras, I., E.J. Feuerman, M. David and R. Segal, 1986. The increasing role of *Microsporum canis* in the variety of dermatophytic manifestations reported from Israel. Mycopathologia, 15: 105-107.
- Aly, R., 1994. Ecology and epidemiology of dermatophyte infections. J. Am. Acad. Dermatol., 31: S21-S24.
- Arenas, R., 2002. Dermatofitosis en Mexico. Rev. Iberoam. Micol., 19: 63-67.
- Carman, M.G., F.M. Rush-Munro and M.E. Carter, 1979. Dermatophytes isolated from domestic and feral animals. New Zealand Vet. J., 27: 136,143-144.
- Das, S., R. Goyal and S.N. Bhattacharya, 2007. Laboratory-based epidemiological study of superficial fungal infections. J. Dermatol., 34: 248-253.
- De Hoog, G.S., J. Guarro, J. Gene and M.J. Figueras, 2002. Atlas of Clinical Fungi. 2nd Edn., Centraalbureau voor Schimmelcultures universitat Roviar Virgili, Utrecht/Reus, Pages: 1126.
- Dobrowolska, A., P. Staczek, C.A. Kaszuba and M. Kozłowska, 2006. PCR-RFLP Analysis of the dermatophytes isolated from patients in Central Poland. J. Dermatol. Sci., 42: 71-74.
- Elewski, B.E., 1996. *Tinea capitis*. Dermatol. Clin., 14: 23-31.
- Elewski, B.E., 2000. *Tinea capitis*: A current perspective. J. Am. Acad. Dermatol., 42: 1-20.
- Fitzpatrick, T.B., 2003. Dermatology in General Medicine. 6th Edn., Mc-Graw Hill, New York, USA.
- Friedlander, S.F., B. Pickering, B.B. Cunningham, N.F. Gibbs and L.F. Eichenfield, 2009. Use of the cotton swab method in diagnosing tinea capitis. Pediatrics, 104: 276-279.
- Gonzalez-Juanatey, C., A. Testa, A. Garcia-Castelo, C. Garcia-Porrúa, J. Llorca and M.A. Gonzalez-Gay, 2004. Active but transient improvement of endothelial function in rheumatoid arthritis patients undergoing long-term treatment with anti-tumor necrosis factor α antibody. Arthritis Rheumatism, 51: 447-450.

- Hay, R.J., M.K. Moore, T. Burns, S.M. Breathnach, N. Cox and C. Griffins, 2004. Rook's Textbook of Dermatology. 7th Edn., Blackwell Science, Oxford, UK., pp: 1405-1506.
- Jhangir, M., I. Hussain, K. Khushid and T.S. Haroon, 1999. A clinico-etiological correlation in tinea capitis. *Int. J. Dermatol.*, 38: 275-278.
- Kane, J., R.C. Summerbell, L. Sigler, S. Krajdén and G. Land, 1999. Laboratory Handbook of Dermatophytes. Star Publishers, Belmont C.A., USA.
- Khosravi, A.R., M.R. Aghamirian and M. Mahmoudi, 1994. Dermatophytoses in Iran. *Mycoses*, 37: 43-48.
- Larone, D.H., 1993. Medically Important Fungi: A Guide to Identification. 2nd Edn., ASM Press, USA., pp: 117-137.
- Larone, D.H., 2002. Medically Important Fungi. 4th Edn., ASM Press, Washington, DC., USA., pp: 310-348.
- Navarrete, O., H. Vazquez and R. Arenas, 1999. Tinea de la cabeza en el anciano. *Dermatologia Rev. Mex.*, 43: 123-126.
- Padhye, A.A., C.N. Young and L. Ajello, 1980. Hair perforation as a diagnostic criterion in the identification of Epidermophyton, Microsporum and Trichophyton species. Proceedings of the 5th International Conference on the Mycoses, Superficial, Cutaneous and Subcutaneous Infections, April 27-30, 1980, Caracas, Venezuela, Spain, pp: 115-120.
- Panasiti, V., R.G. Borroni, V. Devirgiliis, M. Rossi and L. Fabbrizio *et al.*, 2006. Comparison of diagnostic methods in the diagnosis of dermatomycoses and onychomycoses. *Mycoses*, 49: 26-29.
- Rebell, G. and D. Taplin, 1970. Dermatophytes, Their Identification and Recognition. 2nd Edn., University of Miami Press, Miami, FL., USA.
- Rebell, G. and D. Taplin, 1979. Dermatophytes Their Recognition and Identification. University of Miami Press, Florida, USA.
- Summerbell, R.C. and J. Kane, 1999. Physiological and other Tests for Identifying Dermatophytes. In: Laboratory Handbook of Dermatophytes: A Clinical Guide and Laboratory Manual of Dermatophytes and other Filamentous Fungi from Skin, Hair and Nails, Kane, J., R.C. Summerbell, L. Sigler, S. Krajdén and G. Land (Eds.). Star Publishing, Belmont, CA., USA., pp: 45-79.
- Summerbell, R.C., I. Weitzman and A.A. Padhye, 2007. Trichophyton, Microsporum, Epidermophyton and Agents of Superficial Mycoses. In: Manual of Clinical Microbiology, Murray, P.R., E.J. Baro, J.H. Jorgensen, M.L. Landry and M.A. Pfaller (Eds.). 9th Edn., ASM Press, Washington, USA., pp: 1874-1897.
- Toshio, K., 2008. Molecular approaches in the diagnosis of dermatophytosis. *Mycopathologia*, 166: 307-317.
- Venugopal, P.V. and T.V. Venugopal, 1993. Tinea capitis in Saudi Arabia. *Int. J. Dermatol.*, 32: 39-40.
- Zaki, S.M., N. Ibrahim, K. Aoyama, Y.M. Shetaia, K. Abdel-Ghany and Y. Mikami, 2008. Dermatophyte infections in Cairo, Egypt. *Mycopathologia*, 167: 133-137.