

ISSN 1996-0727

Asian Journal of  
**Developmental**  
Biology

## Stem Cells for Treating Ankylosing Spondylitis Disease

<sup>1,2</sup>Sarder Nasir Uddin and <sup>3</sup>Md. Eunos Ali

<sup>1</sup>Developmental Biology Lab., Department of Biology and Chemistry,  
Graduate School of Medicine, Yamaguchi University, Yamaguchi-735-8512, Japan

<sup>2</sup>Biotechnology and Genetic Engineering Discipline, Khulna University, Bangladesh

<sup>3</sup>Gaco Pharmaceuticals and Research Laboratory, Dhaka, Bangladesh

---

**Abstract:** The aim of this study to find out and accumulate the possible way of recent treatments of ankylosing spondylitis specially by using Stem Cells. There is accumulating evidence that anti-tumor-necrosis-factor (anti-TNF) therapy is highly effective in SpA, especially in ankylosing spondylitis and psoriatic arthritis. In ankylosing spondylitis there is an unmet medical need, since there are almost no disease-modifying antirheumatic drugs available for severely affected patients, especially those with spinal manifestations. This review found that the replacement therapy of stem cells led to a new idea: by taking healthy stem cells from the developing goat's bone marrow cells or human blastocyst and transplanting them into the affected area of a ankylosing spondylitis patient. The cell survives and they formed connections with the surrounding tissue. Transplantation strategies based on stem cells present enormous potential for repairing the damage caused by ankylosing spondylitis disease. Stems cells may also be preferable to other tissue, especially if they can be derived from the patient's own body, avoiding potential immunological problems. So, stem cell replacement therapy for ankylosing spondylitis disease will some day become a therapeutic reality.

**Key words:** Ankylosing spondylitis, stem cells, treatment, patients

---

## INTRODUCTION

Ankylosing Spondylitis (AS) is a chronic inflammatory disease which affects primarily the sacroiliac joints and the spine. The term Ankylosing spondylitis is derived from Greek words where the meaning of the word itself infers the nature of the disease. Ankylosing refers to fusing together Spondylitis refers to inflammation of vertebral bone. The cause for Ankylosing spondylitis is unknown and unclear. As it is a progressive disease, the pelvic region is affected first followed by lower back, chest wall, neck, Shoulder, Hips, Knees, Jaw, Eyes, Lungs, Heart and Bowel. Ankylosing spondylitis is a long-term (chronic) disease of the spinal column that affects about 1 in 250 people, mainly young men (Colbert *et al.*, 1994). In patients with active disease, Magnetic Resonance Imaging (MRI) of the spine shows areas of bone marrow edema, the histopathological equivalent of which is unknown. Appel *et al.* (2006) has conducted a study and they correlate inflammation in the spine of patients with AS as revealed by histological examination with bone marrow edema as detected by MRI. They have compared the histopathological findings of zygapophyseal joints from 8 patients with AS and quantified infiltrates of CD3+, CD4+ and CD8+ T-cells as well as CD20+ B cells immunohistochemically. There are lots of patients affected by different diseases like AIDS, Cancer etc. Fully one-third of the world's population is already infected with *Mycobacterium tuberculosis* (Uddin *et al.*, 2006). It is very necessary to control all the diseases, otherwise it will be a big burden to human being.

---

**Corresponding Author:** Sarder Nasir Uddin, Developmental Biology Lab., Department of Biology and Chemistry,  
Graduate School of Medicine, Yamaguchi University, Yamaguchi-735-8512, Japan

Bone marrow edema was evaluated in hematoxylin and eosin stained sections and quantified as the percentage of the bone marrow area involved. All patients with AS showed interstitial mononuclear cell infiltrates and various degrees of bone marrow edema (range from 10 to 60%) in histopathological analysis. This study correlating histopathological changes in the spine of patients with AS with findings in MRI scans suggests that a substantial degree of bone marrow inflammation and edema is necessary to be detected by MRI (Appel *et al.*, 2006). Ankylosing Spondylitis is a type of arthritis that mainly affects the spine. Specifically, Ankylosing Spondylitis is a condition that causes the joints of the spine and the joints between the spine and pelvis to become inflamed. The inflammation caused by Ankylosing Spondylitis results in pain and stiffness in the neck and back (Brooks *et al.*, 1993). Although there is no cure for Ankylosing Spondylitis, exercise can help relieve symptoms and medicines are available to reduce pain. Medical professionals and researchers have not yet been able to determine a cause of Ankylosing Spondylitis, but research indicates that the condition may be partially hereditary (Bowness *et al.*, 1994). In fact there is a strong association between Ankylosing Spondylitis and a gene called HLA-B27. As a result, Ankylosing Spondylitis is often thought of and referred to as an autoimmune disease (Khan, 1995). The differential distribution of a functional polymorphism in the HLA-E gene suggests a possible role of natural killer function in AS pathogenesis (Cascino *et al.*, 2007). Today there are two main biologic agents targeting TNF- $\alpha$ : the chimeric monoclonal IgG<sub>1</sub> antibody infliximab (Remicade) with human constant and murine variable regions and the recombinant 75 kDa TNF receptor IgG<sub>1</sub> fusion protein etanercept (Enbrel). Both capture soluble TNF- $\alpha$  in the plasma; etanercept also captures TNF- $\beta$ . Infliximab also binds to cell-membrane-bound TNF- $\alpha$ , possibly leading to cell lysis. These differences may account for the somewhat different clinical efficacies of the two compounds. The elimination half-life is 210 h for infliximab and 115 h for etanercept. The manufacturers estimate that the numbers of patients treated with these compounds worldwide are, respectively 200,000 and 150,000 (Braun and Sieper, 2002).

Ankylosing Spondylitis (AS) is a chronic inflammatory disease. It is part of a group of rheumatic diseases termed seronegative spondyloarthropathies (vertebral joints) that share the human antigen HLA-B27. AS is seronegative (serum negative) because a rheumatoid factor is not detected in the patient's blood (serum) (Fig. 1). AS is considered to be hereditary, although environmental factors have been suggested. Most people with the HLA-B27 antigen do not develop AS. It is known to affect

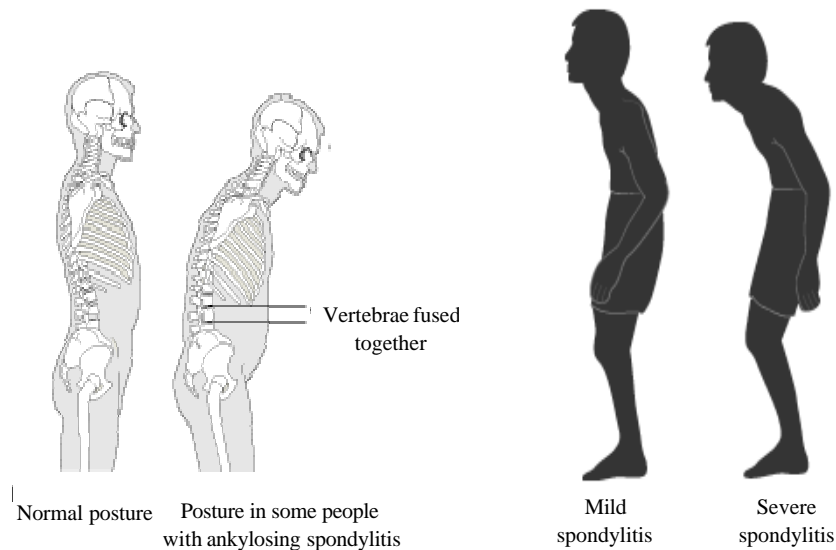


Fig. 1: Model of ankylosing spondylitis patients

white males about four times as often as females. Onset typically occurs between the ages of 15 and 45 (Breur-Vriesendorp *et al.*, 1987). First, second and third-degree relatives of patients with AS had risk ratios of 94, 25 and 3.5, respectively, indicating an increased risk of developing AS (each  $p < 0.0005$ ) (Thjodleifsson *et al.*, 2007). There may be hereditary links as evidence shows that the HLA antigen B27, which is related with the disease, can be inherited. It is extremely rare in Japanese, Australian Aborigines and Black Africans (Khan *et al.*, 1977). There may be genetic links-up to 90% of patients have the HLA antigen B27. The exact cause of ankylosing spondylitis is not known but genetics do seem to play an important role in the development of this disease.

Ankylosing Spondylitis begins with pain in the lower spine and sacroiliac joints with muscle spasm, often spreading to the upper back and neck and improved by exercise. Fatigue, fever, loss of weight and appetite occur as the disease advances. As the back stiffens the spine can move less freely and smaller breaths are taken as the chest is not able to move freely. If untreated the spine can become permanently curved, in severe cases spinal movement may become impossible. Inflammation of the eyes can also arise, with redness, eye-ache and blurred vision. There is a link to uveitis, where the iris and surrounding muscle become inflamed (Gross *et al.*, 1998; Henderson *et al.*, 1996). Patients will suffer episodes of pain and stiffness throughout. Eventually the ligaments and intervertebral discs of the spine ossify so the vertebrae become fused so the spine is stuck in one position. In severe cases the patient may not be able to raise their head. Plantar Fasciitis and Achilles Tendinitis are also common in long term sufferers (Matsumoto *et al.*, 1999). As the disease progresses, ossification is triggered by the body's defense mechanism. Ossification causes new bone to grow between vertebrae eventually fusing them together increasing the risk for fracture. Further, ossification may affect spinal ligaments causing spinal canal stenosis (narrowing), which can result in neurologic deficit (Lopez de Castro, 1998). The most common early signs of spondylitis are constant pain and stiffness in the low back, buttocks and hips that continue for more than three months. Spondylitis often starts around the sacroiliac joints where the sacrum (the lowest major part of the spine) joins the ilium of the pelvic bone. Spondylitis can cause an overgrowth of the bones, which may lead to abnormal joining of parts that are normally separate. This is called bony fusion (D'Amato *et al.*, 1995).

### **Stem Cells**

This review found that a stem cell is an unspecialized cell that has the ability to renew itself indefinitely and, under appropriate conditions, can give rise to a wide range of mature cell types in the human body. The 2007 Nobel Prize in Physiology or Medicine has been awarded to Mario Capecchi, Martin Evans and Oliver Smithies for developing specific gene modification techniques and mouse embryonic stem cell technology that, when combined, enable the creation of knockout mice. Analyses of these mutant animals have revolutionized the elucidation of gene functions and these mice have proved to be valuable models of numerous human diseases (Mak, 2007). Stem cells are immature, unprogrammed, unspecialised precursor cells that can grow and change to make new cells and tissues. They can transform into about 250 types of specialised cells that make up a human being. Thus they can develop into heart cells, kidney cells, nerve cells, blood cells, skin cells, bone cells, etc. They have been called master cells (Reubinoff *et al.*, 2000). Because of this capacity they may prove useful for treatment of some conditions (Chapman *et al.*, 1999; Pera *et al.*, 2001). Stem cells are also cells that have the ability to divide for indefinite periods in culture and give rise to multiple specialized cell types. They can develop into blood, bone, brain, muscle, skin and other organs. A stem cell is an unspecialized cell which has the ability to renew itself indefinitely and, under appropriate conditions, can give rise to a wide range of mature cell types in the human body. As any disorder involving loss of, or injury to, normal cells could be a candidate for stem cell replacement therapy; the potential of stem cells is profound (Itskovitz-Eldor *et al.*, 2000).

The main clinical application of stem cells is as a source of donor cells to be used to replace cells in transplantation therapy. Stem cells can be obtained from several sources (Lumelsky *et al.*, 2001). Spare embryos: stem cells can come from leftover embryos stored at fertility clinics that were not used

by couples to have children. Special purpose embryos: embryos are created *in vitro* fertilization (artificially in the lab) for the sole purpose of extracting their stem cells. Cloned embryos: embryos are cloned in labs using somatic nuclear transfer method in order to harvest their stem cells. Aborted fetuses: stem cells are taken from fetuses in early development that have been aborted. Umbilical cords: this after-childbirth tissue holds potential for research. Adult tissue or organs: stem cells are obtained from the tissue or organs of living adults during surgery.

### HOW ARE STEM CELLS OBTAINED?

At the blastocyst stage of stem cells development, which occurs around day five, the early embryo has two distinct structures: an inner cell mass (which will develop into the fetus) and the trophoblast-an outer ring of cells (which will become the placenta). The trophoblast is removed from the embryo, the inner cell mass is isolated and stem cells are extracted from the inner cell mass. The stem cells are then placed in culture in a laboratory. The intent of researchers is to coax these cells into differentiating into the desired tissue, which would then be placed into the tissue or organ of the recipient (Fig. 2).

A newly fertilised egg produces 8 identical cells that go on to form a 'clump' of cells that can potentially produce other types of cells (Brown *et al.*, 1996).

#### Procedure of Stem Cell Production

According to Fiorillo *et al.* (1997) the procedure of stem cell production are given bellow:

- Eggs are coaxed to mature in a culture dish. Each has a remnant egg cell called the polar body and cumulus cells from the ovary clinging to it.
- While an egg is held still with a pipette, a needle is used to drill through the zona pellucida, removing a plug.
- After ejecting the zona plug, the needle is inserted back in the egg through the hole to withdraw and discard the polar body and the egg's genetic material.
- A cumulus cell from another egg is taken up into the needle. Cells called fibroblasts (or their nuclei) can also be used in this step.
- The cumulus cell is injected deep into the egg that has been stripped of its genetic material.
- The injected egg is exposed to a mixture of chemicals and growth factors designed to activate it to divide
- After roughly 24 h, the activated egg begins dividing. The cells contain genetic material only from the injected cumulus cell.

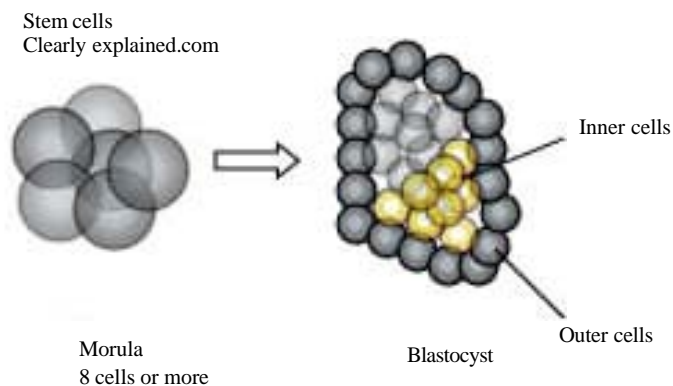


Fig. 2: An illustration showing the basics of stem cells

- By the fourth or fifth day, a hollow ball of roughly 100 cells has formed. It holds a clump of cells called the inner cell mass that contains stem cells.
- The blastocyst is broken open and the inner cell mass is grown in a culture dish to yield stem cells.
- The stem cells, in turn, can be coaxed to grow into a variety of cells that might be injected into patients.

### **Tissue Engineers Steering Stem Cells to Produce Bones, Cartilage**

Johns Hopkins University researchers have caused stem cells from cardiac cells to grow into tissue that resembles cartilage, a key step toward creating a minimally invasive procedure that may one day be used to repair injured knees, backbone, noses and other body parts.

#### **Step 1**

In this method, doctors would inject a fluid filled with stem cells and nutrients into damaged tissue, then use light to harden the liquid into a stable gel. Although human testing remains years away, the researchers believe stem cells within the gel will multiply and form new bone or cartilage to replace the injured tissue ((Dick, 1996; Elisseeff *et al.*, 1999).

#### **Step 2**

Paving the way for this technique, the researchers have conducted lab experiments that turned stem cells within a gel into cartilage-like tissue. The team expects to begin testing the process on mice. Jennifer Elisseeff, assistant professor in the Department of Biomedical Engineering is leading a multi-disciplinary tissue engineering team that includes a plastic surgeon, an orthopedic surgeon, a polymer chemist and graduate students, all affiliated with the Whitaker Biomedical Engineering Institute at Johns Hopkins.

#### **Step 3**

The team's goal is to develop a new way to deliver and control the behavior of adult stem cells to restore bone and cartilage that has been damaged by disease or injury or is impaired by a genetic defect. Restoration of cartilage the tough but elastic tissue in noses, ears and joints-would be particularly helpful because, unlike skin, cartilage does not naturally regenerate. Routine use of this procedure in humans may be many years away, but the potential benefits could be significant. If the lab results can be replicated in humans, patients would end up with living tissue rather than metal or plastic replacement parts and doctors will have a new and possibly more effective option for treating severe joint injuries.

#### **Step 4**

Like many new research projects, this work uses stem cells because they have the ability to renew themselves and also to develop into many types of tissue. Elisseeff's lab is using adult multipotent cells, meaning they can be stimulated to produce different types of musculoskeletal tissue. Ethical debates surrounding stem cell research have focused on material removed from human embryos and fetuses, not the adult cells used in Elisseeff's experiments. Adult cells offer another advantage: In theory, patients preparing for cartilage or bone repairs will be able to donate their own stem cells prior to the procedure, reducing the likelihood of infection and tissue rejection.

#### **Step 5**

Elisseeff was lead researcher in developing a polymer fluid-laced with cartilage cells called chondrocytes that can be injected under the skin. The liquid is then hardened by shining an ultraviolet light or visible laser through the skin. The solid material, called a hydrogel, forms a scaffold or framework upon which cells can reproduce and form new tissue.

### Step 6

Now, in a new lab at Johns Hopkins, Elisseeff and her colleagues are placing stem cells in her hydrogels and coaxing them to produce cartilage and an early form of bone within the polymer framework. Recently, Christopher Williams, a plastic surgery fellow in the lab, has conducted experiments with stem cells derived from the bone marrow of adult goats. By surrounding these cells with a specific growth factor that helps direct cellular differentiation, Williams has prodded the stem cells into forming what lab tests indicate are osteoblasts (cells that develop into bone) or chondrocytes. The cartilage samples show the proper gene expression and a cartilage-specific extracellular matrix. Lab tests show that the bone precursor cells are producing calcium, a first step toward osteogenesis, the formation of bone.

The researchers are synthesizing a new hydrogel that should degrade harmlessly in the body after the new tissue develops. Also, the team is refining its cell growth methods to more closely mimic the normal development of cartilage and bone cells (Takahashi *et al.*, 1998).

### SURGICAL MANAGEMENT

Several procedures are available to the surgeon. The type of surgery performed is dependent on the angle of the deformity, spinal stability, neurologic considerations and compromise and a host of other variables. Spinal osteotomy involves the removal and/or resection of bone (vertebra). The bone is cut to correct the angular deformity. Bone is realigned and allowed to heal. Spinal instrumentation and fusion are combined with osteotomy to stabilize the spine during healing and fusion (Herbert, 1959; Duncan and Simmons, 1979) (Fig. 3a-f). Restoring the spine to a more normal order may require surgical procedures involving more than one spinal region. For example, the lumbar and thoracic regions may be modified to produce a better correction. Once again, the procedures and levels to be corrected are dependent on the individual patient's needs (Grob *et al.*, 1994). Following thoracolumbar surgery, the patient wears a jacket-like brace for several months. The brace stabilizes the spine during the healing process.

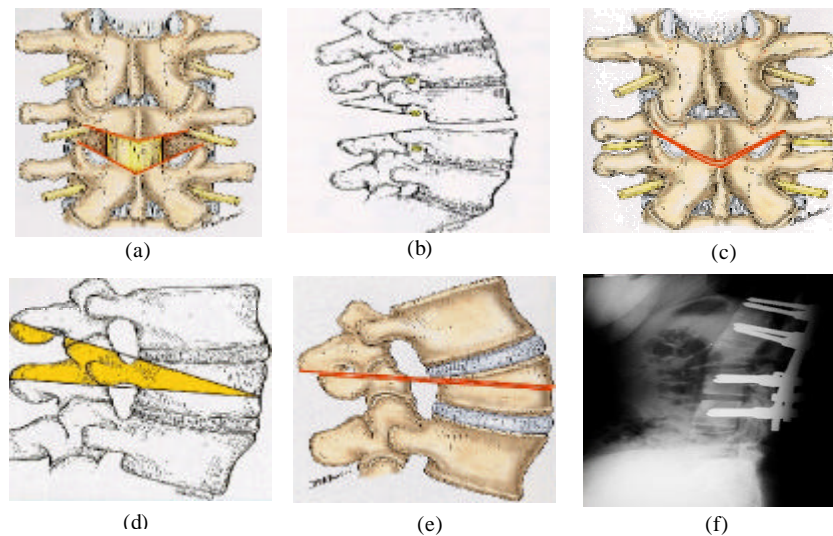


Fig. 3 (a-f): Surgical management of the patient (a) Smith-Petersen V-shaped posterior wedge osteotomy, (b) Lateral aspect of a Smith-Petersen V-shaped wedge osteotomy, (c) Posterior aspect of a closed Smith-Petersen wedge osteotomy. (d) Lateral aspect of a Thomasen wedge osteotomy and verbal corpectomy, (e) Lateral aspect of a closed Thomasen osteotomy and (f) Postoperative lateralspect of transpedicular screw-rod fixation and Thomassubtraction

## CONCLUSION

Although Ankylosing Spondylitis can result in severe spinal deformity, for most patients surgery is not necessary. Often the symptoms of AS can be managed with medication and exercise. Lifestyle changes, such as complete cessation of smoking can be beneficial. For the few that may face surgical correction of a spinal deformity, keep in mind that it is not an easy task and requires a highly experienced surgeon (Haase *et al.*, 1995). Stem cells are immature, unprogrammed, unspecialised precursor cells that can grow and change to make new cells and tissues. They can transform into about 250 types of specialised cells that make up a human being. Thus they can develop into heart cells, kidney cells, nerve cells, blood cells, skin cells, bone cells, etc. They have been called master cells. Stem cells are also cells that have the ability to divide for indefinite periods in culture and give rise to multiple specialized cell types. They can develop into blood, bone, brain, muscle, skin and other organs. Because of this capacity they may prove useful for treatment of some conditions. Because of the complexity of environmental factors and for the high cost of equipments, this culture has not still been practiced anywhere rather than MIT. By using the stem cell culture we can produce the artificial vertebrae and can treat the Ankylosing Spondylitis diseases. From the above discussion, it can be concluded and recommended for further research in this field in order to minimize constraints.

## REFERENCES

- Appel, A.H., C. Loddenkemper, Z. Grozdanovic, H. Ebhardt, M. Dreimann, A. Hempfing, H. Stein, P. Metz-Stavenhagen, M. Rudwaleit and J. Sieper, 2006. Correlation of histopathological findings and magnetic resonance imaging in the spine of patients with Ankylosing Spondylitis. *Arthritis Res. Ther.*, 8: R143.
- Bowness, P., R.L. Allen and A.J. McMichael, 1994. Identification of T cell receptor recognition residues for a viral peptide presented by HLA B27. *Eur. J. Immunol.*, 24: 2357-2363.
- Braun, J. and J. Sieper, 2002. Therapy of Ankylosing Spondylitis and other spondyloarthritis: Established medical treatment, anti-TNF- $\alpha$  therapy and other novel approaches. *Arthritis Res.*, 4 (5): 307-321.
- Breur-Vriesendorp, B.S., A.J. Dekker-Saeyns and P. Ivanyi, 1987. Distribution of HLA-B27 subtypes in patients with Ankylosing Spondylitis: The disease is associated with a common determinant of the various B27 molecules. *Ann. Rheum. Dis.*, 46 (5): 353-356.
- Brooks, J.M., R.J. Murray, W.A. Thomas, M.G. Kurilla and A.B. Rickinson, 1993. Different HLA-B27 subtypes present the same immunodominant Epstein-Barr virus peptide. *J. Exp. Med.*, 178: 879-887.
- Brown, M.A., K.D. Pile, L.G. Kennedy, A. Calin, C. Darke and J. Bell, 1996. HLA class I associations of Ankylosing Spondylitis in the white population in the United Kingdom. *Br. Med. J. Ann. Rheum. Dis.*, 55: 268-270.
- Cascino, I., F. Paladini, F. Belfiore, A. Cauli, C. Angelini, M.T. Fiorillo, A. Mathieu and R. Sorrentino, 2007. Identification of previously unrecognized predisposing factors for Ankylosing Spondylitis from analysis of HLA-B27 extended haplotypes in Sardinia. *Arthritis Rheum.*, 56 (8): 2640-2651.
- Chapman, A.R., M.S. Frankel and M.S. Garfinkel, 1999. Stem cell research and applications; monitoring the frontiers of biomedical research. *Am. Assoc. Adv. Sci. Inst. Civil Soc.*, Ch 34: 405-416.
- Colbert, R.A., S.L. Rowland-Jones, A.J. McMichael and J.A. Frelinger, 1994. Differences in peptide presentation between B27 subtypes: The importance of the P1 side chain in maintaining high affinity peptide binding to B\*2703". *Immunity*, 1: 121-130.



- D'Amato, M., M.T. Fiorillo, C. Carcassi, A. Mathieu, A. Zuccarelli, P.P. Bitti, R. Tosi and R. Sorrentino, 1995. Relevance of residue 116 of HLA-B27 in determining susceptibility to ankylosing spondylitis. *Eur. J. Immunol.*, 25: 3199-3201.
- Dick, J.E., 1996. Normal and leukemic human stem cells assayed in SCID mice. *Semin. Immunol.*, 8: 197-206.
- Duncan, C.P. and E.H. Simmons, 1979. Fracture of the cervical spine in ankylosing spondylitis: An analysis of its influence on severe deformity presenting for spinal osteotomy. *Orthop. Trans.*, 3: 126.
- Elisseeff, J., K. Anseth, D. Sims, W. McIntosh, M. Randolph and R. Langer, 1999. Transdermal photopolymerization for minimally invasive implantation. *Proc. Natl. Acad. Sci. USA.*, 96 (6): 3104-3107.
- Fiorillo, M.T., L. Meadows, M. D'Amato, J. Shabanowitz, D.F. Hunt, E. Appella, R.L. Sorrentino and Meadows, 1997. Susceptibility to Ankylosing Spondylitis correlates with the C-Terminal residue of peptides presented by various HLA-B27 subtypes. *Eur. J. Immunol.*, 27 (2): 368- 373.
- Grob, D., J. Dvorak and M.M. Panjabi, 1994. The role of plate and screw fixation in occipitocervical fusion in rheumatoid arthritis. *Spine*, 19: 2545-2551.
- Gross, D.M., T. Forsthuber, M. Tary-Lehmann, C. Etling, K. Ito, Z.A. Nagy, J.A. Field, A.C. Steere and B.T. Huber, 1998. Identification of LFA-1 as candidate autoantigen in treatment-resistant Lyme arthritis. *Science*, 281 (5377): 703-706.
- Haase, D., C. Fonatsch and M. Freund, 1995. Cytogenetic findings in 179 patients with myelodysplastic syndromes. *Ann. Hematol.*, 70: 171-187.
- Henderson, E.S., T.A. Lister and M.F. Greaves, 1996. *Ankylosing Spondylitis Philadelphia, Pa: WB Saunders*, pp: 46-64.
- Herbert, J.J., 1959. Vertebral osteotomy for kyphosis, especially in Marie-Strumpell Arthritis. *J. Bone Joint Surg. Am.*, 41A (2): 291-302.
- Itskovitz-Eldor, J., M. Schuldiner, D. Karsenti, A. Eden, O. Yanuka, M. Amit, H. Soreq and N. Benvenisty, 2000. Differentiation of human embryonic stem cells into embryoid bodies comprising the three embryonic germ layers. *Mol. Med.*, 6: 88-95.
- Khan, M., W. Braun, I. Jushner, D.E. Grecek, W.A. Muir and A.G. Steiberg, 1977. HLA B27 in ankylosing spondylitis: Differences in frequency and relative risk in American blacks and caucasians. *J. Rheumatol.*, 4 (3): 39-43.
- Khan, M., 1995. HLA-B27 and its subtypes in world populations. *Curr. Opin. Rheumatol.*, 7: 263-269.
- Lopez de Castro, J.A., 1998. The pathogenetic role of HLA-B27 in chronic arthritis. *Curr. Opin. Immunol.*, 10: 59-66.
- Lumelsky, N., O. Blondel, P. Laeng, I. Velasco, R. Ravin and R. McKay, 2001. Differentiations of embryonic stem cells to insulin secreting structures similar to pancreatic islets. *Science*, 292: 1389-1394.
- Mak, T.W., 2007. Gene Targeting in embryonic stem cells scores a knockout in stockholm. *Cell*, 131 (6): 1027-1031.
- Matsumoto, I., A. Staub, C. Benoist and D. Mathis, 1999. Arthritis provoked by linked T and B cell recognition of a glycolytic enzyme. *Science*, 286: 1732-1735.
- Pera, E., O. Wessely, S. Li and E.D. Robertis, 2001. Neural and head induction by insulin-like growth factor signals. *Dev. Cell*, 1 (5): 655-665.
- Reubinoff, B.E., M.F. Pera, C.Y. Fong, A. Trounson and A. Bongso, 2000. Embryonic stem cells lines from human blastocyst: Somatic differentiation *in vitro*. *Nat. Biotechnol.*, 18 (4): 399-404.

- Takahashi, N., I. Miura, K. Saitoh and A.B. Miura, 1998. Lineage involvement of stem cells bearing the Philadelphia chromosome in chronic myeloid leukemia in the chronic phase as shown by a combination of fluorescence-activated cell sorting and fluorescence in situ hybridization. *Blood*, 92: 4758-4763.
- Thjodleifsson, B., A.J. Geirsson, S. Björnsson and I. Bjarnason, 2007. A common genetic background for inflammatory bowel disease and ankylosing spondylitis: A genealogic study in Iceland. *Arthritis Rheum.*, 56 (8): 2633-2639.
- Uddin, S.N., S.J. Hossain, M.N. Huda, M.H. Rahman and M.D. Eunos Ali, 2006. Consequence on treatment of tb patients affected by HIV/AIDS: A conceptual research. *Am. J. Infect. Dis.*, 2 (4): 210-218.