OPEN ACCESS International Journal of Pharmacology

ISSN 1811-7775
DOI: 10.3923/ijp.2017.

Research Article

Impaired Growth Performance and Testicular Cells Apoptosis Following Restraint Stress in Adult Hypothyroid Mice

[1]Asif Mehfooz, [1]Quanwei Wei, [1]Mohamed Babo Fadlalla, [1]Farman Ali Siyal, [2]Kuldeep Dhama, [1]Dagan Mao and [1]Fangxiong Shi

[1]Laboratory of Animal Reproduction, College of Animal Science and Technology, Nanjing Agricultural University, 210095 Nanjing, China
[2]Division of Pathology, ICAR-Indian Veterinary Research Institute, Izatnagar, 243122 Uttar Pradesh, India

Abstract

Background and Objective: Restraint stress and hypothyroidism impair animal testicular functions. As stress is increasing gradually in our daily life, there is an increased chance of the occurrence of both stress and hypothyroidism together. Therefore, this study was designed to evaluate the effect of restraint stress on growth performance and testicular cells apoptosis in adult hypothyroid mice. **Methodology:** Twenty-four adult male mice were divided into four groups: control, Restraint Stress (RS), hypothyroid (HT) and RS+HT. ANOVA followed by Tukey as post hoc tests were used to determine the difference between multiple groups. **Results:** The results indicated that the feed and water index, body weight and testes weight, serum concentration of T3, T4 and testosterone exhibited a reduction but the TSH levels were increased in all experimental groups compared to the control. Histological observations of the testis from different experimental groups exhibited considerable interstitial edema, broken basement membrane and increased interstitial spaces compared with the control group. Seminiferous tubules were also morphologically shrinkage and deformed in RS+HT group compared to control group. Obvious suppression of spermatogenesis by restraint stress, the degenerative population of round spermatids was markedly increased due to apoptosis in the lumen of RS group as compared to the control group. Moreover, leydig cells, blood vessels, sertoli cells, primary and secondary spermatocytes are absent in large numbers and exposing apoptosis in RS+HT mice than RS and HT mice as compared to the control mice. **Conclusion:** Restraint stress and hypothyroidism together have adverse effects on male fertility based on increasing of the apoptotic process.

Key words: Restraint stress, hypothyroidism, histopathology, testis, hormonal imbalance, feed and water index, apoptosis

Received: Accepted: Published:

Citation: Asif Mehfooz, Quanwei Wei, Mohamed Babo Fadlalla, Farman Ali Siyal, Kuldeep Dhama, Dagan Mao and Fangxiong Shi, 2017. Impaired growth performance and testicular cells apoptosis following restraint stress in adult hypothyroid mice. Int. J. Pharmacol., CC: CC-CC.

Corresponding Author: Fangxiong Shi, Laboratory of Animal Reproduction, College of Animal Science and Technology, Nanjing Agricultural University, 210095 Nanjing, China Tel: 00 86 25 84399112 Fax: 00 86 25 84399112

Competing Interest: The authors have declared that no competing interest exists.

Data Availability: All relevant data are within the paper and its supporting information files.

INTRODUCTION

Stress is an inevitable phenomenon in this modern world. Stressful situations can lead to many physiological and psychological alterations[1,2]. Disturbance of homeostasis is called stress and homeostasis is challenged by a stimulus is termed as stressor. Generally there are three types of stressors physical, psychological and metabolic. In research stressors are often used in a mixed type, such as Restraint Stress (RS) is a combination of physical and mental stressors, limiting movement and separating the animal from its group[3]. Stress has been reported to influence the animal reproduction adversely[1,4]. There are proofs that testicular functions may negatively affected by environmental factors, like chemical, physical or emotional. Many researchers have frequently used restraint stress in rodents as stress inducer. Stress causes obvious suppression of spermatogenesis with decrease in size and weight of testes and all the phases of cell division and maturity of spermatogenesis were inhibited[5].

Thyroid hormones play an important role in several mammalian tissues in regulating development, differentiation and metabolism[6,7]. Hyper and hypothyroidism are the major thyroid diseases with negative effects on male reproductive system[8]. Hypothyroidism is a disease of ineffective or low thyroid hormone leads to a metabolic disturbance. Adverse effects of hypothyroidism on spermatogenesis and testicular histology has been established. In production of domestic animal, growth and development have great importance on the value of animal how they are produced. Thyroid hormones are necessary for normal growth. Insufficient T4 (thyroxine) and T3 (triiodothyronine) resulted in decreased growth as an effect of reduced muscle synthesis[9]. Homeostasis is directly connected with growth and development. Disturbed homeostasis affected on normal growth. Homeostasis is maintained by several processes under the control of nervous and endocrine systems.

Removal of useless cells by a regulated mechanism is called programmed cell death or apoptosis. Apoptosis is a tightly controlled mode of cell death[10,11]. The testis is a complex organ with multiple cell types, all of which are coordinated to produce spermatozoa. During spermatogenesis, germ cell apoptosis is a normal occurrence, which increases when sertoli cells are injured and can no longer support their normal complement of germ cells. Germ cell apoptosis can also be induced through direct injury to the germ cells[12]. Apoptosis has two pathways, intrinsic pathway or mitochondrial pathway and the extrinsic pathway or death receptor pathway which are active in the animal testes. Probable, the intrinsic or the extrinsic pathways of apoptosis are selectively activated by spermatogenic cells depending on external stimuli[13].

Restraint stress and hypothyroidism impair testicular function both in animal and human models. As stress is increasing gradually in our daily life, there is more chance of the happening of both stress and hypothyroidism together. However, the harmful effects of this combination on testis have not been studied. Based on the obvious different mechanisms by which stress and hypothyroidism impair testis, the combination of restraint stress and hypothyroidism would be expected to result in a greater impairment of testes than either condition alone. The purpose of this study was, thus, to define and characterize apoptosis histological as a mean of germ cell loss in the stressed hypothyroid testis.

MATERIALS AND METHODS

Animals: Young adult male (30-35 g) Swiss ICR (Institute for Cancer Research) mice were purchased from Qinglongshan Laboratory Animal Company (Nanjing, China). They were kept under control environment providing a room temperature of 22-23 C, humidity at 60-70% and a 12 h light: 12 h dark cycle. Standard balanced rodent pellets were fed to mice. Feed and drinking water was made available freely. Animals were accommodated 7 days before for adaptation the environment to starting of the experiment. The trial conventions including mice were acknowledged as per the Guide for the Care and Use of Laboratory Animals arranged by the Institutional Animal Care and Use Committee of Nanjing Agricultural University, PR China.

Experimental design: The study was carried out on 24 adult male mice. The animals were divided into two groups of 12 each. Group A: Served as normal (without treatment). Group B: The mice of this group were rendered hypothyroid by the administration of 0.5% potassium perchlorate and 0.05% methimazole-MMI (both from Sigma Chemical Co., St Louis, MO, USA) in their drinking water until the end of the experiment[14,15]. After 35 days, groups were divided into two subgroups (n = 6) and made four groups as follows: (1) Control group-mice without exposure to RS and treatment. (2) RS group-mice were restrained in a conical tube for 2 h (for 7 consecutive days). (3) HT-hypothyroid mice. (4) RS+HT-hypothyroid mice were restrained in a conical tube for 2 h (for 7 consecutive days). All animals were sacrificed after 7 days restraint stress period. Blood samples were collected and centrifuged at 4000 rpm for 10 min to retrieve sera and then

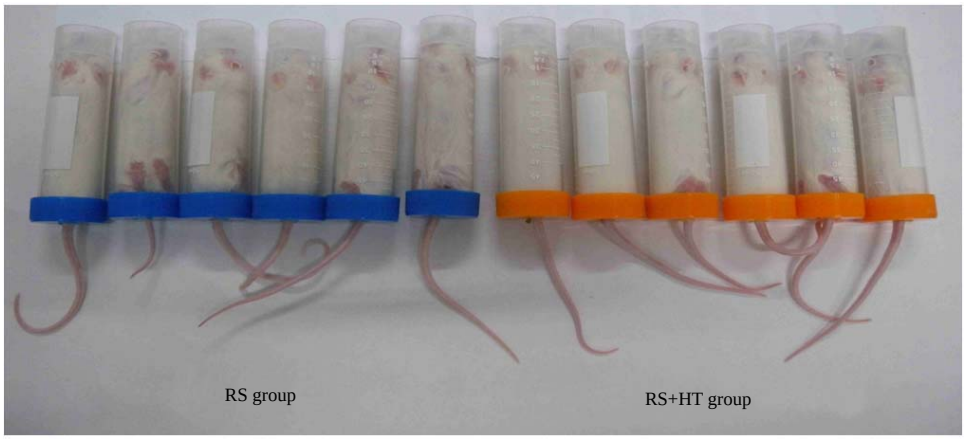

Fig. 1: Experimental mouse during Restraint Stress (RS) in white transparent tubes

stored at −80°C until use. Testes were collected and weighed and portions were stored at −80°C, while others were fixed in Bouin's fluid for histological analysis.

Restraint stress procedure: According to protocol as reported by Iwakabe *et al.*[16], 50 mL conical centrifuge tubes were used to physically restrain the mice and 0.4 cm diameter of various holes were made in the tube by drill machine for ventilation. Consecutive 7 days individual mice were restrained in a 50 mL tube for 2 h daily without food and water (Fig. 1). Same time control mice were kept in their cages without food and water.

Measurement of body weight, food consumption, water intake and gonadosomatic index: Body weight, food consumption and water intake of every group mice were daily measured. Food consumption index (g/10 g) and water intake index (mL/10 g) were calculated as follows: Food consumption index = total food consumption per day/body weight×10; water intake index = total water intake per day/body weight×10[17]. Gonadosomatic index (GSI) was determined by using the following Eq. 1[18,19]:

$$\text{GSI} = \frac{\text{Testes weight}}{\text{Body weight}} \times 100 \quad (1)$$

Radioimmunoassay (RIA) for serum hormone concentrations: Serum was used to determine the concentrations of testosterone, TSH (thyroid stimulating hormone), T4 (thyroxine) and T3 (triiodothyronine) getting commercial RIA kits from Shanghai University of Traditional Chinese Medicine, China and used in the General Hospital of the Nanjing Military Command, China.

Histological analysis: Testes were fixed for 24-48 h in Bouin's fluid. After this a graded series of ethanol were used to dehydrate the tissues. Xylene was used to clear the tissues and paraffin wax for embedding. Sections were cut at 5 μm thickness and stained with hematoxylin and eosin (H and E) (Nanjing Jiancheng Bioengineering Institute, Nanjing, China) and examined any histopathology changes under a light microscope (Nikon Tokyo, Japan).

Statistical analysis: SPSS Version 19.0 (SPSS, Chigago, IL, USA) and Excel were used for statistical analysis computations. All values were expressed as Mean±SEM. One-way analysis of variance (ANOVA) followed by Tukey as a post hoc test were used to determine the difference between multiple groups. p-values of less than 0.05 were considered statistically significant[9].

RESULTS

Feed and water intake: The control group mice had good body health and their activities were strong. There were no changes in food consumption and water intake of control mice during the whole experimental period. Feed index showed a reduction in all experimental groups but RS and RS+HT groups reduced significantly ($p<0.05$) as compared with the control, while the HT mice were not statistically ($p<0.05$) different in feed index as compared with the control mice. Water index exhibited a significant ($p<0.05$) reduction in mice of all the RS, HT and RS+HT groups compared with the control (Fig. 2).

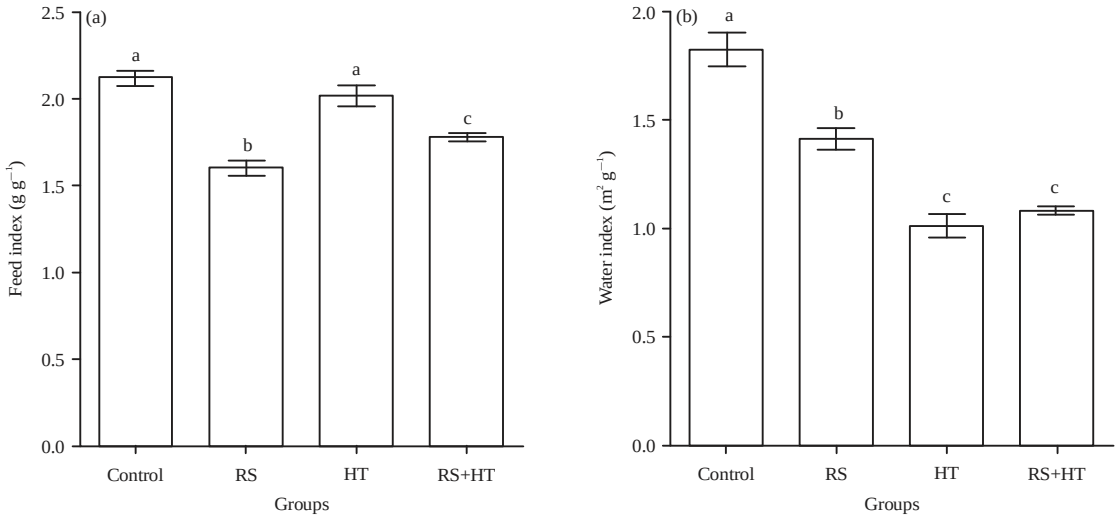

Fig. 2(a-b): (a) Feed index and (b) Water index in the control, RS: Restraint stress, HT: Hypothyroid, RS+HT: Restraint stress+hypothyroid groups

Different superscript letters indicate significant differences among groups ($p<0.05$) (n = 6, Mean±SEM)

Body weight, testes weight and gonadosomatic index: The control group of mice showed better body weight gain but all experimental mice exhibited significant ($p<0.05$) reduction in body weight; while, the RS+HT group has the lowest body weight among the all groups (Fig. 3a). In addition, a significant decrease ($p<0.05$) in testes weight was observed in all experimental groups compared with the mice in the control group (Fig. 3b). Moreover, the gonadosomatic index was not statistically ($p<0.05$) different in all experimental groups compared with the control group (Fig. 3c).

Serum hormone concentrations: The effects of different experimental groups on serum T3, T4, TSH and testosterone levels were investigated in the control, RS, HT and RS+HT mice (Fig. 4). Compared with the control group, the serum concentrations of T3 was markedly decreased ($p<0.05$) in the HT and RS+HT mice, while no significant ($p<0.05$) difference was observed in serum concentrations of T3 between the RS and control groups (Fig. 4a). Furthermore, serum T4 concentration was prominently diminished ($p<0.05$) in all experimental groups as compared to control group (Fig. 4b). Moreover, the TSH levels in the RS, HT and RS+HT mice distinctly augmented ($p<0.05$) compared with the control mice (Fig. 4c). To study the direct effects of thyroid hormones and restraint stress on testes function, serum testosterone levels were measured. The results showed that serum testosterone concentration was markedly decreased ($p<0.05$) in all experimental groups as compared to control group (Fig. 4d).

Histological observations: Histology of the control testes exhibited the normal testicular structure and spermatogenesis. Regular morphology of seminiferous tubules showed the presence of spermatogonia, primary and secondary spermatocytes, round spermatids, elongated spermatids and spermatozoa. In addition, seminiferous tubules of control group indicated normal presence of sertoli cells and basement membrane. Moreover, seminiferous tubules were confined together by loose intertubular connective tissue in control group. These have blood vessels, collagen fibers, fibroblasts and groups of leydig cells (Fig. 5a, b).

Histological observations of the testes from different experimental groups exhibited significant changes ($p<0.05$) compared with the control group (Fig. 5c, e, g). There was considerable interstitial edema in HT group (Fig. 5e, f) than RS and RS+HT groups, while broken basement membrane were more in RS group (Fig. 5c, d) than HT and RS+HT groups. Moreover, interstitial spaces were more increased, leydig cells and blood vessels were absent and showed significantly higher ($p<0.05$) apoptosis in RS+HT group (Fig. 5g, h) than RS and HT groups. In addition, sertoli cells, primary and secondary spermatocytes were absent in large numbers and exposing apoptosis in RS+HT mice than RS and HT mice as compared to the control mice. The degenerative population of round spermatids was markedly increased in the lumen of RS group in agreement with obvious suppression of spermatogenesis as compared to the control group (Fig. 5c, d). Seminiferous tubules were also morphologically shrinkage and deformed in RS+HT group compared to control group (Fig. 5g, h).

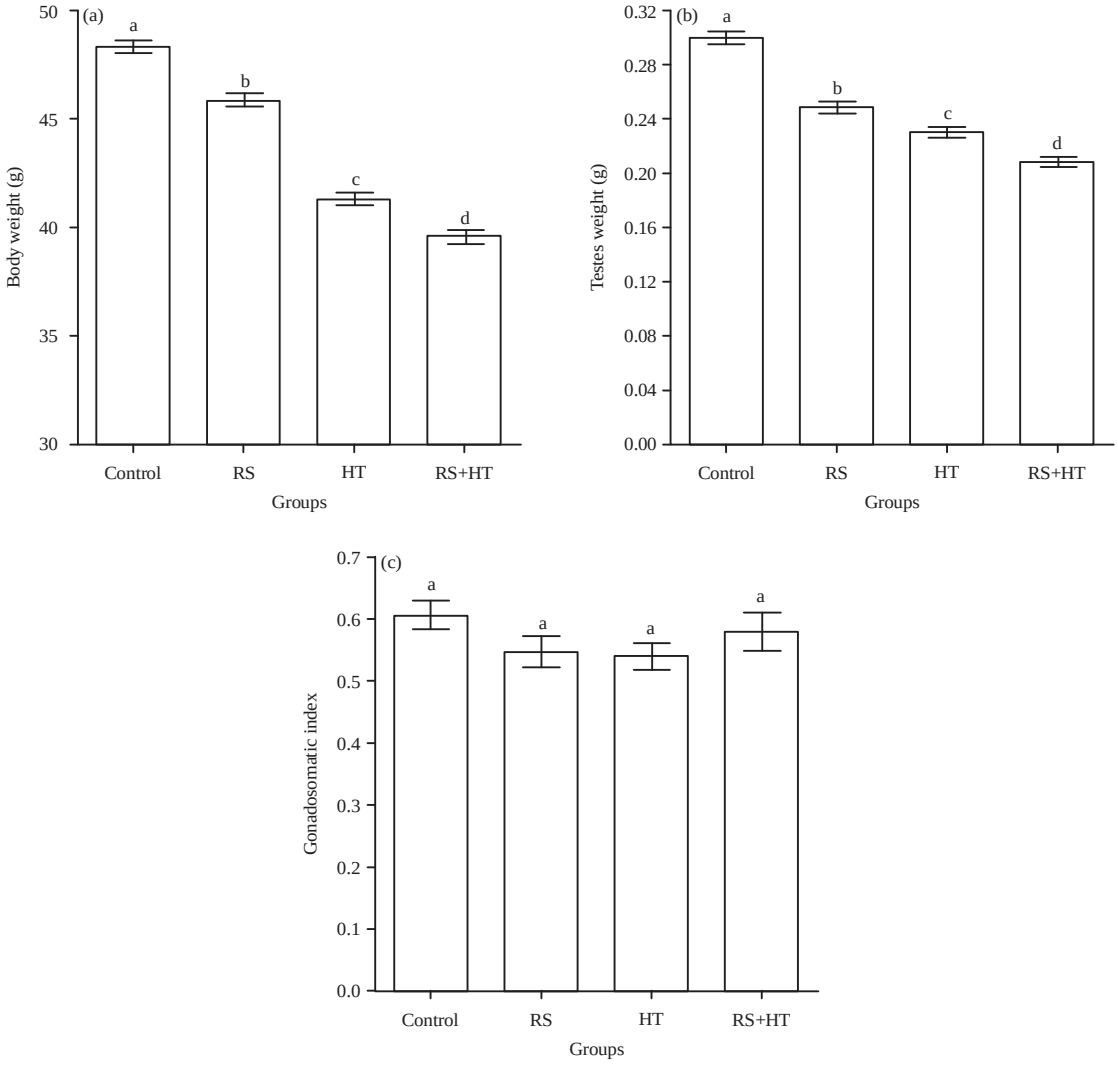

Fig. 3(a-c): (a) Body weight, (b) Testes weight and (c) Gonadosomatic index in the control, RS: Restraint stress, HT: Hypothyroid, RS+HT: Restraint stress+hypothyroid groups

Different superscript letters indicate significant differences among groups ($p<0.05$) (n = 6, Mean±SEM)

DISCUSSION

The present study objectives were to explore the effects of restraint stress on spermatogenesis in testis of hypothyroid mice.

Feed and water intake are the variables sensitive to stress and it is particularly interesting in stress research not only because of the impact of food and water on growth and health but also because it can be measured with minimal disturbance of the animals[20]. In the current study, effects of different experimental groups on feed and water intake were examined. Feed and water intake were reduced in RS, HT and RS+HT groups. These findings are consistent with previous reports of decreased feed and water intake in restraint stress and hypothyroid mice[21-23]. When an animal combats with stress, numerous stages happen to avert the effects properly and to help surviving mechanisms. In case of acute appetite regulation, paraventricular nucleus (PVN) of the hypothalamus releases Corticotropin Releasing Hormone (CRH) in response to the stress. Additionally, pituitary discharges the adrenocorticotropic hormone (ACTH) and a number of incidents resulting release of glucocorticoid, hypothalamus is also secreted CRH to suppress neuropeptide Y (NPY)/agouti-related peptide (AGRP) neurons there. These cells population is usually important for inducing feeding behavior and inhibiting energy consumption, thus CRH secreted following acute stress suppress appetite[24].

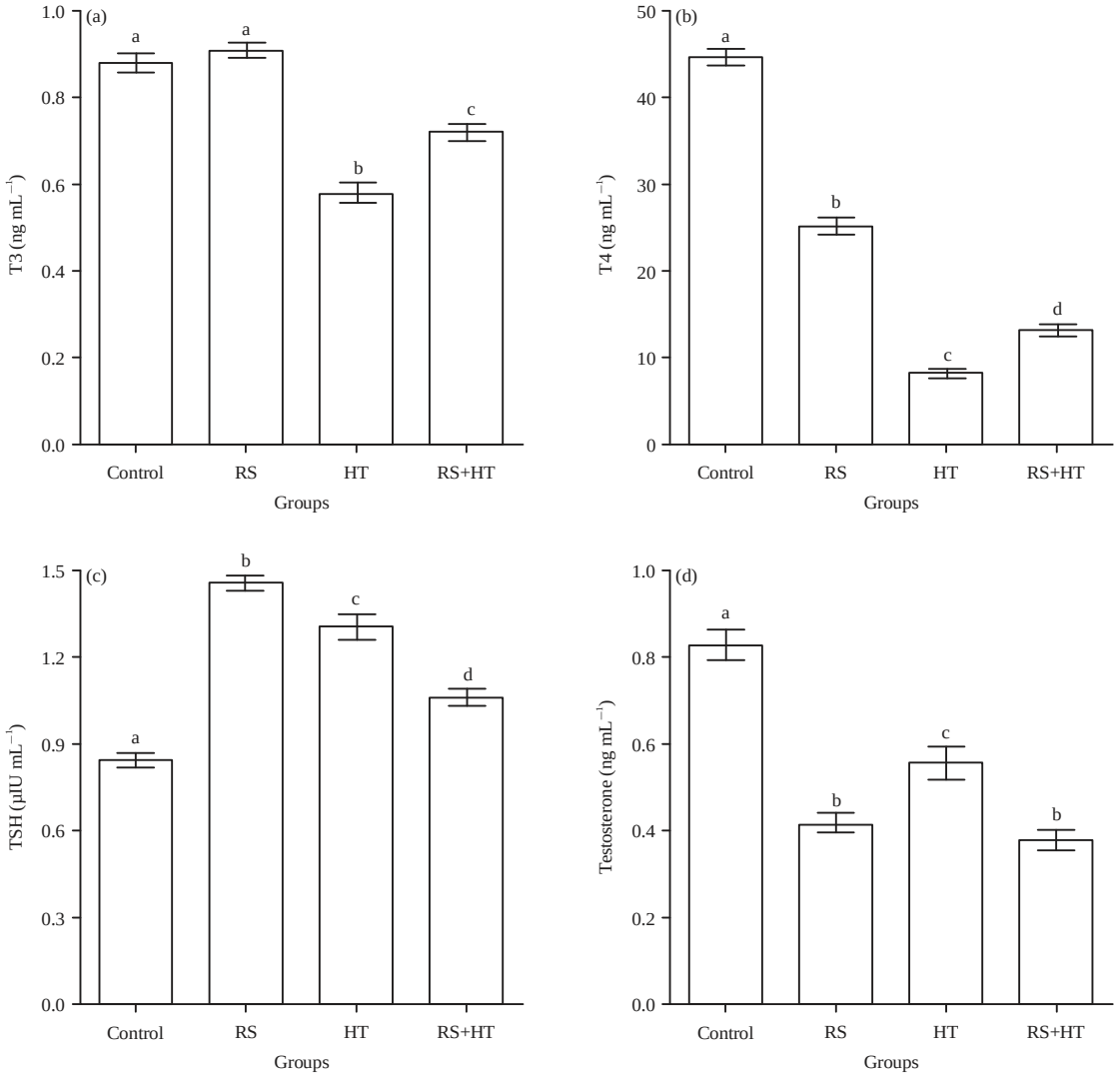

Fig. 4(a-d): Serum concentrations of (a) T3, (b) T4, (c) TSH and (d) Testosterone in the control, RS: Restraint stress, HT: Hypothyroid, RS+HT: Restraint stress+hypothyroid groups

Different superscript letters indicate significant differences among groups ($p<0.05$) (n = 6, Mean±SEM)

In this study, changes in body weight, testes weight and gonadosomatic index were also investigated in different experimental groups. The present study showed that the RS, HT and RS+HT mice had a lower body weight and testes weight than the control mice, which is similar to previous studies[25,26]. The current results exhibited that restraint stress rapidly induces a marked decrease in body weight that may be due to a reduction of food intake[23]. The decrease of body weight in hypothyroid animals was already expected. This change in the body weight of animals due to thyroid dysfunctions[22]. Reduction in testes weight in restraint stress and hypothyroid group of mice is similar to the earlier reported studies[27-29]. In the current study, gonadosomatic index showed no considerable change between RS, HT and RS+HT groups compared to the control group, which is not in agreement with previous studies[30,31]. Gonadosomatic index was significantly lower in stressed animals[30], while it was higher ($p<0.05$) in hypothyroid mice between 5 and 15 days of age as well as in adult animals[31].

The results of the present study showed that the serum concentration of T3 was not changed statistically in RS group, while the serum concentration of T4 and testosterone were significantly decreased ($p<0.05$) in RS group. These findings are in accordance with those of previous studies[32]. There was not any significant change for the serum concentration of T3 in depressed animals, whereas markedly decreased T4 was observed for Chronic Mild Stress (CMS) group when compared with control group[32]. Commonly, T3 level is not affected by

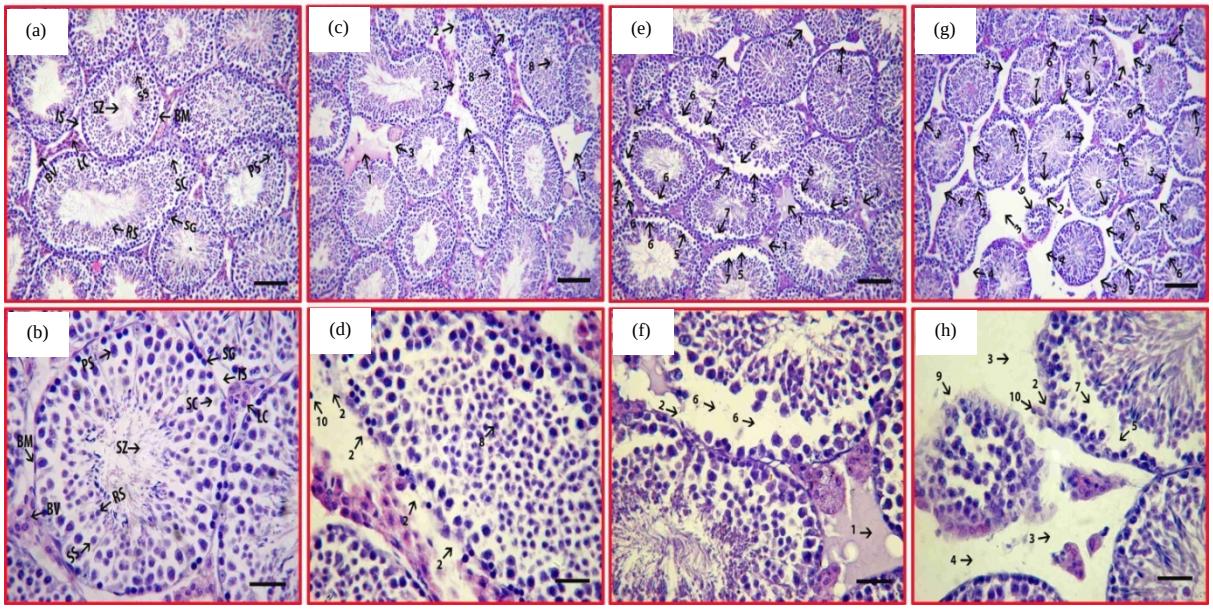

Fig. 5(a-h): Histological changes among different experimental groups in mouse testes. (a, b) Control, (c, d) RS (Restraint stress), (e, f) HT (Hypothyroid) and (g, h) RS+HT (Restraint stress+hypothyroid)

SG: Spermatogonia, PS: Primary spermatocytes, SS: Secondary spermatocytes, RS: Round spermatids, SZ: Spermatozoa, SC: Sertoli cells, LC: Leydig cells, BV: Blood vessels, BM: Basement membrane and IS-Interstitial space. 1: Interstitial edema, 2: Broken basement membrane, 3: Increasing interstitial space, 4: Leyding cells and blood vessels are absent, 5: Sertoli cells absent, 6: Primary spermatocytes absent, 7: Secondary spermatocytes absent, 8: Degenerative round spermatids in lumen, 9: Shrinkage and deformed seminiferous tubule, 10: Spermatogonium. Scale bar: a, c, e, g: 100 μm and b, d, f, h: 30 μm

stress, whereas in some studies on stress it is decreased due to incidence of stress[33]. It is indicated that decreases in T3 in major stress cases may be because of secondary effect of stress such as starvation, swoon and anti-depressant drugs[34]. But T4 level can be changed due to depression or environmental stresses[35]. In an idea, loss of serotonin was announced as main cause of change in thyroid activity. It seems that T4 decreases in stressed animals were in related to serotonin losses, minor energy intake and subsequent declines in basal metabolism[32]. Previous studies indicated that serum testosterone concentration is decreased by restraint stress[36]. Orr and Mann[37] reported that plasma glucocorticoids concentration was augmented by restraint stress and testosterone concentration was diminished without any effect on LH concentration. They recommended that higher glucocorticoids concentration worked on leydig cells by glucocorticoid receptors to inhibit the testicular response to gonadotropins[37]. The serum level of TSH was significantly higher ($p<0.05$) in RS group compared to control group. These results were consistent with previous study that found increase in TSH levels in depressed patients than non-depressed counterparts[38]. A possible hypothesis for the increase in serum TSH in depression stems from the observations that the plasmatic level of this hormone is also influenced by somatostatin, which suppresses its release by the hypophysis. Some reports found a reduction in somatostatin in the Cerebral Spinal Fluid (CSF) of depressed subjects[39] and this may contribute for the increase of serum TSH in depressive conditions[40].

The serum concentrations of T3, T4 and testosterone were significantly decreased ($p<0.05$) in HT and RS+HT group, while the serum concentration of TSH was markedly increased in HT and RS+ HT group compared to control group. These results are in accordance with previous studies[25,41-43]. Serum concentrations of T3, T4 and TSH in hypothyroid mice in the present investigation were in agreement with hypothyroid condition. To study the direct effects of thyroid hormone on testes function in hypothyroid mice, serum testosterone levels were measured. It has been reported that hypothyroidism decreases LH, Follicle Stimulating Hormone (FSH), testosterone and Sex Hormone Binding Globulin (SHBG) concentrations[44]. Decrease in testosterone concentration following hypothyroidism perhaps due to a reduction in serum Luteinizing Hormone (LH) concentration. It is a well-known fact that testosterone synthesis is stimulated by LH in leydig cells of animal testis[25].

In experimental groups, considerable interstitial edema was observed in HT group than RS and RS+HT groups, while

broken basement membrane were more prominent in RS group than HT and RS+HT groups. Tahmaz *et al.*[41] found significant interstitial edema in hypothyroid rats whereas Swami *et al.*[45] found the basement membrane was broken and the germ cells sloughed into the interstitium in stressed rats, which is similar to present study. Moreover, seminiferous tubules were also morphologically shrinkage and deformed while interstitial spaces were increased in RS+HT group than RS group compared to control group. Present results are consistent with previous studies, which indicated that the diameters of semniferous tubules were decreased and they were deformed so the interstitial spaces were raised in stressed animal[27,46,47].

The present study showed degenerative population of round spermatids was markedly increased in the lumen of RS group in agreement with obvious suppression of spermatogenesis as compared to the control group. These results are in accordance with previous studies showing that the primary spermatocytes and round spermatids as the primary germ cell stage undergoing apopotosis and these stages are the most sensitive to stress[48,49]. When seminiferous epithelium is damaged seriously numbers of multinucleated germ cells appeared mainly round spermatids and rarely spermatocytes. They do not have the ability to differentiating into spermatozoa and are completely removed. These cells are also occasionally observed in common testes but are, for instance, big numbers in heated testes. When a single round spermatid undergo to degeneration first chromatin is condensed into a circle shape around the nucleus boundary and it looks continuously for a long period during the degeneration process. Next procedure can be held as quite apoptosis-like and was founded in cultured spermatids[50]. In rats, apoptosis of testicular germ cells is associated with decrease in testosterone concentration and increase in the corticosterone level followed by restraint stress. Thus, it is thought that apoptosis is mediated by androgens in the seminiferous epithelium and primary spermatocytes and round spermatids have been shown to undergo apoptosis in result to withdrawal of androgen[51].

In the present study, apoptosis of sertoli cells, primary and secondary spermatocytes were also found in HT and RS+HT treatment groups. These findings are consistent with previous reports[41,52]. They found significant reduction ($p<0.05$) in the number of sertoli cells, primary and secondary spermatocytes in hypothyroid and stressed animals. It was shown that thyroid hormone receptor expresses in the germ cells from spermatogonia to primary spermatocytes. It suggests a possible direct effect of thyroid hormone in proliferation and maintenance of germ cells. Alternatively, these effects can be attributed to the effects of thyroid hormone on the number of sertoli and leydig cells. Sertoli cells are the major determinants of the magnitude of sperm production. Sertoli cells express thyroid hormone receptor and thyroid hormone control proliferation and maturation of sertoli cells. The current results indicated that the majority of effects of hypothyroidism on the sertoli cells may be its direct effect on these cell[43]. It is already described that primary spermatocytes are the most sensitive to stress and testicular tissues particularly sertoli cells are sensitive to temperature changes and to preserve their exposure to heat stress induces a chain of protective responses, including modification of communication and flow of materials between cells. These modified connections between cells in the heat stress harmfully causes more flow of many apoptotic factors which enhance the apoptosis and cell death[52].

Herein, this study reported that leydig cells and blood vessels were absent and showing significant apoptosis in RS+HT group than RS and HT groups. Present results are in agreement with previous findings[27,41]. Kumar *et al.*[53] indicated that thyroid hormones regulate leydig cell development and steroidogenesis. Thyroid hormone (T3) is essential for differentiation of mesenchymal stem cells into leydig cells in adult rats[53]. Chen *et al.*[54] exhibited that due to increased level of glucocorticoids, stress can disrupt endocrine signalling in the male reproductive axis. Their earlier report showed that a stress level of exogenous glucocorticoids could induce apoptosis of rat leyding cells, which are the primary source of testosterone. It is well-known that glucocorticoid caused apoptosis in rat leydig cells is mediated by receptors of glucocorticoid, which transmit from cytoplasm to nucleus. These findings exhibited that due to stress augmented in corticosterone level resulted in leydig cells apoptosis and thus diminished testosterone synthesis[54].

CONCLUSION

These results revealed that restraint stress and hypothyroidism combination has adverse effects on body in terms of feed intake, water intake and body and testes weight. It also reduced thyroid and testosterone hormones, as well as caused obvious suppression of spermatogenesis and increasing the germ cells apoptotic process.

SIGNIFICANCE STATEMENT

This study discovers the combined effect of restraint stress and hypothyroidism on growth performance and testicular cells apoptosis in adult mice. Findings of this study

may be helpful to uncover the critical problems caused by combination of stress and hypothyroidism leading to male infertility that many researchers were not able to explore and will also be supportive to understand related pathways and their preventive measures. Thus a new theory may be arrived at on restraint stress and hypothyroidism.

ACKNOWLEDGMENTS

This study was supported by National Natural Science Foundation of China (Grant No. 31572403, 31172206 and 31402075).

REFERENCES

1. Bitgul, G., I. Tekmen, D. Keles and G. Oktay, 2013. Protective effects of resveratrol against chronic immobilization stress on testis. ISRN Urol. 10.1155/2013/278720.
2. Arun, S., J. Burawat, W. Sukhorum, A. Sampannang, C. Maneenin and S. Iamsaard, 2016. Chronic restraint stress induces sperm acrosome reaction and changes in testicular tyrosine phosphorylated proteins in rats. Int. J. Reprod. BioMed., 14: 443-452.
3. Weissman, B.A., C.M. Sottas, P. Zhou, C. Iadecola and M.P. Hardy, 2007. Testosterone production in mice lacking inducible nitric oxide synthase expression is sensitive to restraint stress. Am. J. Physiol. Endocrinol. Metab., 292: E615-E620.
4. Arun, S., J. Burawat, W. Sukhorum, A. Sampannang, N. Uabundit and S. Iamsaard, 2016. Changes of testicular phosphorylated proteins in response to restraint stress in male rats. J. Zhejiang Univ. Sci. B, 17: 21-29.
5. Rai, J., S.N. Pandey and R.K. Srivastava, 2003. Effect of immobilization stress on spermatogenesis of albino rats. J. Anat. Soc. India, 52: 52-57.
6. Gao, Y., W.M. Lee and C.Y. Cheng, 2014. Thyroid hormone function in the rat testis. Frontiers Endocrinol., Vol. 5. 10.3389/fendo.2014.00188.
7. Kong, L., Q. Wei, J.S. fedail, F. Shi, K. Nagaoka and G. Watanabe, 2015. Effects of thyroid hormones on the antioxidative status in the uterus of young adult rats. J. Reprod. Dev., 61: 219-227.
8. Nikoobakht, M.R., M. Aloosh, N. Nikoobakht, A. Mehrsay, F. Biniaz and M.A. Karjalian, 2012. The role of hypothyroidism in male infertility and erectile dysfunction. Urol. J., 9: 405-409.
9. Korejo, N.A., Q.W. Wei, A.H. Shah and F.X. Shi, 2016. Effects of concomitant diabetes mellitus and hyperthyroidism on testicular and epididymal histoarchitecture and steroidogenesis in male animals. J. Zhejiang Univ. Sci. B, 17: 850-863.
10. Savill, J., 1992. Apoptosis: A mechanism for regulation of the cell complement of inflamed glomeruli. Kidney Int., 41: 607-612.
11. Mu, Y., W.J. Yan, T.L. Yin and J. Yang, 2016. Curcumin ameliorates high fat diet induced spermatogenesis dysfunction. Mol. Med. Rep., 14: 3588-3594.
12. Murphy, C.J. and J.H. Richburg, 2014. Implications of sertoli cell induced germ cell apoptosis to testicular pathology. Spermatogenesis, Vol. 4. 10.4161/21565562.2014.979110.
13. Moreno, R.D., C. Lizama, N. Urzua, S.P. Vergara and J.G. Reyes, 2006. Caspase activation throughout the first wave of spermatogenesis in the rat. Cell Tissue Res., 325: 533-540.
14. Modric, T., K. Rajkumar and L.J. Murphy, 1999. Thyroid gland function and growth in IGF binding protein-1 transgenic mice. Eur. J. Endocrinol., 141: 149-159.
15. Buras, A., L. Battle, E. Landers, T. Nguyen and N. Vasudevan, 2014. Thyroid hormones regulate anxiety in the male mouse. Hormones Behav., 65: 88-96.
16. Iwakabe, K., M. Shimada, A. Ohta, T. Yahata, Y. Ohmi, S. Habu and T. Nishimura, 1998. The restraint stress drives a shift in Th1/Th2 balance toward Th2-dominant immunity in mice. Immunol. Lett., 62: 39-43.
17. Tian, H.L., L.S. Wei, Z.X. Xu, R.T. Zhao, D.L. Jin and J.S. Gao, 2010. Correlations between blood glucose level and diabetes signs in streptozotocin-induced diabetic mice. Global J. Pharmacol., 4: 111-116.
18. Shinkafi, B.A. and J.K. Ipinjolu, 2012. Gonadosomatic index, fecundity and egg size of *Auchenoglanis occidentalis* (Cuvier and Valenciennes) in Rima River, North-western Nigeria. Niger. J. Basic Applied Sci., 20: 217-224.
19. Zeyl, J.N., O.P. Love and D.M. Higgs, 2014. Evaluating gonadosomatic index as an estimator of reproductive condition in the invasive round goby, *Neogobius melanostomus*. J. Great Lakes Res., 40: 164-171.
20. Valles, A., O. Marti, A. Garcia and A. Armario, 2000. Single exposure to stressors causes long-lasting, stress-dependent reduction of food intake in rats. Am. J. Physiol. Regulatory Integ. Compar. Physiol., 279: R1138-R1144.
21. Cordeiro, A., L.L. de Souza, L.S. Oliveira, L.C. Faustino and L.A. Santiago *et al*., 2013. Thyroid hormone regulation of Sirtuin 1 expression and implications to integrated responses in fasted mice. J. Endocrinol., 216: 181-193.
22. Ferreira, E., A.E. Silva, R. Serakides, A.E.S. Gomes and G.D. Cassali, 2007. Model of induction of thyroid dysfunctions in adult female mice. Arquivo Brasileiro de Medicina Veterinaria e Zootecnia, 59: 1245-1249.
23. Jeong, J.Y., D.H. Lee and S.S. Kang, 2013. Effects of chronic restraint stress on body weight, food intake and hypothalamic gene expressions in mice. Endocrinol. Metab., 28: 288-296.

24. Sominsky, L. and S.J. Spencer, 2014. Eating behavior and stress: A pathway to obesity. Front. Psychol., Vol. 5. 10.3389/fpsyg.2014.00434.
25. Choudhury, S., G.B.N. Chainy and M.M. Mishro, 2003. Experimentally induced hypo and hyper thyroidism influence on the antioxidant defence system in adult rat testis. Andrologia, 35: 131-140.
26. Guesmi, F., H. Beghalem, A.K. Tyagi, M.B. Ali, R.B. Mouhoub, H. Bellamine and A. Landoulsi, 2016. Prevention of H_2O_2 induced oxidative damages of rat testis by *Thymus algeriensis*. Biomed. Environ. Sci., 29: 275-285.
27. Khandve, B., V. Gujar, P. Bokariya, A. Tarnekar and M. Shende, 2013. Deranged spermatogenesis of adult swiss albino mice as effect of immobilisation stress-histological study. Iosr J. Pharm., 3: 7-10.
28. Rao, J.N., J.Y. Liang, P. Chakraborti and P. Feng, 2003. Effect of thyroid hormone on the development and gene expression of hormone receptors in rat testes *in vivo*. J. Endocrinol. Investig., 26: 435-443.
29. Naghdi, M., M. Maghbool, M. Seifalah-Zade, M. Mahaldashtian and Z. Makoolati *et al*., 2016. Effects of common fig (*Ficus carica*) leaf extracts on sperm parameters and testis of mice intoxicated with formaldehyde. Evid. Based Complementary Alter. Med., Vol. 2016. 10.1155/2016/2539127
30. Consten, D., J. Bogerd, J. Komen, J.G.D. Lambert and H.J. Goos, 2001 2001. Long-term cortisol treatment inhibits pubertal development in male common carp, *Cyprinus carpio* L. Biol. Reprod., 64: 1063-1071.
31. Auharek, S.A. and L.R. De Franca, 2010. Postnatal testis development, Sertoli cell proliferation and number of different spermatogonial types in C57BL/6J mice made transiently hypo- and hyperthyroidic during the neonatal period. J. Anat., 216: 577-588.
32. Narimani-Rad, M., V. Babapour, M. Zendehdel, M.M. Abbasi and S. Farhang, 2014. Investigation on serum hormonal parameters (Ghrelin, Corticosterone, Insulin, T_3 and T_4) in chronic mild stress rat model of depression. Arastırılmasi, 20: 267-271.
33. Baumgartner, A., K.J. Graf, I. Kurten and H. Meinhold, 1988. The hypothalamic-pituitary-thyroid axis in psychiatric patients and healthy subjects: Parts 1-4: Part 4: TRH tests, thyroxine, triiodothyronine and reverse triiodothyronine determinations in medical students during a major examination. Psychiatry Res., 24: 316-332.
34. Kirrkegaard, C. and J. Faber, 1998. The role of thyroid hormones in depression. Eur. J. Endocrinol., 138: 1-9.
35. Olivares, E.L., C. Silva-Almeida, F.M. Pestana, R. Sonoda-Cortes and I.G. Araujo *et al*., 2012. Social stress-induced hypothyroidism is attenuated by antidepressant treatment in rats. Neuropharmacology, 62: 446-456.
36. Salem, E.A., N.A. Salem and W.J. Hellstrom, 2017. Therapeutic effect of ozone and rutin on adriamycin induced testicular toxicity in an experimental rat model. Andrologia, Vol. 49. 10.1111/and.12603.
37. Orr, T.E. and D.R. Mann, 1992. Role of glucocorticoids in the stress-induced suppression of testicular steroidogenesis in adult male rats. Hormone Behav., 26: 350-363.
38. Cleare, A.J., A. McGregor and V. O'Keane, 1995. Neuroendocrine evidence for an association between hypothyroidism, reduced central 5 HT activity and depression. Clin. Endocrinol., 43: 713-719.
39. Bissette, G., E. Widerlov, H. Walleus, I. Karlsson, K. Eklund, A. Forsman and C.B. Nemeroff, 1986. Alterations in cerebrospinal fluid concentrations of somatostatinlike immunoreactivity in neuropsychiatric disorders. Arch. General Psychiatry, 43: 1148-1151.
40. Bahls, S.C. and G.A. de Carvalho, 2004. The relation between thyroid function and depression: A review. Revista Brasileira de Psiquiatria, 26: 40-48.
41. Tahmaz, L., A. Gokalp, Y. Kibar, I. Kocak, O. Yalcın and Y. Ozercan, 2000. Effect of hypothyroidism on the testes in mature rats and treatment with levothyroxine and zinc. Andrologia, 32: 85-89.
42. Hamid, W., 2013. Oxidative stress induced histological changes in thyroid of hyperthyroidism patients. Int. J. Eng. Sci. Innovat. Technol., 2: 324-330.
43. Ai, J., A. Zarifkar, M.A. Takhshid, J. Alavi and M. Moradzadeh, 2007. The effect of thyroid activity on adult rat spermatogenesis. Iran. J. Vet. Res., 8: 155-160.
44. Krajewska-Kulak, E. and P. Sengupta, 2013. Thyroid function in male infertility. Frontiers Endocrinol., Vol. 4. 10.3389/fendo.2013.00174.
45. Swami, C.G., J. Ramanathan and C.C. Jeganath, 2007. Noise exposure effect on testicular histology, morphology and on male steroidogenic hormone. Malaysian J. Med. Sci., 14: 28-35.
46. Rai, J., S.N. Pandey and R.K. Srivastava, 2004. Testosterone hormone level in albino rats following restraint stress of long duration. J. Anat. Soc. India, 53: 17-19.
47. Tavakoli, P., R. Ahmadi and M. Mafi, 2012. Restraint stress is biomedically important in male reproductive failure. Proceedings of the International Conference on Chemical, Biological and Medical Sciences, August 25-26, 2012, Kuala Lumpur, pp: 17-19.
48. Yin, Y., K.L. Hawkins, W.C. de Wolf and A. Morgentaler, 1997. Heat stress causes testicular germ cell apoptosis in adult mice. J. Androl., 18: 159-165.

49. Chowdhury, A.K. and E. Steinberger, 1970. Early changes in the germinal epithelium of rat testes following exposure to heat. J. Repro. Fertil., 22: 205-212.
50. Henriksen, K. and M. Parvinen, 1998. Stage-specific apoptosis of male germ cells in the rat: Mechanisms of cell death studied by supravital squash preparations. Tissue Cell., 30: 692-701.
51. Yazawa, H., I. Sasagawa and T. Nakada, 2000. Apoptosis of testicular germ cells induced by exogenous glucocorticoidin rats. Hum. Reprod., 15: 1917-1920.
52. Hassanpour, H., A. Kadivar, P. Mirshokraei, H. Nazari, A. Afzali and M. Badisanaye, 2015. Connexin-43: A possible mediator of heat stress effects on ram Sertoli cells. Vet. Res. Forum, 6: 125-130.
53. Kumar, A., S. Shekhar and B. Dhole, 2014. Thyroid and male reproduction. Indian J. Endocrinol. Metab., 18: 23-31.
54. Chen, Y., Q. Wang, F.F. Wang, H.B. Gao and P. Zhang, 2012. Stress induces glucocorticoid-mediated apoptosis of rat Leydig cells *in vivo*. Stress, 15: 74-84.