



Research Article

Gastroprotective Effects of *Dregea sinensis* Hemsl. (Daibaijie) Against Aspirin-induced Gastric Ulcers in Rats

¹Imran Suheryani, ¹Yujuan Li, ¹Rongji Dai, ¹Xiujie Liu, ²Shoaib Anwer, ¹Song Juan and ¹Yulin Deng

¹School of Life Sciences, Beijing Institute of Technology, 5 South Zhongguancun Street, 100081 Beijing, China

²School of Materials Science and Engineering, Beijing Institute of Technology, Beijing, China

Abstract

Background and Objective: Daibaijie (DBJ) is Chinese name of *Dregea sinensis* Hemsl. Traditionally it is used for treatment of various diseases. The objective of study was to determine the gastroprotective effect of DBJ against aspirin-induced gastric ulcers. **Methodology:** In this research 60 Sprague Dawley (SD) rats were divided into 6 groups. Water was provided to normal and negative groups, omeprazole (20 mg kg⁻¹) to positive group and DBJ extract (1, 2 and 3 g kg⁻¹) to low, middle and high dose groups, respectively as pre-treatment. After 1 h of pre-treatment, aspirin (250 mg kg⁻¹) were administered to all groups except normal group. Above scheduled treatments were provided continuously for 2 weeks. After 2 weeks, rats were sacrificed. The pH plus acidity, Gastric Wall Mucus (GWM), ulcer index, histological assessment, superoxide dismutase (SOD), catalase (CAT), glutathione peroxidase (GSH-Px), malondialdehyde (MDA), myeloperoxidase (MPO), prostaglandin E2 (PGE2) and protein concentration were examined. Moreover, all the data were statistically analyzed by one way ANOVA, followed by student's t-test to compare different groups. **Results:** The DBJ showed a dose-dependent (60.11-84.34%) protection, while omeprazole showed (82.74%) protection. In addition, DBJ also considerably increased ($p < 0.01$) the pH and reduced the acidity of gastric contents. Gastric levels of antioxidant enzymes SOD, CAT, GSH-Px were markedly enhanced while MDA level and MPO activity significantly reduced ($p < 0.001$) by DBJ. Furthermore, DBJ also increased the PGE2 level and mucus production. **Conclusion:** It is concluded from results, that DBJ extract has great potential to prevent stomach ulcers. The gastroprotective effect might be associated to increase in PGE2 to produce mucus and inhibition of neutrophil infiltration due to decrease in MPO activity.

Key words: *Dregea sinensis* Hemsl., gastroprotection, aspirin, neutrophil infiltration, myeloperoxidase (MPO), Prostaglandin E2 (PGE2), gastric ulcer

Received:

Accepted:

Published:

Citation: Imran Suheryani, Yujuan Li, Rongji Dai, Xiujie Liu, Shoaib Anwer, Song Juan and Yulin Deng, 2017. Gastroprotective effects of *Dregea sinensis* Hemsl. (Daibaijie) against aspirin-induced gastric ulcers in rats. Int. J. Pharmacol., CC: CC-CC.

Corresponding Author: Rongji Dai, School of Life Sciences, Beijing Institute of Technology, 5 South Zhongguancun Street, 100081 Beijing, China
Tel: 010-68949331 Fax: 010-68467208-112

Copyright: © 2017 Imran Suheryani *et al.* This is an open access article distributed under the terms of the creative commons attribution License, which permits unrestricted use, distribution and reproduction in any medium, provided the original author and source are credited.

Competing Interest: The authors have declared that no competing interest exists.

Data Availability: All relevant data are within the paper and its supporting information files.

INTRODUCTION

Gastric ulcer is very dangerous health problem due to its high morbidity and mortality^{1,2}. It is most common disease of gastrointestinal tract and affects about 10% population of the world³. In normal conditions, gastric mucosa retains a balance in between protective and injurious factors. Injurious factors include gastric acid, pepsin, free radicals and protective factors include mucus, bicarbonates, prostaglandins etc. Gastric ulcer is caused due to overproduction of injurious elements or decrease in protective factors^{4,5}. There are so many factors which can cause gastric ulcer, which includes psychological stress, cigarette smoking, alcohol consumption, nutritional deficiencies, *H. pylori* infection and consumption of NSAIDs for longer period of time⁶.

In this study aspirin was used to produce gastric ulcers. Aspirin causes ulcer by inhibiting cyclooxygenase (COX) enzyme and to reduce the synthesis of prostaglandins (PGs). Moreover, aspirin increases Reactive Oxygen Species (ROS)⁷ and damage gastric tissue by inducing lipid peroxidation and inhibiting antioxidant enzymes.

In recent times Chinese Medicines (CM) is getting popularity and acceptance in many countries, because it is general belief that these drugs are inexpensive and without any side effects⁸. Previous studies revealed that about 1.5 billion people consume these herbal medicines in the world⁹. *Dregea sinensis* Hemsl. (Daibaijie) belongs to Asclepiadaceae family and it is a common herbal medicine of Dai ethnicity. Traditionally, it is used for detoxification to remove toxins from body, anti-inflammatory and to relieve pain and fever^{10,11}. One pharmacological study in our school revealed that it has immunomodulatory effects¹², but no one has conducted research about gastroprotective effect of Daibaijie. The main aim of this research was to evaluate the gastroprotective potential of DBJ in aspirin induced ulcers in rats. In this research co-treatment with DBJ and aspirin has been used and it is a new potential approach to advance new knowledge for decreasing the risk of stomach ulcer in patients on long-term therapy of NSAIDs or aspirin.

MATERIALS AND METHODS

Drugs and chemicals: Daibaijie were collected in February 2016 from Yunnan province, China. The herbal drug was identified by Dr. Shaohua Jia. Omeprazole and Aspirin obtained from J and K scientific Ltd. (Beijing, china). Alcian Blue obtained from BBI Life Sciences Corporation (Shanghai, China). The PGE2 Elisa Kit Obtained from Beijing Freemore

Bioscience, Co., Ltd. (Beijing, china). The SOD, CAT, GSH-PX, MPO, MDA and Coomassie brilliant blue assay kits were purchased from Jiancheng Institute of Bioengineering (Nanjing, China). All other reagents were of commercially available analytical grade.

Animals: Male Sprague-Dawley rats weighing 220-250 g were obtained from the Military Medical Sciences Experimental Animal Co. Ltd. (Beijing, China). The animals were kept in polypropylene cages in an air-conditioned room maintained at a precise temperature of 22-25 °C, humidity of 60-70% and at an alternating cycle of 12 h light plus 12 h dark. Standard laboratory food pellets and free access to water were made available for them. Adult male SD rats have cared according to guidelines provided by National Institute of Health (NIH)¹³ and animal ethics approval was achieved from Animal Ethics Committee, Beijing Institute of Technology, Beijing (BIT), China with reference No: SYXK (Jing) 2012-0035.

Extraction and preparation of drugs: Daibaijie were finely powdered and 0.5 kg powder was taken and extracted in 9 L of 90% analytical grade ethanol for 1 h, after that extract was filtered and residue were extracted again with 9 L of 80% ethanol for 1 h and filtered again. Above process of extraction and filtration repeated thrice. The entire first, second and third clear supernatants were pooled and evaporated by rotary evaporator. Above prepared extract used to check the biological activity.

Afterwards the aqueous suspensions of both positive control drug (Omeprazole) and test drug DBJ were prepared by using 0.1% sodium carboxymethyl cellulose (Sod. CMC) as a suspending agent. Moreover, drugs were administered orally to rats at appropriate doses.

Experimental procedure: Prior to start of experiment, rats were provided with a pre-experimental phase of 7 days to acclimatise the environment of animal house. After that, they were divided into 6 experimental groups, each group comprises of 8 animals. The groups and their doses were as follows:

- **Group 1:** Normal group received 0.5% sodium CMC
- **Group 2:** Negative group received 0.5% sodium CMC
- **Group 3:** Positive group received omeprazole 20 mg kg⁻¹
- **Group 4:** Low dose received DBJ 1.0 g kg⁻¹
- **Group 5:** Middle dose received DBJ 2.0 g kg⁻¹
- **Group 6:** High dose received DBJ 3.0 g kg⁻¹

Exactly after 1 h of above doses, Aspirin (250 mg kg⁻¹) were administered to all groups except normal group. Drugs were administered intragastrically once a day, continuously for two weeks. After 14 days of scheduled treatment rats were sacrificed and stomachs were collected for further analysis.

Evaluation of pH, free and total acidity of gastric content:

For estimation of pH, free and total acidity the stomachs were softly squeezed to collect gastric juice. Collected gastric juice was then centrifuged for 15 min at 3500 rpm. Clear supernatant was used to measure acidity and pH of gastric juice. The pH of gastric juice were measured by digital pH meter, furthermore, total and free acidity were assessed by titration, by utilizing previous method of Srivastava *et al.*¹⁴.

Assessment of Gastric Wall Mucus (GWM): Previous method of Corne *et al.*¹⁵ was used to estimate the GWM.

Evaluation of gastric ulcer: For estimation of gastric ulcer, stomachs were opened along with greater curvature and washed with cold physiological saline to remove gastric residual debris and blood clots. The sum of length (mm) of the entire lesions for each stomach were calculated and used as ulcer index. Protection percentage was calculated by Eq. 1¹⁶:

$$\text{Protection (\%)} = \frac{\text{UI}_{\text{control}} - \text{UI}_{\text{treated}}}{\text{UI}_{\text{control}}} \times 100 \quad (1)$$

Estimation of biochemical parameters: Gastric tissue samples, which were preserved previously at -80°C were weighed. Weighed gastric tissues were homogenized by a glass homogenizer in (10% w/v) normal saline in ice water bath. Homogenate then centrifuged at 3500 rpm for 15 min at cold environment to collect the clear supernatant. The Clear supernatant was used to measure the biochemical parameters like CAT, SOD, GSH-Px, MPO, MDA, PGE2 and protein concentration by using commercially available assay kits according to instructions of the manufacturers. The analyzed

parameters were expressed as per mg protein; moreover, protein concentrations were analyzed by Coomassie brilliant blue method¹⁷.

Histology of gastric mucosa: Hematoxylin and eosin staining were performed for histological studies. For histological estimation gastric tissues were fixed in 0.01 M PBS (pH 7.4) containing 4% formalin, dehydrated by gradient alcohol and then fixed in paraffin. Tissues sample (5 μm thick) was placed on glass slides, deparaffinized and stained with Hematoxylin-eosin dyes. H.E. stained slides then observed under Olympus BX50 (Olympus, Japan) microscope. Cool SNAP CCD (Photometrics, USA) were used to capture the images.

Statistical analysis: All the results are stated as Mean ± SEM. Statistical analysis was performed by using one way ANOVA, followed by Student's t-test to compare two groups. A probability level of lower than 0.05 was considered to be significant¹⁸.

RESULTS

Protective effect of DBJ on aspirin induced gastric ulcers:

Protective effect of DBJ is depicted in Table 1. In this experiment it is observed that the rats pretreated with different doses of DBJ and omeprazole has significantly reduced (p<0.001) the gastric ulcers. Practically no any gastric ulcer was seen in the normal group while aspirin caused 64.81 ± 2.28 mm² ulcers in aspirin group. In the omeprazole group, the ulcer area was considerably reduced with an average of 17.26 ± 0.99 mm² and provides 82.74% protection. Further pre-treatment with different doses DBJ showed significant (p<0.001) protection when compared with aspirin group.

Effect of DBJ on Gastric Wall Mucus (GWM) contents:

In this experiment, aspirin caused a significant (p<0.001) decrease in GWM in gastric tissues. While pretreatment with DBJ extract

Table 1: Effects of DBJ to protect aspirin-induced gastric ulcers

Groups	Dose	Ulcer index (mm)	Protection (%)
Normal	0.5% Sod. CMC	00	100
Aspirin	250 mg kg ⁻¹	64.81 ± 2.28 ^{##}	00 ^{##}
Omeprazole	20 mg kg ⁻¹	17.26 ± 0.99 ^{***}	82.74 ^{***}
Low dose DBJ	1 g kg ⁻¹	39.89 ± 1.80 ^{***}	60.11 ^{***}
Middle dose DBJ	2 g kg ⁻¹	29.08 ± 1.76 ^{***}	70.92 ^{***}
High dose DBJ	3 g kg ⁻¹	15.66 ± 0.759 ^{***}	84.34 ^{***}

Sod. CMC: Sodium carboxymethyl cellulose, DBJ: Daibaijie, Results are expressed as Mean ± SEM and analyzed by ANOVA followed by student's t-test, ^{##}p<0.001, compared with the normal group, ^{***}p<0.001, compared with the aspirin group

Table 2: Effects of DBJ extract on GWM and PGE2

Groups	Dose	GWM (Mcg g ⁻¹ tissue)	PGE2 (pg mL ⁻¹)
Normal	0.5% Sod. CMC	122.41 ± 2.21	61.50 ± 1.80
Aspirin	250 mg kg ⁻¹	61.22 ± 2.44 ^{###}	26.50 ± 1.29 ^{###}
Omeprazole	20 mg kg ⁻¹	108.34 ± 2.31 ^{***}	56.93 ± 1.23 ^{***}
Low dose DBJ	1 g kg ⁻¹	72.88 ± 1.80 ^{**}	35.91 ± 1.52 ^{**}
Middle dose DBJ	2 g kg ⁻¹	78.01 ± 1.88 ^{**}	45.07 ± 2.15 ^{***}
High dose DBJ	3 g kg ⁻¹	97.55 ± 1.67 ^{***}	62.51 ± 1.58 ^{***}

Sod. CMC: Sodium carboxymethyl cellulose, GWM: Gastric wall mucus, PGE2: Prostaglandin E2, DBJ: Daibaijie, Results are expressed as Mean ± SEM and analyzed by ANOVA followed by student's t-test, ^{###}p<0.001, compared with the normal group, ^{**}p<0.01, ^{***}p<0.001, compared with the aspirin group

Table 3: Effects of DBJ extract on pH, free and total acidity of gastric fluids

Groups	Dose	pH	Free acidity (mEq L ⁻¹)	Total acidity (mEq L ⁻¹)
Normal	0.5% Sod. CMC	3.25 ± 0.03	68.99 ± 1.12	115.13 ± 0.95
Aspirin	250 mg kg ⁻¹	1.22 ± 0.02 [#]	84.65 ± 5.43 [*]	151.75 ± 3.56 ^{###}
Omeprazole	20 mg kg ⁻¹	3.10 ± 0.07 [*]	69.06 ± 1.06 [*]	119.00 ± 1.97 ^{***}
Low dose DBJ	1 g kg ⁻¹	2.24 ± 0.04 [*]	75.75 ± 0.66 [*]	133.44 ± 2.91 ^{***}
Middle dose DBJ	2 g kg ⁻¹	3.16 ± 0.18 [*]	69.60 ± 0.37 [*]	121.30 ± 2.40 ^{***}
High dose DBJ	3 g kg ⁻¹	3.36 ± 0.05 ^{**}	66.18 ± 1.29 ^{**}	117.18 ± 1.67 ^{***}

DBJ: Daibaijie, Results are expressed as Mean ± SEM and analyzed by ANOVA followed by student's t-test, [#]p<0.05, ^{###}p<0.001, compared with the normal group, ^{*}p<0.05, ^{**}p<0.01, ^{***}p<0.001, compared with the aspirin group

significantly restored the depleted value of GWM at all doses. Furthermore DBJ extract showed a dose-dependent increase in it. High dose showed significant (p<0.001) increase in GWM when compared with aspirin group (Table 2).

Effect of DBJ on prostaglandin E2 (PGE2): In this study, aspirin caused significant decrease (p<0.001) in PGE2 level in gastric tissues, while pretreatment with DBJ extract restored the decreased level of PGE2 at all doses. Furthermore DBJ extract showed a dose-dependent increase PGE2. High dose showed significant (p<0.001) increase when compared with aspirin group. Likewise, the animals pretreated with Omeprazole also increased PGE2 but at lower extent as compare to DBJ extract (Table 2).

Effect of DBJ on pH and acidity of gastric juice: As illustrated in Table 3, aspirin caused significant decrease (p<0.05) in pH of gastric juices from 3.25 ± 0.03-1.22 ± 0.02, while pretreatment with omeprazole and all doses of DBJ has significantly (p<0.05) increased the pH when compared to aspirin group. Moreover; administration of both Omeprazole and DBJ caused a significant (p<0.001) decrease in the total acidity of gastric juices.

Effect of DBJ on MPO, GSH-Px, SOD, CAT, MDA and protein concentration: The antioxidant activities in gastric tissue homogenates were different among the groups. Aspirin caused significant decrease (p<0.001) in SOD, GSH-Px and CAT activities in gastric tissues. While, Omeprazole (positive control drug) significantly (p<0.001) increase the level of CAT, GSH-Px

and SOD. Likewise DBJ (experimental groups) also caused an increase in CAT, GSH-Px and SOD but less efficient as compare to omeprazole. Furthermore, aspirin caused significant increase (p<0.001) in MPO and MDA, while Omeprazole and DBJ (experimental groups) had shown a significant decrease (p<0.001) in the MPO and considerable decrease (p<0.01) MDA when compared to Aspirin group. The decrease in MPO and MDA levels by DBJ extract was in proportion to the increasing test doses. Further aspirin also caused a considerable (p<0.01) decrease in Protein concentration in rats from 4.57 ± 0.34-3.33 ± 0.23 mg protein mL⁻¹. While, omeprazole (20 mg kg⁻¹) and different doses of DBJ has considerably (p<0.01) increased the protein concentration as depicted in Fig. 1.

Histological evaluation of gastric lesions: As depicted in Fig. 2, no any pathological changes were observed in the mucosa of normal group animals (Fig. 2a) but aspirin group showed relatively large scale damage in glandular mucosa, hemorrhage and inflammatory cell infiltration around the necrotized area (Fig. 2b). Pretreatment low, middle and high doses of DBJ (Fig. 2d-f) had provided relatively good protection of gastric tissues as compared to aspirin group and omeprazole (Fig. 2c).

DISCUSSION

Present study is the first study to evaluate the gastroprotective effect of three different doses (1.0, 2.0 and 3.0 g kg⁻¹) of DBJ and omeprazole (20 mg kg⁻¹) against aspirin

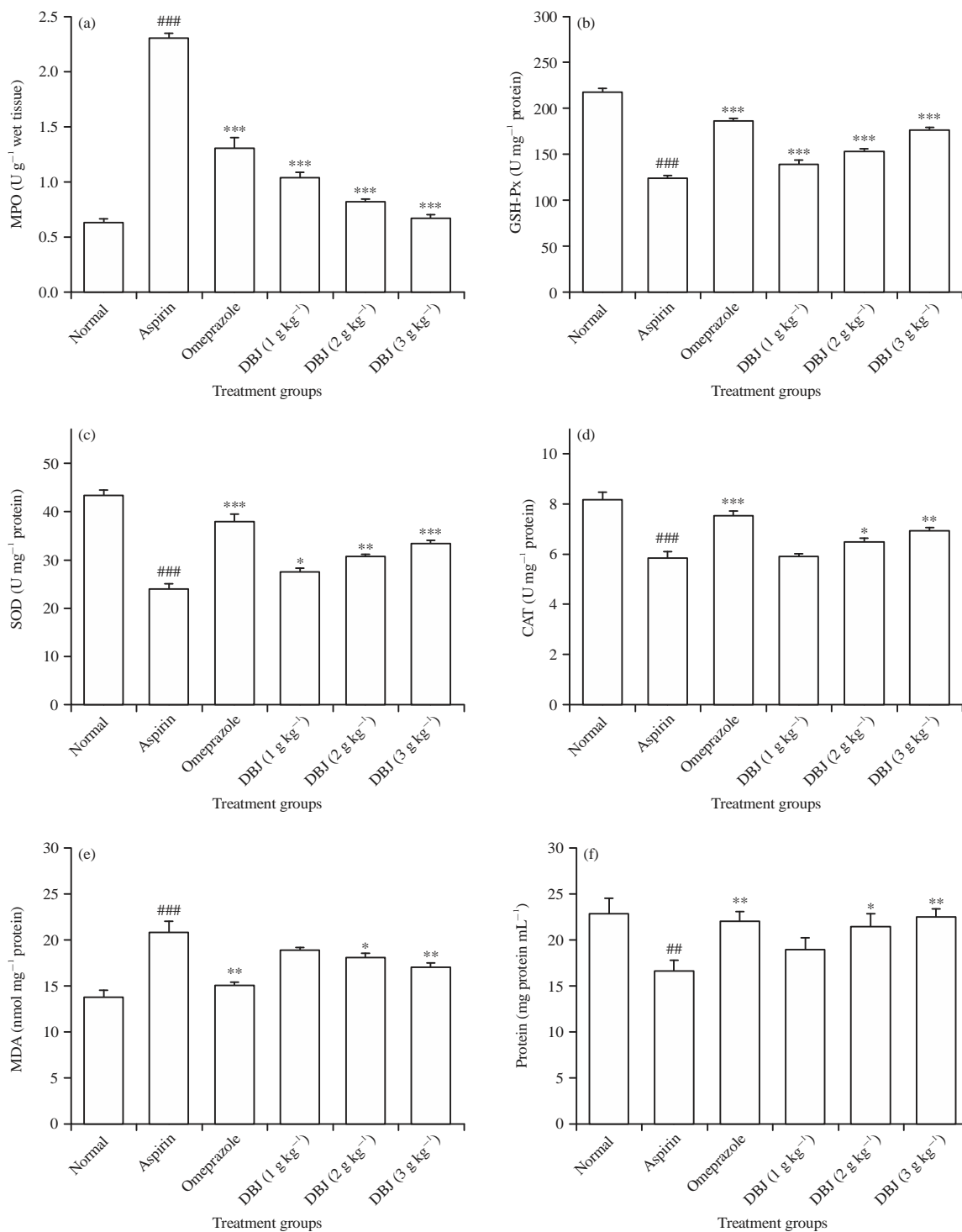


Fig. 1(a-f): Effects of different doses of DBJ and omeprazole on (a) MPO, (b) GSH-Px, (c) SOD, (d) CAT, (e) MDA and (f) Protein concentration in aspirin-induced gastric ulcers

Results are expressed as Mean \pm SEM, ##p<0.01, ###p<0.001, compared with the normal group, *p<0.05, **p<0.01, ***p<0.001, compared with the aspirin group

induced gastric ulcers in rats. Parietal cells are located in the gastric glands, which are responsible for secretion of gastric acid (HCl)⁶. The increase in gastric acid secretion by the

parietal cells will cause gastric ulcer. Therefore, the inhibition of acid secretion is the main target for the gastroprotection¹⁹. Results of this study shown that DBJ increased the pH and

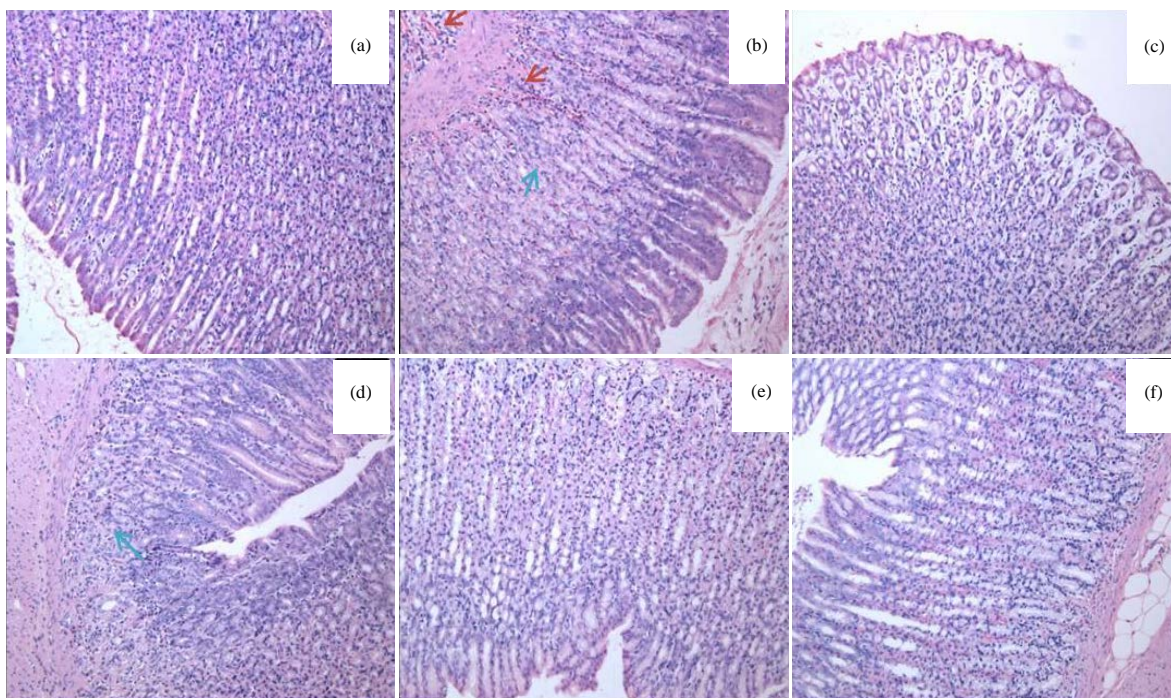


Fig. 2(a-f): Effect of DBJ extract on histological assessment in aspirin-induced stomach ulcer of rats (HE staining, magnification 100X), (a) Normal group, (b) Negative group: Necrosis (indicated by red arrow) and (blue arrow indicates) inflammatory cell infiltration in glandular stomach mucosa, (c) Positive control and (d-f) Depict low, middle and high dose groups, respectively

reduced the free and total acidity in gastric contents, these results of this study are consistent to a previous study²⁰.

The PGE₂ is present in the gastrointestinal tract and responsible to protect ulcer by production of mucus and bicarbonates²¹. Mucus and bicarbonate will work as gastroprotective and inhibit acid secretion²² in the stomach. Inhibition of prostaglandin synthesis by aspirin will decrease mucus production and cause gastric ulcers. Similarly, PGE₂ and gastric mucus levels were decreased by aspirin but pretreatment with DBJ has increased the depleted levels of both PGE₂ and mucus, these results of this study are parallel to the previous studies^{20,23}. Furthermore, in this study it is resulted that aspirin has induced the oxidative stress in gastric mucosa, which is evaluated by increased levels of MDA and decreased levels of antioxidant enzymes like SOD, CAT and GPH-Px, our results are perfect agreement with the reported one that aspirin are responsible to cause oxidative stress²⁴⁻²⁶. Further DBJ has decreased the MDA level and increased the level of antioxidant enzymes like SOD, CAT and GPH-Px, the mentioned results are consistent with the previous report²⁷.

The increase in neutrophils is the key source to generate Reactive Oxygen Species (ROS)²⁸, which will cause gastric

damage by release and aggregation of oxygen free radicals and proteases²⁹. The neutrophil infiltration can be measured in the gastric mucosal tissues by myeloperoxidase (MPO) enzyme³⁰. The critical analysis showed that aspirin caused significant increase ($p < 0.001$) in MPO in gastric tissues³¹ but pretreatment by DBJ has significantly reduced ($p < 0.001$) MPO level. Thus, the results of this study suggested that DBJ has great potential to protect aspirin induced ulcers. Moreover Daibaijie has not shown any behavioural modifications such as restlessness; irritation, abnormal locomotion, respiratory distress and catalepsy during the course of treatment. These results suggested that this drug has good safety profile.

CONCLUSION

The results of this study revealed that DBJ extract has gastroprotective effect against aspirin-induced gastric ulcers in rats. In this research observed that administration of DBJ significantly decreased the MPO activity, MDA level and increased the PGE₂ and gastric wall mucus. The gastroprotective effect might be associated with the inhibition of neutrophil infiltration and enhancement in defensive

factors like PGE2 and gastric wall mucus. Results of this study provide logical support that DBJ could be new potential drug to treat gastric ulcers.

SIGNIFICANCE STATEMENT

This study discovers the gastroprotective effect of *Dregea sinensis* Hemsl. (Daibaijie) in aspirin induced ulcers that can be beneficial to reduce the risks of gastric ulcer caused by NSAIDs like aspirin. This study will help the researchers to find the potential compounds responsible for gastroprotection that many researchers were not able to explore. Thus a new idea/theory on combination of NSAIDs like aspirin and DBJ or its possible potential compounds, is suggested to prevent the gastric ulcer in patients on long-term therapy of NSAIDs.

ACKNOWLEDGMENTS

This study was funded by Ministry of Science and Technology, China (Grant No. 2013YQ03059514).

REFERENCES

1. Brown, L.F. and D.E. Wilson, 1999. Gastroduodenal ulcers: Causes, diagnosis, prevention and treatment. *Compr. Ther.*, 25: 30-38.
2. Dimaline, R. and A. Varro, 2007. Attack and defence in the gastric epithelium-a delicate balance. *Exp. Physiol.*, 92: 591-601.
3. Zapata-Colindres, J.C., S. Zepeda-Gomez, A. Montano-Loza, E. Vazquez-Ballesteros, J.D.J. Villalobos and F. Valdovinos-Andraca, 2006. The association of *Helicobacter pylori* infection and nonsteroidal anti-inflammatory drugs in peptic ulcer disease. *Can. J. Gastroenterol.*, 20: 277-280.
4. Allen, A. and A. Garner, 1980. Mucus and bicarbonate secretion in the stomach and their possible role in mucosal protection. *Gut*, 21: 249-262.
5. Laine, L., K. Takeuchi and A. Tarnawski, 2008. Gastric mucosal defense and cytoprotection: Bench to bedside. *Gastroenterology*, 135: 41-60.
6. Rang, H.P., M.M. Dale, J.M. Ritter, R.J. Flower and G. Henderson, 2012. *Rang and Dale's Pharmacology*. 7th Edn. Churchill Livingstone, Edinburgh.
7. Pohle, T., T. Brzozowski, J.C. Becker, I.R. van der Voort and A. Markmann *et al*, 2001. Role of reactive oxygen metabolites in aspirin-induced gastric damage in humans: Gastroprotection by vitamin C. *Aliment. Pharm. Therap.*, 15: 677-687.
8. Gupta, L.M. and R. Raina, 1998. Side effects of some medicinal plants. *Curr. Sci.*, 75: 897-900.
9. Hosbach, I., G. Neeb, S. Hager, S. Kirchhoff and B. Kirschbaum, 2003. In defence of traditional Chinese herbal medicine. *Anaesthesia*, 58: 282-283.
10. Committee of Flora of China, 2010. *Flora of China*. Vol. 63. Science Press, Beijing, Pages: 496.
11. Committee of Chinese Materia Medica, 1999. *Chinese Materia Medica*. Vol. 6. Shanghai Scientific and Technical Publishers, Shanghai, Pages: 358.
12. Lin, F.K., J.W. Fu, J. Liu, R.P. Hou and B.W. Yu, 2015. Protective effect of Daibaijie on immune function under microgravity environment. *Trans. Beijing Inst. Technol.*, 35: 29-33.
13. Kanter, M., H. Demir, C. Karakaya and H. Ozbek, 2005. Gastroprotective activity of *Nigella sativa* L oil and its constituent, thymoquinone against acute alcohol-induced gastric mucosal injury in rats. *World J. Gastroenterol.*, 11: 6662-6666.
14. Srivastava, V., A.H.M. Viswanathaswamy and G. Mohan, 2010. Determination of the antiulcer properties of sodium cromoglycate in pylorus-ligated albino rats. *Indian J. Pharmacol.*, 42: 185-188.
15. Corne, S.J., S.M. Morrissey and R.J. Woods, 1974. Proceedings: A method for the quantitative estimation of gastric barrier mucus. *J. Physiol.*, 242: 116-117.
16. Li, W.F., D.J. Hao, T. Fan, H.M. Huang, H. Yao and X.F. Niu, 2014. Protective effect of chelerythrine against ethanol-induced gastric ulcer in mice. *Chemico-Biol. Interact.*, 208: 18-27.
17. Bradford, M.M., 1976. A rapid and sensitive method for the quantitation of microgram quantities of protein utilizing the principle of protein-dye binding. *Anal. Biochem.*, 72: 248-254.
18. Antonisamy, P., P. Kannan, A. Aravinthan, V. Duraipandiyar and M. Valan Arasu *et al*, 2014. Gastroprotective activity of violacein isolated from *Chromobacterium violaceum* on indomethacin-induced gastric lesions in rats: Investigation of potential mechanisms of action. *Sci. World J.*, Vol. 2014. 10.1155/2014/616432.
19. Jain, K.S., A.K. Shah, J. Bariwal, S.M. Shelke, A.P. Kale, J.R. Jagtap and A.V. Bhosale, 2007. Recent advances in proton pump inhibitors and management of acid-peptic disorders. *Bioorganic Med. Chem.*, 15: 1181-1205.
20. Zakaria, Z.A., T. Balan, V. Suppaiah, S. Ahmad and F. Jamaludin, 2014. Mechanism(s) of action involved in the gastroprotective activity of *Muntingia calabura*. *J. Ethnopharmacol.*, 151: 1184-1193.
21. Rachchh, M.A. and S.M. Jain, 2008. Gastroprotective effect of *Benincasa hispida* fruit extract. *Indian J. Pharmacol.*, 40: 271-275.
22. Adhikary, B., S.K. Yadav, K. Roy, S.K. Bandyopadhyay and S. Chattopadhyay, 2010. Black tea and theaflavins assist healing of indomethacin-induced gastric ulceration in mice by antioxidative action. *Evidence-Based Complementary Alter. Med.*, Vol. 2011. 10.1155/2011/546560.

23. Liu, Y.H., Z.B. Zhang, Y.F. Zheng, H.M. Chen and X.T. Yu *et al*, 2015. Gastroprotective effect of andrographolide sodium bisulfite against indomethacin-induced gastric ulceration in rats. *Int. Immunopharmacol.*, 26: 384-391.
24. Jainu, M., K.V. Mohan and C.S.S. Devi, 2006. Protective effect of *Cissus quadrangularis* on neutrophil mediated tissue injury induced by aspirin in rats. *J. Ethnopharmacol.*, 104: 302-305.
25. Liu, L., J. Cui, C.J. Song, J.S. Bian and A. Sparatore *et al*, 2012. H(2) S-releasing aspirin protects against aspirin-induced gastric injury via reducing oxidative stress. *PLoS One*, Vol. 7. 10.1371/journal.pone.0046301.
26. Zhang, J.Y., Q.F. Wu, Y. Wan, S.D. Song and J. Xu *et al*, 2014. Protective role of hydrogen-rich water on aspirin-induced gastric mucosal damage in rats. *World J. Gastroenterol.*, 20: 1614-1622.
27. Sebai, H., M.A. Jabri, A. Souli, K. Hosni and S. Selmi *et al*, 2014. Protective effect of *Artemisia campestris* extract against aspirin-induced gastric lesions and oxidative stress in rat. *RSC Adv.*, 4: 49831-49841.
28. Karakoyun, B., M. Yuksel, F. Ercan, C. Erzik and B.C. Yegen, 2009. Alpha-lipoic acid improves acetic Acid-induced gastric ulcer healing in rats. *Inflammation*, 32: 37-46.
29. Chanudom, L. and J. Tangpong, 2015. Anti-inflammation property of *Syzygium cumini* (L.) Skeels on indomethacin-induced acute gastric ulceration. *Gastroenterol. Res. Pract.*, Vol. 2015. 10.1155/2015/343642.
30. Yang, C., Y. Song and H. Wang, 2017. Suppression of RAGE and TLR9 by ketamine contributes to attenuation of lipopolysaccharide-induced acute lung injury. *J. Invest. Surg.*, 30: 177-186.
31. Zhang, W., K. Liu, L. Li, Y. Li and X. Sui *et al*, 2016. Therapeutic effect of low molecular weight chitosan containing sepia ink on ethanol-induced gastric ulcer in rats. *Acta Cirurgica Brasileira*, 31: 813-820.