



Research Article

Effect of Memantine Hydrochloride on Cisplatin-induced Toxicity with Special Reference to Renal Alterations in Mice

¹Nadia Abdulkareem Salih and ²Banan Khalid AL-Baggou

¹Department of Basic Sciences, College of Veterinary Medicine, University of Sulaimani, Sulaimani, Iraq

²Department of Pharmacology and Toxicology, College of Veterinary Medicine, University of Mosul, Mosul, Iraq

Abstract

Background and Objective: Cisplatin is a highly nephrotoxic and widely used anti-cancer agent, used to treat various types of cancers, due to its nephrotoxicity; cisplatin use is limited, which may result from free radical damage, evidence exists that memantine reduces oxidative stress-induced damage. This study was conducted to explore the possible protective role of memantine by pre-treatment with two different therapeutic doses of orally administered memantine 5 and 10 mg kg⁻¹ as an agent to minimize the toxic side effects of cisplatin injected by 4 mg kg⁻¹ with special reference to the kidney. **Materials and Methods:** Seventy-five adult male BALB/c mice were divided into 5 groups: G1: No treatment, G2: Cisplatin treatment, G3: Memantine treatment, G4: Pre-treatment of 5 mg kg⁻¹ memantine combined with cisplatin 4 mg kg⁻¹, G5: Pre-treatment of 10 mg kg⁻¹ memantine combined with cisplatin 4 mg kg⁻¹. Biochemical investigations of kidney function, oxidative stress markers, histopathological examination of kidney tissues and immunohistochemical staining of myeloperoxidase (MPO) mentioned tests were performed by special kits available and following the main instructions of each test provided with kits. **Results:** Mice were treated only with cisplatin showed significant elevation in blood urea nitrogen (BUN), serum creatinine (Scr), alkaline phosphatase (ALP), alanine aminotransferase (ALT) and aspartate aminotransferase (AST); malondialdehyde (MDA); high score expression of myeloperoxidase (MPO), parallel to decline in levels of glutathione (GSH), glutathione transferase (GST), superoxide dismutase (SOD), Catalase (CAT) and glutathione peroxidase (GPX) contents. Moreover, histopathological examination of kidney tissue reflected marked injury; combination treatment with memantine significantly ameliorated these parameters and showed results similar to that of the control group, indicating its renoprotective effect. **Conclusion:** These findings showed that pre-treatment with 5 mg kg⁻¹ memantine offered partial protection while the 10 mg kg⁻¹ of memantine showed complete protection against cisplatin-induced renal cellular damage.

Key words: Memantine, cisplatin, histopathological examination of kidney, kidney tissue, cisplatin injected, renal cellular damage and myeloperoxidase

Received:

Accepted:

Published:

Citation: Nadia Abdulkareem Salih and Banan Khalid AL-Baggou, 2019. Effect of memantine hydrochloride on cisplatin-induced toxicity with special reference to renal alterations in mice. *Int. J. Pharmacol.*, CC: CC-CC.

Corresponding Author: Nadia Abdulkareem Salih, Department of Basic Sciences, College of Veterinary Medicine, University of Sulaimani, Sulaimani, Iraq
Tel: 009647701987123

Copyright: © 2019 Nadia Abdulkareem Salih and Banan Khalid AL-Baggou. This is an open access article distributed under the terms of the creative commons attribution License, which permits unrestricted use, distribution and reproduction in any medium, provided the original author and source are credited.

Competing Interest: The authors have declared that no competing interest exists.

Data Availability: All relevant data are within the paper and its supporting information files.

INTRODUCTION

Cisplatin (CP) is an alkylating, water-soluble class of anti-cancer drugs¹; a widely used cytotoxic agent with a broad spectrum of activity acts against proliferating and resting cells^{1,2}. Its clinical usage is restricted by some undesirable side effects, such as hepatotoxicity, nephrotoxicity, gastrointestinal toxicity, ototoxicity, central and peripheral neuropathy³. Its anti-cancer effect is obtained by several mechanisms, including formation of DNA adducts and generation of reactive oxygen species (ROS), one of the possible mechanisms responsible for cisplatin nephrotoxicity through their oxidative stress injury and suppression of the antioxidant defense system, an imbalance between generation of oxygen-derived radicals and endogenous enzymatic and non-enzymatic antioxidants leading to oxidative stress^{4,7}. Because there is no specific treatment of this main side effect of cisplatin, therefore, many investigations have been designed to assess the potential nephro protective effects of many anti-oxidants and anti-inflammatory agents, for this reason, this study was conducted out to study the possible protective role of memantine.

Memantine is a moderate affinity, uncompetitive N-methyl-D-aspartate (NMDA) receptor antagonist with strong voltage-dependency and fast kinetics. It has been reported that NMDAR presents in kidneys and its activation leads to increased recruitment of mononuclear leukocytes, neutrophils and macrophage, these cells can release glutamate, which can further exacerbate the toxic status, both glutamate and NMDARs play an important role in regulating inflammation in cells and tissues, Activation of NMDA receptors can induce renal alteration, such mechanism of action of memantine as NMDA antagonists could be beneficial to improve renal function^{8,9}.

Oxidative stress has a critical role in the pathophysiology of several kidney diseases and many complications of these diseases are mediated by oxidative stress, oxidative stress-related mediators and inflammation¹⁰.

Myeloperoxidase (MPO) is a heme-containing peroxidase highly expressed in neutrophils when it will be stimulated by various stimulants, MPO increases like other cellular tissue-damaging substances, the MPO-hydrogen peroxide-chloride system leads to lipid adducts that in turn may cause dysfunction of the kidney^{11,12}. The adherence of neutrophils to the glomerular basement membrane and the degradation of the basement membrane by oxidants at sites of attachment pointed toward a direct involvement of MPO damage of cell components^{6,13}.

This study investigated the possible protective effect of memantine on cisplatin-induced nephrotoxicity via main parameters of oxidative status and renal impairment in mice kidneys; Scr, BUN, ALP, ALT and AST were measured, they are indicators of impaired renal function.

MATERIALS AND METHODS

Experimental design: Seventy-five adult male BALB/c mice were used, each of which weighing 25-30 g were housed in plastic cages, 15 mice placed in each group. The study carried out at the histopathology and chemical laboratory of Shorsh hospital in Sulamani region, mice were allocated into 5 groups as follows:

- **Group 1 (-ve control) (G1):** Mice were treated orally with distilled water 1 mL kg⁻¹ for 30 days
- **Group 2 (+ve Control) (G2):** Mice were treated intraperitoneally with 4 mg kg⁻¹ of cisplatin (Bristol-Myers Squibb, New York, NY, USA) for 30 days
- **Group 3 (G3):** Mice were treated orally with 5 mg kg⁻¹ of memantine hydrochloride (Panpharma S. A., France) for 30 days
- **Group 4 (G4):** Mice were pretreated with 5 mg kg⁻¹ memantine hydrochloride and cisplatin 4 mg kg⁻¹ for 30 days
- **Group 5 (G5):** Mice were pretreated with 10 mg kg⁻¹ memantine hydrochloride and cisplatin 4 mg kg⁻¹ for 30 days

Biochemical analysis: Blood samples were collected by heart puncture route, once time after 4 weeks of the treatment period and then centrifuged at 3000 round per minutes for 10 min. Serums were collected in clean test tubes. Renal function parameters (BUN, Scr, ALP, AST and ALT) were done by using standard kits for each test (Vitro Scient Co., Hannover, Germany); all parameters were analyzed by using LISA 200 an automatic chemistry analyzer (Pejohesh-co., France)¹³⁻¹⁵.

Preparation of tissue homogenate: At the end of the experimental period, mice were anesthetized by ketamine and xylazine then euthanized by cervical dislocation; kidneys were quickly excised, placed in chilled phosphate buffer solution (pH 7.4) at 4°C, blotted with filter paper and weighed. One gram of kidney was taken to prepare 10% tissue homogenate using the same buffer solution utilizing Omni tissue homogenizer (10 mm), the homogenate then centrifuged^{16,17} at 5000 rpm for 10 min at 4°C; the homogenate level of lipid

peroxide as MDA, GSH, GST, SOD, CAT and GPX contents were measured by using standard kits for each test (Elabsciences Biotechnology Co., Ltd. China)^{18,19}.

Histopathological and immunohistochemistry study:

Kidneys from mice were fixed in 10% neutral buffered formalin solution NBF (100 mL formalin (40%), 4 g sodium phosphate monobasic, 6.5 g sodium phosphate dibasic and 900 mL D.W) and processed for paraffin embedding. Two sections of 4 µm thickness were taken from each paraffin block, the first section was mounted on an ordinary slide for hematoxylin and eosin and examined by different magnifying powers of light microscopy (Leica, Germany), the second section was mounted on positively charged slide and proceed with the process of immunohistochemistry staining technique following the manufacturer's instructions that were supplied with the kit of myeloperoxidase polyclonal antibody from (Elabsciences Biotechnology Co., Ltd. China). The intensity of immunostaining was independently scored by 2 readers on a scale range from 0-3; Estimated as (0) no staining, (1) Weak staining, (2) Moderate staining and (3) Strong staining²⁰.

Statistical analysis: The data obtained were statistically evaluated using one-way analysis of variance (ANOVA), followed by Duncan test with SPSS software version 21 (SPSS® Inc., USA), the mean differences were considered significant at the level of $p < 0.05$.

RESULTS

In the current study the level of MDA significantly high at ($p < 0.05$) in the cisplatin-treated group when compared with control group, memantine treatment alone and in combination groups in both low and high therapeutic doses significantly dropped the level of MDA when compared with the G2 group. Administration of cisplatin significantly increased renal lipid peroxidation and decreased GSH, SOD, GPX, CAT and GST level as enzymatic and non-enzymatic anti-oxidant parameters when compared to the G1 in the present study, while in G3 and combination treatments G4 and G5 the levels of MDA, GSH, SOD, GPX, CAT and GST, showed in significant changes in comparison with G1 (Table 1).

Those mice treated with cisplatin (G2) showed a significant ($p < 0.05$) elevation in the levels of BUN, Scr, ALP, ALT and AST, when compared with their levels in G1 (Table 2), while in G3 the serum level of ALP, AST, ALT, BUN and Scr were significantly ($p < 0.05$) decreased in comparison with those of G2 group.

Mice treated with combination treatment of both therapeutic doses of memantine with cisplatin 4 mg kg⁻¹ (G4 and G5) showed a low level of ALP, AST, ALT, BUN and Scr which stay within normal range (Table 2), memantine at low therapeutic dose (G4) showed partial protection from nephrotoxic side effect of cisplatin while the higher therapeutic dose of memantine in the combination

Table 1: Effect of cisplatin and memantine on enzymatic and non-enzymatic antioxidants parameters

Groups parameters	Group 1 Control group	Group 2 Cisplatin (4 mg kg ⁻¹)	Group 3 Memantine (5 mg kg ⁻¹)	Group 4 Cisplatin (4 mg kg ⁻¹) and memantine (5 mg kg ⁻¹)	Group 5 Cisplatin (4 mg kg ⁻¹) and memantine (10 mg kg ⁻¹)
MDA (nmol g ⁻¹ tissue)	0.90 ± 0.71 ^a	5.40 ± 0.89 ^b	1.10 ± 0.29 ^a	1.30 ± 0.59 ^a	1.40 ± 0.11 ^a
GSH (µmol g ⁻¹ tissue)	18.40 ± 0.25 ^a	11.40 ± 0.79 ^c	17.90 ± 0.10 ^a	14.40 ± 0.10 ^b	18.90 ± 0.67 ^a
GST (U g ⁻¹ tissue)	70.40 ± 0.43 ^a	44.11 ± 0.21 ^b	69.60 ± 0.14 ^a	66.31 ± 0.71 ^a	69.10 ± 0.1 ^a
SOD (nmol g ⁻¹ tissue)	2.90 ± 0.71 ^a	0.94 ± 0.89 ^b	2.41 ± 0.29 ^a	2.30 ± 0.59 ^a	2.40 ± 0.11 ^a
Gpx glutathione peroxidase (U g ⁻¹ tissue)	2.19 ± 0.71 ^a	0.64 ± 0.89 ^c	2.01 ± 0.29 ^a	1.74 ± 0.10 ^b	1.98 ± 0.37 ^a
Catalase (k g ⁻¹ protein)	8.50 ± 0.25 ^a	4.40 ± 0.79 ^b	8.40 ± 0.3 ^a	6.31 ± 0.71 ^b	7.80 ± 0.77 ^a

Value expressed as Mean ± SE, different letter mean significant differences at $p < 0.05$

Table 2: Effect of cisplatin and memantine on renal parameters

Groups	Treatments	Serum creatinine (mg dL ⁻¹)	ALP (IU L ⁻¹)	ALT (IU L ⁻¹)	BUN (mg dL ⁻¹)	AST (IU L ⁻¹)
1	Control	0.53 ± 0.01	65.4 ± 0.43 ^a	37.73 ± 0.91 ^a	30.1 ± 0.41 ^a	57.91 ± 0.41 ^a
2	Cisplatin (4 mg kg ⁻¹)	3.41 ± 0.03 ^c	144.11 ± 0.21 ^c	63.19 ± 0.78 ^b	66.4 ± 0.21 ^b	126.41 ± 0.21 ^b
3	Memantine (5 mg kg ⁻¹)	0.68 ± 0.41 ^a	65.5 ± 0.14 ^a	38.8 ± 0.64 ^a	34.1 ± 0.31 ^a	58.91 ± 0.31 ^a
4	Cisplatin and memantine (5 mg kg ⁻¹)	1.99 ± 0.1 ^b	75.31 ± 0.71 ^b	39.1 ± 0.81 ^a	33.1 ± 0.19 ^a	59.91 ± 0.19 ^a
G5	Cisplatin and memantine (10 mg kg ⁻¹)	0.49 ± 0.1 ^a	66.1 ± 0.1 ^a	38.9 ± 0.91 ^a	30.1 ± 0.1 ^a	59.71 ± 0.1 ^a

Value expressed as Mean ± SE, different letter mean significant differences at $p < 0.05$

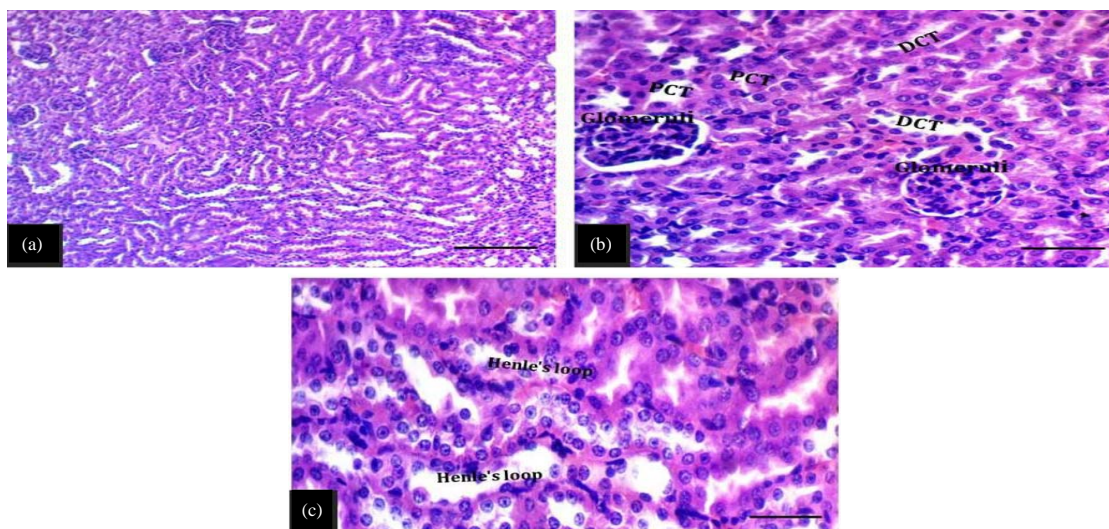


Fig. 1(a-c): Light micrograph of kidney sections in the control group, (a) Normal histological features of renal parenchyma, (b) Normal structures of glomeruli with distal (DCT) and proximal (PCT) convoluted tubules and (c) Henle's loops showed normal histological appearance (H and E stain, scale bar 100 μ m, scale bar 20 μ m)

treatment group (G5) showed complete protection from the adverse effect of cisplatin on renal parameters.

Histopathological result of the control renal section showed normal histological structure, normal histological features of renal parenchyma and normal structures of glomeruli with distal and proximal convoluted tubules (Fig. 1a-c), while in G2 the kidneys showed severe inflammation and pronounced changes in histological section of the renal corpuscle and renal parenchyma with vascular congestion, marked degeneration of collecting tubules (Fig. 2a-g), sections from G3 showed mild to moderate changes in renal parenchyma, mild-moderate hydropic degeneration of renal tubules with slightly blurring of brush borders (Fig. 3a-c), G4 showed moderate hydropic degeneration of renal tubules, blurring of brush borders, vascular congestion with interstitial hemorrhages and dilation of Bowman's capsule (Fig. 4a-c). G5 showed mild cell swelling, mild swelling of renal tubules that forming star-shaped appearance with a slight blurring of brush borders (Fig. 5a-d). The results of immuno histochemical staining of renal tissue by MPO antibody confirmed the protective role of memantine. G2 had the higher score of an intensity of immuno staining while G3 and G5 showed the lower score in comparison with G1 (Fig. 6-10).

DISCUSSION

This study investigated the possible protective effect of memantine on cisplatin-induced nephrotoxicity via main

parameters of oxidative status and renal impairment in mice kidneys; Scr, BUN, ALP, ALT and AST were measured, they are an indicator of impaired renal function and one of the dependable tests. Serum creatinine and blood urea nitrogen are waste products excreted by the kidney were in accordance with nephrotoxic effect. Cisplatin-treated group showed a significant increase in Scr, BUN, ALP, ALT and AST levels in comparison with the control group while other treatment groups that contain memantine either alone or in combination groups showed no significant changes^{21,22}. The results of these tests can assume that memantine has a complete reno protective effect at the higher therapeutic dose in comparison with the low therapeutic dose which gives partial protection.

Oxidative stress has a critical role in the pathophysiology of several kidney diseases and many complications of these diseases are mediated by oxidative stress, oxidative stress-related mediators and inflammation¹⁰. Free radical scavenging enzymes such as GST, GPX and GR protect the biological systems from oxidative stress. An imbalance between the generation of oxygen-derived radicals with endogenous enzymatic and non-enzymatic antioxidants leading to oxidative damage of the cell components^{6,13}. The kidney is an organ highly vulnerable to damage caused by ROS, likely due to the abundance of long-chain polyunsaturated fatty acids on the composition of renal lipids. Cisplatin is nephrotoxic agents; their nephrotoxicity is mainly attributed to the induction of ROS and depletion of anti-oxidant enzyme activities in the kidney^{10,23}.

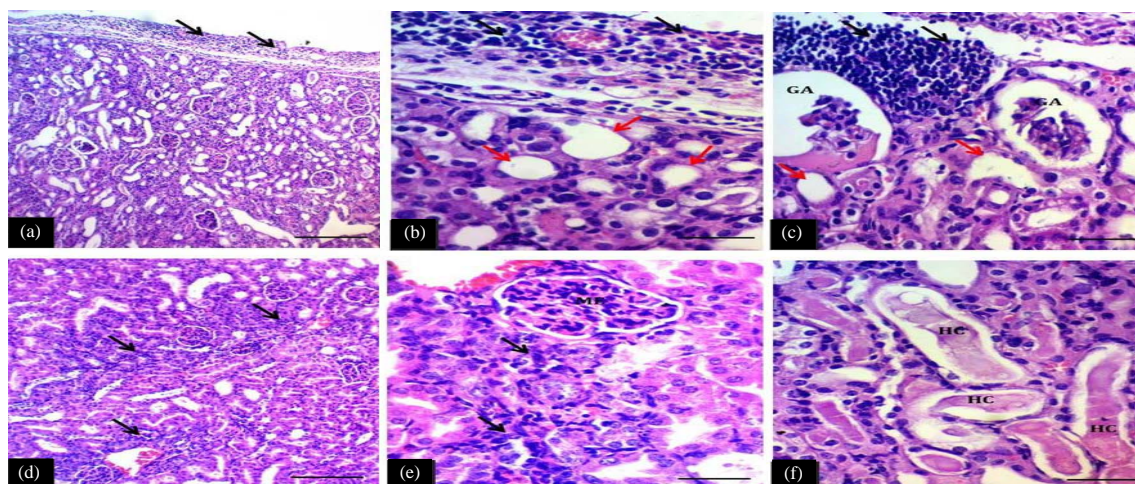


Fig. 2(a-f): Light micrograph of the kidney sections in the cisplatin group showed severe histopathological lesions, (a and b) Marked inflammation (black arrows) in capsule+subcapsular regions and extend into the renal parenchyma with marked necrosis of proximal and distal convoluted tubules (red arrows) with completely brush borders destruction, hyaline cast in renal tubules, (c) Infiltration of mononuclear inflammatory cells within interstitial tissue with completely atrophied of glomeruli (GA) (H and E stain, scale bar 100 μ m, scale bar 20 μ m), (d and e) Diffuse infiltration of inflammatory cells in interstitial tissue with mildly increasing glomerular cellularity in the form of mesangial expansion (ME), vascular congestion, marked degeneration of collecting tubules and (f) Severe degeneration and necrosis of loops of Henle with hyaline cast in their lumen as marked by HC (H and E stain, scale bar 100 μ m, scale bar 20 μ m)

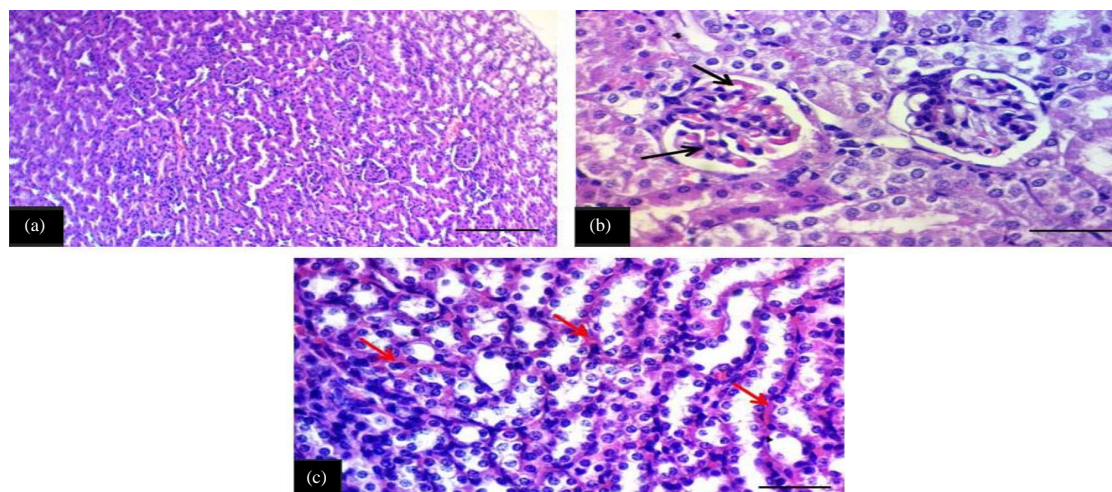


Fig. 3(a-c): Kidney sections showed mild-moderate changes in 5 mg kg⁻¹ of memantine treatment group (a and b) Mild-moderate hydropic degeneration of renal tubules with slightly blurring of brush borders, mild vascular congestion with interstitial hemorrhages (red arrows), the glomeruli showed mild dilation with congestion of mesangial capillary (black arrows) and (c) Mild- moderate degeneration of Henle loops with mild interstitial hemorrhages (red arrows) (H and E stain, scale bar 100 μ m, scale bar 20 μ m)

The histopathological and immunohistochemical expressions are dependable tests for the nephrotoxic effect of cisplatin, which encourages the formation of reactive oxygen

species (ROS) and lipid peroxidation of the membrane lipid. Histopathological examination of slides from the kidney section revealed no morphological adverse effect at the

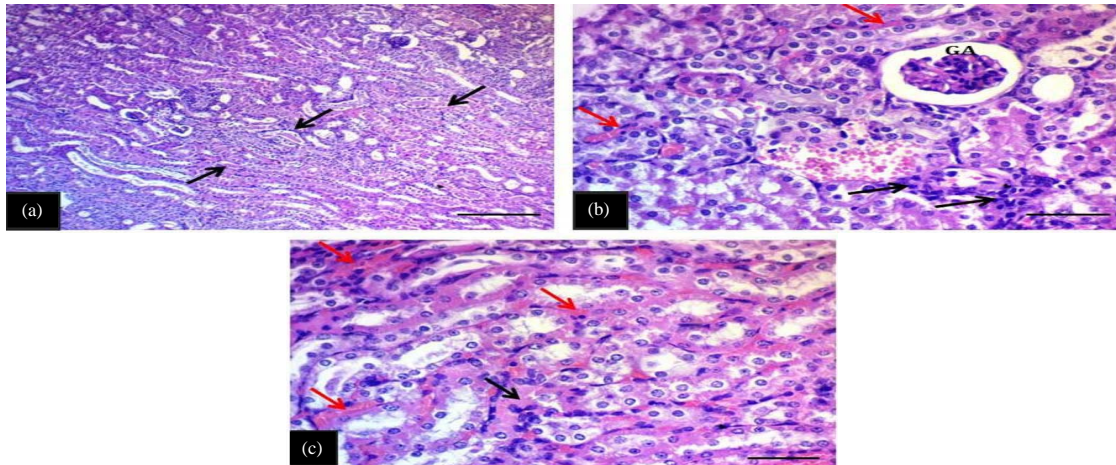


Fig. 4(a-c): Light micrograph of the kidney sections showed moderate changes in cisplatin with 5 mg kg⁻¹ memantine group, (a and b) Moderate hydropic degeneration of renal tubules with a blurring of brush borders, vascular congestion with interstitial hemorrhages, the glomeruli showed mild atrophy (GA) with dilation of Bowman's capsule and focal interstitial infiltration of neutrophils (black arrows) and (c) Moderate hydropic degeneration of Henle loops with interstitial hemorrhages (red arrows) and presence of hyaline cast in their lumen as indicated by black arrows (H and E stain, scale bar 100 μ m, scale bar 20 μ m)

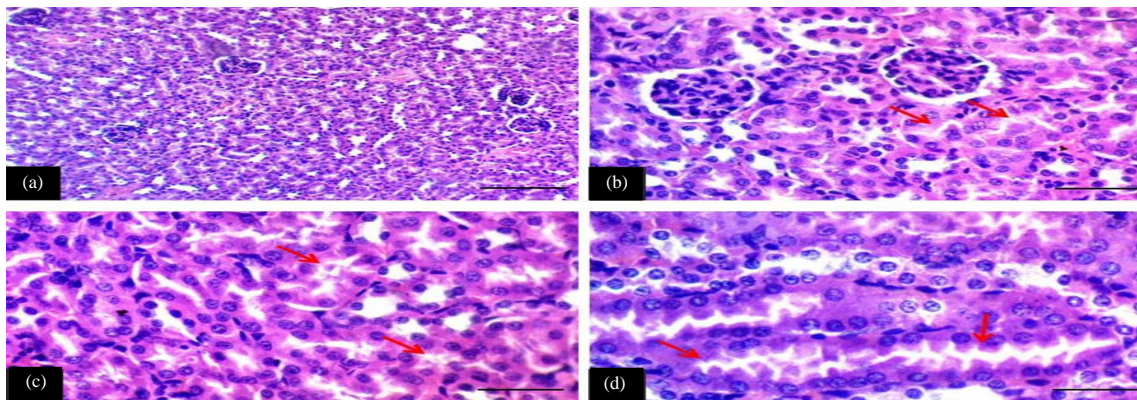


Fig. 5(a-d): Kidney sections showed mild cell swelling in 10 mg kg⁻¹ of memantine and cisplatin-treated group (a-c) Mild swelling of renal tubules that forming star shaped appearance with slight blurring of brush borders (red arrows), the glomeruli showed mild dilation of Bowman's capsule and (d) Mild swelling of Henle loops which appear as star-like structures (red arrows) (H and E stain, scale bar 100 μ m, scale bar 20 μ m)

microscopic level and reflected the protective role of memantine in preventing the appearance of renal abnormal changes²⁴⁻²⁷.

In this study, cisplatin has been reported to increase the level of MDA and MPO were correlated with low levels of GSH. Cisplatin has a negative impact on the antioxidant defense mechanisms by reducing the intracellular concentration of GSH, superoxide dismutase (SOD), catalase (CAT) and glutathione peroxidase (GPx) in kidney tissue compared to the normal group^{28,29}.

Memantine represents a new class of therapeutic agent with efficacy for the symptomatic treatment of moderately severe to severe Alzheimer's disease (AD) with moderate affinity, uncompetitive N-methyl-D-aspartate (NMDA) receptor antagonist with strong voltage-dependency and fast kinetics^{30,31}.

Memantine at lower therapeutic dose 5 mg kg⁻¹ offered some protection in renal parameters induced by cisplatin, while treatment with a high therapeutic dose of memantine 10 mg kg⁻¹ obviously reduced the cisplatin-induced renal

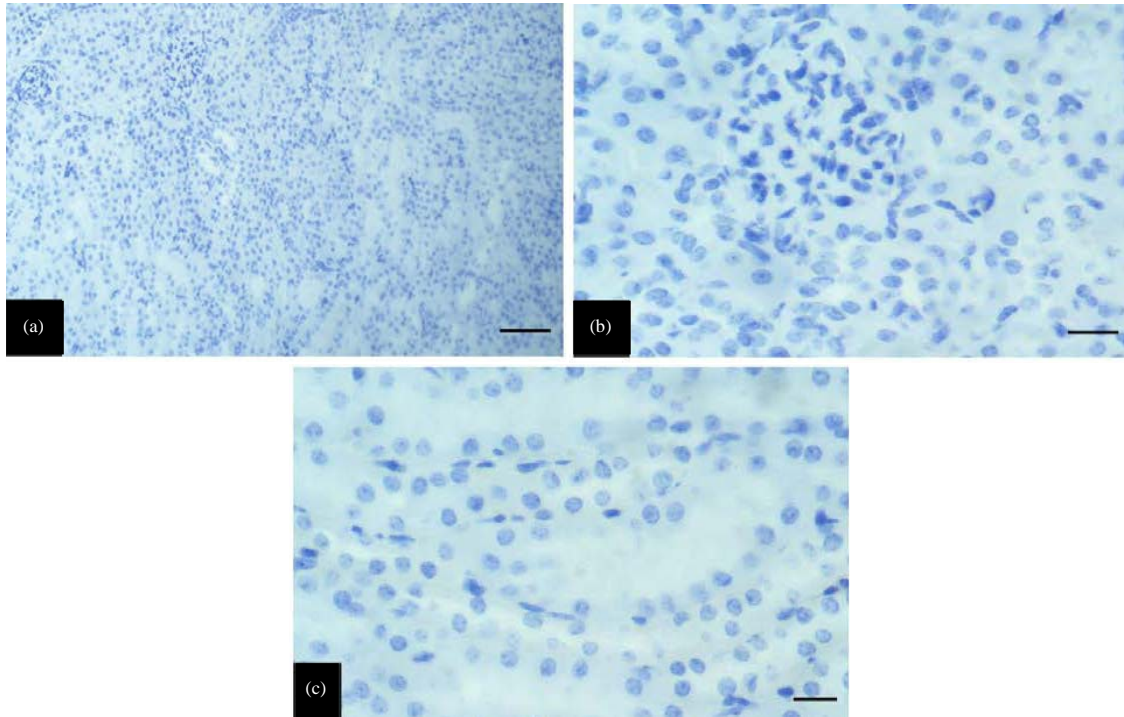


Fig. 6(a-c): Myeloperoxidase expression in kidney section in mice of the control group, (a-c) Score 0, no positive cells throughout renal parenchyma (scale bar 100 μm , scale bar 20 μm)

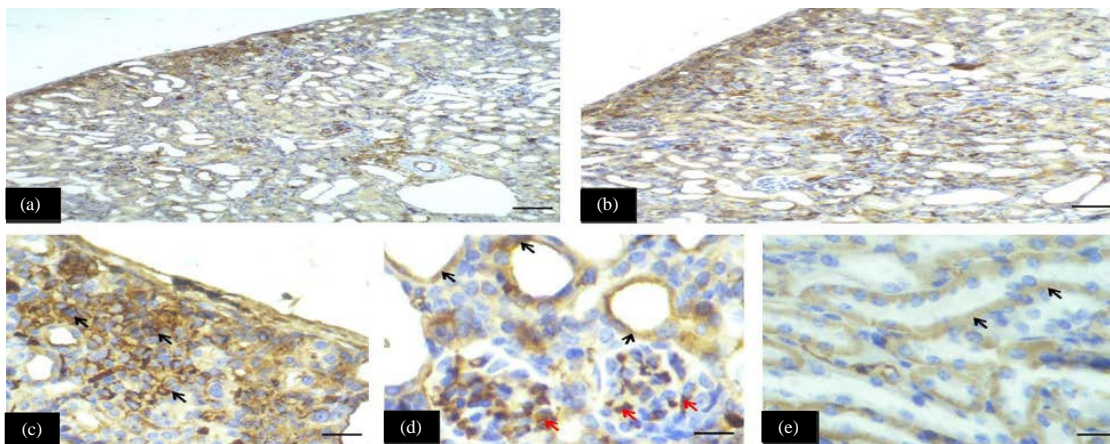


Fig. 7(a-e): Myeloperoxidase expression in kidney section in mice of cisplatin group, (a-c) Intense or strong cytoplasmic staining (score 3), in section c the arrows indicated myeloperoxidase expression in neutrophils, (d) Black arrows showed expression in proximal convoluted tubules and the red arrows showed in mesangial cell expression of myeloperoxidase and (e) Arrows showed expression in Henle loops (scale bar 100 μm , scale bar 20 μm)

oxidative stress, restored enzymatic and non-enzymatic anti-oxidants activities, thus forming the molecular basis for the protective mechanism of memantine against cisplatin-induced nephrotoxicity.

Previous studies showed a significant decrease in these enzymatic activities in rats treated with cisplatin which may be related to the impairment of GSH metabolism and increased oxidative damage which is in agreement with the results of

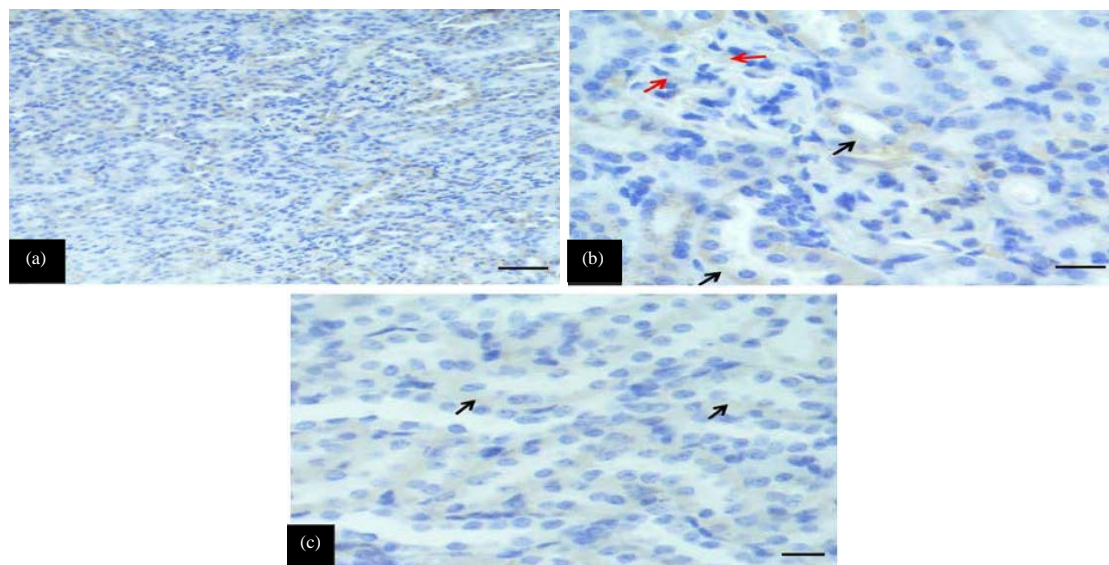


Fig. 8(a-c): Myeloperoxidase expression in kidney section in mice of memantine treated group, (a) Weak-local cytoplasmic staining (score 1), (b) Black arrows showed expression in proximal convoluted tubules and the red arrows showed mesangial cell expression of myeloperoxidase and (c) Arrows showed expression in Henle loops (scale bar 100 μm , scale bar 20 μm)

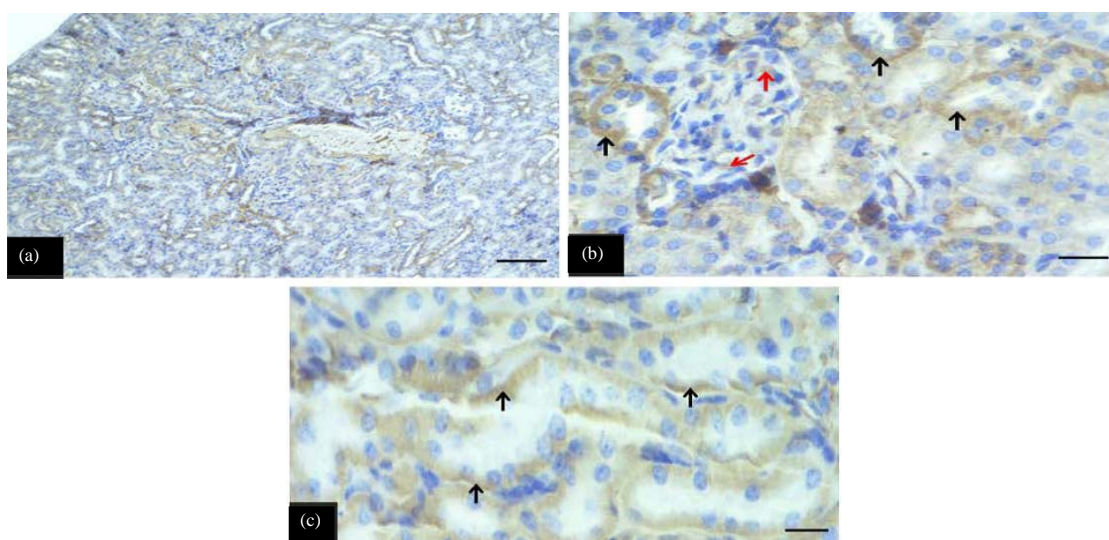


Fig. 9(a-c): Myeloperoxidase expression in kidney section of cisplatin + 5 mg kg^{-1} memantine treated group, (a) Moderate cytoplasmic staining (score 2), (b) Black arrows showed myeloperoxidase expression in proximal convoluted tubules and the red arrows showed mesangial cell expression of myeloperoxidase and (c) Arrows showed myeloperoxidase expression in Henle loops (scale bar 100 μm , scale bar 20 μm)

the current study³¹. The nephrotoxicity of cisplatin is the result of the binding of cisplatin to GSH and the subsequent metabolism of the cisplatin-GSH complex (a platinum-GSH conjugate) via a γ -glutamyl transpeptidase (GGT)-dependent pathway in the proximal tubules²⁹.

Myeloperoxidase (MPO) is a heme-containing peroxidase highly expressed in neutrophils. The ability of MPO to generate hypochlorous acid from hydrogen peroxide in the presence of chloride ions is a unique activity for this enzyme, when neutrophils are stimulated by various stimulants, MPO

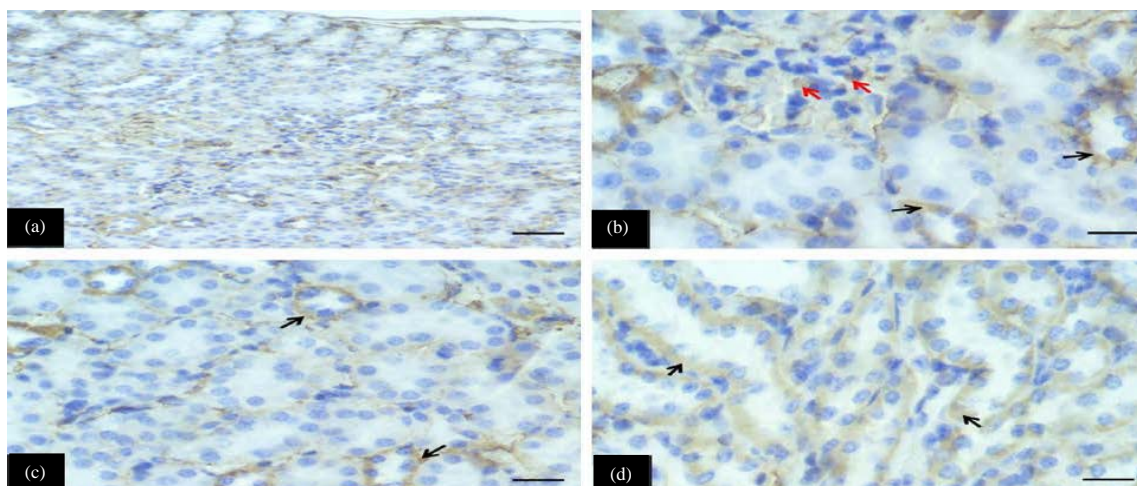


Fig. 10(a-d): Myeloperoxidase expression in kidney section in mice of cisplatin+10 mg kg⁻¹ b.wt., memantine treated group, (a) Weak-diffuse cytoplasmic staining (score 1), (b and c) Black arrows showed expression in proximal convoluted tubules and the red arrows showed mesangial cell expression of myeloperoxidase and (d) Arrows showed expression in Henle loops (scale bar 100 μ m, scale bar 20 μ m)

increases like other cellular tissue-damaging substances, the MPO-hydrogen peroxide-chloride system leads to lipid adducts that in turn may cause dysfunction of the kidney^{11,12}. The adherence of neutrophils to the glomerular basement membrane and the degradation of the basement membrane by oxidants at sites of attachment pointed toward a direct involvement of MPO^{31,32}.

Memantine is a moderate affinity, uncompetitive N-methyl-D-aspartate (NMDA) receptor antagonist with strong voltage-dependency and fast kinetics. It has been reported that NMDAR presents in kidneys and its activation leads to increased recruitment of mononuclear leukocytes, neutrophils and macrophage, these cells can release glutamate, which can further exacerbate the toxic status, both glutamate and NMDARs play an important role in regulating inflammation in cells and tissues. Activation of NMDA receptors can induce renal alteration, such mechanism of action of memantine as NMDA antagonists could be beneficial to improve renal function^{8,9,33,34}.

When too much glutamate is present, it allowing too much calcium to move into the cells causing damage and generation of free radicals. Memantine sticks to the same receptors, blocking glutamate and this prevents too much calcium from moving into the cells. NMDA receptors in renal cortex mediate a tonic vasodilator response and it is possible that inhibition of these receptors produces hemodynamic effects that preserve renal function. As mentioned previously,

sustained application of NMDA to cultured podocytes induces Ca²⁺ influx and oxidative stress^{13,35-37}.

CONCLUSION

This study explored the potential role of memantine as a protective agent against main side effects of cisplatin which is nephrotoxicity that can be beneficial for those patients suffering from cancer; memantine at higher therapeutic dose 10 mg kg⁻¹ is more effective than the lower therapeutic dose 5 mg kg⁻¹ for reserving intracellular levels of biological pathways and supportively enhance all the main renal parameters (BUN, Scr, ALP, AST, ALT) and improve the enzymatic and non-enzymatic antioxidants levels which is confirmed by the results of histopathological and immunohistochemical study.

ACKNOWLEDGMENT

We would like to express our profound sense of gratitude to all the doctors and technicians in the Histopathology Department of Shorsh Hospital for their cooperation and assistance, especially Dr. Michael Hughson, Dr. Hemin and Mr. Zahir for their helpful assistance and generous support during my research study. This research received no specific grant from any funding agency in the public, commercial or not-for-profit sectors and the

results described in this paper are a part of an in-progress PhD thesis of the corresponding author.

SIGNIFICANCE STATEMENT

This study discovered the potential protective role of memantine as a newly tried agent against main side effect of cisplatin which is nephrotoxicity, that can be beneficial for those patients suffering from cancer; a comparison between 2 different therapeutic doses was examined and main renal parameters were selected and confirmed by histopathological and immunohistochemistry technique. This study will help the researcher to uncover the critical areas of newly tried agent that never been used before with anticancer drugs, for the first time this study focused on and explored a new indication of memantine hydrochloride. Thus by this study a new theory on nephroprotective agents may arrive, in past all works on cisplatin focused on use of antioxidants agents as a protective agent for decreasing the nephrotoxicity effect of cisplatin, but this work idea is new and different from other studies on cisplatin, by attracting attention to new probable clinical use of highly effective and widely used drugs like memantine by depending on its mechanism of action as NMDA and glutamate antagonist.

REFERENCES

1. Ciarimboli, G., T. Ludwig, D. Lang, H. Pavenstadt and H. Koepsell *et al.*, 2005. Cisplatin nephrotoxicity is critically mediated via the human organic cation transporter 2. *Am. J. Pathol.*, 167: 1477-1484.
2. Circu, M.L. and T.Y. Aw, 2010. Reactive oxygen species, cellular redox systems and apoptosis. *Free Radic. Biol. Med.*, 48: 749-762.
3. Fearon, K.C.H., D.J. Glass and D.C. Guttridge, 2012. Cancer cachexia: Mediators, signaling and metabolic pathways. *Cell Metab.*, 16: 153-166.
4. Guan, S., Q. Liu, F. Han, W. Gu and L. Song *et al.*, 2017. Ginsenoside Rg1 ameliorates cigarette smoke-induced airway fibrosis by suppressing the TGF- β 1/Smad pathway *in vivo* and *in vitro*. *BioMed. Res. Int.*, Vol. 2017. 10.1155/2017/6510198.
5. Hsu, C.Y., Y.P. Chan and J. Chang, 2007. Antioxidant activity of extract from *Polygonum cuspidatum*. *Biol. Res.*, 40: 13-21.
6. Al-Malki, A.L. and A.A.R. Sayed, 2014. Thymoquinone attenuates cisplatin-induced hepatotoxicity via nuclear factor kappa- β . *BMC Complement. Altern. Med.*, Vol. 14. 10.1186/1472-6882-14-282.
7. Chakravarthi, S., C.E. Jessop and N.J. Buleid, 2006. The role of glutathione in disulphide bond formation and endoplasmic reticulum generated oxidative stress. *EMBO Rep.*, 7: 271-275.
8. Bardgett, M.E., R. Boeckman, D. Krochmal, H. Fernando, R. Ahrens and J.G. Csernansky, 2003. NMDA receptor blockade and hippocampal neuronal loss impair fear conditioning and position habit reversal in C57Bl/6 mice. *Brain Res. Bull.*, 60: 131-142.
9. Huang, Q., R.T. Dunn II, S. Jayadev, O. DiSorbo and F.D. Pack *et al.*, 2001. Assessment of cisplatin-induced nephrotoxicity by microarray technology. *Toxicol. Sci.*, 63: 196-207.
10. Ali, B.H. and M.S. Al Moundhri, 2006. Agents ameliorating or augmenting the nephrotoxicity of cisplatin and other platinum compounds: A review of some recent research. *Food Chem. Toxicol.*, 44: 1173-1183.
11. Kumar, D., 2011. Anti-inflammatory, analgesic and antioxidant activities of methanolic wood extract of *Pterocarpus santalinus* L. *J. Pharmacol. Pharmacother.*, 2: 200-202.
12. Dabas, A., N.S. Nagpure, R. Kumar, B. Kushwaha, P. Kumar and W.S. Lakra, 2012. Assessment of tissue-specific effect of cadmium on antioxidant defense system and lipid peroxidation in freshwater murrel, *Channa punctatus*. *Fish Physiol. Biochem.*, 38: 469-482.
13. Amin, A. and A.A. Hamza, 2006. Effects of Roselle and Ginger on cisplatin-induced reproductive toxicity in rats. *Asian J. Androl.*, 8: 607-612.
14. Kumar, S. and S. Gupta, 2011. Thymosin beta 4 prevents oxidative stress by targeting antioxidant and anti-apoptotic genes in cardiac fibroblasts. *PLoS One*, Vol. 6, No. 10. 10.1371/journal.pone.0026912.
15. Barbosa, L.H.F., H.V.L. Ramos, L.R. Neves, N.G. de Biase, C. Oshima, J.E. de Sa Pedroso and P.A. de Lima Pontes, 2008. Detection of hyaluronic acid receptor in human vocal folds by immunohistochemistry. *Rev. Bras. Otorrinolaringol.*, 74: 201-206.
16. Kumar, R.R., P.H. Rao, V.V. Subramanian and V. Sivasubramanian, 2014. Enzymatic and non-enzymatic antioxidant potentials of *Chlorella vulgaris* grown in effluent of a confectionery industry. *J. Food Sci. Technol.*, 51: 322-328.
17. Luqmans, S., S. Srivastava, R. Kumar, A.K. Maurya and D. Chanda, 2012. Experimental assessment of *Moringa oleifera* leaf and fruit for its antistress, antioxidant and scavenging potential using *in vitro* and *in vivo* assays. *Evidence-Based Complement. Altern. Med.* 10.1155/2012/519084.
18. Kumar, R.S., K. Asokkumar and N.V. Murthy, 2011. Hepatoprotective effects and antioxidant role of *Scutia myrtina* on paracetamol induced hepatotoxicity in rats. *J. Complement. Integr. Med.*, Vol. 8, No. 1. 10.2202/1553-3840.1461.
19. Kumar, D., R.K. Pandey, D. Agrawal and D. Agrawal, 2011. An estimation and evaluation of total antioxidant capacity of saliva in children with severe early childhood caries. *Int. J. Paediatric Dent.*, 21: 459-464.

20. Torrelo, A., I. Colmenero, L. Requena, A.S. Paller and Y. Ramot *et al.*, 2015. The histological and immunohistochemical features of the skin lesions in CANDLE syndrome. *Am. J. Dermatopathol.*, 37: 517-522.
21. Kumar, P., R.K. Kale and N.Z. Baquer, 2011. Estradiol modulates membrane-linked ATPases, antioxidant enzymes, membrane fluidity, lipid peroxidation and lipofuscin in aged rat liver. *J. Aging Res.*, Vol. 2011. 10.4061/2011/580245.
22. Abdelmeguid, N.E., H.N. Chmisse and N.S. Abou Zeinab, 2010. Silymarin ameliorates cisplatin-induced hepatotoxicity in rats: Histopathological and ultrastructural studies. *Pak. J. Biol. Sci.*, 13: 463-479.
23. Al-Badrany, Y.M.A. and F.K. Mohammad, 2007. Effects of acute and repeated oral exposure to the organophosphate insecticide chlorpyrifos on open-field activity in chicks. *Toxicol. Lett.*, 174: 110-116.
24. Punithavathi, V.R., P.S. Prince, R. Kumar and J. Selvakumari, 2011. Antihyperglycaemic, antilipid peroxidative and antioxidant effects of gallic acid on streptozotocin induced diabetic Wistar rats. *Eur. J. Pharmacol.*, 650: 465-471.
25. Ali, B.H., M. Al-Moundhri, M.T. Eldin, A. Nemmar, S. Al-Siyabi and K. Annamalai, 2008. Amelioration of cisplatin-induced nephrotoxicity in rats by tetramethylpyrazine, a major constituent of the Chinese herb *Ligusticum wallichii*. *Exp. Biol. Med.*, 233: 891-896.
26. Balakrishna, A., M.V.N. Reddy, P.V. Rao, M.A. Kumar and B.S. Kumar *et al.*, 2011. Synthesis and bio-activity evaluation of tetraphenyl(phenylamino) methylene bisphosphonates as antioxidant agents and as potent inhibitors of osteoclasts *in vitro*. *Eur. J. Med. Chem.*, 46: 1798-1802.
27. Flores, E.M., S.E. Cappelari, P. Pereira and J.N. Picada, 2011. Effects of memantine, a non competitive N methyl d aspartate receptor antagonist, on genomic stability. *Basic Clin. Pharmacol. Toxicol.*, 109: 413-417.
28. Blumenthal, R.D., W. Lew, A. Reising, D. Soyne, L. Osorio, Z. Ying and D.M. Goldenberg, 2000. Anti-oxidant vitamins reduce normal tissue toxicity induced by radio-immunotherapy. *Int. J. Cancer*, 86: 276-280.
29. Bhandari, S., M.P. Agarwal, S. Dwivedi and B.D. Banerjee, 2008. Monitoring oxidative stress across worsening Child Pugh class of cirrhosis. *Indian J. Med. Sci.*, 62: 444-451.
30. Sharma, U.S. and A. Kumar, 2011. *In vitro* antioxidant activity of *Rubus ellipticus* fruits. *J. Adv. Pharm. Technol. Res.*, 2: 47-50.
31. Boulikas, T. and M. Vougiouka, 2003. Cisplatin and platinum drugs at the molecular level. (Review). *Oncol. Rep.*, 10: 1663-1682.
32. Walia, H., S. Kumar and S. Arora, 2011. Comparative analysis of antioxidant and phenolic content of chloroform extract/fraction of *Terminalia chebula*. *J. Basic Clin. Pharm.*, 2: 115-124.
33. Alias, A., M. Al-Zubaidy, Y. Mousa and F. Mohammad, 2011. Plasma and whole brain cholinesterase activities in three wild bird species in Mosul, IRAQ: *In vitro* inhibition by insecticides. *Interdiscip. Toxicol.*, 4: 144-148.
34. Huang, T.G., S.M. Ip, W.S.B. Yeung and H.Y.S. Ngan, 2001. Mitomycin C and cisplatin enhanced the antitumor activity of p53-expressing adenovirus in cervical cancer cells. *Cancer Invest.*, 19: 360-368.
35. Dimri, U., S.K. Singh, M.C. Sharma, S.K. Behera, D. Kumar and P. Tiwari, 2012. Oxidant/Antioxidant balance, minerals status and apoptosis in peripheral blood of dogs naturally infected with *Dirofilaria immitis*. *Res. Vet. Sci.*, 93: 296-299.
36. Bennett, W.M., L. Pastore and D.C. Houghton, 1980. Fatal pulmonary bleomycin toxicity in cisplatin-induced acute renal failure. *Cancer Treat. Rep.*, 64: 921-924.
37. Tiwari, A.K., K.S. Reddy, J. Radhakrishnan, D.A. Kumar, A. Zehra, S.B. Agawane and K. Madhusudana, 2011. Influence of antioxidant rich fresh vegetable juices on starch induced postprandial hyperglycemia in rats. *Food Funct.*, 2: 521-528.