



Research Article

Protective and Antioxidant Role of Selenium Nanoparticles and Vitamin C Against Acrylamide Induced Hepatotoxicity in Male Mice

^{1,3}Reham Z. Hamza, ^{1,2}Shaden E. Al-Motaani and ^{1,2}Nusrat Malik

¹Department of Biology, Faculty of Science, Taif University, 888 Taif, Saudi Arabia

²General Department of Education, Taif, Saudi Arabia

³Department of Zoology, Faculty of Science, Zagazig University, 44519 Zagazig, Egypt

Abstract

Background and Objectives: Selenium (SeNPs) and vitamin C have a lot of significant protective antioxidant effects. Acrylamide (ACR) is found in starchy foods and breads that has been heated over long periods over 120°C. The current study aimed to evaluate the ameliorative roles of SeNPs and/or vitamin C on acrylamide (ACR)-induced hepatotoxicity in male mice. **Materials and Methods:** Total 42 male mice were divided randomly to seven groups: Control, ACR, SeNPs, vitamin C, ACR plus SeNPs, ACR plus vitamin C, ACR plus SeNPs and vitamin C. Hepatic enzymes levels (Alanine and aspartate aminotransferases) and tumor necrosis factor-alpha as well as the antioxidant markers: Superoxide dismutase, glutathione-S-transferase, catalase and glutathione reductase were evaluated. Histological, transmission electron microscopic and comet assay alterations in the hepatic cells as markers of hepatic damage after the ACR administration alone or combined with SeNPs and/or vitamin C were done. The ACR genotoxic effects were also assessed and the ameliorative roles of SeNPs and/or vitamin C on the liver cells were recorded as well. **Results:** Results clarified that vitamin C and SeNPs administration declined ACR-elicited increment in aminotransferase levels and declined oxidative stress significantly. Additionally, vitamin C combined with SeNPs had a potent synergistic effects and increased the antioxidant enzymes significantly and declined lipid peroxidation markers as compared with ACR-group. **Conclusion:** It is apparent that both vitamin C and SeNPs prohibit the liver damage and enhance the redox state in male mice.

Key words: Nanoparticles, selenium, vitamin C, oxidative stress, acrylamide, hepatotoxicity

Received: March 07, 2019

Accepted: May 02, 2019

Published:

Citation: Reham Z. Hamza, Shaden E. Al-Motaani and Nusrat Malik, 2019. Protective and antioxidant role of selenium nanoparticles and vitamin C against acrylamide induced hepatotoxicity in male mice. *Int. J. Pharmacol.*, CC: CC-CC.

Corresponding Author: Reham Z. Hamza, Department of Biology, Faculty of Science, Taif University, 888 Taif, Saudi Arabia
Department of Zoology, Faculty of Science, Zagazig University, 44519 Zagazig, Egypt Tel: 00201154200862/00966531355470

Copyright: © 2019 Reham Z. Hamza *et al.* This is an open access article distributed under the terms of the creative commons attribution License, which permits unrestricted use, distribution and reproduction in any medium, provided the original author and source are credited.

Competing Interest: The authors have declared that no competing interest exists.

Data Availability: All relevant data are within the paper and its supporting information files.

INTRODUCTION

Acrylamide is a white compound which is water-soluble in a crystalline form. The main implementation of acrylamide is in the plastics manufacturing and in the waterpipes welding. Acrylamide is also formed in starchy foods as fried potatoes, cookies and bread heated¹ above 120°C. Generally, the acrylamide is formed during cooking with very high temperatures and this is due to the reaction between the amino acid asparagine and a carbonyl-containing source². Acrylamide (ACR) is used widely as a material in the industrial production as synthesis of the polyacrylamide, dye synthesis and cosmetic manufacturing³. This compound is formed in carbohydrate-rich foods when the temperature is higher⁴ than 120°C. Humans may be exposed to ACR in diet or workplaces. The ACR is an intermediate compound for the polyacrylamide synthesis. The ACR used as one of additives in many kinds of industrial products and used to construct reservoirs for water⁵. Moreover, it is used as an additive in the industrial treatment, printing, cosmetics and textile industry⁶.

The functionalized nanoparticles have gained high attention recently, they have unique properties and they are considered, approved materials in medical applications⁷. The nanomedicine concept has evolved as a new rising star in the therapeutics area as this novel concept offers a lot of unique advantages. Nanomedicine based on many approaches that is associated with different forms of drugs. A widely accepted advantage of nanomedicine is the enhanced safety. The use of nanoparticles Se has been greatly confirmed globally⁸. Selenium (Se) is a vital micronutrient required for the selenoproteins biosynthesis⁹. Selenium (Se) is an essential nutrient and an essential component of glutathione peroxidase as well¹⁰. Deficiency of Se is the main reason for the degenerative diseases and muscular dystrophy that are age-related in humans. The other advantages of Se are the enhancement of the immune responses and the declining of cancer mortality. Selenium nanoparticles (SeNPs) have potent and high biological properties together with lower toxicity and this makes it as a good candidate and alternative of other forms of selenium in the nutritional supplements¹¹.

Vitamin C is a potent antioxidant and act by scavenging the free radicals and compensates the decrease in glutathione levels¹². It is a potent antioxidant that protects cell membrane and cytosol substances¹³. Vitamin C is considered as a potent free radical scavengers. The ameliorative effect of vitamin C on the biochemical and histopathological outcome in animal model of blunt trauma has been recently proved¹⁴.

Thus, this study was proceeded to estimate the ameliorative effects of SeNPs or/and vitamin C in mitigating the hepatotoxicity after ACR treatment and to assess their enhancing effects on antioxidant capacities.

MATERIALS AND METHODS

Chemicals: The ACR and SeNPs were obtained from Sigma-Aldrich. Vitamin C was purchased from local pharmacy. The ACR was used at a dose¹⁵ of 500 mg kg⁻¹. SeNPs was administrated¹⁶ at a dose of 1.7 ppm. Vitamin C was used at a dose¹⁷ of 500 mg kg⁻¹. All the chemicals of commercially grade were kept at 2-8°C.

Characterization and determination of selenium nanoparticles (SeNPs): Size and morphology of SeNPs were analyzed using Nanotracer analyzer. SeNPs were washed into various size of pieces, eliminated and the morphology of nanoparticles were constructed with Malvern Instruments.

Experimental animals: About 42 adult male mice ranging from 30-35 g were taken from the unit of animals in King Abdul Aziz University, Jeddah, Saudi Arabia and then, were kept in the metal cages. This study was carried out from November, 2019 and continued for 30 successive days. The anatomical features and other analysis experimentations were done on 12 December, 2019 at Department of Biology, Faculty of Science, Taif University. This study was undertaken by following EU Directive 2010/63/EU for animal experiments. This study was approved by the ethical committee of deanship of scientific research by approval number: 40-31-0143. The animals were adapted to the laboratory for 2 weeks before the experiment beginning.

Experimental design: Male mice were divided into 7 groups: control (1 mg kg⁻¹ DMSO); group 2 (ACR at 500 mg kg⁻¹); group 3 (SeNPs at 1.7 ppm), group 4 (vitamin C at 500 mg kg⁻¹), group 5 (ACR+SeNPs), group 6 (ACR+vitamin C) and group 7 (ACR with both SeNPs and vitamin C). All groups were treated orally for 30 consecutive days.

Liver tissue homogenates preparation: Portion of the liver tissue (about 0.30 g) was used for oxidative status assessment. Hepatic tissues were homogenized in sodium phosphate buffer (pH 7.4) combined with cold saline/gram tissue. After centrifugation, the resultant supernatant was preserved in deep freezer till use.

Hepatic function biomarkers: Protein levels in serum samples were evaluated¹⁸. Serum aspartate and alanine aminotransferase (AST and ALT) and lactic dehydrogenase (LDH) levels were assessed¹⁹.

Serum cytokines assessment: Tumor necrosis factor-alpha (TNF- α) levels were estimated by using an ELISA kit.

Liver antioxidant enzymatic biomarkers: Catalase (CAT) activity was estimated by Aebi²⁰. Superoxide dismutase (SOD) was evaluated according to Marklund and Marklund²¹.

Malondialdehyde (MDA) levels were evaluated by the method presented by Ohkawa *et al.*²². Glutathione-S-transferase (GST) was estimated by Couri and Abdel-Rahman²³ and GRx was estimated according to Glodberg and Spooner²⁴.

Determination of myeloperoxidase and xanthine oxidase: Myeloperoxidase (MPO) is present in neutrophil²⁵ and it is determined by using a commercial kits. Xanthine Oxidase (XO) was determined according to Litwack *et al.*²⁶.

Histological and transmission electron microscopic evaluation: A portion of liver was kept in 10% formalin as described by Gabe²⁷. Liver portion was kept in 2.5% glutaraldehyde²⁸. Then other processes were taken to obtain the grids that were examined using TEM.

Single cell gel electrophoresis (Comet assay): Liver tissue parts were put into an ice-cold solution. Viability of the cells was indirectly determined by the comet images²⁹. The comet assay was performed under alkaline conditions³⁰.

Statistical analysis: Data are presented as the Mean \pm SD. Statistical analyses were carried out by using one-way ANOVA³¹. The significance level at a $p \leq 0.05$.

RESULTS

Selenium nanoparticles characterization: Selenium nanoparticles appeared in the nanoscale size and the particles appeared as rounded sphere particles with diameter range (48.47-67.34 nm) (Fig. 1).

Liver biomarkers: Treatment with ACR highly induced a significant decline in the total protein levels as compared with the control group. While, it was apparent that ACR, SeNPs and vitamin C combination improved the declined levels of proteins due to ACR administration. The ALT, AST, ALP and LDH levels were significantly increased after treatment with ACR as compared with the control group (Table 1).

Serum tumor necrosis factor-alpha activity: The ACR treatment elicited a marked increment in TNF- α level. While ACR combined with SeNPs and/or vitamin C induced a marked increment in TNF- α level as compared with the normal control group. Conversely, a significant decrement




Fig. 1: TEM morphology image of selenium nanoparticles

Table 1: Liver function markers of groups treated with acrylamide, selenium nanoparticles and/or vitamin C and their combinations in male mice

Groups	Parameters				
	Total protein (g dL ⁻¹)	AST (U mL ⁻¹)	ALT (U mL ⁻¹)	ALP (U L ⁻¹)	LDH (μ LU mL ⁻¹)
Control	7.1 \pm 0.3 ^c	18.6 \pm 0.6 ^f	17.5 \pm 0.7 ^f	31.1 \pm 1.6 ^g	209.3 \pm 5.0 ^e
Acrylamide	2.1 \pm 0.4 ^f	162.9 \pm 2.01 ^a	88.0 \pm 3.2 ^a	59.5 \pm 1.6 ^a	481.3 \pm 6.5 ^a
Selenium nanoparticles	8.5 \pm 0.4 ^a	14.8 \pm 0.4 ^g	18.8 \pm 1.4 ^e	31.6 \pm 1.6 ^{ef}	205.4 \pm 2.4 ^e
Vitamin C	7.7 \pm 0.7 ^{bc}	24.6 \pm 1.0 ^{ef}	17.9 \pm 2.1 ^f	31.1 \pm 1.4 ^f	207.3 \pm 3.21 ^e
Acrylamide+Selenium nanoparticles	5.6 \pm 0.7 ^e	76.9 \pm 1.7 ^b	42.2 \pm 0.7 ^b	40.1 \pm 1.3 ^b	287.3 \pm 6.4 ^c
Acrylamide+vitamin C	5.8 \pm 0.5 ^e	51.9 \pm 1.02 ^c	30.1 \pm 1.6 ^c	38.6 \pm 1.3 ^c	290.4 \pm 5.3 ^{bc}
Acrylamide+Selenium nanoparticles+Vitamin C	6.8 \pm 0.9 ^d	47.4 \pm 3.6 ^d	25.3 \pm 1.4 ^d	36.1 \pm 1.7 ^{de}	264.7 \pm 2.34 ^d

Means within the same column in each category (Mean \pm SE) carrying different letters are significant at $p \leq 0.05$ using Duncan's multiple range test, where the highest mean value has the symbol (a) and decreasing in value were assigned alphabetically, AST: Aspartate aminotransferase, ALT: Alanine aminotransferase, LDH: Lactate dehydrogenase, ALP: Alkaline phosphatase

in TNF- α level were noticed in ACR treated group combined with SeNPs and/or vitamin C as compared with the ACR group (Table 2).

Oxidative stress biomarkers: The ACR treatment elicited a marked decline in the CAT, SOD, GRx and GST levels as compared with the normal control group. The ACR combined with SeNPs and/or vitamin C induced marked increment in the above antioxidant enzymes as compared with the ACR group. The MDA levels in the liver were significantly elevated after ACR treatment as compared with the control group. The liver MDA was significantly elevated in the groups treated with ACR plus SeNPs and/or vitamin C, but it was significantly declined as compared with the ACR-treated group. There was a highly apparent ameliorating effect of SeNPs and/or vitamin C against ACR toxicity (Table 3).

Treatment with ACR induced a highly increment in MPO and XO levels as compared with the normal control group. The ACR combined with SeNPs and/or vitamin C induced a significant increment in MPO and XO activities, where ACR combined with SeNPs and/or vitamin C exhibited a great improvement of MPO and XO levels as compared with the normal control group but significantly decreased as compared with ACR group (Table 4).

Histopathologic observations: The control group had a normal Central Vein (CV) and normal polyhedral hepatocytes (*) with normal nuclei (Fig. 2a). The ACR-treated group showed a significantly congested and dilated CV (***) and appearance of highly fibrotic hepatic connective tissues (Black arrow) (Fig. 2b). SeNPs-treated group showed normal-size (CV) with normal hepatocytes with normal nuclei (*) (Fig. 2c). Vitamin C treated group has normal-size CV with normal hepatocytes (*) (Fig. 2d). Cross-sections of the ACR and SeNPs-group showed a normal-size mildly congested CV with normal hepatocytes (Black arrow) (Fig. 2e).

The cross-section of the ACR and vitamin C-treated group showed normal-size CV and sinusoids with mild congested central vein and less fibrotic connective tissues and less fatty change (*) (Fig. 2f). The ACR, SeNPs and/or vitamin C-treated group showed a normal liver tissues (*) and mildly dilated CV with less congestion (Fig. 2g).

Transmission electron microscopy: Liver sections TEM images are shown in Fig. 3a. The control group showed normal round nucleus (N). The boundaries of the nucleus are normal with nuclear bores, normal mitochondria (M), Endoplasmic Reticulum (ER) with normal intact hepatocytes (Fig. 3a). The ACR-group showed a pyknotic nuclei (N) with irregular nuclear envelope (Black arrow) with some damaged mitochondria (DM), narrow endoplasmic reticulum, fatty change (***) with presence of red blood cells (RBCs) and more fibrotic tissues (Fig. 3b). The SeNPs-treated group had a normal Bi-nucleated (BN), normal mitochondria (M) with normal endoplasmic reticulum (ER) (Fig. 3c). The vitamin C-treated group showed nucleus (N), normal mitochondria (M) and normal Endoplasmic Reticulum (ER) were noticed in Fig. 3f. Group treated with ACR and SeNPs-showed nucleus (N), intact and regular nuclear boundaries, normal mitochondria (M) and with mild fatty changes (***) (Fig. 3e).

Table 2: Changes in TNF- α level in groups treated with acrylamide, selenium nanoparticles and/or vitamin C and their combinations in male mice

Groups	TNF- α (pg mL ⁻¹)
Control	3.2 \pm 0.2 ^e
Acrylamide	97.5 \pm 1.8 ^a
Selenium nanoparticles	3.2 \pm 0.58 ^e
Vitamin C	2.8 \pm 1.2 ^f
Acrylamide+Selenium nanoparticles	36.5 \pm 1.2 ^{bc}
Acrylamide+Vitamin C	30.3 \pm 1.0 ^c
Acrylamide+Selenium nanoparticles+Vitamin C	13.7 \pm 2.1 ^d

Means within the same column in each category (Mean \pm SE) carrying different letters are significant at $p \leq 0.05$ using Duncan's multiple range test, where the highest mean value has symbol (a) and decreasing in value were assigned alphabetically, TNF- α : Tumour necrosis factor alpha

Table 3: Changes in oxidant/antioxidant parameters in hepatic tissues of groups treated with acrylamide, selenium nanoparticles and/or vitamin C and their combinations in male mice

Groups	Parameters				
	Liver CAT (U g ⁻¹)	Liver SOD (U g ⁻¹)	Liver MDA (U g ⁻¹)	Liver GRx (U g ⁻¹)	Liver GST (U g ⁻¹)
Control	1.70 \pm 0.1 ^b	24.20 \pm 2.2 ^{ab}	5.3 \pm 0.6 ^{ef}	35.3 \pm 2.2 ^a	25.7 \pm 0.7 ^b
Acrylamide	0.40 \pm 0.1 ^g	8.50 \pm 1.5 ^g	47.1 \pm 1.4 ^a	11.4 \pm 1.2 ^f	6.4 \pm 0.8 ^f
Selenium nanoparticles	1.60 \pm 0.3 ^c	22.10 \pm 2.2 ^c	4.2 \pm 0.7 ^f	35.1 \pm 1.3 ^b	25.7 \pm 0.5 ^a
Vitamin C	1.80 \pm 0.4 ^{ab}	23.70 \pm 2.5 ^{bc}	5.1 \pm 0.7 ^{ef}	35.4 \pm 1.5 ^a	25.0 \pm 1.1 ^b
Acrylamide+Selenium nanoparticles	1.02 \pm 0.6 ^f	14.40 \pm 1.5 ^f	22.4 \pm 2.1 ^b	21.1 \pm 2 ^e	15.3 \pm 0.4 ^e
Acrylamide+Vitamin C	1.40 \pm 0.7 ^e	19.87 \pm 2.2 ^e	19.8 \pm 1.7 ^c	28.2 \pm 1.3 ^d	17.9 \pm 0.8 ^{de}
Acrylamide+Selenium nanoparticles+Vitamin C	1.80 \pm 0.3 ^d	21.50 \pm 3.7 ^d	9.2 \pm 1.4 ^d	30.9 \pm 1.7 ^c	19.2 \pm 0.5 ^c

Means within the same column in each category (Mean \pm SE) carrying different letters are significant at $p \leq 0.05$ using Duncan's multiple range test, where the highest mean value has symbol (a) and decreasing in value were assigned alphabetically, SOD: Superoxide dismutase, MDA: Malondialdehyde, CAT: Catalase, GRx: Glutathione reductase, GST: Glutathione-S-transferase

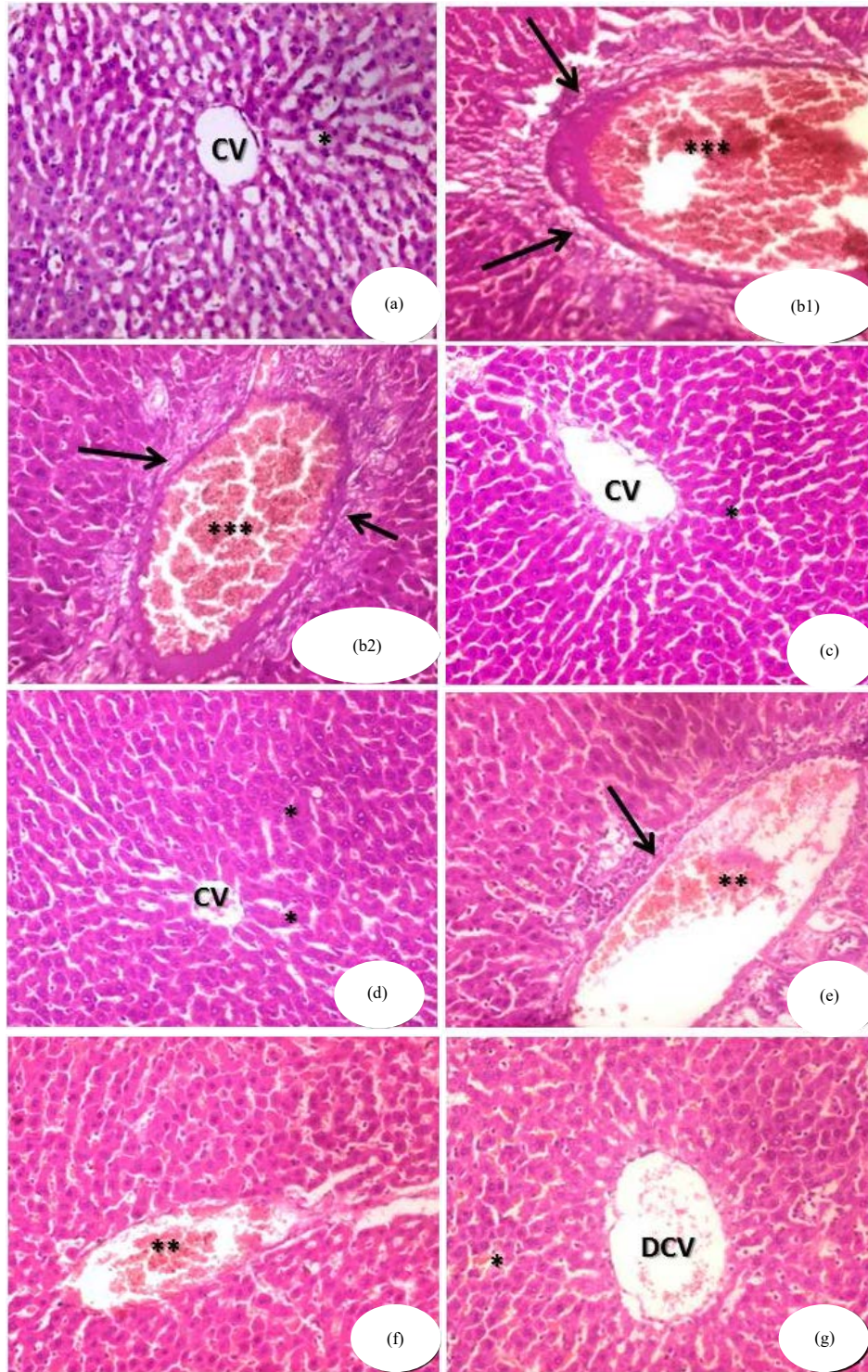


Fig. 2(a-g): Photomicrographs of liver sections in male mice of different groups, (a) Control group with normal Central Vein (CV) and normal hepatocytes (*), (b1, b2) ACR-group having congested and dilated central vein (***), (c) SeNPs-group with (CV) and normal hepatocytes (*), (d) Vitamin C-group having normal central vein and normal hepatocytes (*), (e) ACR and SeNPs-group (mildly congested central vein (**, indicated by a black arrow) and normal hepatocytes (Black arrow), (f) ACR and Vitamin C-group with mild congested central vein (**), (g) ACR, SeNPs and/or Vitamin C-group (normal hepatic tissues (*) and mildly dilated central vein (DCV)

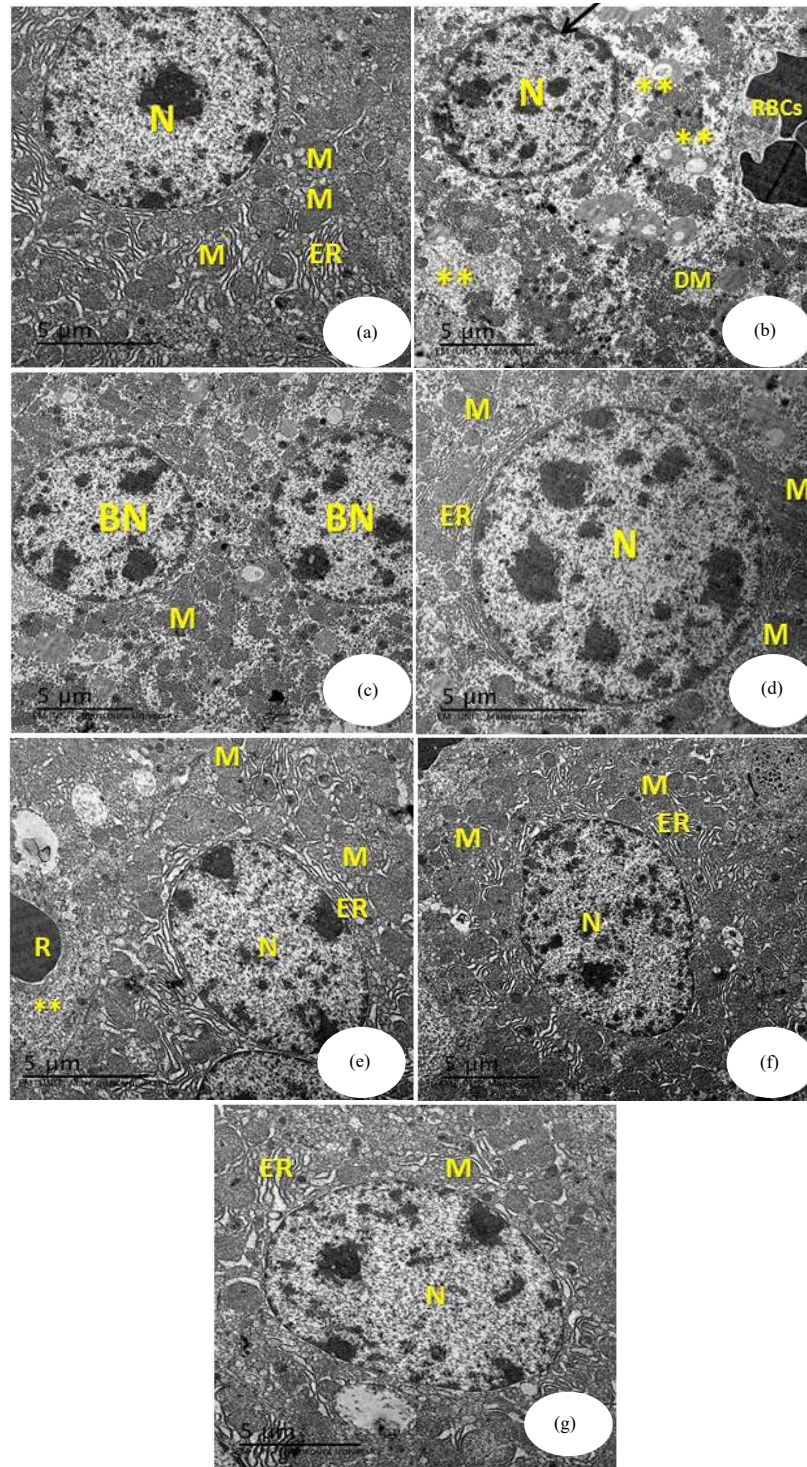


Fig. 3(a-g): Electron photomicrographs of ultra thin liver sections from male mice of different groups, (a) Control group with normal round nucleus (N), normal boundaries, normal mitochondria (M) and endoplasmic reticulum (ER), (b) ACR-group (pyknotic nuclei (N) with irregular envelope (Black arrow), (c) SeNPs- group (normal Bi-nucleated (BN) and normal mitochondria (M), (d) Vitamin C-group with normal nucleus (N), Normal mitochondria (M), (e) ACR and SeNPs have normal nucleus (N), normal mitochondria (M), Normal endoplasmic reticulum (ER), (f) ACR and vitamin C with normal nucleus (N), endoplasmic reticulum (ER) and (g) ACR, SeNPs and vitamin C have normal endoplasmic reticulum (ER), normal mitochondria (M)

Table 4: Changes in MPO and XO in hepatic tissues of groups treated with acrylamide, selenium nanoparticles and/or vitamin C and their combinations in male mice

Groups	Parameters	
	MPO (nmol min ⁻¹ mL ⁻¹)	XO (U g ⁻¹)
Control	17.4±2.4 ^{ef}	15.4±2.1 ^{ef}
Acrylamide	29.4±3.3 ^a	31.8±2.1 ^a
Selenium nanoparticles	17.8±1.6 ^{ef}	15.3±1.4 ^{ef}
Vitamin C	17.6±2.1 ^f	15.4±1.3 ^f
Acrylamide+Selenium nanoparticles	23.4±1.1 ^{bc}	25.4±1.3 ^b
Acrylamide+Vitamin C	20.3±1.2 ^c	22.9±1.3 ^c
Acrylamide+selenium nanoparticles+vitamin C	19.4±1.7 ^d	18.4±1.2 ^d

Means within the same column in each category (Mean±SE) carrying different letters are significant at p≤0.05 using Duncan's multiple range test, where the highest mean value has symbol (a) and decreasing in value were assigned alphabetically, MPO: Myeloperoxidase, XO: Xanthine oxidase

Group treated with ACR and vitamin C showed highly regular nucleus (N) with high restoration of most of the intact hepatic tissues, endoplasmic reticulum (ER), normal-size mitochondria (M) (Fig. 3f). Group treated with ACR, SeNPs and vitamin C-showed a normal intact nucleus, more Endoplasmic Reticulum (ER), normal mitochondria (M) with less fatty changes area (Fig. 3g).

Comet assay: Comet images of control group for hepatic cells derived from the liver showed intact nuclei without tail (Fig. 4a). The ACR group clarified the appearance of highly damage with more apoptotic cells with a large tail forming a comet like structure (Fig. 4b). The SeNPs-group showed nuclei in intact form with uninjured DNA in a

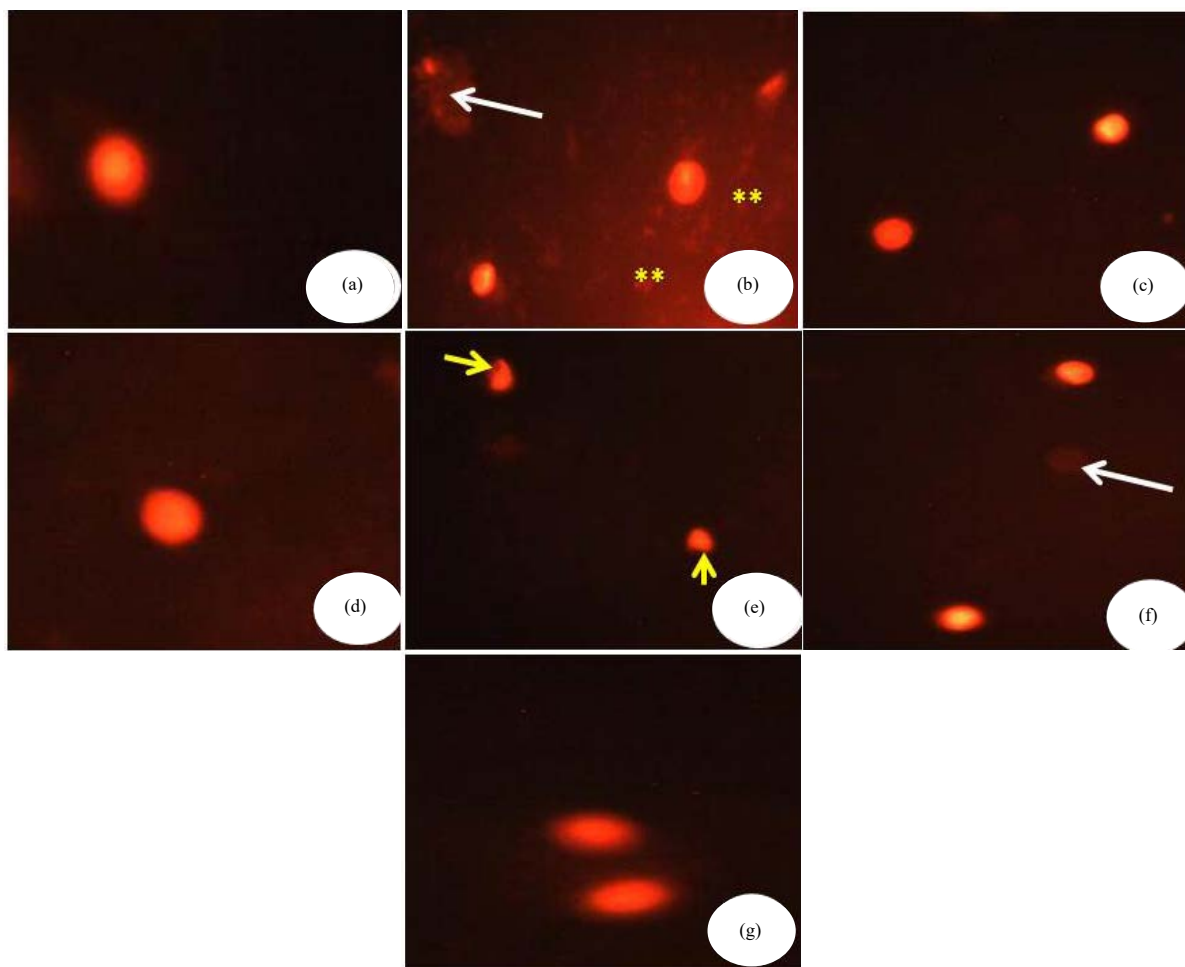


Fig. 4(a-g): Comet assay of liver sections from male mice of different groups, (a) Control group, (b) ACR group (highly damage with more apoptotic cells (*)) (White arrow), (c) SeNPs-group with nuclei in intact form with uninjured DNA, (d) Vitamin C-treated group have nuclei in intact form with undamaged DNA, (e) ACR+SeNPs with percent of damaged DNA (Yellow arrow), (f) ACR+Vitamin C having percent more of cells in intact form with undamaged DNA with less count of comet cells (White arrow) and (g) ACR+SeNPs+Vitamin C (highly degree of restoration of normal intact DNA with less comet tails)

coiled state (Fig. 4c). The vitamin C-treated group exhibited nuclei in intact form with undamaged DNA (Fig. 4d). ACR+SeNPs revealed amelioration of the cells as with a few record in the length of tail with percentage of damaged DNA (Fig. 4e). The ACR+vitamin C showed percentage more of cells in intact form with undamaged DNA with less count of comet cells (Fig. 4f). The ACR+SeNPs+vitamin C treated group showing highly degree of restoration of normal intact DNA with less comet tails (Fig. 4g).

DISCUSSION

The ACR causes important risks to the human health due to its genotoxic characteristics. The ACR leads to free radicals generation by disturbing the antioxidant balance and thus causing oxidative stress³². The results of this study exhibited a significant decrement in the total protein and increment in the hepatic enzymes after ACR administration. Declined protein levels were noticed in ACR-treated group, which would be due to nutrition insufficiency, failure of protein synthesis or excess of excretion³³. Declining of total protein level might be due to the hepatic inflammation due to ACR exposure, which disarranged the protein synthesis³³. The current results are in agreement with Hamdy *et al.*³⁴, who demonstrated that ACR induced damage in liver tissues.

The obtained results significantly induced increment in ALT, AST and LDH levels in ACR group as compared with the control group. These results agreed with El-Bohi *et al.*³⁵ and Abdel-Daim *et al.*³⁶. Administration of either SeNPs or vitamin C exhibited a significant decline in their levels. This may confirm the hepatic protective activity of SeNPs and vitamin C. The ACR induced a significant increment in TNF- α level and this indicated the inflammatory effects of ACR and the anti-inflammatory effects of both SeNPs and vitamin C in alleviating this inflammation. The present results are in agreement with the results reported by Ruiz *et al.*³⁷, who reported that TNF- α is a potent regulator of cell death and survival and effector in immune responses.

The current results clarified that MDA levels in the hepatic tissues were significantly increased in response to ACR treatment. This finding is consistent with Al-Salmi¹⁵ who reported that there was a significant increment in serum MDA levels in ACR group when compared with the control group and this is consistent with Venkatasubbaiah *et al.*³⁸ who reported that ACR induced oxidative stress. A significant decline in SOD, CAT and GST activities in ACR treated group was noticed as compared with the control group. This synchronized with other scientists as well³⁹. There were a significant increment in SOD, GST and CAT activities in

SeNPs and vitamin C-ACR treated group when compared with ACR group. The GST is an essential factor for enzymatic antioxidants, prohibits the damage produced from the free radicals and helps in the removal of any toxins⁴⁰ and this confirmed the current finding which approved that GST declined in ACR group and increased in either SeNPs or vitamin C treated groups alone or combined with ACR. The ACR treatment induced a marked increment in hepatic MPO levels as compared with the normal control group. The MPO is most expressed in granulocytes. Therefore, they are used to kill pathogens⁴¹ and these observations proved the present study results that showed a significant increment in MPO levels in ACR-group, thus promoting the level of oxidative injury. The ACR elicited a marked increment in XO level as compared with the normal control group. The XO generated reactive oxygen species. This enzyme played a vital role in the catabolism of purine⁴². This reinforced the observations of the present study of increment of XO levels in ACR group. ACR-treated group showed an excessive liver injury. Most of the hepatocytes were noticed as fibrotic with highly congested central vein. The obtained results were highly fortified by those of Al-Mosaibih⁴³, who reported that most signs of hepatic tissue damages were spotted in hepatocytes of ACR treated group. Additionally, ACR induced necrosis in the liver hepatocytes of chicken embryos⁴⁴. The vacuolation of hepatic cells as ballooning degeneration which is considered as a kind of cellular defensive activity was described by Abdel Hameed⁴⁵. Similarly to the current results, the exposure to either ACR and monosodium glutamate toxins turned the degenerative alterations into tissue lysis and necrotic injury. These finding is in coincidence with Totani *et al.*⁴⁶ who reported that Acrylamide treatment showed necrosis and hemorrhage in the liver tissues. The present study revealed pyknosis of nuclei and this may indicate the loss of functional unit and effectiveness of the hepatic cell.

Similar results have been reported by Kedam *et al.*⁴⁴ who showed the presence of hypertrophy in nuclei and appearance of pyknotic nuclei in acrylamide treated chicken. The nuclear damage is a consequence of cytoplasmic damage. Hemorrhages and bile ducts proliferation were noticed in acrylamide treated group was demonstrated by Abdel Hameed⁴⁵ and Nagao *et al.*⁴⁶.

It was apparent from the present results that SeNPs has hepatoprotective effect by declining the high level of liver enzymes after treatment with ACR, it has antioxidant ameliorative effect against ACR toxicity by reducing level of MDA and increment of other antioxidant enzymes, this finding is in agreement with Khurana *et al.*⁸ who reported that SeNPs has improvement properties.

The abilities of SeNPs in alleviating hepatotoxicity induced by ACR as appeared clearly in histological, ultrastructural and comet images revealed its high biocompatibility and biological stability which may be a good food supplement and may be a component in the pharmaceutical industry⁴⁷.

Vitamin C is considered as strong scavenger for free radicals¹⁴. The ameliorative effect of vitamin C on the biochemical and histopathological aspect of ACR hepatotoxicity in animal model has been proved. Moreover, vitamin C could be easily administrated into the cell. So, vitamin C is hypothesized to have potential antioxidant protective roles on ACR recovery and may enhance the hepatic pathological changes. The present study confirmed that administration of vitamin C has a protective effect on hepatic function markers and elevate antioxidant enzymes and the possible causes for these beneficial results, may be due to the inflammatory actions induced by ACR and the potential anti-inflammatory effect of vitamin C specially when given with SeNPs which elicited more beneficial effect. Similar to the obtained results about antioxidant activities of vitamin C and anti-hepatotoxicity induced by ACR, vitamin C is highly effective in alleviation the toxic effect of zinc oxide nanoparticles¹².

CONCLUSION

The results exhibited that ACR induced the formation of free radicals, which are the main cause of oxidative damage and structural alterations in the hepatic tissues and impairment of the hepatic activities. The use of vitamin C in combination with SeNPs protected the hepatic tissues from the biological and the structural injuries.

SIGNIFICANCE STATEMENT

This study discovered the beneficial effect of both vitamin C and SeNPs in alleviating the hepatotoxicity induced by ACR. This study will help in reducing the toxic effects produced by ACR on liver and reaching to potent antioxidant combinations against oxidative stress series.

ACKNOWLEDGMENT

Dr. Reham Zakaria Hamza is thankful to the support of Deanship of Scientific Research, in Taif University for funding the Future Researcher Program in the project No. 1-439-6095.

REFERENCES

1. Albalawi, A., R.H.A. Alhasan, L. Biswas, J. Reilly and X. Shu, 2017. Protective effect of carnosic acid against acrylamide-induced toxicity in RPE cells. *Food Chem. Toxicol.*, 108: 543-553.
2. Zyzak, D.V., R.A. Sanders, M. Stojanovic, D.H. Tallmadge and B.L. Eberhart *et al.*, 2003. Acrylamide formation mechanism in heated foods. *J. Agric. Food Chem.*, 51: 4782-4787.
3. Guan, Q., B. Su, X. Wei, S. Wang and M. Wang *et al.*, 2018. Protective effect of calpeptin on acrylamide-induced microtubule injury in sciatic nerve. *Toxicology*, 409: 103-111.
4. Fu, Z., M.J.Y. Yoo, W. Zhou, L. Zhang, Y. Chen and J. Lu, 2018. Effect of (-)-epigallocatechin gallate (EGCG) extracted from green tea in reducing the formation of acrylamide during the bread baking process. *Food Chem.*, 242: 162-168.
5. Komoike, Y. and M. Matsuoka, 2019. *In vitro* and *in vivo* studies of oxidative stress responses against acrylamide toxicity in zebrafish. *J. Hazard. Mater.*, 365: 430-439.
6. Gedik, S., M.E. Erdemli, M. Gul, B. Yigitcan, H.G. Bag, Z. Aksungur and E. Altinoz, 2017. Hepatoprotective effects of crocin on biochemical and histopathological alterations following acrylamide-induced liver injury in Wistar rats. *Biomed. Pharmacother.*, 95: 764-770.
7. Rizk, M.Z., D.M. Abo-El-Matty, H.F. Aly, H.I. Abd-Alla and S.M. Saleh *et al.*, 2018. Therapeutic activity of sour orange albedo extract and abundant flavanones loaded silica nanoparticles against acrylamide-induced hepatotoxicity. *Toxicol. Rep.*, 5: 929-942.
8. Khurana, A., S. Tekula, M.A. Saifi, P. Venkatesh and C. Godugu, 2019. Therapeutic applications of selenium nanoparticles. *Biomed. Pharmacother.*, 111: 802-812.
9. Zhao, G., X. Wu, P. Chen, L. Zhang, C.S. Yang and J. Zhang, 2018. Selenium nanoparticles are more efficient than sodium selenite in producing reactive oxygen species and hyper-accumulation of selenium nanoparticles in cancer cells generates potent therapeutic effects. *Free Radic. Biol. Med.*, 126: 55-66.
10. Abu-El-Zahab, H.S., R.Z. Hamza, M.M. Montaser, M.M. El-Mahdi and W.A. Al-Harhi, 2019. Antioxidant, antiapoptotic, antigenotoxic and hepatic ameliorative effects of L-carnitine and selenium on cadmium-induced hepatotoxicity and alterations in liver cell structure in male mice. *Ecotoxicol. Environ. Safety*, 173: 419-428.
11. Forootanfar, H., M. Adeli-Sardou, M. Nikkhoo, M. Mehrabani, B. Amir-Heidari, A.R. Shahverdi and M. Shakibaie, 2014. Antioxidant and cytotoxic effect of biologically synthesized selenium nanoparticles in comparison to selenium dioxide. *J. Trace Elem. Med. Biol.*, 28: 75-79.

12. Alkaladi, A., 2019. Vitamins E and C ameliorate the oxidative stresses induced by zinc oxide nanoparticles on liver and gills of *Oreochromis niloticus*. Saudi J. Biol. Sci., 26: 357-362.
13. Izquierdo, M., D. Dominguez, J.I. Jimenez, R. Saleh, C.M. Hernandez-Cruz, M.J. Zamorano and K. Hamre, 2019. Interaction between taurine, vitamin E and vitamin C in microdiets for gilthead seabream (*Sparus aurata*) larvae. Aquaculture, 498: 246-253.
14. Abdoulhossein, D., I. Taheri, M.A. Saba, H. Akbari, S. Shafagh and A. Zataollah, 2018. Effect of vitamin C and vitamin E on lung contusion: A randomized clinical trial study. Ann. Med. Surg., 36: 152-157.
15. Al-Salmi, F.A., 2019. Ameliorative and synergistic effect of red raspberry and lycopene against hepatotoxicity induced by acrylamide in male mice. Pharmacology, 15: 166-176.
16. Jang, D.Y., S.J. Kim, J.H. Jeong, S.Y. Nam, J.S. Kim, Y.W. Yun and B.J. Lee, 2016. Protective effects of sodium selenite and selenium nanoparticles against experimental colon carcinogenesis in mice. J. Prev. Vet. Med., 40: 101-108.
17. Zadrozniak, M., M. Szymanski and J.J. Luszczki, 2019. Vitamin C alleviates ototoxic effect caused by coadministration of amikacin and furosemide. Pharmacol. Rep., 71: 351-356.
18. Kaplan, A. and L.L. Szabo, 1983. Clinical Chemistry: Interpretation and Techniques. 2nd Edn., Lea & Febiger, Philadelphia, USA., ISBN-13: 9780812108736, Pages: 427.
19. King, J., 1965. The Transferases-Alanine and Aspartate Transaminases. In: Practical Clinical Enzymology, King, J. (Ed.), Van Nostrand Company Ltd., London, pp: 121-138.
20. Aebi, H., 1984. Catalase *in vitro*. Meth. Enzymol., 105: 121-126.
21. Marklund, S. and G. Marklund, 1974. Involvement of the superoxide anion radical in the autoxidation of pyrogallol and a convenient assay for superoxide dismutase. Eur. J. Biochem., 47: 469-474.
22. Ohkawa, H., N. Ohishi and K. Yagi, 1979. Assay for lipid peroxides in animal tissues by thiobarbituric acid reaction. Anal. Biochem., 95: 351-358.
23. Couri, D. and M.S. Abdel-Rahman, 1979. Effect of chlorine dioxide and metabolites on glutathione dependent system in rat, mouse and chicken blood. J. Environ. Pathol. Toxicol., 3: 451-460.
24. Goldberg, D.M. and R.J. Spooner, 1983. Assay of Glutathione Reductase. In: Methods of Enzymatic Analysis, Bergmeyer, H.V. (Ed.) 3rd Edn., Wiley-VCH, USA., ISBN-13: 978-0895732323, pp: 258-265.
25. Suzuki, K., H. Ota, S. Sasagawa, T. Sakatani and T. Fujikura, 1983. Assay method for myeloperoxidase in human polymorphonuclear leukocytes. Anal. Biochem., 132: 345-352.
26. Litwack, G., J.W. Bothwell, J.N. Williams Jr. and C.A. Elvehjem, 1953. A colorimetric assay for xanthine oxidase in rat liver homogenates. J. Biol. Chem., 200: 303-310.
27. Gabe, M., 1968. Techniques Histologiques [Histological Techniques]. Masson Publisher, Paris, France, Pages: 1113.
28. Weakley, B., 1981. A Beginner's Handbook in Biological Transmission Electron Microscopy. 2nd Edn., Churchill Livingstone, London, UK., ISBN: 9780443020919, Pages: 252.
29. Endoh, D., T. Okui, S. Ozawa, O. Yamato, Y. Kon, J. Arikawa and M. Hayashi, 2002. Protective effect of a lignan-containing flaxseed extract against CCl₄-induced hepatic injury. J. Vet. Med. Sci., 64: 761-765.
30. Collins, A.R., 2004. The comet assay for DNA damage and repair: Principles, applications and limitations. Mol. Biotechnol., 26: 249-261.
31. Duncan, D.B., 1955. Multiple range and multiple F tests. Biometrics, 11: 1-42.
32. Acaroz, U., S. Ince, D. Arslan-Acaroz, Z. Gurler and I. Kucukkurt *et al.*, 2018. The ameliorative effects of boron against acrylamide-induced oxidative stress, inflammatory response and metabolic changes in rats. Food Chem. Toxicol., 118: 745-752.
33. Chawla, R., 2014. Practical Clinical Biochemistry: Methods and Interpretations. 4th Edn., Jaypee Brothers Medical Publ., India, ISBN-13: 978-9350909423, Pages: 345.
34. Hamdy, S.M., A.M. Shabaan, A.K.M.A. Latif, A.M. Abdel-Aziz and A.M. Amin, 2017. Protective effect of hesperidin and tiger nut against acrylamide toxicity in female rats. Exp. Toxicol. Pathol., 69: 580-588.
35. El-Bohi, K.M., G.G. Moustafa, N.I. El Sharkawi and L.M.E. Sabik, 2011. Genotoxic effects of acrylamide in adult male albino rats liver. J. Am. Sci., 7: 1097-1108.
36. Abdel-Daim, M.M., M.A. Abd Eldaim and A.G. Hassan, 2014. *Trigonella foenum-graecum* ameliorates acrylamide-induced toxicity in rats: Roles of oxidative stress, proinflammatory cytokines and DNA damage. Biochem. Cell Biol., 93: 192-198.
37. Ruiz, M.A., M.B. Betancor, L. Robaina, D. Montero and C.M. Hernandez-Cruz *et al.*, 2019. Dietary combination of vitamin E, C and K affects growth, antioxidant activity and the incidence of systemic granulomatosis in meagre (*Argyrosomus regius*). Aquaculture, 498: 606-620.
38. Venkatasubbaiah, K., D.M. Venkataswamy, K.S. Suresh and K.J. Rao, 2014. Acrylamide induced oxidative stress in rat and chick embryonic liver. Indo Am. J. Pharmaceut. Res., 6: 2791-2798.
39. Yousef, M.I. and F.M. El-Demerdash, 2006. Acrylamide-induced oxidative stress and biochemical perturbations in rats. Toxicology, 219: 133-141.
40. Hayes, J.D., J.U. Flanagan and I.R. Jowsey, 2005. Glutathione transferases. Annu. Rev. Pharmacol. Toxicol., 45: 51-88.
41. Klebanoff, S.J., 2005. Myeloperoxidase: Friend and foe. J. Leukocyte Biol., 77: 598-625.
42. Hille, R., 2005. Molybdenum-containing hydroxylases. Arch. Biochem. Biophys., 433: 107-116.
43. Al-Mosaibih, M.A., 2013. Effects of monosodium glutamate and acrylamide on the liver tissue of adult Wistar rats. Life Sci., 10: 35-42.

44. Kedam, T.R., R.B. Sheik, M.M. Bai and S.K.H. Bhanu, 2012. A histological study on acrylamide and cadmium chloride altered chick embryonic liver. *IOSR J. Pharm.*, 2: 1-8.
45. Abdel Hameed, T.F., 2004. Light and electron microscopic studies on the effect of orally-administered formalin on liver and kidney of guinea pig. *J. Egypt. Ger. Soc. Zool. C: Histol. Histochem.*, 45: 203-224.
46. Totani, N., M. Yawata and Y. Ojiri and Y. Fujioka, 2007. Effects of trace acrylamide intake in Wistar rats. *J. Oleo Sci.*, 56: 501-506.
47. Chen, W., Y. Li, S. Yang, L. Yue, Q. Jiang and W. Xia, 2015. Synthesis and antioxidant properties of chitosan and carboxymethyl chitosan-stabilized selenium nanoparticles. *Carbohydr. Polym.*, 132: 574-581.