



# International Journal of Pharmacology

ISSN 1811-7775

**science**  
alert

**ansinet**  
Asian Network for Scientific Information

## Mucosal Protective Effects of Vitamin E on Aspirin-induced Gastric Lesions in Rats

<sup>1</sup>J. Kamsiah, <sup>2</sup>W. Muhaizan, <sup>3</sup>M.T. Gapor and <sup>1</sup>O. Roslin

<sup>1</sup>Department of Pharmacology, <sup>2</sup>Department of Pathology, Faculty of Medicine,  
University Kebangsaan Malaysia, Kuala Lumpur, Malaysia

<sup>3</sup>Palm Oil Research Institute of Malaysia, Malaysia

**Abstract:** This study examined the effects of vitamin E on the prevention of aspirin induced gastric lesions. Sixty-four rats of Sprague-Dawley species (200-250 g) were randomized into four groups. Group I was fed a normal diet, Groups II to Group IV were fed with palm vitamin E and tocopherol enriched diet in a dose of 100, 150 and 30 mg kg<sup>-1</sup> food, respectively. After four weeks of feeding with the respective diets the rats were challenged with a single intragastric dose of 400 mg kg<sup>-1</sup> body weight aspirin suspended in propylene glycol. The rats were killed 6 h post-aspirin exposure for the determination of histological changes, gastric lesion index and gastric acid and malondialdehyde. The gastric mucosal thickness was significantly higher in the groups treated with palm vitamin E in the dose of 100 mg kg<sup>-1</sup> body weight and 150 mg kg<sup>-1</sup> body weight compared to control and tocopherol treated group. Gastric lesions index was significantly lower in all the vitamin E groups compared to control. However, there was no significant difference in ulcer indices between palm vitamin E and tocopherol treated groups. The lower ulcer index and better histological changes were accompanied by lower gastric MDA and gastric acid content. It is concluded that the histological changes post aspirin exposure was better in palm vitamin E treated group compared to tocopherol group. However palm vitamin E in a dose of 100 and 150 mg kg<sup>-1</sup> body weight as well as tocopherol in a dose of 30 mg have an equal effect on gastric lesions index, gastric acid and malondialdehyde. It thus appear that the protective effect of vitamin E on aspirin induced gastric lesion mediated through its ability in limiting lipid peroxidation and gastric acid secretion.

**Key words:** Palm vitamin E, tocopherol, aspirin, histological, rat

### INTRODUCTION

Many structurally unrelated chemicals such as strong acids, alcohol or drugs damage the gastric mucosa and induce lesions in human and experimental animals<sup>[1]</sup>. Over 30 million people worldwide use non-steroidal anti-inflammatory drugs (NSAIDs) daily. Numerous human studies have shown that the use of NSAIDs is associated with various gastroduodenal mucosal lesions<sup>[2,3]</sup>. The mechanism by which aspirin and other NSAIDs produce acute and chronic gastroduodenal mucosal injury are incompletely understood<sup>[4]</sup>. It has been suggested that the mechanism of aspirin-induced gastric lesion be mediated through lipid peroxidation<sup>[5]</sup>.

Alpha tocopherol (vitamin E) is a naturally occurring antioxidant in biological systems and is present in the cell membrane of various tissues including the intestine and stomach<sup>[6]</sup>. Vitamin E prevents free radical-induced injury by blocking the free radical chain

reaction. The formation of experimental gastric lesions may be reduced through decreasing free radicals and minimizing lipid peroxidation<sup>[5]</sup>. Previous studies have shown that deficiencies in vitamin E have resulted in peptic ulceration<sup>[7]</sup> and that vitamin E supplementation to the diet has protective effects on the gastric mucosa<sup>[8,9]</sup>.

Serbinova and Packer<sup>[9]</sup> have shown that tocotrienol to be a more potent antioxidant than alpha tocopherol. Palmvitee is a vitamin E concentrate from palm oil and it contains approximately 80% tocotrienol and 20% tocopherol.

Earlier studies<sup>[10-12]</sup> have reported that palm vitamin E given at the dose of 150 mg kg<sup>-1</sup> food for three weeks either before or after the induction of gastric lesions were able to accelerate the healing of ethanol-induced gastric injury in rats. However, the same dose of palm vitamin E could not prevent the ethanol-induced lesion in rats. The findings suggest the possibility that the effect of palm vitamin E or tocopherol on chemical-induced gastric

lesions is dose dependent. We subsequently reported that palm vitamin E in a dose of 60, 100, 150 and 300 mg kg<sup>-1</sup> food and tocopherol in a dose of 20, 30, 50 and 300 mg kg<sup>-1</sup> food given for duration of 4 to 8 weeks were equally effective in preventing aspirin-induced gastric lesions in rats<sup>[13,14]</sup>. This study was undertaken to ascertain whether the protective effect of palm vitamin E and tocopherol on aspirin-induced gastric lesions is accompanied by better histological changes.

## MATERIALS AND METHODS

All experimental animal used in this study was approved by University Kebangsaan Malaysia animal ethic committee. Sixty-four male rats of sprague-Dawley species weighing between 200 to 250 g were randomized to four groups. The animals were maintained in singles cages and were deprived of food for 12 h before experiments. Free access to water and *ad libitum* was allowed until 1 h before the beginning of experiment. Group I (n=16) was fed a normal rat chow, whereas groups II (n=16) and III (n=16) were fed with a normal rat chow and the same time were supplemented with orogastric tube administration of palm vitamin E in a dose 100 mg kg<sup>-1</sup> body weight, 150 mg kg<sup>-1</sup> weight, respectively for four weeks. Whereas rats in group IV (n=16) was supplemented with tocopherol in a dose of 30 mg kg<sup>-1</sup> body weights for the same duration. After 4 weeks of feeding, the rats were challenged with a single dose of 400 mg kg<sup>-1</sup> body weight of aspirin administered via an orogastric tube. The rats were killed at 6 h post-aspirin exposure for gastric histological sampling, determination of gastric lesions, gastric acidity and MDA content.

**Measurement of gastric acidity:** The measurement of gastric acidity was done according to the method described by Shay *et al.*<sup>[15]</sup>. The lower end of the oesophagus was clamped and the stomach was removed. Samples of gastric juice were collected and centrifuged at 1500 g for 10 min. Aliquots of each sample were titrated with 0.01 N NaOH to a pH of 7.0. The concentration of hydrogen ion was calculated as described by Shay *et al.*<sup>[15]</sup>.

**Measurement of malondialdehyde (MDA):** Tissue samples weighing 0.2 g from the corpus region was homogenized using a glass homogenizer (Potter). The content of gastric tissue MDA was then determined using the method described by Ledwozyw *et al.*<sup>[16]</sup>. A sample of 0.5 mL was acidified with 2.5 mL, 1.22 mol L<sup>-1</sup> trichloroacetic acid in 0.5 mol L<sup>-1</sup> HCl. The mixture was left to stand

for 15 min. After this time, 1.5 mL of 0.6% thiobarbituric acid in 0.05 mol NaOH was added. The samples were incubated in a 100°C water bath for 30 min. Subsequently it was cooled under running tap water and 4 mL of n-butanol was added. After thorough mixing, the mixture was centrifuged for 10 min at 1500 g. The absorbance of the upper phase was read at 535 nm using a spectrophotometer.

**Determination of gastric lesion:** The gastric mucosa was then exposed by cutting the stomach along the greater curvature, washed with saline and laid on a flat wooden board. The severity of gastric mucosal lesions expressed as ulcer index was determined semiquantitatively as described by Berry *et al.*<sup>[17]</sup> which were graded as follows: 5 = multiple ulcers following almost the entire length of gastric fold, 4 = lesions which followed approximately 80% of the folds, 3 = ulcer 1-4 mm in length on 80% of the folds, 2 = at least 2 ulcers approximately 2 mm in length, 1 = the presence of 1 ulcer and generalised erythema and 0 = no visible damage.

**Histological assessment and calculation of gastric mucosal thickness:** Representative sections were taken from the site of the lesion and one sample each from the fundus, body and antrum. These tissues were fixed in formalin, embedded in paraffin blocks, sectioned at 3 to 4 microns and stained with hematoxylin and eosin. Histopathologist who is unaware of the treatment groups that the specimen belongs to then examined the slides.

Calculation of mucosal thickness was done as follows: 10 areas of well orientated gastric glands whose lumens could be seen throughout their length were counted per section and measured with an Olympus U-OCM 10/100 micrometer eyepiece along its perpendicular axis are expressed as the mean mucosal thickness (in micrometers)

**Statistical analysis:** Data are expressed as mean±SEM. Statistical significance (p<0.05) was determined by ANOVA followed by student's t-test.

## RESULTS

**Effect of palm vitamin E on gastric acidity:** There was a significant decrease in gastric acid concentration in the vitamin E groups compared to control (P<0.05). However, there was no significant difference in gastric acid concentration among the vitamin E-treated groups (Fig. 1).

**Effect of palm vitamin E on gastric MDA:** The gastric tissue content of MDA was significantly lower in the

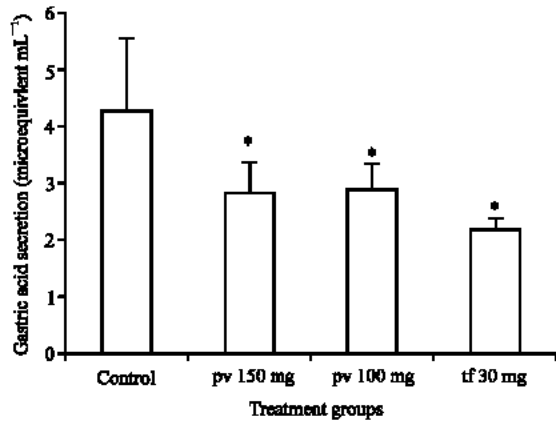


Fig. 1: Effect of vitamin E on gastric acidity (\*P<0.05 compared to control)

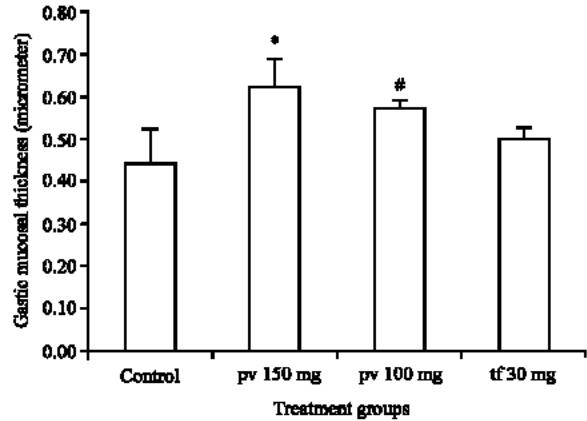


Fig. 4a: Effect of vitamin E on gastric mucosal thickness (\*P<0.05 compared to control, #P<0.05 compared to the other treatment groups)

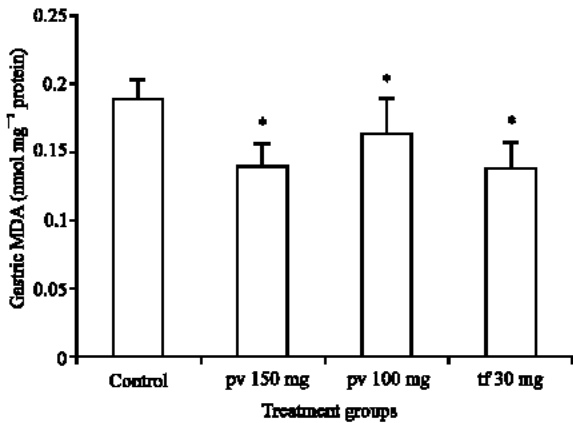


Fig. 2: Effect of vitamin E on gastric MDA (\*P<0.05 compared to control)

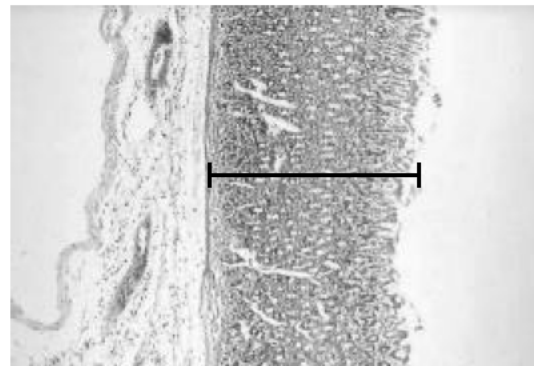


Fig. 4b: Measurement of gastric mucosal thickness along its perpendicular axis using eyepiece Olympus micrometer (Original magnification X100 H and E)

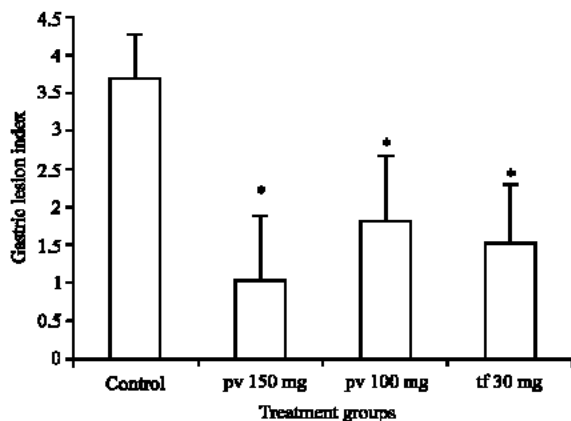


Fig. 3: Effect of vitamin E on gastric lesions index

vitamin E-treated groups compared to control (P<0.05). There was no significant difference in gastric MDA among the vitamin E-treated groups (Fig. 2).

**Effect of palm vitamin E and tocopherol on aspirin-induced gastric lesions:** The gastric lesions index of the palm vitamin E and tocopherol-treated groups were significantly lower compared to control at 6 h after aspirin administration (P<0.05). However, there was no significant difference in gastric lesion index between the palm vitamin E- and tocopherol-treated groups throughout the study period (Fig. 3).

**Effect of palm vitamin E and tocopherol on gastric mucosal thickness post-aspirin exposure:** The gastric mucosal thickness was significantly higher in all the groups treated with either palm vitamin E in the dose of 100 mg kg<sup>-1</sup> body weights and 150 mg kg<sup>-1</sup> body weights compared to control (P<0.05) (Fig. 4a). However, there were no significant differences in gastric mucosal thickness between the tocopherol-supplemented groups

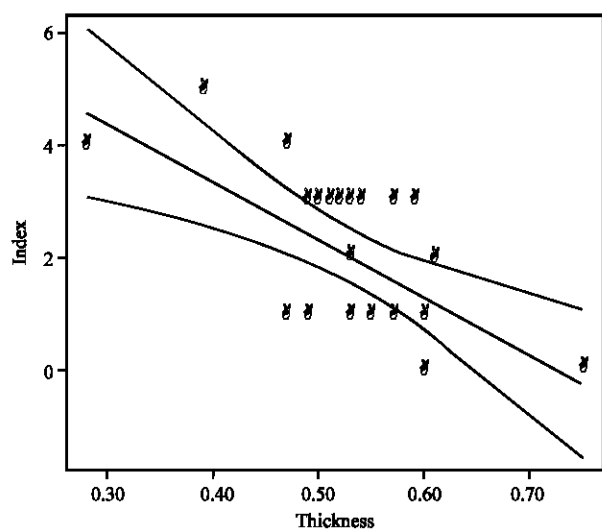


Fig. 4c: Correlation between gastric mucosal thickness and gastric ulcer index

and control after 6 h of aspirin administration (Fig. 4b). There was negative correlation ( $r=-0.634$ ) between the gastric ulcer index and gastric mucosal thickness (Fig. 4c).

**Histological assessment:** In all the control and the test groups there is no ulcer or stomach mucosal denudation seen. In almost all cases there are abundant eosinophilic infiltration in the deep mucosal layer and some going into the lamina propria and submucosal region. However there is no specific pattern seen between the control and the test. This infiltration could be a normal composition of the rat stomach mucosa or as a reaction towards aspirin given, which could not be ascertain. In some, accompanied patchy lymphocytes are also seen.

### DISCUSSION

Many studies have shown that vitamin E can improve gastric ulcers or lesions induced by ethanol and non-steroidal anti-inflammatory drugs. Previous studies have indicated that palm vitamin E in a dose of  $150 \text{ mg kg}^{-1}$  food was able to promote the healing but was unable to prevent ethanol-induced gastric lesions in rats<sup>[12,18]</sup>. The healing effect of palm vitamin E on ethanol induced gastric lesions is not mediated by a reduction of gastric acid concentration but appears to be mediated through retarding the lipid peroxidation process. We subsequently reported that palm vitamin E in a dose of 60, 100, 150 and  $300 \text{ mg kg}^{-1}$  food and tocopherol in a dose of 20, 30, 50 and  $300 \text{ mg kg}^{-1}$  food given for duration of 4 to 8 weeks were equally effective in preventing aspirin-induced gastric lesions in rats<sup>[13,14]</sup>. In the current

study, the gastric tissue content of MDA and gastric acid were significantly reduced in the vitamin E groups compared to the control group. There was however, no difference between the MDA and gastric acid content in the gastric tissue of the palm vitamin E and the tocopherol groups. This indicates that vitamin E confers an equivalent anti-lipid peroxidation and antisecretory effect on the gastric tissue. The effect of palm vitamin E on gastric acid, MDA content was not dependent on dose as  $100 \text{ mg kg}^{-1}$  body weight of palm vitamin E had the same effect as palm vitamin E in the dose of  $150 \text{ mg kg}^{-1}$  body weights.

Palm vitamin E and tocopherol given 4 weeks before aspirin exposure were able to prevent aspirin-induced gastric lesions as the gastric lesion index in the palm vitamin E and tocopherol treated group were significantly lower compared to control. In this study, we found that the effect of  $100 \text{ mg kg}^{-1}$  body weight and  $150 \text{ mg kg}^{-1}$  body weight of palm vitamin E on ulcer index and gastric parameters were equipotent to tocopherol dose of  $30 \text{ mg kg}^{-1}$  body weight. However, the effect of vitamin E on gastric mucosal thickness was significantly higher in palm vitamin E and not in the tocopherol treated group. This study suggested that palm vitamin E in a dose of  $100 \text{ mg kg}^{-1}$  weight and  $150 \text{ mg kg}^{-1}$  body weight appear to be more effective in preventing aspirin-induced gastric lesions than tocopherol in a dose of  $30 \text{ mg kg}^{-1}$  weight, as the gastric mucosal thickness in these palm vitamin E groups were significantly higher compared to the other groups.

Even though there was a negative correlation between gastric lesions index and mucosal thickness, it thus appears that gastric lesions index should be supported with histological finding.

Even though tocotrienol is more potent antioxidant than tocopherol<sup>[9]</sup>, this study showed that palm vitamin E, although rich in tocotrienol, is less potent than tocopherol in its effect on gastric lesion index and other gastric parameters. A higher dose of palm vitamin E is required to manifest the same effect on gastric lesion index and other gastric parameters. The reason for this is not clear. It is possible that the effect of tocotrienol in palm vitamin E is attenuated by the higher fraction (20%) of tocopherol. This finding was in contrast to earlier work<sup>[11,12]</sup> in which palm vitamin E in a dose of  $150 \text{ mg kg}^{-1}$  food was unable to prevent ethanol-induced lesions. This discrepancy may be attributed to the severity of gastric lesions. It thus appears that ethanol-induced gastric lesions were more severe compared to aspirin-induced lesions, thus requiring larger doses of palm vitamin E (in excess of  $150 \text{ mg kg}^{-1}$  food) for prevention. Aspirin-induced lesions in the other hand only required palm vitamin E or

tocopherol as low as 100 mg kg<sup>-1</sup> food or 30 mg kg<sup>-1</sup> food, respectively.

The preventive effect of palm vitamin E and tocopherol on aspirin-induced lesions was associated with a significant reduction in gastric MDA and acid content.

This study concluded that the histological changes post aspirin exposure was better in palm vitamin E treated group compared to tocopherol group. However palm vitamin E in a dose of 100 and 150 mg kg<sup>-1</sup> body weight have as well as tocopherol in a dose of 30 mg have and equal effect on gastric lesions index and gastric acid and malondialdehyde. It thus appear that the protective effect of vitamin E on aspirin induced gastric lesion mediated through its ability in limiting lipid peroxidation and gastric acid secretion.

Since the dose of tocopherol required to produce the protective effect is lower compared to the dose of Palm vitamin E, it thus appear that the effect of tocopherol on gastric is more potent compared to palm vitamin E.

#### ACKNOWLEDGMENTS

The authors wish to express their gratitude to Palm Oil Research Institute of Malaysia for supplying palmvittee and Professor Masbah Omar for editing the manuscript.

#### REFERENCES

1. Miller, T., 1983. Protective effect of prostaglandin against gastric mucosal damage. Current knowledge and proposed mechanisms. *Am. J. Physiol.*, 245: G601-G623.
2. Kendall, B.J. and D.A. Peura, 1993. NSAIDS-associated gastrointestinal damage and the elderly. *Practical Gastroenterol.*, 17: 13-29.
3. Somerville, K., G. Faulkner and M. Langman, 1986. Non-steroidal anti-inflammatory drugs and bleeding peptic ulcer. *Lancet*, 1: 462-464.
4. Kauffman, G., 1989. Aspirin-induced gastric mucosal injury: lessons learned from animal models. *Gastroenterology*, 96: 606-614.
5. Granger, D.N., L.A. Hernandez and M.B. Grisham, 1986. Reactive oxygen metabolite: Mediators of cell injury in digestive system. *Viewpoints Dig. Dis.*, 18: 13-17.
6. Fajer, A., H.B. Carneiro and H. Oria, 1955. Effect of vitamin E on the incidence of gastric ulcers in rats on simplified diets. *Hospital (Brazil)*, 48: 543-548.
7. Howitt, M.K., C.C. Harvey and B.J. Meyer, 1958. Plasma tocopherol, hemolysis and dietary unsaturated lipid relationships in man. *Federation Proc.*, 17: 245-254.
8. Pihan, G., C. Regillo and S. Szabo, 1987. Free radicals and lipid peroxidation in ethanol or aspirin-induced gastric mucosal injury. *Dig. Dis. Sci.*, 32: 1395-1401.
9. Serbinova, E.A. and L. Packer, 1994. Antioxidant and biological activities of palm vitamin E. *Food Nutr. Bull.*, 15: 138-143.
10. Nafeeza, M.I., J. Kamsiah, B.A. Aminuddin, A. Marzuki, M.Z. Mazlam, M.R. Isa, A. Gapoor and A. Suriati. 1996. Effects of dietary palmvittee on alcohol induced ulcer in rats. *Gastroenterol. Hepatol.*, 11 (suppl 2): A55.
11. Nafeeza, M.I., J. Kamsiah, A. Aminuddin, A. Marzuki, W.K. Ng and M.T. Gapoor, 1999. Palm vitamin E and the healing of ethanol-induced gastric lesions. *Asia Pacific J. Clin. Nutr.*, 8: 258-262.
12. Kamsiah, J., N. Renuvathan, M.I. Nafeeza and M.T. Gapor, 1999. Comparative effect of palm vitamin E and Ramitidine on the healing of ethanol-induced gastric lesions in rats. *Int. J. Exp. Pathol.*, 80: 259-263.
13. Fauzee, A.M., J. Kamsiah, M.T. Gapor and M.I. Nafeeza, 2002. Comparative effects of a tocotrienol rich-fraction and tocopherol in aspirin induced gastric lesions in rats. *Asia Pacific J. Clin. Nutr.*, 11: 309-311.
14. Kamsiah, J., M.T. Gapor, M.I. Nafeeza and A.M. Fauzee, 2002. Effect of various doses of palm vitamin E and tocopherol on aspirin-induced gastric lesion in rats. *Int. J. Exp. Pathol.*, 83: 295-301.
15. Shay, H., C.H. David and M. Gruenstein, 1954. A quantitative method for measuring spontaneous gastric acid secretion in rat. *Gastroenterology*, 26: 906-913.
16. Ledwozyw, A., J. Michalak, A. Stepień and A. Kadiolka, 1986. The relationship between plasma triglycerides, cholesterol, total lipid and lipid peroxidation products during human atherosclerosis. *Clin. Chim. Acta.*, 155: 275-284.
17. Berry, C.N., M. Proteau and K.G. Lloyd, 1988. Sulphasalazine and PhCL28A inhibit the formation of ethanol-and phenylbutanole-induced rat gastric ulcer: Lack of involvement of endogenous prostaglandin? *Br. J. Pharmacol.*, 93: 465-472.
18. Kamsiah, J., N. Renuvathani, M.I. Nafeeza and M.T. Gapor, 1998. Improvement of gastric lesions index after treatment with palm vitamin E compared to ramitidine. *Asia Pacific J. Pharmacol.*, 13: 159-164.