



International Journal of Pharmacology

ISSN 1811-7775

science
alert

ansinet
Asian Network for Scientific Information

Chloroquine Phosphate Potentiates Indomethacin and HCl/Ethanol-Induced Gastric Mucosa Injury in Rats

¹K.O. Ajeigbe, ²E.O. Nwobodo, ¹T.O. Oyesola, ³D.A. Ofusori and ⁴S.B. Olaleye

¹Department of Physiology, School of Basic Medical Sciences,
Igbinedion University, Benin City, Nigeria

²Department of Physiology, Faculty of Medicine,
Nnamdi Azikiwe University, Nnewi, Nigeria

³Department of Anatomy, School of Basic Medical Sciences,
Igbinedion University, Benin City, Nigeria

⁴Department of Physiology, College of Medicine, University of Ibadan, Ibadan, Nigeria

Abstract: The aim of this study was to investigate the effect of Chloroquine phosphate (at therapeutic dose) on existing gastric ulceration in albino rats. Rats were treated with Chloroquine phosphate (8.5 mg kg^{-1}) intramuscularly for 24 h after formation of ulcers induced by acidified ethanol and indomethacin. Following sacrifice, colorimetric assays were applied to determine the concentration of protein and mucus, activities of catalase and lipid peroxidation in homogenized gastric mucosal samples. Chloroquine phosphate worsens gastric lesions produced by both indomethacin and acidified ethanol. Also, it seemed to elaborate the indomethacin and acidified ethanol induced effects on gastric juice volume, pH and acid output. On the other hand, thiobarbituric acid reactants (TBAR) was further increased and protein, catalase and mucus were decreased in the gastric mucosal samples. The data indicates that the use of Chloroquine may be dangerous to the integrity of the stomach, especially in existing gastric ulcers. It increases oxidative stress in the gastric mucosa caused by indomethacin and acidified ethanol.

Key words: Chloroquine phosphate, ulcer, oxidative stress, thiobarbituric acid reactive, catalase

INTRODUCTION

Chloroquine is a 4-aminoquinoline derivative used, particularly in the sub-Saharan Africa, as a cheap antimalarial and for the treatment of rheumatoid arthritis, lupus erythematosus and various inflammatory conditions (Onigbogi *et al.*, 2000).

In spite of reports of increasing resistance to it by *Plasmodium falciparum* Chloroquine still remains the most prescribed antimalarial medication in most Sub-Saharan African countries (Olliaro and Taylor, 2003). This may be due to its affordability and availability across the tropics. Also, misuse is widespread (White, 2004). Although well tolerated in most individuals, Chloroquine is associated with pruritus (Ajayi *et al.*, 1989; Onigbogi *et al.*, 2000).

Hypotension induced by parenteral administration of Chloroquine is a common and serious adverse effect of this drug. It stimulates the release of histamine, as evidenced in the cause of venodilation (Abiose *et al.*,

1997). Besides, it promotes attenuation of cyclic adenosine monophosphate (cAMP) and an increase in nitric oxide (NO) production in renal functions (Ahmed and Osman, 2007). Lysosomal dysfunction (Mahon *et al.*, 2004), aberrations in serum proteins and free amino acids (El-Sayed *et al.*, 1998) and various lipidemic effects (Gafaar *et al.*, 1995) are all Chloroquine's toxicological consequences on the retina.

Chloroquine stimulates gastric acid secretion (Etimita *et al.*, 2005), which may not be beneficial in peptic ulceration.

Peptic ulceration results from increased formation of Reactive Oxygen Species (ROS) and/or decreased antioxidant reserve in the gastric mucosa, a condition termed as oxidative stress.

Hence, its occurrence is associated with oxidative stress increases by pro-ulcerative factors in the gut like *Helicobacter pylori* (Yamaguchi and Kakizoe, 2001), use of Non steroidal anti-inflammatory drugs, NSAIDs (Rostom *et al.*, 2000), smoking (Ma *et al.*, 2000),

psychological stress (Mawdsley and Rampton, 2006), lead exposure (Olaleye *et al.*, 2007) and dietary intake of potential ulcerogens (Ibironke *et al.*, 1997).

From available literature, there seems to be a dearth of information on possible role of use and/or misuse of chloroquine in the etiology of gastric ulceration. We, therefore, present findings on the potentiation of gastric mucosa injury by therapeutic dose of chloroquine in albino rats.

MATERIALS AND METHODS

This study was carried out between July and August 2007 in the Department of Physiology, School of Basic Medical Sciences, Igbinedion University, Okada, Edo State, Nigeria.

Drugs: Chloroquine phosphate used were obtained from a local pharmacy duly registered by the Pharmacists' Council of Nigeria (PCN). Indomethacin was obtained from Strides, Belgium. All other reagents were of analytical grade and obtained from the British Drug Houses, Poole, UK.

Animals: Forty healthy adult albino rats of Wistar strain weighing between 180-220 g each were used in the study. The animals were housed under standard conditions of temperature ($23\pm 2^\circ\text{C}$), humidity ($55\pm 15\%$) and 12 h light (7.00 am-7.00 pm).

They were kept in wire meshed cages and fed with commercial rat pellets (Ladokun Feeds Ltd., Ibadan, Nigeria) and allowed water ad-libitum.

Treatment: The animals were divided into five groups with eight rats each. Group 1 was treated with normal saline after 36 h fasting. Group 2 was treated with indomethacin (40 mg kg^{-1}) orally after 36 h fasting. Group 3 was treated with 1.0 mL HCl/Ethanol mixture (0.15 N HCl in 70% ethanol). Group 4 and 5 received Chloroquine intramuscularly (8.5 mg kg^{-1}) 4 h after indomethacin and acidified ethanol administration.

Ulcer induction and index determination

Indomethacin induced ulceration: Indomethacin (Strides, Belgium) dissolved in sodium bicarbonate was administered orally (40 mg kg^{-1}) to 36 h fasted rats.

Four hours later (for the treated control) and 24 h later (for the experimental group), the animals were killed with ether anaesthesia. The stomachs were opened along the greater curvature, washed in normal saline to remove debris and pinned on a cork mat for ulcer scoring. This was done by locating the wounds in the glandular regions under a simple microscope. The lengths (mm) of all the elongated black-red lines parallel to the long axis of the

stomachs in the mucosa was measured. The ulcer index was calculated by adding the lengths of all the lesions in the glandular region of the stomach (Rifat-uz-Zaman *et al.*, 2004; Tanaka *et al.*, 1993). The wounds were assessed independently by three observers.

HCl/Ethanol induced ulceration: Thirty-six hours fasted rats were given 1.0 mL HCl/Ethanol mixture containing 0.15 N HCl in 70% ethanol (Anadan *et al.*, 1999). Four hours later (for the treated control) and 24 h later (for the experimental group), the animals were sacrificed under sodium pentobarbitone anaesthesia (60 mg kg^{-1} i.p.). The stomachs were removed, inflated with 10 mL of 2% formaldehyde for 10 min to fix the tissue walls and opened along the greater curvature. The hemorrhagic lesions were stretched out on a glass plate and their sizes were estimated using an underlying graph study with a 1 mm^2 grid. Lesions areas were summed up per stomach and expressed as % of the total mucosal area.

Gastric juice volume, pH and acid output: The four hour gastric juice collection was drained into a graduated test tube and centrifuged at 2000 rpm for 10 min. The supernatant volume and pH were recorded. The total acid content of the gastric juice was also determined by titration to pH 7.0 with 0.05 N NaOH, using phenolphthalein as indicator.

The protein content was also estimated as described by Lowry *et al.* (1951).

Determination of lipid peroxidation: Lipid peroxidation was assayed by measuring the thiobarbituric acid reactants (TBAR) products using the procedure of Walls *et al.* (1976). Briefly, the homogenate was supplemented with 0.75 g L^{-1} TBA in 0.1 mol L^{-1} HCl. The reactants were then supplemented with 5 mL n-butanol-pyridine mixture, shaken vigorously for 1 min and centrifuged for 10 min at 4000 rpm. Absorbance was then read at 532 nm and the results expressed as nmol TBA/100 mg wet tissue.

Determination of catalase activity: Activity of catalase in gastric mucosa was determined according to the procedure of Sinha (1972). This method is based on the reduction of dichromate in acetic acid to chromic acetate when heated in the presence of H_2O_2 , with the formation of perchromic acid as an unstable intermediate. The chromic acetate so produced is measured calorimetrically at 530 nm.

Determination of gastric mucous: Adherent gastric glandular mucous was measured by the method of Corne *et al.* (1974). The excised stomachs were soaked for 2 h in 0.1% Alcian blue dissolved in buffer solution

containing 0.1 M sucrose and 0.05 M Sodium acetate (pH adjusted to 5.8 with hydrochloric acid). After washing the stomach twice in 0.25 M sucrose (15 and 45 min), the dye complexed with mucous was eluted by immersion in 10 mL aliquots of 0.5 M MgCl₂ for 2 h. The resulting blue solution was shaken with equal volumes of diethyl ether and the optical density of the aqueous phase measured at 605 nM using a spectrophotometer.

Using a standard curve, the absorbance of each solution was then used to calculate the various concentration of the dye and the weight of dye (expressed in mg). The weight of the dye was then expressed over the weight of the stomach.

Statistical analysis: The data obtained were expressed as Means±SEM (Standard Error of Means of eight experiments) and analysed statistically by application of the Statistical Package for Social Sciences (SPSS).

The student's t-test was applied and p-values were determined. Differences were considered significant at p<0.05 and highly significant at p<0.001.

RESULTS AND DISCUSSION

Indomethacin and acidified ethanol causes increased gastric secretion volume and acid output, with significant

decreased gastric pH (Table 2, 4). Similarly, gastric ulcer lesions were formed by indomethacin and acidified ethanol in the experimental rats (Table 1, 3) (p<0.001). This is in agreement with the report of several authors on the role of indomethacin and acidified ethanol on gastric ulcer and erosion formation (Christopher *et al.*, 1998). Also, gastric mucous and protein were significantly decreased in the indomethacin (Table 1) and acidified ethanol (Table 2) treated gastric mucosa, which is not contradictory to the findings of Rao *et al.* (1997) and Desai *et al.* (1997).

Chloroquine administration on existing ulcer in the rat led to an increase in the ulcer index; 13.75±1.59 mm (when compared with 8.58±1.44 mm index of the indomethacin treated group) as shown in Table 1 (p<0.001) and 10.20±0.45% (when compared with 7.15±0.55% mucosa damage in the acidified ethanol treated group) as shown in Table 3 (p<0.05), with further decrease in barrier mucus and protein content of the gastric mucosa (Table 1, 3), p<0.05.

In addition, Chloroquine seemed to elaborate the gastric changes induced by indomethacin and acidified ethanol. This is depicted in Table 2 and 4.

Figure 1 and 2 show the lipid peroxidation and catalase activity in the ulcerated gastric mucosa after chloroquine treatment, expressed as percentage change

Table 1: Effects of chloroquine treatment on indomethacin-induced gastric mucosa injury in the rat

Groups	Treatments	Ulcer score (mm)	Gastric mucus (mg g ⁻¹)	Protein (mg g ⁻¹)
1	Saline	0.00	33.50±0.95	10.60±0.52
2	Indomethacin (40 mg kg ⁻¹)	8.58±1.44**	30.25±0.70*	8.20±0.15*
3	Indomethacin (40 mg kg ⁻¹)+Chloroquine (8.5 mg kg ⁻¹)	13.75±1.59**	26.00±0.65*	5.45±0.40*

Indomethacin: Highly significant from normal saline treated p<0.001**, significant p<0.05, Chloroquine: Highly significant from indomethacin treated p<0.001**, significant p<0.05*

Table 2: Gastric juice profile of saline, indomethacin and chloroquine treated rats

Groups	Treatments	Volume (mL)	pH	Acid output (×10 ⁴ mmol 4 h ⁻¹)
1	Saline	3.50±1.20	2.51±0.51	8.10±0.25
2	Indomethacin (40 mg kg ⁻¹)	6.20±0.75*	1.50±0.20*	11.05±0.16**
3	Indomethacin (40 mg kg ⁻¹)+Chloroquine (8.5 mg kg ⁻¹)	8.33±0.52*	1.10±0.27	13.56±0.10*

Indomethacin: Highly significant from normal saline treated p<0.001**, significant p<0.05*, Chloroquine: Highly significant from indomethacin treated p<0.001**, significant p<0.05*

Table 3: Effects of chloroquine treatment on acidified ethanol gastric mucosa injury in the rat

Groups	Treatments	Mucosal damage score (% of total mucosal area)	Gastric mucus (mg g ⁻¹)	Protein (mg g ⁻¹)
1	Saline	0.00	33.50±0.95	10.66±0.52
2	HCl/Ethanol	7.15±0.55**	30.50±0.65*	8.52±0.21*
3	HCl/Ethanol+Chloroquine (8.5 mg kg ⁻¹)	10.20±0.45*	25.46±0.11**	6.15±0.27*

Acidified ethanol: Highly significant from normal saline treated p<0.001**, significant p<0.05*, Chloroquine: Highly significant from acidified ethanol treated p<0.001**, significant p<0.05*

Table 4: Gastric juice profile of saline, acidified ethanol and chloroquine treated rats

Groups	Treatments	Volume (mL)	pH	Acid output (×10 ⁴ mmol 4 h ⁻¹)
1	Saline	3.50±1.20	2.71±0.57	8.10±0.25
2	HCl/Ethanol	8.35±1.05**	2.50±0.40	10.15±0.30**
3	HCl/Ethanol+Chloroquine (8.5 mg kg ⁻¹)	10.56±0.42*	1.20±0.20*	15.03±0.65**

Acidified ethanol: Highly significant from normal saline treated p<0.001**, Chloroquine: Highly significant from acidified ethanol treated p<0.001**, significant p<0.05*

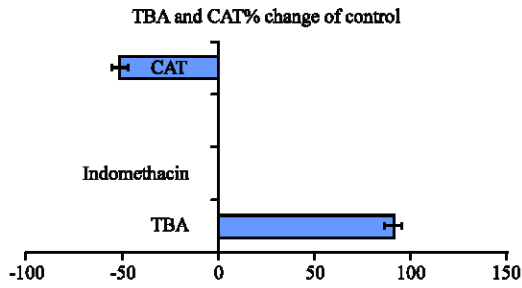


Fig. 1: TBA reactants and catalase activities in ulcerated (indomethacin) gastric mucosa treated with chloroquine. (Mean±SEM, n = 8) (p<0.05)

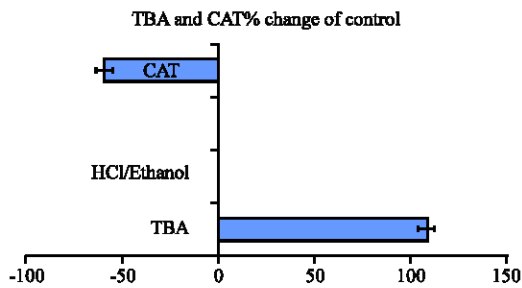


Fig. 2: TBA reactants and catalase activities in ulcerated (acidified ethanol) gastric mucosa treated with Chloroquine (Mean±SEM, n = 8) (p<0.05)

of the control value. Lipid peroxidation is measured as the amount of TBA reactants in the gastric mucosa. In the indomethacin treated control animals, it was 620 ± 71 mmol g⁻¹ tissue. Chloroquine significantly increased gastric TBA reactants level to $51.2 \pm 2.3\%$ of the control value. Similarly, in the acidified ethanol treated control animals lipid peroxidation was 640 ± 37 mmol g⁻¹ tissue, which was significantly increased on chloroquine administration to $110 \pm 10\%$ of the control value.

On the other hand, chloroquine administration further decreases gastric mucosal catalase activity to $49.5 \pm 5.1\%$ of indomethacin-treated control value and $60.5 \pm 2.5\%$ of acidified ethanol treated control value.

The results of this study show a kind of relationship between the use of antimalarials and gastric ulceration.

Chloroquine phosphate, the first line defense synthetic drug in Nigeria and many African countries because of its commonality and cheap status, (Gustafsson *et al.*, 1983), is observed to aggravate the existing ulcer in the stomach of the rat. Previous studies have shown that it caused significant increase in gastric acid secretion (Etimita *et al.*, 2005), one of the risk factors in the development of ulcer. This is also, confirmed by the increase in acid output observed in the present study. It

is well known that gastric acid secretion plays a role in gastric ulcer; which explains the mechanism of action of many anti-ulcer drugs (Schmassmann, 1998).

Lipid peroxidation, a result of the reaction of oxyradicals and polyunsaturated fatty acids, has been implicated in the etiology of damage to subcellular membranes and then injury in the cell.

In the present study, lipid peroxidation, as measured by the amount of TBA reactants, was increased on chloroquine administration. This implies that chloroquine causes an increase in the formation of free radicals, which, if not mopped up by free radical scavengers such as superoxide dismutase, catalase, or glutathione, will expose the stomach to inflammation.

Moreover, indomethacin and acidified ethanol has been known to cause lipid peroxidation (Kapui *et al.*, 1993; Anadan *et al.*, 1999), with depletion of endogenous antioxidants. The result of this study also showed a further significant decrease in barrier mucous and glandular protein level in the ulcerated gastric mucosa treated with chloroquine. This may not be unconnected with the low level of CAT observed in the study.

Gastrointestinal wall integrity is known to be controlled by two opposing forces: Defensive forces and the aggressive force (Corne *et al.*, 1974). The defensive force are gastro protective and involve antioxidative enzymes; SOD which catalyses the dismutation of superoxide radical anion (O₂⁻) into less noxious hydrogen peroxide (H₂O₂) and CAT or glutathione peroxidase that inactivate H₂O₂ by the degradation into water (Masuda *et al.*, 1995). Depletion of CAT, as evidenced in this study underscore the predisposition of stomach to a greater impact of free radicals produced through increased lipid peroxidation. However, further studies are still needed to investigate the role of other anti-oxidative enzymes in the aggravation of existing ulcers by Chloroquine.

In conclusion, the results of the present study show that there is potentiation of ulceration in the stomach of rats treated with Chloroquine phosphate. If these findings are extrapolated to man, they suggest that indiscriminate and unguided use of Chloroquine by peptic ulcer-prone individuals, may be dangerous.

REFERENCES

- Abiose, A.K., M. Grossman, O. Tangphao, B.B. Hoffman and T.F. Blaschke, 1997. Chloroquine-induced venodilation in human hand veins. Clin. Pharmacol. Ther., 61: 677-683.

- Ahmed, M.H. and M.M. Osman, 2007. Why does chloroquine impair renal function? Chloroquine may modulate the renal tubular response to vasopressin either directly by inhibiting cyclic AMP generation, or indirectly via nitric oxide. *Med. Hypotheses*, 68: 140-143.
- Ajayi, A.A., A. Oluokun, O. Sofowora, A. Akinleye and A.T. Ajayi, 1989. Epidemiology of antimalaria induced pruritus in Africans. *Eur. J. Clin. Pharmacol.*, 37: 539-540.
- Anadan, R., R.D. Rekha, N. Saravanan and T. Devaki, 1999. Protective effects of *Picrorrhiza kurroa* against HCl/ethanol induced ulceration in rats. *Fitoterapia*, 70: 498-503.
- Christopher, J.S., Z. Yan, M. Carol, M. Koboldt and S.Z. Ben *et al.*, 1998. Pharmacological analysis of cyclo-oxygenase 1 in inflammation. *Proc. Natl. Acad. Sci. USA.*, 95: 13313-13318.
- Corne, S.J., S.M. Morrissey and R.J. Woods, 1974. A method for the quantitative estimation of gastric barrier mucus. *J. Physiol.*, 242: 116-117.
- Desai, J.K., R.K. Goal and N.S. Parmar, 1997. Pathogenesis of peptic ulcer disease and current trends in therapy. *Indian J. Physiol. Pharmacol.*, 41: 3-15.
- El-Sayed, N.K., L.R. Abdel-Khalek and K.M. Gaafar, 1998. Profiles of serum proteins and free amino acids associated with chloroquine retinopathy. *Acta Ophthalmol. Scand.*, 76: 422-430.
- Etimita, Y.O., S.A. Bisong, A.B. Antai, C.O. Nku and E.E. Osim, 2005. Preliminary studies on effect of Chloroquine phosphate on gastric acid secretion in rats. *Nigeria J. Physiol. Sci.*, 20: 69-73.
- Gaafar, K.M. L.R. Abdel-Khalek and N.K. El-Sayed, 1995. Lipidemic effect as a manifestation of chloroquine retinotoxicity. *Arzneimittelforschung*, 45: 1231-1235.
- Gustafsson, L.I., O. Walker, G. Alvan, B. Beermann and F. Esterverz *et al.*, 1983. Disposition of chloroquine in man after single intravenous and oral dose. *Br. J. Clin. Pharmacol.*, 15: 471-479.
- Ibironke, G.F., S.B. Olaleye, O. Balogun and D.A. Aremu, 1997. Effects of diets containing seeds of *Garcinia kola* (Heckel) on gastric acidity and experimental ulceration in rats. *Phytotherapy Res.*, 11: 312-313.
- Kapui, Z., K. Boer, I. Rozsa, G.Y. Blasko and I. Hermeicz, 1993. Investigations of indomethacin-induced gastric ulcer in rats. *Arzneim-Forsch/Drug Res.*, 43: 767-771.
- Lowry, O.H., N.J. Rosebrough, A.C. Larr and R.I. Randall, 1951. Protein measurement with the folin phenol reagent. *J. Biol. Chem.*, 193: 265-275.
- Ma, L., W.P. Wang, J.Y. Chow, S.T. Yuen and C.H. Cho, 2000. Reduction of EDF is associated with the delay of ulcer healing by cigarette smoking. *Am. J. Physiol. Gastrointest. Liver Physiol.*, 278: G10-G17.
- Mahon, G.J., H.R. Anderson and T.A. Gardiner, 2004. Chloroquine causes lysosomal dysfunction in neural retina and RPE: Implications for retinopathy. *Curr. Eye Res.*, 28: 277-284.
- Masuda, E., S. Kawano, K. Nagano, S. Tsuji and Y. Takei *et al.*, 1995. Endogenous nitric oxide modulates ethanol-induced gastric mucosal injury in rats. *Gastroenterology*, 108: 58-64.
- Mawdsley, J.E. and S. Rampton, 2006. The role of psychological stress in inflammatory bowel disease. *Neuroimmunomodulation*, 13: 327-336.
- Olaleye, S.B., O.A. Adaramoye, P.P. Erigbali and O.S. Adeniyi, 2007. Lead increase oxidative stress in the gastric mucosa of HCl/Ethanol exposed rats. *World J. Gastroenterol.*, 13: 5121-5126.
- Olliaro, P.L. and W.R.J. Taylor, 2003. Antimalarial compounds: From bench to bedside. *J. Exp. Biol.*, 206: 3753-3759.
- Onigbogi, O., A.A. Ajayi and O.E. Ukponwan, 2000. Mechanism of chloroquine induced body-scratching behaviour in rats, evidence of involvement of endogenous opioid peptides. *Pharmacol. Biochem. Behav.*, 65: 333-337.
- Rao, V.S., F.A. Santos, T.T. Sobrierra, M.F. Souza and C.L. Melo *et al.*, 1997. Investigations on the gastroprotective and antiarrhoeal properties of Ternatin, a tetramethoxy flavones from *Egletes viscoso*. *Planta Medica*, 63: 146-149.
- Rifat-uz-Zaman, M.S. Akhtar and M.S. Khan, 2004. Gastroprotective and antisecretory effect of *Nigella sativa* and its extracts in indomethacin treated rats. *Pak. J. Biol. Sci.*, 7: 995-1000.
- Rostom, A., G. Wells, P. Tugwell, V. Welch, C. Dube and J. McGowon, 2000. Prevention of chronic NSAID induced upper gastrointestinal toxicity. *Cochrane Database Syst. Rev.*
- Schmassmann, A., 1998. Mechanisms of ulcer healing and effects of nonsteroidal anti-inflammatory drugs. *Am. J. Med.*, 104: 43S-51S.
- Sinha, A.K., 1972. Colorimetric assay of catalase. *Anal. Biochem.*, 47: 389-394.
- Tanaka, T., Y. Morioka and U. Gebert, 1993. Effect of a novel Xanthenes derivative on experimental ulcers in rats. *Arzneim-Forsch/Drug Res.*, 43: 558-562.
- Walls, R., K.S. Kumar and P. Hochstein, 1976. Aging human erythrocytes, Differential sensitivity of young and old erythrocytes to hemolysis induced by peroxide in the presence of thyroxine. *Arch. Biochem. Biophys.*, 174: 463-468.
- White, N.J., 2004. Antimalaria drug resistance. *J. Clin. Investigat.*, 113: 1084-1092.
- Yamaguchi, N. and T. Kakizoe, 2001. Synergistic interaction between *Helicobacter pylori* and gastric cancer. *Lancet Oncol.*, 2: 88-94.