



International Journal of Pharmacology

ISSN 1811-7775

science
alert

ansinet
Asian Network for Scientific Information

Hepatoprotective Activity of *Coccinia grandis* Leaves Against Carbon Tetrachloride Induced Hepatic Injury in Rats

^{1,2}J. Anbu Jeba Sunilson, ^{1,2}M. Muthappan, ¹Amitava Das, ¹R. Suraj,
¹R. Varatharajan and ¹P. Promwichit

¹School of Pharmacy, Masterskill University College of Health Sciences,
Taman Kemacahaya 11, Jalan Kemacahaya, Cheras, Selangor, Malaysia

²Honorary Associate, School of Pharmacy, La Trobe University,
Bendigo, Victoria 3552, Australia

Abstract: *Coccinia grandis* Linn. (Cucurbitaceae) is a perennial branched handsome tendril climber, distributed through out India. It has been used in folk medicine for the treatment of jaundice. The aim of this work was to study the hepatoprotective effect of crude ethanolic and aqueous extracts from the leaves of *C. grandis* against liver damage induced by CCl₄ in rats. The ethanolic extract at an oral dose of 200 mg kg⁻¹ exhibited a significant (p<0.05) protective effect as shown by lowering serum levels of glutamic oxaloacetic transaminase, glutamic pyruvic transaminase, alkaline phosphatase, total bilirubin and total cholesterol and increasing levels of total protein and albumin levels as compared to silymarin, the positive control. These biochemical observations were supported by histopathological examination of liver sections. The activity may be due to the presence of flavonoid compounds. The extracts showed no signs of acute toxicity up to a dose level of 2000 mg kg⁻¹. Thus it could be concluded that ethanolic extract of *C. grandis* leaves possesses significant hepatoprotective activity.

Key words: Indian traditional medicine, extracts, protective, Cucurbitaceae, silymarin

INTRODUCTION

Liver plays a major role in detoxification and excretion of many endogenous and exogenous compounds. Any impairment to its functions may lead to many implications on one's health. Management of liver diseases is still a challenge to the modern scientific community (Reddy *et al.*, 1992). Modern medicine has little to offer alleviation of hepatic ailments. Phytoconstituents remain to be a major contributor in the treatment of liver disorders. The growing concern for the identification of novel hepatoprotective agents from natural sources is evident from literature available on the same. The hepatoprotective activity of *Amaranthus spinosus* (Zeashan *et al.*, 2008), *Hibiscus ecculentus* Linn. (Sunilson *et al.*, 2008) and *Vitex negundo* leaf extract (Tandon Vishal *et al.*, 2008) are reported in the literature. The study of hepatoprotective role of pomegranate flowers (Celik *et al.*, 2009), Bacoside-A, a major constituent of *Bacopa monniera* (Sumathi and Nongbri, 2008) and aqueous extract of *Solanum fastigiatum* (Sabir and Rocha, 2008) bears further testimony to the quest of natural hepatoprotective agents.

Recent scientific studies revealed that the plants *Trichosanthes cucumerina* (Kumara *et al.*, 2009) and *Cucurbita pepo* L. (Makni *et al.*, 2008) both belonging to the Cucurbitaceae family possessed significant hepatoprotective activity. *Coccinia grandis* Linn, also, belonging to the family Cucurbitaceae and commonly known as kovai in tamil, is a perennial much branched handsome tendril climber, cultivated throughout India and also found wild. The medicinal use of the plant can be traced to ancient period where the juice of the roots and leaves were used in the treatment of diabetes mellitus, bronchitis, skin diseases, tongue-sores and ear ache (Geetu *et al.*, 2007). The fruit is commonly eaten in Indian cuisine. The plant is ethnomedically used as anti inflammatory, wound healing, purgative, antiemetic, antiulcer, antipyretic anticonvulsant and astringent (Warrier *et al.*, 1995) and is traditionally used to treat jaundice by the people of Tirunelveli district, Tamil Nadu state. Literature survey revealed that few works have been carried out on this plant. The fruits have been reported to possess hepatoprotective activity (Vadivu *et al.*, 2008). However, there has been no report on the hepatoprotective activity of the leaves of this plant. The

present study was thus undertaken to scientifically prove the activity of the leaves against liver disorders.

MATERIALS AND METHODS

Plant material: Leaves of *Coccinia grandis* were collected from Kadayanallur, Tirunelveli District of Tamilnadu, India, in July 2005. The plant sample was authenticated by Dr. P. Jayaraman, M.Sc., Ph.D., Director, Plant Anatomy Research Center, Chennai, Tamil Nadu, India. A voucher specimen of the collected plant sample was also deposited in the Herbarium of Sankaralingam Bhuvaneswari College of Pharmacy, Sivakasi, Tamil Nadu (SBCPHA/C12/M 0014).

Preparation of extracts: The shade dried leaves of *C. grandis* (500 g) were subjected to size reduction to coarse powder. The powder was defatted with petroleum ether (60-80°C) and then extracted with 95% ethyl alcohol using soxhlet apparatus (Bose *et al.*, 2007) till exhaustion for about 32 h. The total aqueous extract was also prepared by the percolation method (Bugno *et al.*, 2007) using water. Both the ethanolic and aqueous extracts were concentrated under vacuum to get the residues. The percentage yields of ethanolic extract and aqueous extracts were found to be 16.3% (w/w) and 22.13% (w/w), respectively. The ethanolic extract was found to contain glycosides, triterpenoids, alkaloids and flavonoids (Wagner and Bladt, 1996). Silymarin was used as a positive control at an oral dose of 20 mg kg⁻¹ (Savita *et al.*, 1994). All the test suspensions are prepared in vehicle, i.e., Tween-80.

Animals: Wistar albino rats of either sex, weighing 200-250 g, were obtained from the animal house of the S.B. College of Pharmacy, Tamilnadu, India. The animals were housed in groups of 6, in standard cages, at room temperature (25±3°C), with 12h dark/12h light cycles, food and water *ad libitum*. Twelve hours prior to the experiments they were transferred to the laboratory and given only water *ad libitum*. The experiments were approved by the Institutional Animal Ethical Committee of the S.B. College of Pharmacy, Tamilnadu, India (IAEC NO.SBCP/F.9 (f)/34b).

Toxicity studies: Acute toxicity study was performed for ethanolic and aqueous extracts in albino rats as per OECD guidelines. The animals were fasted overnight and provided only water, after which the extracts were administered orally at the dose of 300 mg kg⁻¹ and observed for 14 days. If mortality was observed in 2 out of 3 animals, the dose administered was assigned as

the toxic dose. If the mortality was observed in 1 animal, the same dose was repeated again to confirm the toxic dose. If mortality was not observed, the procedure was repeated for a higher dose, i.e., 2000 mg kg⁻¹. One-tenth of the maximum dose of the extract tested for acute toxicity was selected for evaluation of hepatoprotective activity, i.e., 200 mg kg⁻¹ (Handa and Sharma, 1990).

Carbon tetrachloride-induced hepatotoxicity in rats: Rats were divided into 5 groups of 6 each, the control, CCl₄-exposed, silymarin and two test groups. The control group received oral vehicle treatment at 0, 24 and 48 h. The animals in CCl₄-treated group received vehicle at 0 h and at 24 h, followed by CCl₄ diluted with liquid paraffin (1:1, i.p.) at a dose of 1.25 mL kg⁻¹, while at 48 h, these animals received only vehicle. The test groups have received the first dose of extracts at 0 h, the second dose of extracts at 24 h, which was followed by a dose of CCl₄ and the third dose of extracts at 48 h (Kumar and Mishra, 2005). The positive control group had received the first dose of silymarin (20 mg kg⁻¹) at 0 h; at 24 h, the second dose of silymarin followed by a dose of CCl₄ and at 48 h, the third dose of silymarin. After 72 h, blood was collected from all the groups sino-orbital puncture and allowed to clot for the separation of serum. The serum was used for estimation of biochemical parameters.

Glutamic oxaloacetic transaminase (SGOT) and Glutamic pyruvic transaminase (SGPT) were estimated by the method followed by Rajkapoor *et al.* (2006), alkaline phosphatase (ALKP) by the method of McComb and Bowers (1972), total bilirubin (TBL) by the method followed by Rana *et al.* (2008), total cholesterol (CHL) by the method of Richmond (1973), total protein (TPTN) by the method followed by Peters (1968) and white albumin (ALB) was estimated by Webster (1974) method. All the determinations were carried out using standard kits by an autoanalyser (300 TX, E. Merck-Micro Labs, Mumbai).

Histopathological studies: One animal from each of the treated groups showing maximum activity as indicated by improved biochemical parameters was used for this purpose. The animals were sacrificed and the abdomen was cut open to remove the liver. The liver was fixed in Bouin's solution (mixture of 75 mL of saturated picric acid, 25 mL of 40% formaldehyde and 5mL of glacial acetic acid) for 12 h and then embedded in paraffin using conventional methods (Galigher and Kozloff, 1971). They were then cut into 5 µm thick sections and stained using haematoxylin-eosin dye and finally mounted in diphenylxylene. The sections were observed under a microscope for histopathological changes in liver architecture and their photomicrographs were taken.

Statistical analysis: The Mean±SEM were calculated for each parameter. The statistical analysis of the results was carried out with a SPSS 9.0 program and based on an Analysis of Variance (ANOVA) followed by the Dunnet's test.

RESULTS AND DISCUSSION

The ethanolic and aqueous extracts did not produce any mortality up to 2000 mg kg⁻¹ and were considered as safe (OECD, 1998). Carbon tetrachloride (CCl₄) intoxication in normal rats elevated the levels of SGOT, SGPT, ALKP, TBL and CHL, whereas the levels of TPTN and ALB were observed significantly decreased indicating acute hepato cellular damage and biliary obstruction (Table 1, Fig. 2).

The rats treated with ethanolic extract of *C. grandis* and silymarin, experienced a significant decrease in the levels of SGOT, SGPT, ALKP, TBL and CHL which were elevated after administration of CCl₄, while a significant increase in TPTN and ALB levels were observed in these animals (Table 1). The rats treated with the aqueous extract showed significant decrease in the levels of SGOT and CHL and an increase in the levels of ALB. Histopathological examination of liver sections of the control group showed normal cellular architecture with distinct hepatic cells, sinusoidal spaces and a central vein (Fig. 1). Disarrangement of normal hepatic cells with intense centrilobular necrosis and vacuolization of periportal vein was observed in liver of CCl₄-intoxicated rats (Fig. 2). The liver sections of the rat treated with ethanolic extract and intoxicated with CCl₄ (Fig. 3), showed less vacuole formation and absence of necrosis and no visible changes were observed as compared to silymarin (Fig. 5), which further corroborated the protective effect of the extract. Although, liver sections of rats treated with aqueous extract and intoxicated with CCl₄ (Fig. 4) showed less visible changes, it was not as prominent as that of ethanol extract-treated rat sections.

In Indian system of medicine certain herbs are claimed to provide relief against liver disorders. The claimed therapeutic reputation has to be verified in a scientific manner. In the present study, the leaves of one such herb *Coccinia grandis* was taken for the evaluation

of hepatoprotective activity. The ethanolic extract of *Coccinia grandis* leaves possessed significant (p<0.05) hepatoprotective effect in the CCl₄ model of intoxication in rats. Preliminary phytochemical investigation on the extracts showed the presence of glycosides, triterpenoids, alkaloids and flavonoids in the ethanolic extract. According to these results, it may be hypothesized that flavonoids, which are present in the ethanolic extract, could be responsible for the hepatoprotective activity. The hepatotoxicity of CCl₄ has been attributed to the formation of the highly reactive trichloromethyl free radicals, which attack polyunsaturated fatty acids. CCl₄ produces hepatotoxicity by altering the liver microsomal membranes in experimental animals (Ashok *et al.*, 2001). The effect of CCl₄ is generally observed after 24 h of its administration. Hence, the withdrawal of blood for biochemical parameters should be carried out only after 24 h of CCl₄ intoxication.

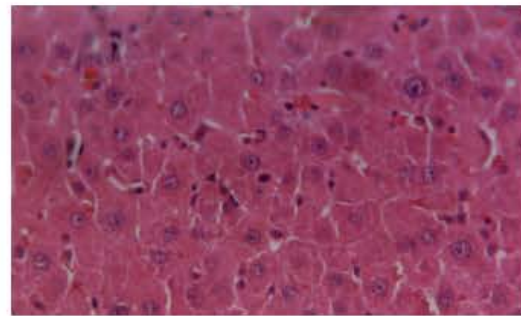


Fig. 1: Normal rat liver section

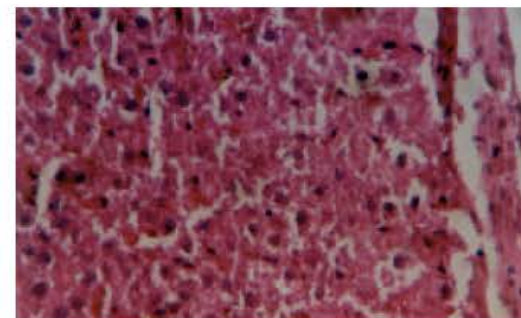


Fig. 2: Liver section of rat intoxicated with CCl₄

Table 1: Effect of oral administration of *Coccinia grandis* on CCl₄-induced liver damage in rats

Groups	SGOT	SGPT	ALKP	TBL	CHL	TPTN	ALB
	(IU L ⁻¹)			(mg dL ⁻¹)		(g dL ⁻¹)	
Control	70.20±3.62	48.20±0.38	342.01±5.78	0.38±0.01	76.28±1.18	7.58±0.13	3.38±0.12
CCl ₄	487.78±5.72	382.01±2.32	471.02±7.26	2.62±0.02	32.86±2.39	4.78±0.39	1.92±0.78
Silymarin	102.30±1.23*	62.32±0.17*	351.28±4.72*	0.32±0.002*	68.42±3.99**	6.98±0.23**	2.76±0.32**
Aqueous extract	158.20±3.2*	223.18±4.78	398.47±9.83	1.48±0.04	60.91±2.22**	5.23±0.96	2.32±0.28**
Ethanol extract	114.81±2.72*	85.61±1.37*	362.02±3.68*	0.56±0.01*	65.81±1.56**	6.12±0.46**	2.52±0.13**

V values are Mean±SEM. *Significant reduction compared to CCl₄ (p<0.05). **Significant increase compared to CCl₄ (p<0.05)

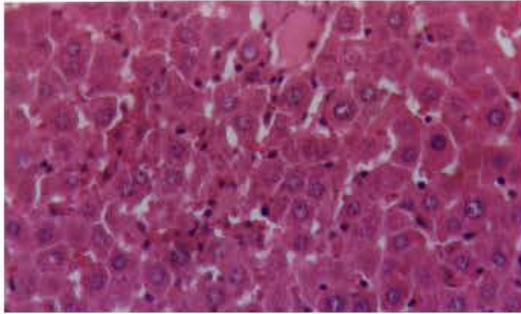


Fig. 3: Liver section of rat treated with ethanolic extract and intoxicated with CCl₄

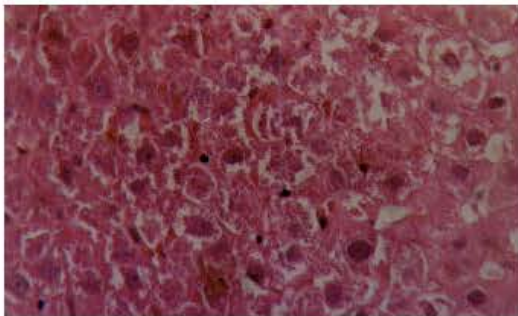


Fig. 4: Liver section of rat treated with aqueous extract and intoxicated with CCl₄

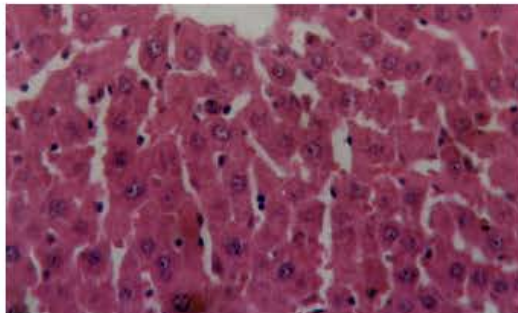


Fig. 5: Liver section of rat treated with silymarin and intoxicated with CCl₄

From Table 1 it is evident that the ethanolic extract of *C. grandis* was able to reduce all biochemical parameters that were elevated by CCl₄. CCl₄ reduced the levels of total proteins and albumin. were reduced due to the CCl₄ intoxication. The reduction is attributed to the damage produced and is probably localised in the endoplasmic reticulum with resulting loss of P₄₅₀ leading to functional

failure and a decrease in protein synthesis and the accumulation of triglycerides. Intoxication with CCl₄ also, resulted in inhibition of bile acids synthesis from cholesterol which is synthesized in liver or derived from plasma lipids, leading to an increase in cholesterol levels. Suppression of cholesterol levels by CCl₄ suggests the inhibition of the synthesis of bile acids from cholesterol which was reversed by the extract. A reduction in the levels of SGOT and SGPT towards the normal value is an indication of revival of plasma membrane as well as repair of hepatic tissue damage caused by CCl₄. A reduction of ALKP levels with concurrent decrease in the raised bilirubin level suggests the stabilization of biliary function which had been adversely affected by injury due to CCl₄. Protein and albumin levels were raised by the extract suggesting the stabilization of endoplasmic reticulum leading to protein synthesis.

The protective effect exhibited by the ethanolic extract was similar to that due to silymarin treatment. Histological examination of the liver sections revealed that the normal liver architecture was disturbed by hepatotoxin intoxication. In the sections obtained from the rats treated with ethanolic extract and intoxicated with CCl₄, the normal cellular architecture was retained as compared to silymarin, thereby confirming the protective effect of the extract. Although, the less visible changes were observed in the liver sections of the rats intoxicated with CCl₄ and subsequently treated with aqueous extract (200 mg kg⁻¹) and intoxicated with CCl₄, the intensity was less compared to ethanolic extract-treated rat sections. Most of the previous studies are reported on the hepatoprotective activity of the fruits of *C. grandis* (Vadivu *et al.*, 2008; Swamy *et al.*, 2007). The only literature available for the same activity using the leaves extract is reported by Umamaheswari and Tapan Kumar (2008), in which the hepatic damage is induced in mice using Paracetamol (2 g kg⁻¹). However, in the present study the hepatotoxicity was induced by CCl₄, in which the changes associated with liver damage are similar to that of acute viral hepatitis (Sreelatha *et al.*, 2009). The ethanolic extract of *C. grandis* leaves at a dose of 200 mg kg⁻¹ showed significant hepatoprotective activity in the latter model. Preceding studies revealed the presence of Cucurbitacin glucosides in members of the Cucurbitaceae family and are well known for its hepatoprotective activity (Tehila *et al.*, 2007) which may support the findings of our study. The results obtained validate the folklore claim of the plant being used for the treatment of jaundice.

CONCLUSION

From this investigations it is evident that, the ethanolic extract of the leaves of *Coccinia grandis*

possessed significant hepatoprotective activity against CCl₄ intoxication in rats. Further detailed studies may confirm the utility profile of this drug.

ACKNOWLEDGMENTS

Authors are grateful to Dato Prof. Dr. Ishak Bin Tambi Kechik, Vice Chancellor and Dato. Edmund Santhara, CEO, Masterskill University College of Health Sciences, Malaysia, for their encouragement and support.

REFERENCES

- Ashok, S.K., S.N. Somayaji and K.L. Bairy, 2001. Hepatoprotective effects of *Gingko biloba* against carbon tetrachloride induced hepatic injury in rats. *Ind. J. Pharmacol.*, 33: 260-266.
- Bose, A., S. Sumanta, G. Jayanta Kumar, G. Tirtha, D. Gouri Kumar and S. Sudam, 2007. Analgesic, anti-inflammatory and antipyretic activities of the ethanolic extract and its fractions of *Cleome rutidosperma*. *Fitoterapia*, 78: 515-520.
- Bugno, A., N. Maria Aparecida, A.B. Adriana Almodóvar, C. Tatiana Pereira and T. Mariângela Auricchio, 2007. Antimicrobial efficacy of *Curcuma zedoaria* extract as assessed by linear regression compared with commercial mouthrinses. *Braz. J. Microbiol.*, 38: 3-3.
- Celik, I., T. Atilla and I. Ismail, 2009. Hepatoprotective role and antioxidant capacity of pomegranate (*Punica granatum*) flowers infusion against trichloroacetic acid-exposed in rats. *Food Chem. Toxicol.*, 47: 145-149.
- Galigher, A.E. and E.N. Kozloff, 1971. *Essentials of Practical Micro Technique*. 2nd Edn., Lea and Febiger, New York.
- Geetu, S., G. Prasoon, R. Preeti, P. Anju, B. Gitika and M. Rakesh, 2007. Antidyslipidemic activity of polyphenol from *Coccinia grandis* in high-fat diet-fed hamster model. *Phytomedicine*, 14: 792-798.
- Handa, S.S. and A. Sharma, 1990. Hepatoprotective activity of andrographolide from *Andrographis paniculata* against carbon tetrachloride. *Ind. J. Med. Res.*, 92: 276-283.
- Kumar, S.V.S. and S.H. Mishra, 2005. Hepatoprotective activity of rhizomes of *Cyperus rotundus* Linn. against carbon tetrachloride induced hepatotoxicity. *Ind. J. Pharm. Sci.*, 67: 84-88.
- Kumara, S.S., B.R. Kumara and G.K. Mohan, 2009. Hepatoprotective effect of *Trichosanthes cucumerina* var. *cucumerina* L. on carbon tetrachloride induced liver damage in rats. *J. Ethnopharmacol.*, 10.1016/j.jep.2009.02.023.
- Makni, M., H. Fetoui, N.K. Gargouri, El M. Garoui, H. Jaber, J. Makni, T. Boudawara and N. Zeghal, 2008. Hypolipidemic and hepatoprotective effects of flax and pumpkin seed mixture rich in α -3 and α -6 fatty acids in hypercholesterolemic rats. *Food Chem. Toxicol.*, 46: 3714-3720.
- McComb, R.B. and G.N. Bowers, 1972. Study of optimum buffer conditions for measuring alkaline phosphatase activity in human serum. *Clin. Chem.*, 18: 97-104.
- OECD., 1998. Ninth Addendum to the OECD Guidelines for the Testing of Chemicals. Acute Oral Toxicity, USA.
- Peters, T., 1968. Proposals for standardization of total protein assays. *Clin. Chem.*, 14: 1147-1159.
- Raj Kapoor, B., B. Jayakar, N. Muruges and D. Sakthisekaran, 2006. Chemoprevention and cytotoxic effect of *Bauhinia variegata* against N-nitrosodiethylamine induced liver tumors and human cancer cell lines. *J. Ethnopharmacol.*, 104: 407-409.
- Rana, M.G., R.V. Katbamna, A.V. Dudhrejiya and N.R. Sheth, 2008. Hepatoprotection of *Tecomella undulata* against experimentally induced liver injury in rats. *Pharmacologyonline*, 3: 674-682.
- Reddy, B.P., C.K. Kokate, D. Rambhau, V. Venkateshwarlu and V.N. Murthy, 1992. Antihepatotoxic activity of some ayurvedic preparations. *Ind. J. Pharm. Sci.*, 55: 137-140.
- Richmond, W., 1973. Preparation and properties of a cholesterol oxidase from *Nocardia* sp. and its application to the enzymatic assay of total cholesterol in serum. *Clin. Chem.*, 19: 1350-1356.
- Sabir, S.M. and J.B.T. Rocha, 2008. Antioxidant and hepatoprotective activity of aqueous extract of *Solanum fastigiatum* (false Jurebeba) against paracetamol-induced liver damage in mice. *J. Ethnopharmacol.*, 120: 226-232.
- Savita, S., K. Arvind, S. Srivastava, G.K. Patnaik and S.B.N. Dhawan, 1994. Effect of picroliv and silymarin on liver regeneration in rats. *Ind. J. Pharmacol.*, 26: 19-22.
- Sreelatha, S., P.R. Padma and M. Umadevi, 2009. Protective effects of *Coriandrum sativum* extracts on carbon tetrachloride-induced hepatotoxicity in rats. *Food Chem. Toxicol.*, 47: 702-708.
- Sumathi, T. and A. Nongbri, 2008. Hepatoprotective effect of Bacoside-A, a major constituent of *Bacopa monniera* Linn. *Phytomedicine*, 15: 901-905.
- Sunilson, J., J. Anbu, P. Jayaraj, M. Syam Mohan, A. Anita Gna Kumari and R. Varatharajan, 2008. Antioxidant and hepatoprotective effect of the roots of *Hibiscus esculentus* Linn. *Int. J. Green Pharmacy*, 2: 200-203.

- Swamy, B.M.V., G.S. Kumar, S.I. Shiva kumar, H.M. Suresh, U. Rajashekar and C. Sreedhar, 2007. Evaluation of hepatoprotective effects of *Coccinia grandis* Linn. Against Carbon Tetrachloride Induced Liver Damage in Wistar Rat. *Asian J. Chem.*, 19: 2550-2554.
- Tandon Vishal, R., V. Khajuria, B. Kapoor, D. Kour and S. Gupta, 2008. Hepatoprotective activity of *Vitex negundo* leaf extract against anti-tubercular drugs induced hepatotoxicity. *Fitoterapia*, 79: 533-538.
- Tehila, T.S., B. Margalit and G. Shlomo, 2007. Curcubitacin glucosides: Antioxidant and free-radical scavenging activities. *Biochem. Biophys. Res. Commun.*, 364: 181-186.
- Umamaheswari, M. and C. Tapan Kumar, 2008. Hepatoprotective and Antioxidant Activities of the Fractions of *Coccinia grandis* against Paracetamol-induced Hepatic Damage in Mice. *Int. J. Biomed. Pharmaceut. Sci.*, 2: 103-107.
- Vadivu, R., A. Krithika, C. Biplab, P. Dedeepya, N. Shoeb and K.S. Lakshmi, 2008. Evaluation of hepatoprotective activity of the fruits of *Coccinia grandis* Linn. *Int. J. Health Res.*, 1: 163-168.
- Wagner, H. and S. Bladt, 1996. *Plant Drug Analysis: A Thin Layer Chromatography*. 2nd Edn. Springer, Verlag, Inc. Atlas, New York.
- Warrier, P.K., V.P.K. Nambiar and C. Ramakutty, 1995. *Indian Medicinal Plants: A Compendium of 500 Species*. Vol. 4, Orient Longman Publication, Hyderabad, India.
- Webster, D., 1974. A study of the interaction of bromocresol green with isolated serum globulin fractions. *Clin. Chim. Acta*, 53: 109-115.
- Zeashan, H., G. Amresh, R. Chandana Venkateswara and S. Satyawar, 2008. Hepatoprotective activity of *Amaranthus spinosus* in experimental animals. *Food Chem. Toxicol.*, 46: 3417-3421.