



International Journal of Pharmacology

ISSN 1811-7775

science
alert

ansinet
Asian Network for Scientific Information

Hepatoprotective Effects of African Locust Bean (*Parkia clappertoniana*) and Negro Pepper (*Xylopia aethiopica*) in CCl₄-Induced Liver Damage in Wistar Albino Rats

K.C. Patrick-Iwuanyanwu, M.O. Wegwu and J.K. Okiyi
Toxicological Unit, Department of Biochemistry, University of Port Harcourt,
P.M.B. 5323, Choba, Port Harcourt, Rivers State, Nigeria

Abstract: The aim of this study was to evaluate the protective effects of Negro pepper (*Xylopias aethiopica*) and African locust bean (*Parkia clappertoniana*) against carbon tetrachloride (CCl₄) -induced hepatotoxicity in rats. Carbon tetrachloride (0.5 mL kg⁻¹ b.wt.) was administered after 21 days of feeding animals with diets containing Negro pepper (*X. aethiopica*) and African locust bean (*P. clappertoniana*). Serum alanine amino transferase (ALT), aspartate amino transferase (AST), alkaline phosphatase (ALP) and lactate dehydrogenase (LDH) levels 24 h after CCl₄ administration decreased significantly ($p \leq 0.05$) in rats pre-treated with *X. aethiopica* and *P. clappertoniana* than in CCl₄-treated rats only. Total serum bilirubin also showed a remarkable decrease in rats pre-treated with *X. aethiopica* and *P. clappertoniana* when compared to those administered CCl₄ alone. Lipid peroxidation expressed by malondialdehyde (MDA) concentration was significantly decreased ($p \leq 0.05$) in rats pre-treated with *X. aethiopica* and *P. clappertoniana* than in rats administered CCl₄ alone. Histopathological examinations of rats administered CCl₄ alone revealed severe hepatic damage to the liver. However, rats pre-treated with *X. aethiopica* and *P. clappertoniana* showed significant improvements in the architecture of rat liver. These findings suggest that *X. aethiopica* and *P. clappertoniana* may be protective against CCl₄- induced liver damage in rats.

Key words: African locust bean, carbon tetrachloride, hepatic injury, lipid peroxidation, negro pepper

INTRODUCTION

The liver is known to perform a multitude of essential functions and several disease states, including hepatitis and cirrhosis alter the metabolism of this organ (Attri *et al.*, 2001). The liver is an organ of paramount importance, which plays an essential role in the metabolism of foreign compounds. Human beings are exposed to these compounds through consumption of contaminated foods or exposure to chemical substances in the occupational environment. Oxidative stress resulting from the toxic effects of free radicals on the tissue plays an important role in the pathogenesis of various diseases such as Alzheimer's disease, Parkinson's disease and those involving anti-inflammatory processes (Habbu *et al.*, 2008). Free radical induced lipid peroxidation is believed to be one of the major causes of cell membrane damage leading to a number of pathological situations (Slater, 1984; Oberley, 1988; Halliwell, 1993).

Carbon tetrachloride is a known hepatotoxin. Its administration in rats enhances hepatic protein oxidation and results in the accumulation of oxidized proteins in the liver (Abraham *et al.*, 1999). A number of recent reports clearly demonstrated that in addition to hepatic problems, CCl₄ also causes disorders in kidney, lungs, testis and brain as well as in blood generating free radicals (Chaurbonneua *et al.*, 1986; Ahamad *et al.*, 1987; Ohata *et al.*, 1997; Ozturk *et al.*, 2003). Lipid peroxides produced from unsaturated fatty acids via radicals, cause histotoxicity and promote the formation of additional free radicals in a chain reaction type. The damage or death of tissue usually results in the leakage of the enzymes in the affected tissue(s) into the blood stream (Siegers *et al.*, 1985; Obi *et al.*, 2001). Serum or plasma enzyme levels have been used as markers for monitoring chemically induced tissue damages (Lin and Wang, 1986; Ngaha *et al.*, 1989). The enzymes L-Alanine aminotransferase (L-ALT) [E.C. 2.6.1.2] and L-Aspartate (L-AST) [E.C. 2.6.1.1] are important enzymes that are often

Corresponding Author: K.C. Patrick-Iwuanyanwu, Toxicological Unit, Department of Biochemistry,
University of Port Harcourt, P.M.B. 5323, Choba, Port Harcourt, Rivers State, Nigeria
Tel: +234(0)8033 1604 29

employed in assessing liver injury (Jaeger *et al.*, 1975; Ngaha *et al.*, 1989; Obi *et al.*, 1998; Patrick-Iwuanyanwu *et al.*, 2007; Patrick-Iwuanyanwu and Wegwu, 2008). The biotransformation of CCl₄ to metabolites is a cytochrome P450-mediated reaction that initiates lipid peroxidation and attendant tissue damage. Shenoy *et al.* (2001) reported that the oxidative damage through free radical generation is among the various mechanisms involved in the hepatotoxic effects of CCl₄. A number of investigators have previously demonstrated that antioxidants prevent CCl₄ toxicity, particularly hepatotoxicity, by inhibiting lipid peroxidation (Teselkin *et al.*, 2000), suppressing alanine aminotransferase (ALT) and aspartate aminotransferase (AST) activities (Lin and Huang, 2000) and increasing antioxidant enzyme activity (Kumaravelu *et al.*, 1995).

Herbal treatment of many diseases including hepatopathy is increasing in many countries (Venukumar and Latha, 2002; Malaya *et al.*, 2004). Some plants have been shown to have protective antioxidant effects and are therefore hepatoprotective. Such plants include *H. rosasinensis* (Obi *et al.*, 1998), Ginkgo biloba (Shenoy *et al.*, 2001), Ginger, garlic, a combination of ginger and garlic (Patrick-Iwuanyanwu *et al.*, 2007) and *Acanthus montanus* (Patrick-Iwuanyanwu and Wegwu, 2008) in CCl₄ hepatotoxicity.

Negro pepper (*Xylopias aethiopica*) is one of the most pungent spices available. It is found mostly in forest and coastal regions in Nigeria and belongs to the family Annonaceae (Dalziel, 1955; Irvine, 1961). It has an attractive aroma and has been applied in ethnomedicine in the treatment of cough, bronchitis, dysentery and female sterilization. It is believed to aid uterine contraction and is applied as an abortifacient (Iwu, 1986). The extract of the fruit is used to treat malaria in the Hausa land of Nigeria (Etkin, 1997), while oral infusion of the seeds is used as an antitussive agent (Mamoudoukande *et al.*, 1994). Phytochemical evaluation shows that *X. aethiopica* is rich in alkaloids, tannins, flavonoids, steroids, oligosaccharides and has tolerable levels of cyanogenic glycosides (Ijeh *et al.*, 2004).

The genus *Parkia* to which the African locust bean belongs is large in the family leguminosae. The pods are flat, large, irregular clusters from which the locust bean seeds are obtained. The species of the genus include *Parkia filicoidea*, *Parkia biglobosa*, *Parkia bicolor* and *Parkia clappertoniana*. The locust bean tree is planted mainly because the fruit is rich and provides valuable protein in the dry season (Odunfa and Oyewole 1986). It is also used for medicinal purposes and as a source of mouth wash to relieve toothache.

The aim of this study was however, to evaluate the hepatoprotective effects of Negro pepper (*Xylopias*

aethiopica) and African locust bean (*Parkia clappertoniana*) against carbon tetrachloride (CCl₄)-induced hepatotoxicity in rats.

MATERIALS AND METHODS

Plant material: Negro pepper and African locust beans were purchased from Choba market, Choba, Rivers State, Nigeria in October, 2008. They were sun dried for 4 days, ground into powdery form using an electric blender (Moulinex) and stored in air-tight containers

Animals: Adult male wistar albino rats (150-170 g) were obtained from the Animal House, Department of Biochemistry, University of Port Harcourt, Port Harcourt, Nigeria in October, 2008. They were housed in standard cages (Griffin and George Modular cage system) and left to acclimatize for 7 days to laboratory conditions before the commencement of experiment. During the acclimatization, the animals were fed with pelleted rat chow and water *ad libitum*.

In this study, rats were separated into four main groups (6 animals in each group) and given extracts of the drugs 21 days prior to CCl₄ administration. Hepatoprotection was assessed by monitoring the levels of selected biochemical parameters in the blood of rats.

Experimental protocol:

Group 1: Normal control rats (feed only)

Group 2: Received normal feed and 0.5 mL CCl₄ kg⁻¹ b.wt.

Group 3: Feed: locust bean (1:1) and 0.5 mL CCl₄ kg⁻¹ b.wt.

Group 4: Feed: Negro pepper (1:1) and 0.5 mL CCl₄ kg⁻¹ b.wt.

Induction of hepatic injury: Carbon tetrachloride (CCl₄)-induced liver damage was achieved by injecting 0.5 mL CCl₄ kg⁻¹ b.wt. intramuscularly on the 21st day of feeding animals of groups 1 to 4 with commercial feed, African locust beans and Negro pepper as stated above.

Preparations of samples: Twenty four hours after the administration of CCl₄, the rats were anaesthetized in chloroform-saturated chamber. The animals were sacrificed by cervical dislocation and blood was collected by cardiac puncture using a 5 mL hypodermic syringe and needle and introduced into an anticoagulant free bottle. Serum was separated by centrifugation at 2500 rpm for 10 min and stored in a refrigerator at 4°C until use. The measurement of different biochemical parameters (L-AST, L-ALT and ALP, LDH and bilirubin) was performed using

the Humazym MUV - test kit. The liver was excised and fixed in formalin for histological assessment of hepatic damage. Lipid peroxidation was also determined by estimating the malondialdehyde levels, using the method of Hunter *et al.* (1963) modified by Gutteridge and Wilkins (1980)

Analysis of data: The mean values of the control and test serum activities of a given enzyme were compared using the student's t-test (Zar, 1984). The significant level was set at $p < 0.05$.

RESULTS AND DISCUSSION

The results of hepatoprotective effects of locust bean (*P. clappertoniana*) and Negro pepper (*X. aethiopica*) on rats treated with single dose of CCl_4 (0.5 mL kg^{-1} b.wt.) are as shown in Table 1. The results indicate that rats administered with 0.5 mL kg^{-1} b.wt. CCl_4 recorded severe hepatic damage (group 2) when compared to control (group 1) and rats pretreated with African locust bean and Negro pepper (groups 3 and 4, respectively). This was evidenced by a marked elevation in the levels of serum marker enzymes, AST, ALT, ALP and LDH, bilirubin and MDA in rats treated with CCl_4 alone. The marker serum enzymes, AST, ALT and LDH recorded the lowest value in the group pre-treated with Negro pepper. However, serum ALP was observed to be lowest in rats pre-treated with African locust bean.

The efficacy of any hepatoprotective drug is indeed dependent on its capability of either reducing the harmful effects or in maintaining the normal hepatic physiological mechanism, which have been imbalanced by a hepatotoxin (Hukkeri *et al.*, 2003). The remarkable elevation in the liver marker enzymes and bilirubin in CCl_4 administered rats in this study is only a confirmation of previous reports on the hepatotoxicity of CCl_4 . In fact, in most experiments involving the induction of liver injury in experimental animals, administration of CCl_4 elicited the elevation in the levels of liver marker enzymes (AST, ALT, ALP and LDH) and Bilirubin resulting in a significant hepatic damage. The elevated levels of these biochemical parameters are direct reflection of alterations in the hepatic structural integrity. The results of marker enzymes levels in rats

administered CCl_4 alone corroborates those of other markers (Obi *et al.*, 1998; Wegwu *et al.*, 2005; Patrick-Iwuanyanwu *et al.*, 2007; Patrick-Iwuanyanwu and Wegwu, 2008) who reported elevated levels in the serum content of hepatic enzymes in rats administered with CCl_4 alone. The elevation of marker enzymes in rats administered CCl_4 alone reported in this study is similar to the findings of Prakash *et al.* (2008) who observed significant hepatic damage in rats treated with single dose of CCl_4 from a substantial increase in the activities of SGOT and SGPT. This is indicative of cellular leakage and loss of functional integrity in liver (Sallie *et al.*, 1991). In particular, the increase in the serum level of ALT is indicative of liver damage (Lin and Wang, 1986; Ngaha *et al.*, 1989). These enzymes are located in the cell cytoplasm and are emptied into the circulation once the cellular membrane is damaged (Lin and Huang, 2000). However, the reduction in the levels of marker enzymes, ALT and AST in rats pre-treated with Negro pepper (*X. aethiopica*) and African locust bean (*P. clappertoniana*) as reported in this study is also in agreement with the commonly accepted view that serum levels of transaminases return to normal with healing of hepatic parenchyma and the regeneration of hepatocytes. This is also similar to the findings of Thabrew *et al.* (1987), who found that serum transaminases returned to normal activities with the healing of hepatic parenchyma and regeneration of hepatocytes.

It is evident that an increase in bilirubin concentration in the serum or tissue is indicative of obstruction in the excretion of bile. Thus, the increased level of bilirubin observed in rats administered with CCl_4 alone (group 2 rats) could be attributed to liver damage. However, the decrease in bilirubin levels in pretreated rats is indicative of reversal of liver damage by the beans and spice.

Administration of 0.5 mL CCl_4 kg^{-1} b.wt. has been reported to elevate malondialdehyde (MDA), a product of lipid peroxidation in liver of rats treated with CCl_4 only (Shenoy *et al.*, 2001; Patrick-Iwuanyanwu *et al.*, 2007). They attributed the increase in MDA levels to enhanced lipid peroxidation, leading to tissue damage and failure of antioxidant defence mechanisms to prevent the formation

Table 1: Hepatoprotective effects of African locust bean (*Parkia clappertoniana*) and Negro pepper (*Xylopias aethiopica*) on ALP, AST, ALT, LDH, Bilirubin and lipid peroxidation (MDA) in CCl_4 -induced hepatotoxicity in rats

Groups	Treatments	ALP (UL ⁻¹)	AST (UL ⁻¹)	ALT (UL ⁻¹)	LDH (UL ⁻¹)	Bilirubin (mg dL ⁻¹)	MDA (μmol L ⁻¹)
1	Feed only	95.4±0.01 ^a	145.2±0.02 ^a	57.9±0.07 ^a	100.1±0.13 ^a	0.34±0.02 ^a	0.63±0.07 ^a
2	Feed + CCl_4	212.8±0.01 ^b	220.6±0.01 ^b	132.2±0.12 ^b	155.3±0.04 ^b	1.60±0.01 ^b	2.63±0.08 ^b
3	Feed + Locust bean + CCl_4	125.6±0.01 ^c	160.1±0.10 ^c	79.2±0.11 ^c	110.1±0.12 ^c	0.36±0.01 ^a	1.34±0.10 ^c
4	Feed + Negro pepper + CCl_4	148.2±0.01 ^d	154.4±0.21 ^c	61.33±0.21 ^d	103.5±0.10 ^a	0.32±0.03 ^a	1.55±0.40 ^d

Values are Mean±SEM, n = 6 rats in each group, Means with different superscript letters (a-d) in the same column are significantly different at the 0.05 level

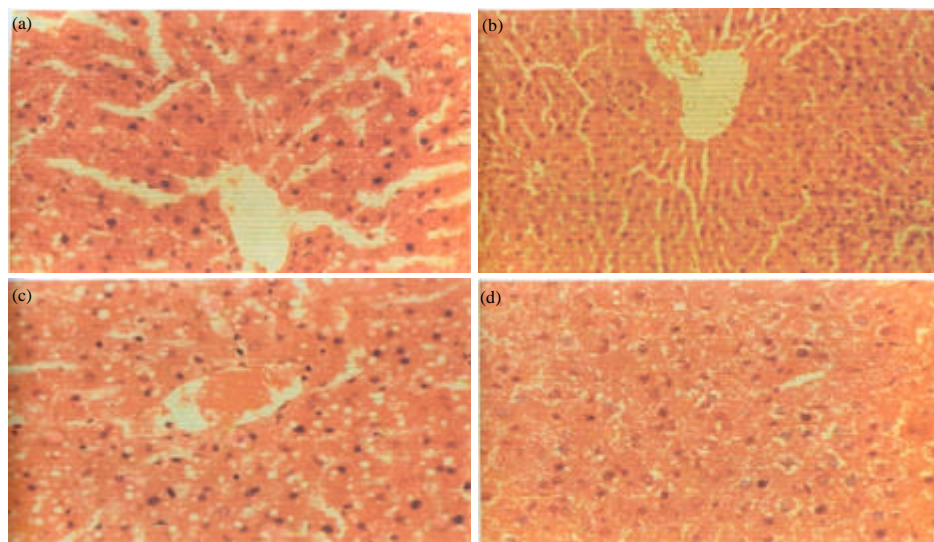


Fig. 1: (a) A section of rat liver treated with CCl_4 only, showing congested central vein, vacuolar degeneration of centrilobular hepatocytes. (b) A section of rat liver pre-treated with African locust bean prior to CCl_4 administration showing a pattern of reduced inflammatory infiltration. (c) A section of rat liver pre-treated with Negro pepper prior to CCl_4 administration showing a pattern of reduced inflammatory infiltration. (d) A section of liver showing normal architecture

of excessive free radicals. This in turn alters the ratio of polyunsaturated to other fatty acids, thus, leading to a decrease in the membrane fluidity, which may be sufficient to cause cell death (Rotruck *et al.*, 1979). The results in this study suggest that pretreatment of rats for 21 days with African locust bean and Negro pepper prior to CCl_4 administration significantly ($p \leq 0.05$) reversed these changes. It would be deduced, therefore, that the antioxidant effects of African locust bean and Negro pepper could possibly be its mechanism of hepatoprotection.

Histopathological examinations (Fig. 1a-d) showed defects ranging from massive tissue necrosis, congested central vein, fatty degeneration and infiltration by inflammatory cells in rats treated with CCl_4 alone. However, histological profile of rats pre-treated with locust bean (*P. clappertoniana*) and Negro pepper (*X. aethiopica*) exhibited significant liver protection against the toxicant as evidenced by the presence of normal hepatic cords, absence of necrosis and lesser fatty infiltration (Fig. 1a-d). Histopathological examination of control rats however, revealed normal architecture.

The marked decrease in the levels of serum marker enzymes and MDA in pre-treated rats are indications of the ability of African locust bean and Negro pepper to protect the liver against CCl_4 poisoning. This is corroborated by the architecture of the liver of rats that received African locust bean and Negro pepper prior to CCl_4 administration (Fig. 1a-d).

The findings in this study indicate that pretreatment of rats with African locust bean and Negro pepper 21 days prior to CCl_4 administration caused a marked decrease in the levels of hepato specific serum enzymes. It thus implies that African locust bean and Negro pepper may be protective against CCl_4 -induced liver damage in rats.

REFERENCES

- Abraham, P., G. Wilfred and B. Ramakrishna, 1999. Decreased activity of hepatic alkaline protease in rats with CCl_4 induced liver cirrhosis. *Indian J. Exp. Biol.*, 37: 1243-1244.
- Ahamad, F.F., D.L. Cowan and A.Y. Sun, 1987. Detection of free radical formation in various tissues after acute carbon tetra chloride administration in gerbil. *Life Sci.*, 41: 2469-2475.
- Attri, S., S.V. Rana, K. Vaiphie, R. Katyal, C.P. Sodhi, S. Kanwar and Singh, 2001. Protective effect of n-acetyl-cysteine in isoniazid-induced hepatic injury in growing rats. *Indian J. Exp. Biol.*, 39: 436-440.
- Chaurbonneua, M., J. Brodeur, P. du Souich and G.L. Plaa, 1986. Correlation between acetone potentiated CCl_4 -induced liver injury and blood concentration after inhalation or oral administration. *Toxi. Applied Pharmacol.*, 84: 286-294.
- Dalziel, J.M., 1955. *The Useful Plants of West Tropical Africa*. Crown Agents for Oversea Governments and Administrations, London, pp: 328.

- Etkin, N.L., 1997. Antimalarial plants used by Hausas in Northern Nigeria. *Trop. Doc.*, 27: 12-16.
- Gutteridge, J.M.C. and C. Wilkins, 1980. Copper dependent hydroxyl radical damage to ascorbic acid formation of a thiobarbituric acid reactive products. *FEBS Lett.*, 137: 327-340.
- Habbu, P.V., R.A. Shastry, K.M. Mahadevan, J. Hanumanthachar and S.K. Das, 2008. Hepatoprotective and antioxidant effects of *Argyrea speciosa* in rats. *Afr. J. Tradit. Complement. Altern. Med.*, 5: 158-164.
- Halliwell, B., 1993. Oxygen Species in Pathology with Special Reference to the Skin. In: *Oxidative Stress in Dermatology*, Fuchs, J. and L. Packer (Eds.). Marcell Dekker Inc., New York, pp: 3-11.
- Hukkeri, V.I., B. Jaiprakash, M.S. Lauhale, R.V. Karadi and I.J. Kuppast, 2003. Hepatoprotective activity of *Ailanthus excelsa* roxb: Leaf extract on experimental liver damage on rats. *Pharmacognosy*, 11: 1-2.
- Hunter, F.E., J.M. Gebicki, P.E. Hoffsetein, J. Weistein and A. Scott, 1963. Swelling and lysis of rats liver mitochondria induced by ferrous ions. *J. Biol Chem.*, 238: 828-835.
- Ijeh, I.I., O.U. Njoku and E.C. Ekenze, 2004. Medicinal evaluation of *Xylopiya ethiopic*a and *ocimum gratissimum*. *J. Med. Aromatic Sci.*, 26: 44-47.
- Irvine, F.R., 1961. *Woody Plants of Ghana*. Oxford University Press, London, pp: 124-126.
- Iwu, M.M., 1986. *Empirical Investigation of Dietary Plants Used in Igbo Ethnomedicine*. Nina Etkined Redgroove Publishing Co., New York, pp: 131-150.
- Jaeger, R.J., R.B. Conolly and S.D. Murphy, 1975. Short term inhalation toxicity of halogenated hydrocarbon. *Arch. Environ. Health*, 30: 26-31.
- Kumaravelu, P., D.P. Dakshinamoorthy, S. Subramaniam, H. Devaraj and N.S. Devaraj, 1995. Effect of eugenol on drug-metabolizing enzymes of carbon tetrachloride-intoxicated rat liver. *Biochem. Pharmacol.*, 49: 1703-1707.
- Lin, C.C. and P.C. Huang, 2000. Antioxidant and hepatoprotective effects of *Acathopanax senticosus*. *Phytother. Res.*, 14: 489-494.
- Lin, J.K. and C.J. Wang, 1986. Protection of Crocin dyes in the acute hepatic damage induced by Aflatoxin B and dimethylnitrosamine in rats. *Carcinogenesis*, 7: 595-599.
- Malaya, G., U.K. Mazumder, T.S. Kumar, P. Gromathi and R.S. Kumar, 2004. Antioxidant and hepatoprotective effect of *Bauhinia racemosa* against paracetamol and carbon tetrachloride induced liver damage in rats. *Iranian J. Pharmacol. Ther.*, 1: 12-20.
- Mamoudoukande, K., S. Philipov and H. Dutschewska, 1994. Alkaloids of *Xylopiya aethiopic*. *Fitoteropia*, 65: 89-90.
- Ngaha, E.O., M.A. Akanji and M.A. Madusolumuo, 1989. Studies on correlation between chloroquine induced tissue damage and serum enzyme changes in the rat. *Experientia*, 45: 143-146.
- Oberley, L.W., 1988. Free radicals and diabetes. *Free Radic. Bio. Med.*, 5: 113-124.
- Obi, F.O., I.A. Usenu and J.O. Osayande, 1998. Prevention of CCl₄-induced hepatotoxicity in the rat by *H. rosasinensis* anthocyanin extract administered in ethanology. *Toxicology*, 131: 93-98.
- Obi, F.O., L.A. Omogbai, O.S.J. Oriafio, O.D. Ovat, 2001. Effect of a short time post carbon tetrachloride treatment interval on rat plasma enzyme levels and percentage mortality. *J. Applied Sci. Environ. Mgt.*, 5: 5-8.
- Odunfa, S.A. and O.B. Oyewole, 1986. Identification of *Bacillus* species from *iru*, a fermented African locust bean product. *J. Basic Microbiol.*, 26: 101-108.
- Ohata, Y., K. Nikida, E. Sasaki, M. Kongo and I. Ishiguro, 1997. Attenuation of disrupted hepatic active oxygen metabolism with the recovery of acute liver injury in rats intoxicated with carbon tetra chloride. *Res. Commun. Mol. Pathol. Pharmacol.*, 95: 197-201.
- Ozturk, F., M. Ucar, I.C. Ozturk, N. Vardi and K. Batcioglu, 2003. Carbon tetra chloride induced nephrotoxicity and protective effects of betaine in Sprague-dawley rats. *Urology*, 62: 353-356.
- Patrick-Iwuanyanwu, K.C. and M.O. Wegwu, 2008. Prevention of carbon tetrachloride (CCl₄)-induced liver damage in rats by *Acanthus montanus*. *Asian J. Biochem.*, 3: 213-220.
- Patrick-Iwuanyanwu, K.C., M.O. Wegwu and E.O. Ayalogu, 2007. Prevention of CCl₄-induced liver damage by ginger, garlic and vitamin E. *Pak. J. Biol. Sci.*, 10: 617-621.
- Prakash, O., G.N. Singh, R.M. Singh, S.C. Mathur, M. Bajpai and S. Yadav, 2008. Protective effects oof herbal formula against carbontetrachloride-induced hepatotoxicity. *Int. J. Pharmacol.*, 4: 282-286.
- Rotruck, J.T., A.L. Pope, H. Ganther, A.B. Awanson, D.G. Haffeman and W.G. Hofekstra, 1979. Selenium: Biochemical role as a component of glutathione peroxides. *Science*, 179: 588-590.
- Sallie, R., J.M. Tredger and R. Williams, 1991. *Drugs and the liver Part 1: Testing liver function*. *Biopharm. Drug Dispos.*, 12: 251-259.
- Shenoy, K.A., S.N. Somayaji and K.L. Bairy, 2001. Hepatoprotective effects of *Ginkgo biloba* against carbon tetrachloride induced hepatic injury in rats. *Ind. J. Pharmacol.*, 33: 260-266.

- Siegers, C.P., W. Horn and M. Younes, 1985. Effects of hypoxia on the metabolism and hepatotoxicity of CCl₄ and vinylidene chloride in rats. *Acta Pharmacol. Toxicol.*, 56: 81-86.
- Slater, T.F., 1984. Free radical mechanism in tissue injury. *Biochem. J.*, 222: 1-15.
- Teselkin, Y.O., I.V. Babenkova, V.K. Kolhir, A.I. Baginskaya and N.A. Tjukavkina *et al.*, 2000. Dihydroquercetin as a means of antioxidative defence in rats with tetrachloromethane hepatitis. *Phytother. Res.*, 14: 160-162.
- Thabrew, M.I., P.D.T.M. Joice and W.A. Rajatissa, 1987. Comparative study of efficacy of *Paetta indica* and *Osbeckia octandra* in the treatment of liver dysfunction. *Planta Medica*, 53: 239-241.
- Venukumar, M.R. and M.S. Latha, 2002. Hepatoprotective effect of metabolic extract of *Cuculigo orchioides* in CCl₄-treated male rats. *Indian J. Pharmacol.*, 34: 269-275.
- Wegwu, M.O., E.O. Ayalogu and O.J. Sule, 2005. Antioxidant protective effects of cassia alata in rats exposed to carbon tetrachloride. *J. Applied Sci. Environ.*, 9: 77-80.
- Zar, J.H., 1984. Production: *Biostatistical Analysis*. Prentice-Hall, Englewood Cliffs, NJ., USA., pp: 293-305.