



International Journal of Pharmacology

ISSN 1811-7775

science
alert

ansinet
Asian Network for Scientific Information

Biochemical, Haematological and Histological Effects of Dietary Supplementation with Leaves of *Gnetum africanum* Welw. on Paracetamol-induced Hepatotoxicity in Rats

Emeka E.J. Iweala and Atinuke O. Osundiya
Biochemistry and Molecular Biology Unit, Department of Biological Sciences,
Covenant University, P.M.B. 1023, Ota, Ogun State, Nigeria

Abstract: Preliminary studies on the effects of dietary supplementation with *Gnetum africanum* leaves on some biochemical, haematological and histological parameters were investigated in female rats in which liver damage was induced with paracetamol. Thirty rats were divided into six hepatotoxic and non-hepatotoxic groups and were fed with 5 and 10% *Gnetum africanum*-supplemented diet. Weight changes and parameters including alanine transaminase, aspartate transaminase, total protein, glucose, total triglycerides, total cholesterol, reduced glutathione, lipid peroxidation, packed cell volume, white blood cell and differentials count, were determined using standard methods. The consumption of a *Gnetum africanum*-supplemented diet did not significantly change the weight of the animals and the levels of protein, alanine transaminase and aspartate transaminase. Reduced glutathione and triglycerides were significantly increased ($p < 0.05$) in the hepatotoxic group while triglycerides were reduced in non-hepatotoxic group fed 10% *Gnetum africanum*-supplemented diet. Glucose was also significantly reduced ($p < 0.05$) in the two groups. Cholesterol and lipid peroxidation levels did not change significantly in all the animals. PCV was significantly reduced ($p < 0.05$) in hepatotoxic groups fed *Gnetum africanum*-supplemented diet. The hepatotoxic control and group fed 10% *Gnetum africanum*-supplemented diet had significant reductions in neutrophils ($p < 0.05$). WBC levels did not change significantly. Additional histological changes observed in the photo micrograph of a cross section of the liver of the rats in the hepatotoxic groups showed necrosis and some regeneration in the group fed *Gnetum africanum*-supplemented diet.

Key words: *Gnetum africanum*, alanine transaminase, aspartate transaminase, reduced glutathione, cholesterol, lipid peroxidation

INTRODUCTION

Gnetum africanum Welw. is one of the numerous plant foods widely consumed in various forms in Africa especially Southern Nigeria due to its palatability and taste (Ekop, 2007; Fu *et al.*, 1999). *G. africanum*, a lone genus belonging to the family Gnetaceae is a dioecious, wild understorey lianas that grow on trees in the humid forests of Africa (Mialoundama, 1993).

The leaves of *G. africanum* are elliptic and lined with reticulate veins, similar to those of a dicotyledonous angiosperm (Doyle, 1998). The leaves of *G. africanum* are used in the treatment of enlarged spleen, sore throat and as a cathartic (Burkill, 1994). It is also used to reduce nausea and neutralize some poisons. It can be externally applied to manage boils and warts and is used to reduce the pain of childbirth. The leaves of *G. africanum* are commonly eaten raw and used in preparing soups and stews (Burkill, 1994). The medicinal and culinary

applications of the leaves of *G. africanum* underscore its importance as major dietary supplement with potential biological effects. Dietary supplementation with vegetables and other nutrients is employed to study their effects on the physiological and biochemical characteristics of experimental animals (Iweala and Obidoa, 2009a; Baylan *et al.*, 2006). Studies have showed varying physiological effects associated with the consumption of diets supplemented with leaves of tropical vegetables such as *Ocimum grattissimum*, *Gongronema latifolium* and *G. africanum* (Iweala *et al.*, 2009; Iweala and Obidoa, 2009b, 2010). Paracetamol (Acetaminophen) is one of the most widely used pharmaceutical analgesic and antipyretic which causes liver toxicity and damage due to excessive use or overdose (Ryder and Beckingham, 2001). Paracetamol induced-hepatotoxicity in experimental animals as well as human subjects is widely recognized and reported (James *et al.*, 2003; Gunnell *et al.*, 2000; Yen *et al.*, 2007).

Studies have shown that several plants have anti-hepatotoxic properties that can protect animals from paracetamol toxicity (Hemabarathy *et al.*, 2009; Fakurazi *et al.*, 2008). Due to its high tolerance and its availability, over-the-counter misuse and overdose of paracetamol is common and well recognized in Nigeria and all over the world (Khashab *et al.*, 2007). However, the widespread consumption of plant based diets such as *G. africanum* in Nigeria may mask the apparent hepatotoxicity from the misuse of paracetamol. This forms the basis of this study aimed at studying the preventive potentials of consumption of *G. africanum* against paracetamol-induced hepatotoxicity as well as other associated biological effects.

MATERIALS AND METHODS

This research was carried out between 7th December, 2009 and 7th March, 2010 at the Department of Biological Sciences, Covenant University, Ota, Ogun State, Nigeria.

Processing of *G. africanum* leaves: Fresh leaves of *G. africanum* were bought from a local market in Ota, Ogun state, South-Western Nigeria. The leaves were picked, air-dried and ground to a coarse powdered form with a hammermill. The proximate composition of the ground leaves of *G. africanum* was determined according to the procedure of AOAC (1975) and considered in the formulation of experimental diets.

Formulation of experimental diets: Three isocaloric and isonitrogenous experimental diets namely control diet, 5 and 10% *Gnetum africanum* -supplemented diets were formulated. The diets were formulated from commercially available feed grade feedstuffs including maize, corn flour, fishmeal, groundnut meal, bone meal and vitamin premix. The control diet was formulated without the inclusion of *G. africanum* leaf powder while the *Gnetum africanum*-supplemented diets were incorporated with 5 and 10% of *G. africanum* leaf powder.

Experimental design and paracetamol-induced hepatotoxicity: Thirty female albino rats aged four to six weeks old and with an average weight of 40-80 g were used for the experiment. The experimental design involved random distribution of five rats each into six experimental groups' namely non-hepatotoxic control, hepatotoxic control, non hepatotoxic fed 5% *Gnetum africanum*-supplemented diet, non-hepatotoxic fed 10% *Gnetum africanum*-supplemented diet, hepatotoxic fed 5% *Gnetum africanum*-supplemented diet and hepatotoxic fed 10%

Gnetum africanum-supplemented diet. The animals in non-hepatotoxic control and hepatotoxic control groups were fed control diet while those in non hepatotoxic fed 5% *Gnetum africanum*-supplemented diet and hepatotoxic fed 5% *Gnetum africanum*-supplemented diet groups were fed 5% *Gnetum africanum*-supplemented diet. The animals in non hepatotoxic fed 10% *Gnetum africanum*-supplemented diet and hepatotoxic fed 10% *Gnetum africanum*-supplemented diet groups were fed 10% *Gnetum africanum*-supplemented diet. All the animals were given the various feed and water *ad libitum* for 56 days. Prior to the end of feeding, animals in hepatotoxic control, hepatotoxic fed 5% *Gnetum africanum*-supplemented diet and hepatotoxic fed 10% *Gnetum africanum*-supplemented diet groups were orally administered daily with 3 g kg⁻¹ b.wt. of paracetamol for seven days while those in non-hepatotoxic control, non hepatotoxic fed 5% *Gnetum africanum*-supplemented diet and non-hepatotoxic fed 10% *Gnetum africanum*-supplemented diet groups were administered with the vehicle (distilled water) only. Weight changes of animals in all the groups were recorded throughout the experiment. All the experiments were performed under standard animal husbandry conditions and after the protocols had been approved by the animal ethics committee of the department of Biological Sciences, Covenant University, Ota, Ogun State, Nigeria.

Collection of blood and tissue samples: At the end of the feeding and administration of paracetamol, the animals from each group were anesthetized and blood samples were collected in labelled sample bottles with drops of Ethylenediaminetetraacetic acid (EDTA). Serum samples were collected in sample bottles without EDTA and allowed to clot before being centrifuged at 5000 rpm for 10 min.

The livers of the animals in all the groups were promptly excised soon after sacrifice and stored in 10% formyl saline.

Determination of biochemical parameters: Glucose, aspartate aminotransferase (AST) and alanine aminotransferase (ALT) were determined using test kits produced by Cypress diagnostics, Belgium. Total triglyceride and cholesterol were determined using test kits produced by Linear chemicals SL, Spain. Total protein was determined by the method described by Lowry *et al.* (1951). Reduced glutathione was determined using the method of Ellman (1959). Lipid peroxidation was determined by the thiobarbituric acid reactive substances (TBARS) method (Buege and Aust, 1978).

Determination of haematological parameters: Full blood count and white blood cells (WBC) differentials were determined according to methods described by Dacie and Lewis (1990).

Histological examination: Histological examinations were done on sections of liver tissues from animals in the different groups according to procedures described by Disbrey and Rack (1970).

Expression of results and statistical analysis: Results were expressed as Mean±Standard Error of Mean (SEM) for triplicate determinations. A One-way Analysis of Variance (ANOVA) for a completely randomized design was used to analyse experimental data. Values were considered significant at $p < 0.05$.

RESULTS

The effect of feeding *Gnetum africanum*-supplemented diet on weight prior to and after induction of hepatotoxicity with paracetamol are shown in Table 1. Prior to the induction of hepatotoxicity, *Gnetum africanum*-supplemented diet caused varying percentage weight gains in all the groups which were not statistically significant when compared to the controls. In contrast, weight losses were recorded after induction of hepatotoxicity in all the groups except the non hepatotoxic group fed 5% *Gnetum africanum*-supplemented diet.

The effect of *Gnetum africanum*-supplemented diet on the biochemical parameters in non-hepatotoxic and hepatotoxic rats are presented in Table 2, the levels of the liver enzymes were not significantly altered except AST

that was significantly increased ($p < 0.05$) in the non-hepatotoxic group fed 5% *Gnetum africanum*-supplemented diet. Blood glucose concentration was only significantly reduced ($p < 0.05$) in both groups fed 10% *Gnetum africanum*-supplemented diet. There were no significant changes in the protein and cholesterol levels in all the groups. Triglyceride concentration was significantly increased ($p < 0.05$) in the hepatotoxic group and reduced in the non-hepatotoxic groups fed 10% *Gnetum africanum*-supplemented diet. Reduced glutathione was significantly increased ($p < 0.05$) only in the hepatotoxic group fed 10% *Gnetum africanum*-supplemented diet. There were no significant changes in the lipid peroxidation levels in all the animals.

The result of feeding *Gnetum africanum*-supplemented diet (GASD) on haematological parameters in control and paracetamol-induced hepatotoxic rats are presented in Table 3. The PCV was significantly reduced ($p < 0.05$) only in the hepatotoxic group fed *Gnetum africanum*-supplemented diet while neutrophils were also reduced only in the hepatotoxic control.

The histological features of the liver of the animals in all the groups are shown in Fig. 1-6. The liver sections of the rats in the control and non-hepatotoxic groups fed with *Gnetum africanum*-supplemented diet (Fig. 1-3) showed less disarrangement and degeneration of hepatocytes, indicating marked preservation of hepatic architecture. The liver sections of the rats in the control hepatotoxic group (Fig. 4) showed disarrangement and degeneration of normal hepatic cells with intense centrilobular necrosis, sinusoidal haemorrhages and dilatation. There was also inflammatory cell infiltrate in the portal tracts. However, Fig. 5 and 6 show that the

Table 1: Weight changes prior to and after paracetamol-induced hepatotoxicity in hepatotoxic and non hepatotoxic rats fed *Gnetum africanum*-supplemented diet

	Non-hepatotoxic control group	Hepatotoxic control group	Non-hepatotoxic group fed 5% <i>Gnetum africanum</i> -supplemented diet	Non-hepatotoxic group fed 10% <i>Gnetum africanum</i> -supplemented diet	Hepatotoxic group fed 5% <i>Gnetum africanum</i> -supplemented diet	Hepatotoxic group fed 10% <i>Gnetum africanum</i> -supplemented diet
Weight change						
Prior to hepatotoxicity (%)	40.1	51.2	41.5	41.5	43.4	43.7
After hepatotoxicity (%)	-5.4	-10.3	6.4	-2.5	-3.0 ^b	-6.5 ^b

^bRepresents values that are significant ($p < 0.05$) with respect to hepatotoxic control

Table 2: Biochemical parameters in hepatotoxic and non hepatotoxic rats fed *Gnetum africanum*-supplemented diet

Parameters	Non-hepatotoxic control group	Hepatotoxic control group	Non-hepatotoxic group fed 5% <i>Gnetum africanum</i> -supplemented diet	Non-hepatotoxic group fed 10% <i>Gnetum africanum</i> -supplemented diet	Hepatotoxic group fed 5% <i>Gnetum africanum</i> -supplemented diet	Hepatotoxic group fed 10% <i>Gnetum africanum</i> -supplemented diet
Glucose (mg dL ⁻¹)	135.10±31.22	181.55±12.84	154.47±16.59	116.66±18.23 ^b	146.67±14.69	119.10±13.60 ^b
Protein (mg mL ⁻¹)	6.31±0.04	5.60±0.70	4.81±0.30	5.90±0.30	5.53±0.31	5.16±0.16
Reduced glutathione (mM mL ⁻¹)	0.0108±0.0017	0.0110±0.0110	0.0115±0.00052	0.0138±0.00116	0.0136±0.00108	0.0155±0.00029 ^b
Cholesterol (mg dL ⁻¹)	255.17±0.57	273.89±10.13	262.74±17.05	249.01±8.33	268.82±9.72	253.22±6.08
Triglycerides (mg dL ⁻¹)	254.16±1.64	298.77±20.34	264.57±11.54	253.90±10.27 ^b	298.49±10.09	302.68±15.94 ^a
Lipid peroxidation (nmol mL ⁻¹)	13.51±0.93	13.32±0.67	16.42±2.28	14.98±0.50	12.92±0.74	15.15±1.52
Aspartate transaminase (IU L ⁻¹)	26.62±3.79	13.77±4.79	38.85±8.29 ^b	24.06±3.61	19.50±5.20	11.96±4.51
Alanine transaminase (IU L ⁻¹)	14.39±4.26	15.40±5.60	25.31±11.42	15.75±4.42	24.0±11.37	11.67±3.99

^aRepresents values that are significant ($p < 0.05$) with respect to non-hepatotoxic control, ^bRepresents values that are significant ($p < 0.05$) with respect to hepatotoxic control, ^{ab}Represents values that are significant ($p < 0.05$) with respect to hepatotoxic and non-hepatotoxic control

Table 3: Haematological parameters in hepatotoxic and non hepatotoxic rats fed *Gnetum africanum*-supplemented diet

Parameters	Non-hepatotoxic control group	Hepatotoxic control group	Non-hepatotoxic group fed 5% <i>Gnetum africanum</i> -supplemented diet	Non-hepatotoxic group fed 10% <i>Gnetum africanum</i> -supplemented diet	Hepatotoxic group fed 5% <i>Gnetum africanum</i> -supplemented diet	Hepatotoxic group fed 10% <i>Gnetum africanum</i> -supplemented diet
Packed cell volume (%)	39.33±0.67	35.20±1.93	37.25±3.04	33.75±0.25	32.00±1.79 ^a	30.25±1.31 ^a
White blood cells (10 ³ mm ⁻³)	6500±288.68	6100±556.78	6500±540.06	5000±204.12	5000±524.40	5250±629.15
Lymphocytes (%)	18.33±1.76	20.00±0.50 ^a	20.40±0.58	20.00±0.82	21.00±1.078	20.25±0.48
Neutrophils (%)	81.67±1.76	78.20±0.58 ^a	79.50±0.96	79.00±0.82	79.60±1.078	78.00±0.41 ^a

^aRepresents values that are significant (p<0.05) with respect to non-hepatotoxic control

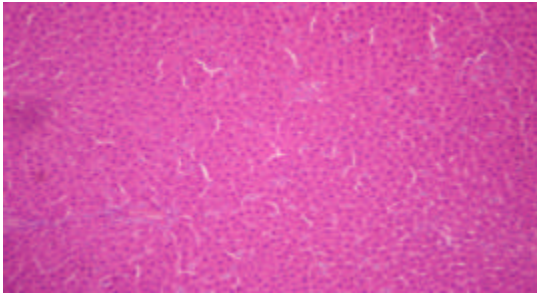


Fig. 1: Photo micrograph of a cross section of liver of non-hepatotoxic rat fed with control diet. MAG. X100

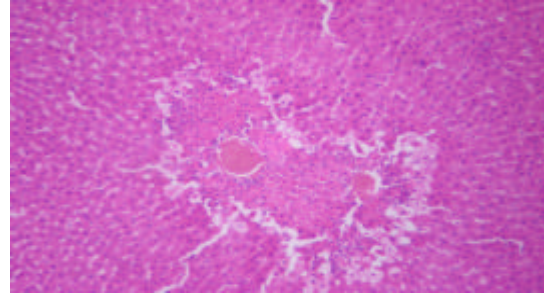


Fig. 4: Photo micrograph of a cross section of liver of hepatotoxic rat fed with control diet. MAG. X100

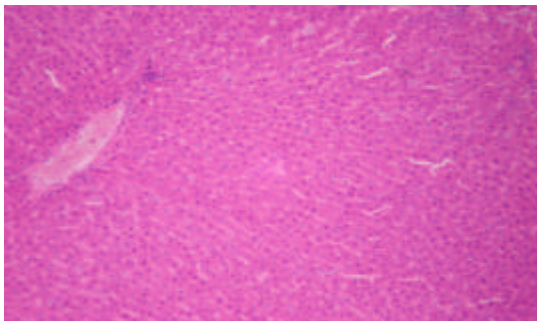


Fig. 2: Photo micrograph of a cross section of liver of non-hepatotoxic rat fed with 5% *Gnetum africanum*-supplemented diet. MAG. X100

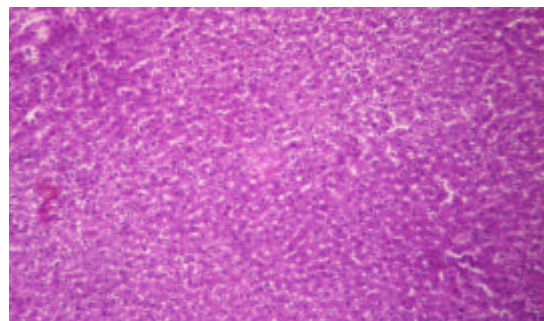


Fig. 5: Photo micrograph of a cross section of liver of hepatotoxic rat fed with 5% *Gnetum africanum*-supplemented diet. MAG. X100

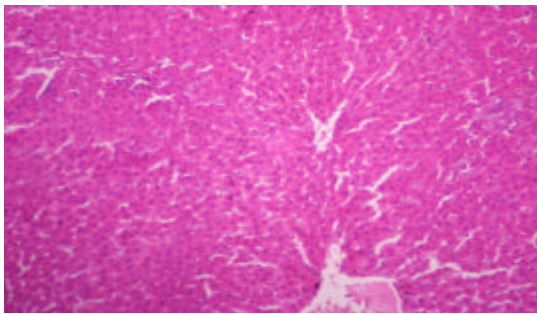


Fig. 3: Photo micrograph of a cross section of liver of non-hepatotoxic rat fed with 10% *Gnetum africanum*-supplemented diet. MAG. X100

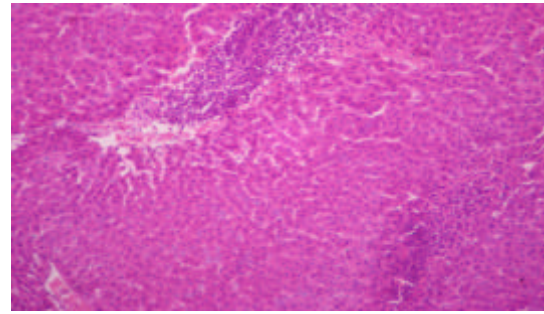


Fig. 6: Photo micrograph of a cross section of liver of hepatotoxic rat fed with 10% *Gnetum africanum*-supplemented diet. MAG. X100

intensity of centrilobular necrosis was less in the liver sections of the hepatotoxic groups fed *Gnetum africanum*-supplemented diet indicating marked regeneration.

DISCUSSION

Paracetamol (Acetaminophen or n-acetyl-p-aminophenol), a commonly used analgesic drug has the potential to cause centrilobular hepatic necrosis in experimental animals and in humans (Ray *et al.*, 1999, 1996; Davidson and Eastham, 1966). Damage to the liver or hepatotoxicity, does not result from paracetamol itself, but from one of its metabolites, *N*-acetyl-*p*-benzoquinoneimine (NAPQI) (Brent and Rumack, 1993). NAPQI is a highly reactive toxic and cytotoxic intermediate metabolite, that is damaging to cell components if not detoxified by conjugation with glutathione (GSH). NAPQI can rapidly react with reduced glutathione (GSH) and lead to a 90% total hepatic GSH depletion in the cells and mitochondria, which can result in hepatocellular death and mitochondrial dysfunction (Mitchell *et al.*, 1973).

Phytochemical products including plant herbs and extracts have been used for centuries to promote liver health. Although the exact mechanisms behind this protection are uncertain, many theories have been proposed. Paracetamol is being used extensively to investigate hepatoprotective activity of different treatments on various experimental animals (Suresh *et al.*, 2006). It is selected as hepatotoxicant in inducing injury to the liver as it is known to cause hepatotoxicity in man and experimental animals when taken overdose (Ahmed and Khater, 2001).

Gnetum africanum is highly valued as a nutritious, medicinal and therapeutic vegetable across Central Africa. The major purpose of this investigation was to study the effect of *Gnetum africanum* Welw. on paracetamol-induced hepatotoxicity and some associated parameters in rats. Aspartate transaminase (AST) and alanine transaminase (ALT) were used as parameters for assessing of liver toxicity, while total protein, triglycerides, cholesterol and glucose were used as supplementary tests for hepatic synthetic and other allied functions. Liver histopathology served as the most important tool for identifying and characterizing liver injury. The feeding of *Gnetum africanum*-supplemented diet of different concentration (5 and 10%) showed a general non-significant ($p < 0.05$) increase in weight of animals. This observation supports the study by Iweala *et al.* (2009) in which there were increases in weights of rats fed a diet supplemented with *Gnetum*

africanum. The increase in weight indicates that the leaves of *Gnetum africanum* was not toxic to the animals and could be attributed to their content of nutrients such as proteins, carbohydrates, lipids, minerals and vitamins which are needed for growth, body repair and maintenance (Isong *et al.*, 1999; Iwu, 1986; Davidson *et al.*, 1975). Thus, the vegetable could be a valuable and viable source of bioactive nutrients and non-nutrient substances with potential hepatoprotective properties.

Increases in activities of liver enzymes such as alanine transaminase and aspartate transaminase are roughly proportional to the extent of liver tissue damage (Gaw *et al.*, 1995). Generally the consumption of *Gnetum africanum*-supplemented diet did not significantly ($p < 0.05$) change any of the liver enzymes in the animals which shows that *Gnetum africanum* does not have any noticeable or apparent toxic effect on the liver.

Total protein levels are rough measures of protein status but reflect major functional changes in liver functions (Pachathundikandi and Varghese, 2006). In this research there was a non-significant change ($p < 0.05$) in the protein level of hepatotoxic animals, which could be due to stabilization in protein synthesis secondary to a decreased amount and availability of mRNA in the liver and this could indicate liver dysfunction (Orhue *et al.*, 2005). In a study by Iweala *et al.* (2009) the total protein levels of rats fed with leaves of *Gnetum africanum* were significantly reduced ($p < 0.05$) which is a reflection of the indigestibility and hence unavailability of protein constituent of leaves of *Gnetum africanum*. Reduction in total protein could have consequences on the overall physiological function of animals.

Oxidative stress caused by Reactive Oxygen Species (ROS) plays a central role in hepatotoxicity (Echard *et al.*, 2001). Reduced glutathione is an important antioxidant and free radical scavenger that has the ability to combat Reactive Oxygen Species (ROS) in the liver (Crocenzi *et al.*, 2000). However, during paracetamol poisoning, NAPQI depletes markedly hepatocellular levels of reduced glutathione making the hepatocytes susceptible to its the toxic effects (Smilkstein *et al.*, 1988). The result of this study showed that there was a significant increase ($p < 0.05$) in the level of reduced glutathione in the hepatotoxic animals fed with the 10% *Gnetum africanum*-supplemented diet. This suggests that increase in quantity of *Gnetum africanum* consumed may be improve hepatoprotection during paracetamol-induced toxicity.

Excess reduction of hepatic glutathione concentration follows paracetamol challenge and is associated with heightened lipid peroxidation via free

radical damage and directly damages cells in the liver (Brent and Rumack, 1993; Ray *et al.*, 1999). There was a stabilization in the level of lipid peroxidation of hepatotoxic control animals and those fed *Gnetum africanum*-supplemented diet which could be attributed to the presence of antioxidant phytochemicals including phenolic substances, flavonoids and anthocyanidins in the *Gnetum africanum* whose phenolic structure favor their reaction with free radicals and Reactive Oxygen Species (ROS).

The reduction ($p < 0.05$) in the levels of glucose in hepatotoxic rats fed *Gnetum africanum*-supplemented diet suggests that consumption of *Gnetum africanum* could reduce the blood concentration of glucose in the case of hyperglycemia seen in disease conditions such as diabetes with associated liver damage.

There were also non-significant changes ($p < 0.05$) in the levels cholesterol in the groups. This supports research suggesting that *Gnetum africanum* may have cholesterol reducing properties that is important in preventing atherosclerosis (Hassel, 1998). The increase in triglycerides of hepatotoxic animals that consumed 10% *Gnetum africanum*-supplemented diet may be due to liver dysfunction that causes their excessive production while their reduction in the non-hepatotoxic group is attributed to the hypolipidemic properties of vegetable diets.

Haematological parameters namely PCV, WBC and differentials were monitored in this study because of their diagnostic significance and role in providing information concerning haematological changes caused by paracetamol-induced toxicity (Patrick-Iwuanyanwu *et al.*, 2007). Most phytochemical constituents of plant foods affect the immune system and other haematological parameters (Kubena and McMurray, 1996). The increase in PCV ($p < 0.05$) in hepatotoxic rats fed 10% *Gnetum africanum*-supplemented diet supports the increase in the levels of haemoglobin with the consumption of *Gnetum africanum* in a previous work by Iweala *et al.* (2009). This may be due to the presence of Haematinic factors in *Gnetum africanum* such as iron which plays a role in iron metabolism that increases the level of PCV and synthesis of haemoglobin (Alada, 2000; Edgerton *et al.*, 1972; Tindal, 1965). The non-significant change in the level of white blood cells of the animals is not in line with the work done by Iweala *et al.* (2009) where the levels of haemoglobin and white blood cells were significantly increased with the consumption of *Gnetum africanum*. This could be attributed to a rare case of hematologic side effects called thrombocytopenia often associated with paracetamol overdose. The increase in the levels of lymphocytes and neutrophils level of the hepatotoxic rats and those fed *Gnetum africanum*-supplemented diet

supports the study done by Duthie *et al.* (1996) which stated that antioxidant phytochemicals that can be found in *Gnetum africanum* are known to protect them. The phytochemical constituents of *Gnetum africanum* which include flavonoids and phytosterol are possible candidates that increase white blood cells (Iweala *et al.*, 2009).

The liver of non-hepatotoxic animals fed with *Gnetum africanum*-supplemented diet showed normal histological features. This result shows that the consumption of *Gnetum africanum*-supplemented diet does not have any apparent toxicity on the liver of rats. The necrotic effects of paracetamol seen in the abnormal histological changes in the liver of the animals is similar to that gotten by Hewawasam *et al.* (2004) where *Epaltes divaricata* plant extract was investigated against carbon tetrachloride induced hepatotoxicity. However, the consumption of *Gnetum africanum*-supplemented diet reduced this necrosis indicating some level of hepatoprotective and regenerative properties. Tropical green leafy vegetables are usually associated with hepatoprotective properties (Obboh, 2005).

The results of this study suggests that *Gnetum africanum* may be used in the treatment or prevention of paracetamol-induced hepatotoxicity probably due to its ability to preserve the structural integrity of hepatocytes when challenged with hepatotoxicants. Further study is suggested be carried out to help unravel the precise mechanism(s) for paracetamol-induced toxicity and the specific constituents of *Gnetum africanum* involved in hepatoprotection against hepatic toxicity.

REFERENCES

- Ahmed, M.B. and M.R. Khater, 2001. Evaluation of the protective potential of *Ambrosia maritime* extract on acetaminophen-induced liver damage. *J. Ethnopharmacol.*, 75: 169-174.
- Alada, A.R.A., 2000. The haematological effect of *Telfairia occidentalis* diet preparation. *Afr. J. Biomed. Res.*, 3: 185-186.
- AOAC, 1975. Official Methods of Analysis. 8th Edn., Association of Official Agricultural Chemists, Washington, DC, USA.
- Baylan, M., S. Canogullari, T. Ayasan and A. Sahin, 2006. Dietary threonine supplementation for improving growth performance and edible carcass parts in Japanese quails, *Coturnix coturnix Japonica*. *Int. J. Poult. Sci.*, 5: 635-638.
- Brent, J.A. and B.H. Rumack, 1993. Role of free radicals in toxic hepatic injury. *J. Toxicol. Clin. Toxicol.*, 31: 173-196.

- Buege, J.A. and S.D. Aust, 1978. Microsomal Lipid Peroxidation. In: Methods of Enzymology, Fleischer, S. and L. Packer (Eds.). Academic Press, New York, pp: 302-310.
- Burkill, H.M., 1994. The Useful Plants of West Tropical Africa. (Families E-J). Royal Botanical Gardens, Kew, pp: 90-94.
- Crocenzi, F.A., J.M. Pellegrino, E.J. Sanchez Pozzi, A.D. Mottino, E.A. Garay and M.G. Roma, 2000. Effect of silymarin on biliary salt secretion in the rat. *Biochem. Pharmacol.*, 59: 1015-1022.
- Dacie, J.V. and S.M. Lewis, 1990. Practical Haematology. 7th Edn., Churchill Livingstone, London, ISBN: 0443039526.
- Davidson, D.G.D. and W.N. Eastham, 1966. Acute liver necrosis following overdose of Paracetamol. *Br. Med. J.*, 2: 497-499.
- Davidson, S., R. Passmore, J.F. Brock and A.S. Truswell, 1975. Human Nutrition and Dietetics. 6th Edn., Churchill Livingstone, Edinburgh, pp: 756.
- Disbrey, B.D. and J.H. Rack, 1970. Histological Laboratory Methods. Livingstone, Edinburgh, ISBN: 0443006946, pp: 56-128.
- Doyle, J.A., 1998. Molecules, morphology, fossils and the relationship of Angiosperms and Gnetales. *Mol. Phylogenet. Evol.*, 9: 448-462.
- Duthie S.J., A. Ma, M.A. Ross and A.R. Collins, 1996. Antioxidant supplementation decreases oxidative DNA damage in human lymphocytes. *Cancer Res.*, 56: 1291-1295.
- Echard, B.W., N.A. Talpur, A.Y. Fan, D. Bagchi and H.G. Preuss, 2001. Effects of a herbal formulation on mild liver injury in rats produced by acute acetaminophen and/or alcohol ingestion. *Res. Com. Mol. Pathol. Pharmacol.*, 110: 73-85.
- Edgerton, V.R., S.L. Bryant, C.A. Gillespie and G.W. Gardner, 1972. Iron deficiency anemia and physical performance and activity of rats. *J. Nutr.*, 102: 381-399.
- Ekop, A.S., 2007. Determination of chemical composition of *Gnetum africana* (Afang) seeds. *Pak. J. Nutr.*, 6: 40-43.
- Ellman, G.L., 1959. Tissue sulfhydryl groups. *Arch. Biochem. Biophys.*, 82: 70-77.
- Fakurazi, S., U. Nanthini and I. Hairuszah, 2008. Hepatoprotective and antioxidant action of *Moringa oleifera* Lam. against acetaminophen induced hepatotoxicity in rats. *Int. J. Pharmacol.*, 4: 270-275.
- Fu, L.K., Y.F. Yu and M.G. Gilbert, 1999. *Gnetaceae*. In: Flora of China 4/Cycadaceae through Fagaceae, Wu, Z.Y. and P.H. Raven (Eds.). Science Press, Beijing.
- Gaw, A., R.A. Cowman, D.S. O'Reilly and J. Shepherd, 1995. Clinical Biochemistry: An Illustrated Color Text. Clinical Biochemistry, New York.
- Gunnell, D., V. Murray and K. Hawton, 2000. Use of paracetamol (Acetaminophen) for suicide and nonfatal poisoning: Worldwide patterns of use and misuse. *Suicide life Threat. Behav.*, 30: 313-326.
- Hassel, C.A., 1998. Animal models: New cholesterol raising and lowering nutrients. *Curr. Opin. Lipidol.*, 9: 7-10.
- Hemabarathy, B., B. Siti Balkis and F. Victor, 2009. Paracetamol hepatotoxicity in rats treated with crude extract of *Alpinia galanga*. *J. Biol. Sci.*, 9: 57-62.
- Hewawasam, R.P., K.A.P.W. Jayatilaka, C. Pathirana and L.K.B. Mudduwa, 2004. Hepatoprotective effect of *Epaltes divaricata* extract on carbon tetrachloride induced hepatotoxicity in mice. *Indian J. Med. Res.*, 120: 30-34.
- Isong, E.U., S.A.R. Adewusi, E.U. Nkanga, E.E. Umoh and E.E. Offiong, 1999. Nutritional and phytotherapeutic studies of three varieties of *Gnetum africanum* (Afang). *Food Chem.*, 64: 489-493.
- Iweala, E.E.J. and O. Obidoa, 2009a. Effect of a long term consumption of a diet supplemented with leaves of *Gongronema latifolium* Benth. on some biochemical and histological parameters in male albino rats. *J. Biol. Sci.*, 9: 859-865.
- Iweala, E.J. and O. Obidoa, 2009b. Some biochemical, haematological and histological responses to a long term consumption of *Telfairia occidentalis*-supplemented diet in rats. *Pak. J. Nutr.*, 8: 1199-1203.
- Iweala, E.E.J., F.O. Uhegbu and O. Obidoa, 2009. Biochemical and histological changes associated with long term consumption of *Gnetum africanum* Welw. Leaves in Rats. *Asian J. Biochem.*, 4: 125-132.
- Iweala, E.E.J. and O. Obidoa, 2010. Studies on some biochemical and histological changes associated with long term consumption of leaves of *Ocimum gratissimum* L. in male rats. *Am. J. Food Technol.*, 5: 376-384.
- Iwu, M.M., 1986. Empirical Investigation of Dietary Plants Used in Igbo Ethnomedicine. Nina Etkined Redgroove Publishing Co., New York, pp: 131-150.
- James, L.P., P.R. Mayeux and J.A. Hinson, 2003. Acetaminophen-induced hepatotoxicity. *Drug Metab Dispos.*, 31: 1499-1506.
- Khashab, M., A.J. Tector and P.Y. Kwo, 2007. Epidemiology of acute liver failure. *Curr. Gastroenterol. Rep.*, 9: 66-73.
- Kubena, K.S. and D.N. McMurray, 1996. Nutrition and the immune system: a review of the nutrient-nutrient interactions. *J. Am. Diet Assoc.*, 96: 1156-1164.

- Lowry, O.H., N.J. Rosebrough, A.L. Farr and R.J. Randall, 1951. Protein measurement with the folin phenol reagent. *J. Biol. Chem.*, 193: 265-275.
- Mialoundama, F., 1993. Nutritional and Socio-Economic Value of *Gnetum* Leaves in Central African Forest. In: Tropical Forests, People and Food: Biocultural Interactions and Applications to Development, Hladik, C.M. (Ed.). Parthenon Publishing Group, Carnforth, United Kingdom, ISBN: 1850703809.
- Mitchell, J.R., D.J. Jollow, W.Z. Potter, J.R. Gillette and B.B. Brodie, 1973. Acetaminophen-induced hepatic necrosis: IV. Protective role of glutathione. *J. Pharmacol. Exp. Ther.*, 187: 211-217.
- Oboh, G., 2005. Hepatoprotective property of ethanolic and aqueous extracts of fluted *T. occidentalis* leaves against garlic induced oxidative stress. *J. Med. Food*, 8: 560-563.
- Orhue, N.E.J., E.A.C. Nwanze and A. Okafor, 2005. Serum total protein, albumin and globulin levels in *Trypanosoma brucei*-infected rabbits: Effect of orally administered *Scoparia dulcis*. *Afr. J. Biotechnol.*, 4: 1152-1155.
- Pachathundikandi, S.K. and E.T. Varghese, 2006. Blood zinc protoporphyrin, serum total protein, and total cholesterol levels in automobile workshop workers in relation to lead toxicity: Our experience. *Indian J. Clin. Biochem.*, 21: 114-117.
- Patrick-Iwuanyanwu, K.C., M.O. Wegwu and E.O. Ayalogu, 2007. The protective nature of garlic, ginger and vitamin E on CCl₄-induced hepatotoxicity in rats. *Asian J. Biochem.*, 2: 409-414.
- Ray, S.D., V.R. Mumaw, R.R. Raju and M.W. Fariss, 1996. Protection of acetaminophen-induced hepatic apoptosis and necrosis by cholesteryl hemisuccinate pretreatment. *J. Pharmacol. Exp. Ther.*, 279: 1470-1483.
- Ray, S.D., A.M. Kumar and D. Bagchi, 1999. A novel proanthocyanidin IH636 grape seed extract increases *in vivo* Bcl-XL expression and prevents acetaminophen-induced programmed cell death in mouse liver. *Arch. Biochem. Biophys.*, 369: 42-58.
- Ryder, S. and I. Beckingham, 2001. ABC of diseases of liver, pancreas and biliary system. Other causes of parenchymal liver disease. *Br. Med. J.*, 322: 290-292.
- Smilkstein, J., L. Knapp, W. Kulig and H. Rumack, 1988. Efficacy of oral N-acetylcysteine in the treatment of acetaminophen overdose. Analysis of the national multicentre study (1976 to 1985). *N. Engl. J. Med.*, 319: 1557-1562.
- Suresh, K.S.V., C. Sujatha, J. Syamala, B. Nagasudha and S.H. Mishra, 2006. Protective effect of root extract of *Operculina turpethum* L. against paracetamol-induced hepatotoxicity in rats. *Indian J. Pharm. Sci.*, 68: 32-35.
- Tindal, H.D., 1965. Fruits and Vegetables of West Africa. 1st Edn., Food and Agriculture Organization, USA.
- Yen, F.L., T.H. Wu, L.T. Lin and C.C. Lin, 2007. Hepatoprotective and antioxidant effects of *Cuscuta chinensis* against acetaminophen-induced hepatotoxicity in rats. *J. Ethnopharmacol.*, 111: 123-128.