



# International Journal of Pharmacology

ISSN 1811-7775

**science**  
alert

**ansinet**  
Asian Network for Scientific Information

## Acute and Subacute Toxicity Studies of *Eurycoma longifolia* in Male Rats

<sup>1</sup>A.N. Shuid, <sup>1</sup>L.K. Siang, <sup>2</sup>T.G. Chin, <sup>1</sup>N. Muhammad, <sup>1</sup>N. Mohamed and <sup>1</sup>I.N. Soelaiman

<sup>1</sup>Department of Pharmacology, Faculty of Medicine, Universiti Kebangsaan Malaysia,  
Jalan Raja Muda Abd Aziz, 50300 KL, Malaysia

<sup>2</sup>Department of Pathology, UKM Medical Centre, Jalan Yaakob Latiff,  
Bandar Tun Razak, 56000 Cheras KL, Malaysia

**Abstract:** *Eurycoma longifolia* (EL) is a widely used herbal extract by men as aphrodisiac. However, there are no complete toxicity studies done on it. This study was conducted to determine the acute and subacute toxicities of EL on male Sprague-Dawley rats. Both acute and subacute studies were done according to the Organization for Economic Cooperation and Development (OECD) Guideline. In acute toxicity study, *Eurycoma longifolia* (EL) aqueous extract at the dose of 5000 mg kg<sup>-1</sup> body weight was given to rats within 24 h by oral gavage. In subacute toxicity study, the first group of rats served as the control group while the other three groups were given EL aqueous extract at doses of 600, 1200 and 2400 mg kg<sup>-1</sup> bodyweight, respectively via daily oral gavages for 28 days. Histopathological examination was done on the testes, kidneys and liver for acute and subacute toxicity study. Biochemistry and haematology analysis as well as thin blood film were done for subacute toxicity study. The oral LD<sub>50</sub> for EL aqueous extract was found to be more than 5000 mg kg<sup>-1</sup>. No pathological changes were observed in the rat liver, testes and kidneys in the acute toxicity study. Subacute toxicity study showed no significant changes in biochemical and haematological parameters while thin blood films were normal. No pathological changes were found in the testes and kidneys. However, hydropic changes were found in the livers of a few of the treated rats. This study shows the EL extract does not cause acute toxicity but was found to cause hepatotoxicity in subacute toxicity study.

**Key words:** *Eurycoma longifolia*, toxicity study, hepatotoxic, histopathology

### INTRODUCTION

*Eurycoma longifolia* is a traditional medical plant, known as Tongkat Ali in Malaysia, tung saw in Thailand, Pasak bumi in Indonesia and Cay ba bihn in Vietnam (Goreja, 2004). *E. longifolia* is an evergreen slow growing herbal plant, reaching a maximum height of 15-18 m and bearing fruits after nearly 2-3 years of cultivation. The leaves are pinnate, spirally arranged, long (10-15 inches) with 10 to 30 leaflets. The flowers are produced in large panicles. The roots which are rich in the active ingredients, can only be harvested for commercial use after 4 years of cultivation (Bhat and Karim, 2010). Studies have confirmed its aphrodisiac effects (Ang and Cheang, 2001; Ang *et al.*, 2003), anti-malarial (Bhat and Karim, 2010) and maintenance of bone calcium in androgen-deficient rats (Nazrun *et al.*, 2010). EL has been shown to promote dissociation of testosterone from sex-hormone binding globulin (Shawn and Kraemer, 2007).

With the increase in the demand for EL, efficient plantlet production using somatic embryogenesis system is required to meet the pharmaceutical needs and prevent EL plant from extinction (Hussein *et al.*, 2005). Studies are ongoing to determine the best method of extraction of EL. In a study, a mass transfer model of major phytochemical components from EL was developed to describe the solid-liquid extraction process. It was found that the yield of extraction of EL was increased with the increase in the extraction temperature (Mohamad *et al.*, 2010).

EL is not only available commercially in various preparations as health supplements but is also added to drinks such as tea and coffee. Despite its wide usage in men, the data on its toxicity is lacking or incomplete. OECD (Organization for Economic Cooperation and Development) defined acute toxicity as the toxic effects which appeared shortly after giving one or more doses of the chemical substance in 24 h. Acute toxicity study is conducted to define the intrinsic toxicity of a chemical

substance, sensitivity of a species towards the toxicity, target organs and information for risk assessment after acute exposure to the chemical substance (Paine and Marrs, 2000). Satayavivad *et al.* (1998) had conducted acute toxicity study on EL and found that the oral LD<sub>50</sub> of the alcoholic extract of EL in mice is 1500-2000 mg kg<sup>-1</sup> while the oral LD<sub>50</sub> for aqueous extract is more than 3000 mg kg<sup>-1</sup>. Mice receiving alcoholic extract of EL were found to exhibit toxicity signs while necropsy showed darken liver and lungs haemorrhage. However, the analysis on the blood chemistry or tissue histopathology was not done.

The objective of this study is to get a more complete information of the acute and subacute toxicities of the aqueous extract of EL using rat as the animal model.

## MATERIALS AND METHODS

The study was conducted from March, 2009 to May, 2010. *Eurycoma longifolia* extract was supplied by Phytes Biotek Sdn. Bhd. (Selangor, Malaysia) in the form of freeze dried standardized extract (Batch No: TA 071210). It is extracted from the root of the plant using a patented high pressure water extraction (US 7, 132, 117 B2), filtered at 1-4 micron and freeze dried without maltodextrin or lactose. The extract is in brownish powder form. It contains bioactive eurypeptide (>22%), glycosaponin (>40%) and eurycomanone (>1%). Male Sprague-Dawley rats (2-3 months of age) weighing between 250g-300g were obtained from the UKM Animal House. The rats were housed in a plastic cage at 29±3°C and daily dark/light cycle. They were fed standard food pellets and tap water *ad libitum*. They were allowed to adjust to the new environment for a week before the study was started. The study was approved by the UKM Animal Ethic Committee (PP/FAR/2008/NAZRUN/21-AUGUST/241-SEPT-2008-MAY, 2009).

Acute toxicity study was done according to the Organization for Economic Cooperation and Development (OECD) Acute Oral Toxicity-Fixed Dose Procedure 420 Guideline (OECD, 2001). Five rats were used for the acute toxicity study. The starting dose for the main study was set at 5000 mg kg<sup>-1</sup> body weight based on the sighting study. The crude aqueous extract powder was dissolved into normal saline to get 25% w/v EL crude extract solution. The dose was given within 24 h by oral gavage and the rats were observed for 14 days. Daily observation was done to check for mortality and abnormal clinical manifestations such as piloerection, salivation and lacrimation. The rats were weighed on day 1, 7 and 14. The rats were sacrificed after 14 days and the liver, kidneys and testes were taken out and fixed in neutral buffered

formalin for 72 h. They were then processed and stained with hematoxylin and eosin stain for histopathology examination. The slides were examined single-blindly by a qualified pathologist.

Subacute toxicity study was conducted according to OECD Test Guideline 407 (OECD, 1995). Thirty two Sprague-Dawley rats were randomly divided into four groups. The first group served as the control group while the rest of the groups were given crude aqueous extract of EL at doses of 600, 1200 and 2400 mg kg<sup>-1</sup> body weight, respectively via oral gavages for 28 days. The crude aqueous extract powder was dissolved into normal saline to get 7.5, 15 and 30% w/v for the 600, 1200 and 2400 mg kg<sup>-1</sup> dose, respectively. The body weight, mortality and clinical observations were recorded daily. At the end of the treatment, rats were fastened overnight and blood was taken via the orbital sinus under anaesthesia. Part of the blood samples was centrifuged at 825x g for 10 min to separate the sera in order to avoid haemolysis. The serum samples were used for measurements of Alanine Aminotransferase (ALT), Aspartate Aminotransferase (AST), Alkaline Phosphatase (ALP), total bilirubin, total protein and serum creatinine using an autoanalyser (Siemens Advia Chemistry 2400, US). Blood was also collected in EDTA tubes for measurements of Red Blood Cell count (RBC), Haemoglobin concentration (Hb), Mean Corpuscular Volume (MCV), Mean Corpuscular Haemoglobin Concentration (MCHC), total White blood Cell Count (WCC), differential white blood cell percentage, platelet count, bleeding time and clotting time using haematology analyser (Siemens Advia 2120, US).

Blood were also collected into EDTA tubes by cardiac puncture for peripheral blood smear. Wright stain was used to stain all blood smear samples. Finally rats were sacrificed and the brain, liver, kidneys and testes were taken out and weighed. Liver, kidneys and testes were fixed in neutral buffered formalin for 72 h and stained with hematoxylin and eosin stain for histopathology examination. The slides were examined single-blindly by a qualified pathologist.

**Statistical analysis:** The results were expressed as Mean±SEM. The statistical significance of the data has been determined using one-way Analysis of Variance (ANOVA) and post hoc Tukey test. The level of significance was taken as p<0.05.

## RESULTS

In the acute toxicity study, there were no significant differences in the body weight for all the rats (Fig. 1). Toxicity signs such as piloerection, salivation and

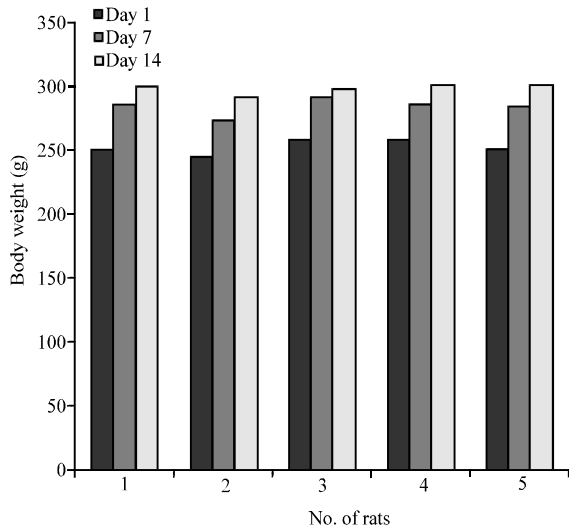


Fig. 1: Weekly mean body weight change in acute toxicity study. Data were expressed as Mean±SEM. The level of significance was taken at  $p < 0.05$

lacrimation were not observed. The oral lethal dose 50 ( $LD_{50}$ ) for crude aqueous extract of EL was more than  $5000 \text{ mg kg}^{-1}$  and cannot be categorized under the GHS (Globally Harmonised System) category. Histopathological examination of the liver, testes and kidneys tissues did not show any pathological changes.

In the subacute toxicity study, there were no significant differences in the body weight for all the rats (Fig. 2). Toxicity signs such as piloerection, salivation and lacrimation were not observed. The biochemistry parameters of the liver and kidneys of treated rats were not significantly different compared to the control groups (Table 1). There were also no significant differences in the hematological parameters between the control and treated groups (Table 2). Peripheral blood smear showed normal morphology of red blood cells in all the rats (data not shown). Histopathological examination did not show any pathological change in testis and kidney tissues. However, there were pathological changes in the liver tissues of two rats in the treated groups. The livers of a rat from  $1200 \text{ mg kg}^{-1}$ -treated group and another rat from  $2400 \text{ mg kg}^{-1}$ -treated group have shown hydropic changes (Fig. 3).

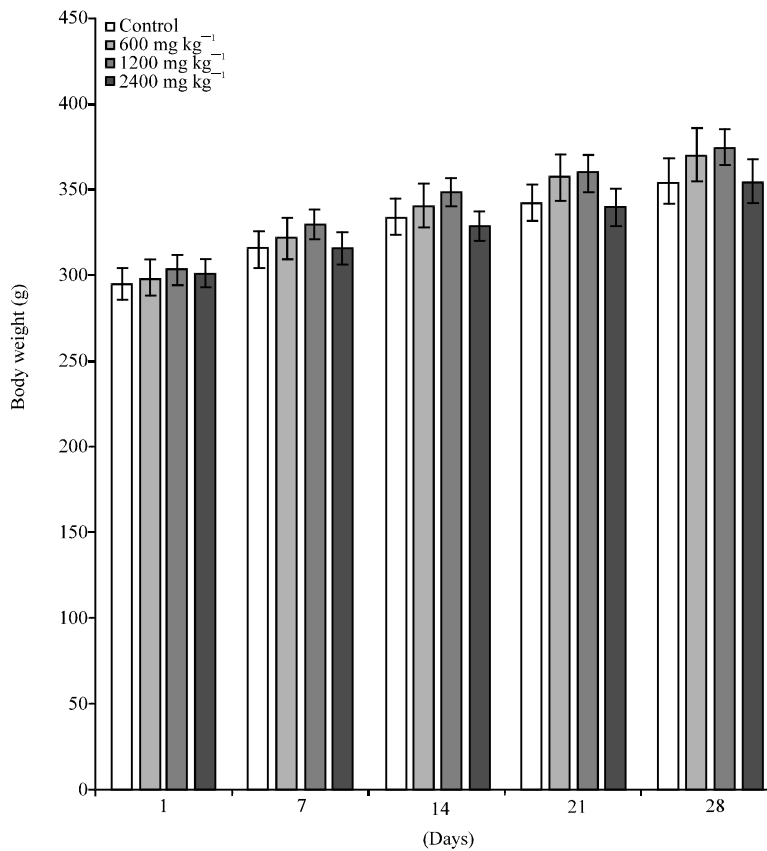


Fig. 2: Weekly mean body weight change in subacute toxicity study. Data were expressed as Mean±SEM. The level of significance was taken at  $p < 0.05$

Table 1: Biochemistry parameters

Parameters	Control	600 mg kg <sup>-1</sup>	1200 mg kg <sup>-1</sup>	2400 mg kg <sup>-1</sup>
ALT (IU L <sup>-1</sup> )	64.12±2.38	59.63±2.06	61.43±2.30	61.38±3.25
AST (IU L <sup>-1</sup> )	239.75±24.27	219.25±18.86	241.43±15.45	264.13±22.39
ALP (IU L <sup>-1</sup> )	221.75±38.96	157.25±18.39	177.71±28.08	190.25±23.65
Total bilirubin (µmol L <sup>-1</sup> )	1.75±0.16	1.75±0.16	2.00±0.01	1.75±0.25
Total protein (g L <sup>-1</sup> )	73.75±1.61	75.25±1.05	74.86±1.90	75.38±1.45
Creatinine (µmol L <sup>-1</sup> )	52.22±0.68	52.60±0.71	50.14±1.06	51.25±1.47

Data were expressed as Mean±SEM. The level of significance was taken at p<0.05

Table 2: Haematological parameters

Parameters	Control	600 mg kg <sup>-1</sup>	1200 mg kg <sup>-1</sup>	2400 mg kg <sup>-1</sup>
RBC count (×10 <sup>12</sup> L <sup>-1</sup> )	7.83±0.56	8.68±0.14	8.47±0.24	8.26±0.25
Haemoglobin concentration (g L <sup>-1</sup> )	15.69±0.19	15.45±0.22	14.94±0.67	15.39±0.70
MCV (fL)	54.25±0.59	53.63±0.78	53.00±1.27	54.35±0.71
MCHC (pg)	33.25±0.25	32.75±0.25	32.96±0.3328	32.75±0.2314
Platelet count (×10 <sup>9</sup> L <sup>-1</sup> )	1051.38±75.75	1050.29±88.03	1131.14±58.06	1104.57±101.00
Bleeding time (s)	152.63±13.33	160.00±9.50	136.43±8.98	148.86±14.35
Clotting time (s)	152.63±13.33	160.00±8.89	136.43±8.98	148.88±14.50
Total white cell count (×10 <sup>9</sup> L <sup>-1</sup> )	15.14±2.00	15.51±1.97	12.06±1.43	12.93±1.00
Lymphocyte (%)	50.62±8.40	49.63±8.40	65.71±2.72	64.13±2.36
Monocyte (%)	4.75±0.65	4.50±0.73	3.43±0.57	2.45±0.87
Neutrophil (%)	41.13±8.24	42.13±8.47	28.57±3.40	29.37±2.46
Eosinophil (%)	2.75±1.00	2.38±0.68	0.29±0.29	0.88±0.40

Data were expressed as Mean±SEM. The level of significance was taken at p<0.05

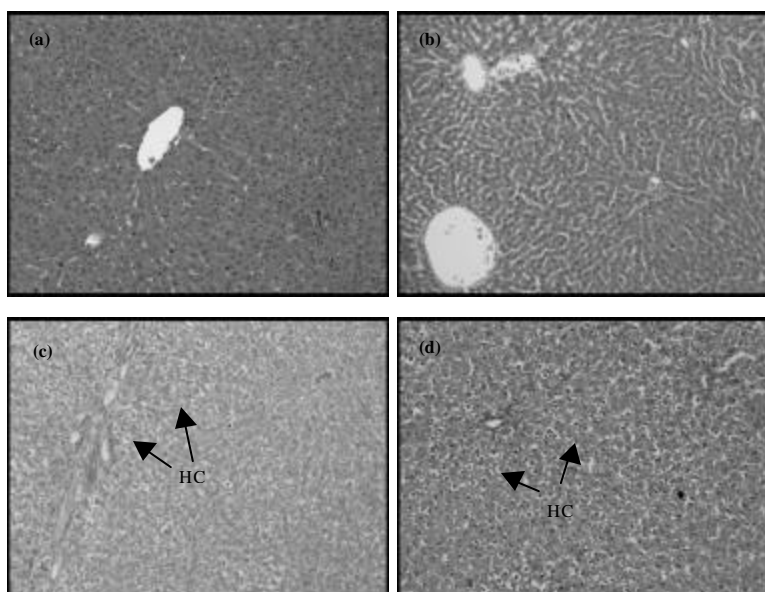


Fig. 3 (a-d): Hepatocytes stained with H and E. (a) The hepatocytes of control group, (b) 600 mg kg<sup>-1</sup> EL treated group show normal histology. Hydropic changes (HC) were seen in the (c) 1200 mg kg<sup>-1</sup> and (d) 2400 mg kg<sup>-1</sup>. EL treated groups. (H and E; X100)

## DISCUSSION

Male rats were used in this toxicity study as EL is taken mainly by men for its aphrodisiac effects. Based on our toxicity study on rat, the oral LD<sub>50</sub> for aqueous extract of EL was more than 5000 mg kg<sup>-1</sup>. It is unlikely to cause

fatality in human as the equivalent dose of EL is 35 in a 70 kg<sup>-1</sup> man. We may be the first to report on the effects of *E. longifolia* aqueous extract on liver, kidneys and testes of rat model. Histopathological examination of the subacute study revealed normal histology of the testis and kidney tissues but there were hydropic changes

seen in the hepatocytes of two rats, one each from the 1200 and 2400 mg kg<sup>-1</sup> treated groups. These degenerative changes were an early manifestation of cell injury, characterized by vacuolization of cell with the nuclei in the centre due to accumulation of water in the cells. It is reversible but if the injuries persisted, necrosis will occur. Despite of the pathological changes in the livers, the ALT levels of the affected rats were not raised. This specific enzyme for liver injury usually peaks for 1 to 2 days only and then drops back to basal level (Gabriel and Michel, 2008), thus making it difficult to rely on its level. It is evident that EL aqueous extract had caused hepatocellular injury but based on the normal levels of ALP and total bilirubin combined with the absence of bile retention in the liver tissue, it did not seem to cause liver cholestasis. In a study on the liver enzymes, EL was not found to have any effects on the human cytochrome P450 system. The ethanolic extract of EL has shown negligible inhibitory activities towards three cytochrome P450 enzymes i.e., CYP2C9, CYP2D6 and CYP3A4 (Hanapi *et al.*, 2010).

EL extract may contain compounds which are toxic to liver. The bioactive compounds of EL are quassinoids (Guo *et al.*, 2005) consisting of eurycomalactone (Goh *et al.*, 1995), eurycomanone (Goh *et al.*, 1995), eurylactone (Grieco *et al.*, 1995) and longilactone (Rahman *et al.*, 1997). Other compounds are saponin, sterol, terpenoids and alkaloid (Goh *et al.*, 1995). Subacute oral intake of EL aqueous extract was hepatotoxic to rats given 1200 and 2400 mg kg<sup>-1</sup> treated groups. This dose was equivalent to at least 8200 mg of EL aqueous extract taken by a 70 kg<sup>-1</sup> man. The highest dose of EL normally recommended is about 400 mg per day which is a relatively safe dose from its hepatotoxic effects.

In conclusion, acute oral intake of aqueous extract EL does not cause acute toxicity to rats. Subacute oral intake of aqueous extract EL may cause liver toxicity in rats. Further chronic toxicity study should be carried out and the compound in EL which has the potential to cause liver toxicity should be identified. With these findings, we recommend that EL should be used with caution especially in elderly or patients with liver problems.

#### ACKNOWLEDGMENT

We thank the Faculty of Medicine UKM for providing the grant FF-226-2008 for this study.

#### REFERENCES

- Ang, H.H. and H.S. Cheang, 2001. Effects of *Eurycoma longifolia* Jack on laevator ani muscle in both uncastrated and testosterone-stimulated castrated intact male rats. Arch. Pharm. Res., 24: 437-440.
- Ang, H.H., T.H. Ngai and T.H. Tan, 2003. Effects of *Eurycoma longifolia* Jack on sexual qualities in middle aged male rats. Phytomedicine, 10: 590-593.
- Bhat, R. and A.A. Karim, 2010. Tongkat Ali (*Eurycoma longifolia* Jack): A review on its ethnobotany and pharmacological importance. Fitoterapia, 7: 669-679.
- Gabriel, L.P. and C. Michel, 2008. Detection and Evaluation of Chemically Induced Liver Injury. In: Principles and Methods of Toxicology, Wallace, A.H. (Ed.). CRC Press, New York, pp: 1465-1507.
- Goh, S.H., C.C. Hock, J.S.L. Mok and E. Soepadmo, 1995. Malaysian Medicinal Plants for the Treatment of Cardiovascular Disease. Pelanduk Publication, Sdn Bhd, Kuala Lumpur.
- Goreja, W.G., 2004. Tongkat Ali: Tree that Cures a Hundred Diseases. Amazing Herbs Press, New York, pp: 1-42.
- Grieco, P.A., J.M.V. Roest, M.M. Pineiro-Nunez, E.E. Campaigne and M. Carmack, 1995. Polyandrol, a C<sub>19</sub> quassinoid from *Castela polyandra*. Phytochemistry, 38: 1463-1465.
- Guo, Z., S. Vangapandu, R.W. Sindelar, L.A. Walker and R.D. Sindelar, 2005. Biologically active quassinoids and their chemistry: Potential leads for drug design. Curr. Med. Chem., 12: 173-190.
- Hanapi, N.A., J. Azizi, S. Ismail and S.M. Mansor, 2010. Evaluation of selected Malaysian medicinal plants on phase I drug metabolizing enzymes, CYP2C9, CYP2D6 and CYP3A4 activities *in vitro*. Int. J. Pharmacol., 6: 494-499.
- Hussein, S., R. Ibrahim, A.L.P. Kiong, N.M. Fadzillah and S.K. Daud, 2005. Micropropagation of *Eurycoma longifolia* jack via formation of somatic embryogenesis. Asian J. Plant Sci., 4: 472-485.
- Mohamad, M., M.W. Ali and A. Ahmad, 2010. Modelling for extraction of major phytochemical components from *Eurycoma longifolia*. J. Applied Sci., 10: 2572-2577.
- Nazrun, A.S., M. Norazlina, M. Norliza and S.I. Nirwana, 2010. Comparison of the effects of tocopherol and tocotrienol on osteoporosis in animal models. Int. J. Pharmacol., 6: 561-568.

- OECD, 1995. OECD guidelines for testing of chemicals: Guideline 407: Repeated dose 28-day oral toxicity in rodents. Office of Economic and Community Development, Paris.
- OECD, 2001. OECD guidelines for testing of chemicals: Guideline 420: Acute oral toxicity: Fixed dose method. Office of Economic and Community Development, Paris. <http://www.oecd.org/dataoecd/17/49/1948362.pdf>.
- Paine, A.J. and T.C. Marrs, 2000. The Design of Toxicological Study. In: General and Applied Toxicology, Ballantyne, B., T.C. Marrs and T. Syversen (Eds.). Grove's Dictionaries Inc., New York, pp: 321-334.
- Rahman, S., N. Fukamiya, N. Ohno, H. Tokuda and H. Nishino *et al.*, 1997. Inhibitory effects of quassinoid derivatives on Epstein-Barr virus early antigen activation. *Chem. Pharm. Bull.*, 45: 675-677.
- Satayavivad, J., S. Noppamas, S. Aimon and T. Yodhathai, 1998. Toxicological and antimalaria activity of *Eurycoma longifolia* Jack extracts in mice. *Thai J. Phytopharm.*, 5: 14-27.
- Shawn, T. and W. Kraemer, 2007. The Cortisol Connection. Hunter House Inc., California, pp: 102-113.