



# International Journal of Pharmacology

ISSN 1811-7775

**science**  
alert

**ansinet**  
Asian Network for Scientific Information

## Protective Activity of *Fumaria vaillantii* Extract and Monomethyl Fumarate on Acetaminophen Induced Hepatotoxicity in Mice

<sup>1,5</sup>Ezzat Zamani-Moghaddam, <sup>1,2</sup>Kian Azami, <sup>3</sup>Bagher Minaei-Zangi,  
<sup>5</sup>Seydeh Zahra Mousavi and <sup>1,4</sup>Omid Sabzevari

<sup>1</sup>Department of Toxicology and Pharmacology, Faculty of Pharmacy,  
Tehran University of Medical Sciences, Tehran-1417614411, Iran

<sup>2</sup>Toxicology and Poisoning Research Centre,

Tehran University of Medical Sciences, Tehran-1417614411, Iran

<sup>3</sup>Department of Histology, Faculty of Medicine, Tehran University of Medical Sciences, Tehran, Iran

<sup>4</sup>Drug Design and Development Research Center,

Tehran University of Medical Sciences, Tehran-1417614411, Iran

<sup>5</sup>Pharmaceutical Sciences Branch, Islamic Azad University, Tehran, Iran

**Abstract:** Mono Methyl Fumarate (MMF) is active component of *Fumaria* sp. methanolic extract. In Iranian traditional medicine, Fumitory is used widely as a remedy for several diseases including liver dysfunction. In the present study, effect of monomethyl fumarate and *Fumaria* extract was investigated against acetaminophen-induced acute liver damage and compared to a known hepatoprotective plant, *Silybum marianum* and its active ingredient, silymarin. Biochemical parameters including AST, ALT, LDH, ALKP and total and direct bilirubin were measured in serum samples. Glutathione (GSH and GSSG) and Malon Di Aldehyde (MDA) contents were determined in mouse liver homogenates. Liver sections were also collected for histopathological examination. Acetaminophen produced acute toxicity at the dose of 640 mg kg<sup>-1</sup> in mice while pretreatment and post treatment of animals (i.p., twice daily for 48 h) with monomethyl fumarate, silymarin (25, 50 and 100 mg kg<sup>-1</sup>) or the plant extracts (300 and 500 mg kg<sup>-1</sup>) significantly lowered the rise of ALT, AST, LDH, ALKP and bilirubin (Total and direct) in serum. In addition, both compounds and the plant extracts significantly increased glutathione content and reduced MDA level of the liver. Taken collectively, the results indicate that monomethyl fumarate and *Fumaria* extract exhibited hepatoprotective action against acetaminophen liver injury which is comparable to that of *Silybum marianum* and silymarin.

**Key words:** Monomethyl fumarate, *Fumaria vaillantii*, acetaminophen, hepatoprotection

### INTRODUCTION

Liver as the key organ in the human body plays an important role for detoxification of entered xenobiotics through phase I and II process. Liver cells therefore, are exposed to high concentration of toxic agents (their metabolites) and can metabolize toxicants for elimination (Guengrich, 2000). Acetaminophen, an analgesic and antipyretic medicine, is mostly metabolized in the liver through glucuronidation and sulfation pathway (Moling *et al.*, 2006). It is transformed, however, to a reactive intermediate, N-acetyl parabenzo quinoreimine which is known to cause centrilobular liver damage and mediate oxidative stress (Zhang *et al.*, 2004; Olaleye and Rocha, 2008). Acetaminophen induced

hepatotoxicity is now a commonly used model for liver damage study to screen hepatoprotective activity of natural medicines (Handa *et al.*, 1986; Natanzi *et al.*, 2009). Application of natural products for liver disease is growing because of their safety and efficacy as an alternative remedy.

Silymarin, a flavolignan component of *Silybum marianum* seeds, has been studied extensively for its protective action against acetaminophen induced liver toxicity (Anundi, 2006; Ellithy and Nada, 2006). *In vitro* studies have showed that it has an inhibitory effect on phase I and II drug metabolizing enzymes (Ramellini and Meldolesi, 1976). By stabilizing the structure of biological membranes, silymarin prevents liver damage which is possibly due to its ability to scavenge

**Corresponding Author:** Omid Sabzevari, Department of Toxicology and Pharmacology, Faculty of Pharmacy,  
Tehran University of Medical Sciences, Tehran-1417614411, Iran  
Tel: +9821 6649 4994, +9821 6412 2161

free radicals. This limits lipid-peroxidation process that contributes in membrane damage by hepatotoxins (Valenzuela *et al.*, 1985). Motivation of lipid peroxidation may arise from the free radicals formation through a weakness of antioxidants leading to oxidative stress (Mortazavi *et al.*, 2007; Meera *et al.*, 2008; Diallo *et al.*, 2009; Prasanna and Purnima, 2011). *Fumaria vaillantii* Loisei. (Fumariaceae) is a species of flowering plant which grows widely in Iran (Zargari, 1989), is used in the Iranian folk medicine for diseases of skin and stimulation of hepatic function and gall bladder. It has also been used as anti-bronchite, antineoplastic, antipyretic, antiscabies, antiscorbite, appetizer, diaphoretic, diuretic and expectorant (Amin, 1991). Monomethyl fumarate (MMF), isolated from the methanolic extract of the whole plant of *Fumaria indica* (another species of genus *Fumaria*), has demonstrated antihepatotoxic activity (Rao and Mishra, 1998) against thioacetamide *in vitro* and against carbon tetrachloride, paracetamol and rifampin toxicities *in vivo* (Rao and Mishra, 1996). Limited information is available on protective effect of monomethyl fumarate and *Fumaria* sp. extract against acetaminophen-induced liver toxicity. A good protection of *Fumaria parviflora* and *Momordica balsamina* extracts from carbon tetrachloride induced hepatotoxicity in rats has been reported (Alqasoumi *et al.*, 2009).

Damage to the structural integrity of the liver is concluded from histopathological examine and elevated activities of aspartate aminotransferase (AST), Alanine aminotransferase (ALT), Lactate Dehydrogenase (LDH) and Alkaline Phosphatase (ALKP), as well as Malondialdehyde (MDA) concentrations as the end product of lipid peroxidation (Ghazi-Khansari *et al.*, 2005; Iyawe *et al.*, 2006; Koriem *et al.*, 2009; Kanbur *et al.*, 2009; Chavda *et al.*, 2010; Natanzi *et al.*, 2010).

Evaluations of these parameters in the serum and tissue samples of experimental animals are used to assess liver toxicity and protective effects of novel compounds as indicators of hepatoprotective activity (Kumar *et al.*, 2009; Dahiru and Obidoa, 2007). The aim of this study was to investigate effect of monomethyl fumarate and *Fumaria* extract against acetaminophen-induced acute liver damage and to compare with a known hepatoprotective plant, *Silybum marianum* and its active ingredient, silymarin.

## MATERIALS AND METHODS

**Plant collection:** The whole plant of *Fumaria vaillantii* Loisei. was collected from Bojnourd region, North East of Iran and *Silybum marianum* was collected from Kelardasht region, North of Iran.

**Chemicals:** Acetaminophen, ethanol, methanol and Tween 80 were purchased from Merck Company

(Germany). Monomethyl fumarate and silymarin were purchased from Sigma-Aldrich Company (USA).

**Preparation of extracts:** Aerial parts of the *F. vaillantii* washed and cleaned with water, then dried and were macerated with 80% ethanol solution by 4-6 times extraction within five days. The resulting extract was filtered and then evaporated by rotary instrument under reduced pressure.

**Animals:** Male mice (25-30 g) purchased from Pasteur institute (Tehran, Iran), were used through this study. The animals were treated on the standard condition with free access to drinking water and feed under constant room temperature (25°C) and humidity (50±10%) with an automatic 12 h light and 12 h dark cycle. The experimental procedures were carried out under policy of MOH Convention for the Protection of Vertebrate Animals Used for Experimental and other Scientific Purposes and the protocol was approved by the Ethics Committee of the Tehran University of Medicine Sciences (TUMS), Tehran, Iran.

**Experimental procedure:** The hepatoprotective effect of the total plant extracts and the active components were studied at two (300 and 500 mg kg<sup>-1</sup>, i.p.) and three doses (25, 50 and 100 mg kg<sup>-1</sup>, i.p.), respectively according to pre- and post-treatment schedule:

**Pre-treatment:** Mice were divided into 6 groups of 6 animals each:

- Group 1: Vehicle control (NS: sodium chloride 0.9%), Blank
- Group 2: Six doses of acetaminophen (640 mg kg<sup>-1</sup>, i.p.) were administrated
- Groups 3/4: 6 doses of *F. vaillantii* extract (300/500 mg kg<sup>-1</sup>) at 12 h intervals
- Groups 5/6: 6 doses of *Silybum marianum* extract (300/500 mg kg<sup>-1</sup>) at 12 h intervals
- Groups 7/8/9: 6 doses of monomethyl fumarate (25/50/100 mg kg<sup>-1</sup>) at 12 h intervals
- Groups 10/11/12: 6 doses of silymarin (25/50/100 mg kg<sup>-1</sup>) at 12 h intervals. Acetaminophen (640 mg kg<sup>-1</sup>, i.p.) was administered 1 h after the last dose in groups 3-12

**Post-treatment:** Mice were divided into 6 groups of 6 animals each:

- Groups 13/14: Six doses of *F. vaillantii* extract (300/500 mg kg<sup>-1</sup>) at 12 h intervals

- Groups 15/16: 6 doses of *Silybum marianum* extract (300/500 mg kg<sup>-1</sup>) at 12 h intervals
- Groups 17/18/19: 6 doses of monomethyl fumarate (25/50/100 mg kg<sup>-1</sup>) at 12 h intervals
- Groups 20/21/22: 6 doses of silymarin (25/50/100 mg kg<sup>-1</sup>) at 12 h intervals. Acetaminophen (640 mg kg<sup>-1</sup>, i.p.) was administered 1 h before the first dose in groups 13-22. Then, 24 h after the last dose, the animals were anaesthetized by ketamine/xylazine and blood samples were obtained from heart. The blood serum was separated by centrifugation at 2000 g for 20 min and kept at -70°C until use. The assays of bilirubin (Total and direct), aspartate aminotransferase (AST), alanine aminotransferase (ALT), Lactate Dehydrogenase (LDH), Alkaline Phosphatase (ALKP) activities were performed using Ellitech diagnostic kits (Sees, France)

**Estimation of MDA:** The quantitative measurement of lipid peroxidation in liver homogenate was determined according to the method described by Esterbauer and Cheeseman (1990). The amount of MDA formed was quantified by reaction with Thiobarbituric Acid (TBA) as the red colored complex measured at the wavelength 532 nm.

**Determination of GSH, GSSG:** Liver GSH content was measured by a colorimetric technique, based on the production of a yellow color when 5, 5-dithiobis-2-nitrobenzoic acid (DTNB) is added to compounds with sulfhydryl groups. Homogenates of liver tissue were acidified with 50% (W/V) trichloroacetic acid and centrifuged at 8000 g for 20 min. The supernatant was divided into two equal tubes: To the first tube, 2 mL of 0.4 M tris buffer, pH 8.9 and 0.5 mL of 0.1 M DTNB were added, vortexed and the absorbance read at 412 nm after 5 min, in order to analyze GSH. For GSSG determination,

1 mL of 5% NaBH<sub>4</sub> slowly was added to the second tube and incubated for 1 h at 45°C. Consequently, 0.5 mL of 0.3 M Na<sub>2</sub>HPO<sub>4</sub> was added and the pH adjusted to 7.2 by 2 N HCl. Then, 0.5 mL of 0.1 M DTNB was added, vortexed and the absorbance was read at 412 nm after 5 min. The amounts of GSH measured in the second tube minus the amount of GSH in the first tube gives the extra amount of GSH in the first tube. Dividing the result by 2 gives the equivalent of GSSG.

**Histopathological studies:** Following autopsy, livers were immediately removed and fixed in 10% formalin for at least 24 h. The paraffin sections were then prepared and cut into 5 µm-thick sections using a rotary microtome. The sections were stained with haematoxylin-eosin dye and mounted with Canada balsam. The histopathological slides were examined and photographs were taken using Carl Zeiss Jena amplual type photomicroscope.

**Statistical analysis:** Data are presented as Mean ±SE and all comparisons were analyzed by one-way analysis of variance (ANOVA) and probability levels of less than 0.05 were considered significant.

## RESULTS

Administration of acetaminophen (640 mg kg<sup>-1</sup>, i.p.) significantly increased measured serum biochemical parameters including ALT, AST, LDH, ALKP and bilirubin (Total and direct). In liver tissue homogenate, GSH content was reduced while GSSG and MDA concentrations were markedly increased.

**Effects of total plant extract treatment on biochemical serum parameters:** Plant extracts (300 and 500 mg kg<sup>-1</sup>) significantly lowered the rise of ALT, AST, LDH, ALKP and bilirubin (Total and direct) in serum. Furthermore, treatment with 300 mg kg<sup>-1</sup> showed the best response

Table 1: Effect of *Fumaria vaillantii* total extract (FTE), *Silybum marianum* total extract (STE), monomethyl fumarate (MMF) and silymarin on biochemical serum parameters in pre-treatment study

Groups	Dose mg dL <sup>-1</sup> (i.p.)	AST (U L <sup>-1</sup> )	ALT (U L <sup>-1</sup> )	LDH (U L <sup>-1</sup> )	ALKP (U L <sup>-1</sup> )	B.T (mg dL <sup>-1</sup> )	B.D (mg dL <sup>-1</sup> )
Blank	Normal saline	45±6	54±8	90.33±6	85±9	0.16±0.02	0.14±0.01
Acetaminophen	640	224±12 <sup>1</sup>	196±18 <sup>1</sup>	170±14 <sup>1</sup>	180±16 <sup>1</sup>	0.50±0.04 <sup>1</sup>	0.42±0.03 <sup>1</sup>
FTE	300	95±7 <sup>3</sup>	97±8 <sup>3</sup>	121±11 <sup>3</sup>	127±12 <sup>3</sup>	0.27±0.03 <sup>3</sup>	0.22±0.02 <sup>3</sup>
FTE	500	169±17 <sup>2</sup>	141±13 <sup>3</sup>	145±15 <sup>3</sup>	162±12 <sup>3</sup>	0.43±0.04 <sup>3</sup>	0.37±0.03 <sup>3</sup>
STE	300	89±9 <sup>2</sup>	85±8 <sup>2</sup>	112±12 <sup>2</sup>	96±9 <sup>2</sup>	0.21±0.02 <sup>2</sup>	0.19±0.01 <sup>2</sup>
STE	500	131±12 <sup>2</sup>	138±11 <sup>2</sup>	135±13 <sup>2</sup>	142±14 <sup>2</sup>	0.31±0.03 <sup>2</sup>	0.28±0.02 <sup>2</sup>
MMF	25	91±8 <sup>3</sup>	82±6 <sup>3</sup>	109±12 <sup>3</sup>	103±11 <sup>3</sup>	0.18±0.03 <sup>3</sup>	0.16±0.02 <sup>3</sup>
MMF	50	147±15 <sup>3</sup>	107±12 <sup>3</sup>	119±12 <sup>3</sup>	116±11 <sup>3</sup>	0.19±0.02 <sup>3</sup>	0.20±0.03 <sup>3</sup>
MMF	100	157±14 <sup>3</sup>	129±12 <sup>3</sup>	122±13 <sup>3</sup>	138±15 <sup>3</sup>	0.40±0.03 <sup>3</sup>	0.384±0.02 <sup>3</sup>
Silymarin	25	81±5 <sup>2</sup>	71±6 <sup>2</sup>	94±9 <sup>2</sup>	87±7 <sup>2</sup>	0.17±0.03 <sup>2</sup>	0.15±0.02 <sup>2</sup>
Silymarin	50	105±10 <sup>2</sup>	99±8 <sup>2</sup>	97±9 <sup>2</sup>	91±7 <sup>2</sup>	0.18±0.02 <sup>2</sup>	0.17±0.01 <sup>2</sup>
Silymarin	100	114±12 <sup>2</sup>	103±9 <sup>2</sup>	115±11 <sup>2</sup>	122±13 <sup>2</sup>	0.33±0.04 <sup>2</sup>	0.26±0.03 <sup>2</sup>

AST: Aspartate aminotransferase, ALT: Alanine aminotransferase, LDH: Lactate dehydrogenase, ALKP: Alkaline phosphatase, B.T: Bilirubin total, B.D: Bilirubin direct, STE: Total extract of *Silybum marianum*, FTE: Total extract of *Fumaria vaillantii*, MMF: Monomethyl fumarate, Values represent the Mean±SE (n = 5), <sup>1</sup>p<0.001 as compared with blank, <sup>2</sup>p<0.01 and <sup>3</sup>p<0.05 as compared with acetaminophen

Table 2: Effect of *Fumaria vaillantii* total extract (FTE), *Silybum marianum* total extract (STE), monomethyl fumarate (MMF) and silymarin on biochemical serum parameters in post-treatment study

Groups	Dose mg kg <sup>-1</sup> (i.p.)	AST (U L <sup>-1</sup> )	ALT (U L <sup>-1</sup> )	LDH (U L <sup>-1</sup> )	ALKP (U L <sup>-1</sup> )	B.T (mg dL <sup>-1</sup> )	B.D (mg dL <sup>-1</sup> )
Blank	Normal saline	45±6	54±8	90.33±6	85±9	0.16±0.02	0.14±0.01
Acetaminophen	640	224±12 <sup>1</sup>	196±18 <sup>1</sup>	170±14 <sup>1</sup>	180±16 <sup>1</sup>	0.5±0.04 <sup>1</sup>	0.42±0.03 <sup>1</sup>
FTE	300	137±11 <sup>3</sup>	152±15 <sup>3</sup>	194±17 <sup>3</sup>	151±14 <sup>3</sup>	0.29±0.02 <sup>3</sup>	0.37±0.03 <sup>3</sup>
FTE	500	184±16 <sup>2</sup>	187±18 <sup>2</sup>	227±21 <sup>3</sup>	171±14 <sup>3</sup>	0.42±0.04 <sup>3</sup>	0.41±0.03 <sup>3</sup>
STE	300	97±8 <sup>2</sup>	83±7 <sup>2</sup>	121±11 <sup>2</sup>	118±10 <sup>2</sup>	0.26±0.03 <sup>2</sup>	0.23±0.01 <sup>2</sup>
STE	500	154±14 <sup>2</sup>	173±16 <sup>2</sup>	226±19 <sup>2</sup>	181±17 <sup>2</sup>	0.37±0.02 <sup>2</sup>	0.39±0.03 <sup>2</sup>
MMF	25	120±13 <sup>3</sup>	137±14 <sup>3</sup>	178±16 <sup>3</sup>	140±15 <sup>3</sup>	0.28±0.03 <sup>3</sup>	0.25±0.02 <sup>3</sup>
MMF	50	147±15 <sup>3</sup>	141±12 <sup>3</sup>	183±17 <sup>3</sup>	150±16 <sup>3</sup>	0.38±0.04 <sup>3</sup>	0.32±0.03 <sup>3</sup>
MMF	100	162±14 <sup>3</sup>	161±12 <sup>3</sup>	193±18 <sup>3</sup>	162±15 <sup>3</sup>	0.41±0.03 <sup>3</sup>	0.34±0.03 <sup>3</sup>
Silymarin	25	82±5 <sup>2</sup>	76±6 <sup>2</sup>	102±9 <sup>2</sup>	93±8 <sup>2</sup>	0.21±0.03 <sup>2</sup>	0.25±0.02 <sup>2</sup>
Silymarin	50	133±14 <sup>2</sup>	130±13 <sup>2</sup>	138±15 <sup>2</sup>	134±11 <sup>2</sup>	0.24±0.02 <sup>2</sup>	0.27±0.03 <sup>2</sup>
Silymarin	100	148±11 <sup>2</sup>	153±14 <sup>2</sup>	192±17 <sup>2</sup>	152±13 <sup>2</sup>	0.31±0.02 <sup>2</sup>	0.33±0.03 <sup>2</sup>

AST: Aspartate aminotransferase, ALT: Alanine aminotransferase, LDH: Lactate dehydrogenase, ALKP: Alkaline phosphatase, B.T: Bilirubin total, B.D: Bilirubin direct, STE: Total extract of *Silybum marianum*, FTE: Total extract of *Fumaria vaillantii*, MMF: Monomethyl fumarate. Values represent the mean±SE (n = 5), <sup>1</sup>p<0.001 as compared with blank, <sup>2</sup>p<0.01 and <sup>3</sup>(p<0.05 as compared with acetaminophen

from two plants extracts. In this context, the extracts were more effective in the pre-treatment study (Table 1, 2).

**Effects of plant active components (MMF and silymarin) on biochemical serum parameters:** The data showed that MMF and silymarin (25, 50 and 100 mg kg<sup>-1</sup>) significantly lowered the rise of LDH, ALT, AST, ALKP and bilirubin (Total and direct) in serum. Among the employed doses, the best response was achieved from 25 mg kg<sup>-1</sup>. In addition, the pre-treatment study considerably was effective (Table 1, 2).

**Effect of plant extracts on GSH, GSSG and MDA in liver tissue homogenate:** Treatment with plant extracts showed a significant increase in the GSH content and decrease in the GSSG (Table 3). The remarkable increase of MDA by acetaminophen was significantly inhibited by administration of *F. vaillantii* and *S. marianum* extracts. The observed effect in the pre-treatment study was more apparent (Table 3).

**Effect of plant active components (MMF and silymarin) on GSH, GSSG and MDA:** Administration of MMF and silymarin effectively increased GSH content and decreased GSSG. MDA concentration was also lowered by MMF and Silymarin which was more significant in the pre-treatment study (Table 3).

**Histological studies:** The results of histological study have presented in Fig. 2. Exposures of rat hepatocytes to acetaminophen (640 mg kg<sup>-1</sup>) lead to histopathological changes including increased mononuclear infiltration, hemorrhage and degeneration of hepatocytes (necrosis) at 24 h (Fig. 2b) in comparison with blank (Fig. 2a). Liver tissue of rats treated with plant extracts (Fig. 2c-f), MMF (Fig. 2g-h) and silymarin (Fig. 2i, j) showed good recovery with absence of necrosis and fatty depositions of hepatocytes.

## DISCUSSION

To screen hepatoprotective activity of medicines, acetaminophen induced liver toxicity is a commonly used model (Handa *et al.*, 1986). In the pharmaceutical market, herbal medicines have considerable portion in which a good number of marketed drugs are directly or indirectly derived from plants. The present study shows that *F. vaillantii* and MMF can reduce acute liver damage caused by acetaminophen, as indicated by significant reduction of the elevated serum biochemical parameters such as ALT, AST, LDH, ALKP, D.B and T.B; increase of GSH content, reduction of GSSG and MDA in liver tissue homogenate, as well as classic histological changes, in a similar manner to that of *S. marianum* and silymarin.

Presence of isoquinoline alkaloids namely protropin, fumaridine fumaramine, adlumidine, d-bicuculline, vaillantine and rutin in *F. vaillantii* has been indicated (Suau *et al.*, 2002; Ramellini and Meldolesi, 1976). It has been shown, however, that MMF is the active component of *Fumaria* sp. which can act as hepatoprotective agent in a dose-dependent manner (Rao and Mishra, 1998). *S. marianum* is used traditionally for treatment of some liver disease (Saller *et al.*, 2001; Wellington and Jarvis, 2001), due to its ability for free radicals scavenging and chelating metal ions (Das and Vasudevan, 2006). The plant active flavonoid, silymarin, has hepatoprotective effect via antioxidant and scavenging properties (Kosina *et al.*, 2002). Furthermore, silybin dihemisuccinate, soluble form of flavonoid silymarin, has protected rats against acetaminophen induced liver glutathione depletion and lipid peroxidation (Campos *et al.*, 1989).

Present study showed that the best protective effect was achieved by treatment of animals with 300 mg kg<sup>-1</sup> of *F. vaillantii* and *S. marianum* extracts and 25 mg kg<sup>-1</sup> of the active components (MMF and silymarin) (Table 1, 2). These doses therefore, were chosen for the further

Table 3: Effect of *Fumaria vaillantii* total extract (FTE), *Silybum marianum* total extract (STE), monomethyl fumarate (MMF) and silymarin on liver tissue GSH, GSSG and MDA in pre and post-treatment study

Groups	MDA ( $\mu\text{mol g}^{-1}$ tissue)	GSSG ( $\mu\text{g g}^{-1}$ tissue)	GSH ( $\mu\text{g g}^{-1}$ tissue)	Dose $\text{mg kg}^{-1}$ (i.p.)
Blank	93.2±8.8	0.03±0.01	20.7±1.8	Normal saline
Acetaminophen	152.6±16.9 <sup>1</sup>	16.2±1.53 <sup>1</sup>	0.5±0.6 <sup>1</sup>	640
Pre-Treatment				
Silymarin	114.7±0.2 <sup>2</sup>	2.3±0.1 <sup>2</sup>	16.2±0.1 <sup>2</sup>	25
MMF	125.8±0.1 <sup>2</sup>	5.6±0.2 <sup>3</sup>	9.5±0.17 <sup>2</sup>	25
TES	126.7±0.05 <sup>3</sup>	5.4±0.1 <sup>2</sup>	9.7±0.03 <sup>2</sup>	300
TEF	139.9±0.2 <sup>2</sup>	7.6±0.4 <sup>2</sup>	5.5±0.1 <sup>3</sup>	300
Post-Treatment				
Silymarin	121.3±11.7 <sup>2</sup>	4.5±0.5 <sup>2</sup>	16.1±1.2 <sup>2</sup>	25
MMF	139.4±12.9 <sup>2</sup>	9.1±1.1 <sup>3</sup>	8.9±0.9 <sup>2</sup>	25
TES	138.4±11.8 <sup>3</sup>	6.5±0.5 <sup>2</sup>	16.1±1.3 <sup>2</sup>	300
TEF	143.6±12.9 <sup>2</sup>	10.1±0.8 <sup>2</sup>	9.5±0.8 <sup>2</sup>	300

GSH: Glutathione reduce, GSSG: Glutathione oxide, MDA: Malondialdehyde, MMF: Monomethyl fumarate, STE: Total extract of *Silybum marianum*, FTE: Total extract of *Fumaria parviflora*. Values represent the Mean±SE (n = 5), Liver GSH, GSSG and MDA levels were determined 24 h after acetaminophen (640 mg kg<sup>-1</sup>) intoxication, <sup>1</sup>(p<0.001) as compared with blank, <sup>2</sup>(p<0.01) and <sup>3</sup>(p<0.05) as compared with acetaminophen

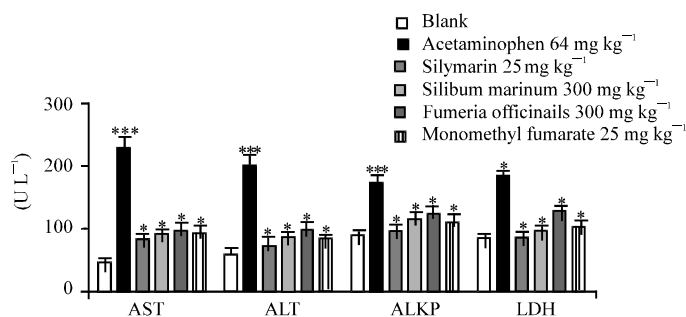


Fig. 1: Comparative study of pre-treatment with effective dose of *Fumaria vaillantii* total extract (FTE, 300 mg kg<sup>-1</sup>), *Silybum marianum* total extract (STE, 300 mg kg<sup>-1</sup>), monomethyl fumarate (MMF, 25 mg kg<sup>-1</sup>) and silymarin (25 mg kg<sup>-1</sup>) on serum AST, ALT, ALKP and LDH in mice. Bar represents Mean±SE, n = 5 mice \*\*\*p<0.001 compared to blank, \*p<0.05 compared to acetaminophen

experiments. In addition, by comparison of the total extracts and the active components, we demonstrated that active components were more effective than total plant extracts (Fig. 1). Moreover, pre-treatment study presented a better protective effect than post-treatment (Table 1, 2 and 3).

Glutathione is a tripeptide which scavenges toxic metabolites and has found in many mammalian tissues and plays a very important role in antioxidant defense system. Determination of total GSH, concomitant to its reduced and oxidized fractions, is a key factor to show the amount of antioxidant reserve in the organism (Lu *et al.*, 1999; Odukoya *et al.*, 2007; Balouchzadeh *et al.*, 2011). In the present study, the content of GSH in the acetaminophen group was significantly decreased 24 h after administration. Induction of cytochrome P450 and/or depletion of liver GSH is needed for acetaminophen induced liver toxicity (Handa and Sharma, 1990). NAPQL, the acetaminophen reactive metabolite, can conjugate with GSH and cause its depletion which leads to the cellular necrosis (Hinson *et al.*, 2004). Pre- and post-treatments with plant extracts, MMF and silymarin

restored GSH levels which further highlights their role against acetaminophen induced hepatotoxicity.

MDA as one of the products of oxidative stress formed during lipid peroxidation process was increased following acetaminophen administration in comparison with control group. Pre- and post-treatments with plant extracts, MMF and silymarin, however, reduced MDA production. Silymarin treatment has previously shown to reduce MDA production (Velussi *et al.*, 1997). It acts as cell membrane stabilizer and regulates permeability by which prevents toxic agents from entering to the hepatocytes via occupying the binding sites as well as inhibiting many transport proteins at the membrane (Faulstich *et al.*, 1980). In addition, silymarin acts as promoters of ribosomal RNA synthesis, with biochemical effects on RNA, protein and DNA synthesis, stimulates liver regeneration (Sonnenbichler and Zetl, 1986). During the present study, MMF showed similar hepatoprotective effect to silymarin by evaluation of ALT, AST, LDH, ALKP, T.B and D.B levels in mouse serum, glutathione (GSH and GSSG) and MDA in mouse liver tissue homogenates. MMF protective activity may be due to its

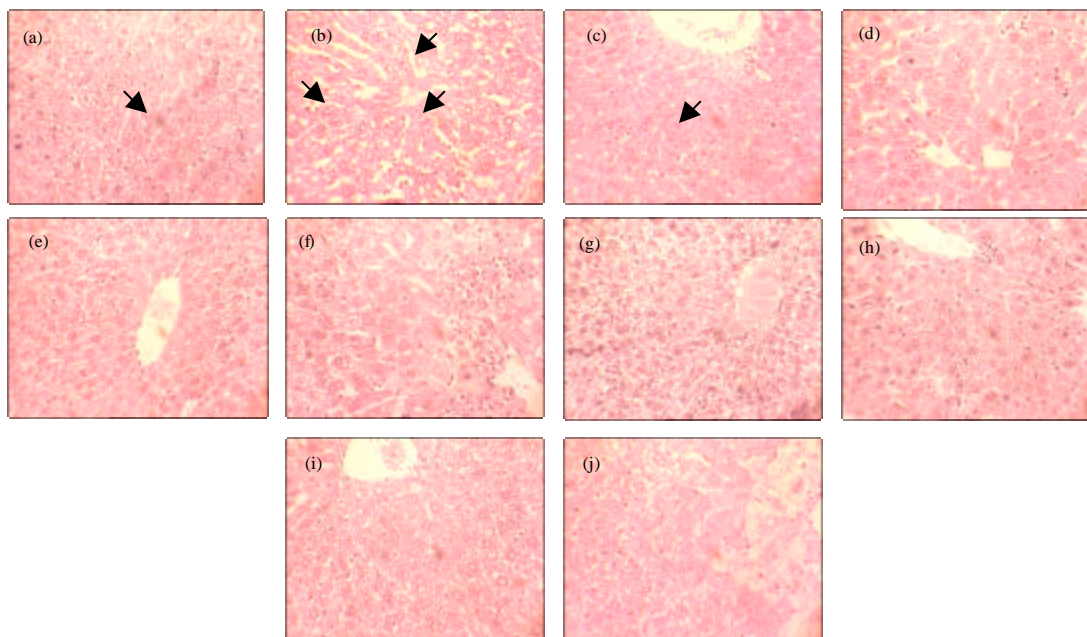


Fig. 2(a-j): Microscopic view of liver sections obtained from (a) blank, (b) acetaminophen ( $640 \text{ mg kg}^{-1}$ ), (c) *Fumaria vaillantii* ( $300 \text{ mg kg}^{-1}$ ) pre-treatment study, (d) *Fumaria vaillantii* ( $300 \text{ mg kg}^{-1}$ ) post-treatment study, (e) *Silybum marianum* ( $300 \text{ mg kg}^{-1}$ ) pre-treatment administration, (f) *Silybum marianum* ( $300 \text{ mg kg}^{-1}$ ) post-treatment study, (g) Monomethyl fumarate ( $25 \text{ mg kg}^{-1}$ ) pre-treatment study, (h) Monomethyl fumarate ( $25 \text{ mg kg}^{-1}$ ) post-treatment study, (i) *Silymarin* ( $25 \text{ mg kg}^{-1}$ ) pre-treatment study and (j) *Silymarin* ( $25 \text{ mg kg}^{-1}$ ) post-treatment study in mice. Haematoxylin and eosin stain and magnifications at  $\times 400$ . The blank mice were given distilled water

ability against formation of active metabolites, by reducing drug metabolism enzymes such as cytochrome P450, promotion of glucuronidation, activation of the reticuloendothelial system functions or inhibition of protein biosynthesis (Rao and Mishra, 1998). Furthermore, MMF antihepatotoxic activity may result from its stimulatory effects on hepatic regeneration and free radical scavenging properties (Rao and Mishra, 1998).

Exposure of hepatocytes to toxic agents such as acetaminophen leads to histopathological changes from the normal cell appearance. The hepatocytes of rat livers treated with a dose of  $640 \text{ mg kg}^{-1}$  acetaminophen, showed centrilobular hepatocyte necrosis, increased mononuclear infiltration, hemorrhage and extensive fatty change. Liver tissue of rats treated with plant extracts, MMF and silymarin in both pre- and post-treatment study plans showed good recovery with absence of necrosis, fatty depositions and recovery to normal histological appearance of hepatocytes (Fig. 2).

In summery our results demonstrate that acetaminophen produced acute toxicity can be treated with monomethyl fumarate and *F. vaillantii* extract in a

similar and comparable manner to silymarin and *S. marianum* by significant lowering in the rise of ALT, AST, LDH, ALKP and bilirubin (Total and direct) in serum and significant increase in glutathione content and reduction of MDA level in the liver. These observations were more apparent in the pre-treatment study which proves that it provides better hepatoprotection than post-treatment (Table 1, 2). This finding is in agreements with a number studies using other protective agents (Oyagbemi and Odetola, 2010; Gilani *et al.*, 1996).

**Conflict of interest statement:** The authors have no financial conflict of interest.

#### ACKNOWLEDGMENTS

The authors are thankful of Dr Faraz Mojab for his kind collaboration in preparation of plant extracts and Dr. HamidReza Rahimi for his assistance. This research was supported by a grant (86-02-33-5324) from vice chancellor for research, Tehran University of Medical Sciences (TUMS), Tehran, Iran.

REFERENCES

- Alqasoumi, S.I., M.S. Al-Dosari, A.M. AlSheikh and M.S. Abdel-Kader, 2009. Evaluation of the hepatoprotective effect of *Fumaria parviflora* and *Momordica balsamina* from Saudi folk medicine against experimentally induced liver injury in rats. Res. J. Med. Plant, 3: 9-15.
- Amin, G.H., 1991. Popular Medicinal Plants of Iran. Vol. 1, Farhang Press, Tehran, pp: 51-52.
- Anundi, I., 2006. Hepatoprotective mechanism of silymarin. Semin. Liver Dis., 6: 78-92.
- Balouchzadeh, A., H.R. Rahimi, A.R. Ebadollahi-Natanzi, B. Minaei-Zangi and O. Sabzevari, 2011. Aqueous extract of Iranian green tea prevents lipid peroxidation and chronic ethanol liver toxicity in rats. J. Pharmacol. Toxicol., 6: 691-700.
- Campos, R., A. Garrido, R. Guerra and A. Valenzuela, 1989. Silybin dihemisuccinate protects against glutathione depletion and lipid peroxidation induced by acetaminophen on rat liver. Planta Med., 55: 417-419.
- Chavda, R., K.R. Vadalia and R. Gokani, 2010. Hepatoprotective and antioxidant activity of root bark of *Calotropis procera* R. Br. (Asclepiadiaceae). Int. J. Pharmacol., 6: 937-943.
- Dahiru, D. and O. Obidoa, 2007. Evaluation of the antioxidant effects of *Ziziphus mauritiana* Lam. Leaf extracts against chronic ethanol-induced hepatotoxicity in rat liver. Afr. J. Tradit. Complement. Altern. Med., 5: 39-45.
- Das, S.K. and D.M. Vasudevan, 2006. Protective effects of silymarin, a milk thistle (*Silybium marianum*) derivative on ethanol-induced oxidative stress in liver. Indian J. Biochem. Biophys., 43: 306-311.
- Diallo, A., K. Eklu-Gadegkeku, T. Mobio, S. Moukha and A. Agbonon *et al.*, 2009. Protective effect of *Moringa oleifera* Lam. and *Lansea kerstingii* extracts against cadmium and ethanol-induced lipid peroxidation. J. Pharma. Toxicol., 4: 160-166.
- Ellithy, M.M. and S.A. Nada, 2006. Efficacy of different medical herbal preparations as hepatoprotective agents. Toxicol. Lett., 164: S311-S312.
- Esterbauer, H. and K.H. Cheeseman, 1990. Determination of aldehydic lipid peroxidation products: Malonaldehyde and 4-hydroxynonenal. Methods Enzymol., 186: 407-421.
- Faulstich, H., W. Jahn and T. Wieland, 1980. Silybin inhibition of amatoxin uptake in the perfused rat liver. Arzneimittelforschung, 30: 452-454.
- Ghazi-Khansari, M., M. Karami, M. Rezayat, M. Abdollahi, B. Minaie and O. Sabzevari, 2005. The protective effects of antioxidants and propranolol on hepatotoxicity of TCDD during isolated rat liver perfusion. Int. J. Pharmacol., 1: 336-341.
- Gilani, A.H., K.H. Janbaz and M.S. Akhtar, 1996. Selective protective effect of an extract from *Fumaria parviflora* on paracetamol-induced hepatotoxicity. Gen. Pharmacol., 27: 979-983.
- Guengrich, F.P., 2000. Metabolism of chemical carcinogen. Carcinogenesis, 21: 345-351.
- Handa, S.S. and A. Sharma, 1990. Hepatoprotective activity of andrographolide against galactosamine and paracetamol intoxication in rats. Ind. J. Med. Res., 92: 284-292.
- Handa, S.S., A. Sharma and K.K. Chakraborti, 1986. Natural products and plants as liver protecting drugs. Fitoterapia, 57: 307-351.
- Hinson, J.A., A.B. Reid, S.S. McCullough and L.P. James, 2004. Acetaminophen-induced hepatotoxicity: Role of metabolic activation, reactive oxygen/nitrogen species and mitochondrial permeability transition. Drug Metab. Rev., 36: 805-822.
- Iyawe, H.O.T., A.O. Onigbinde and O.O. Aina, 2006. Effect of chloroquine and ascorbic acid interaction on the oxidative stress status of *Plasmodium berghei* infested mice. Int. J. Pharmacol., 2: 1-4.
- Kanbur, M., G. Eraslan, L. Beyaz, S. Silici, B.C. Liman, S. Altinordulu and A. Atasever, 2009. The effects of royal jelly on liver damage induced by paracetamol in mice. Exp. Toxicol. Pathol., 61: 123-132.
- Koriam, K.M., A.R. Farrag, M.A. Badawy and S.A. El-Toumy, 2009. Role of some Egyptian medicinal plants against liver and kidney toxicity induced by cadmium chloride. Toxicol. Mechanisms Methods, 19: 524-534.
- Kosina, P., V. Kren, R. Gebhardt, F. Grambal, J. Ulrichova and D. Walterova, 2002. Antioxidant properties of silybin glycosides. Phytother. Res., 16: 33-39.
- Kumar, S.S., B.R. Kumar and G.K. Mohan, 2009. Hepatoprotective effect of *Trichosanthes cucumerina* var. *cucumerina* L. on carbon tetrachloride induced liver damage in rats. J. Ethnopharmacol., 123: 347-350.
- Lu, S.C., Z.Z. Huang, J.M. Yang and H. Tsukamoto, 1999. Effect of ethanol and high-fat feeding on hepatic  $\gamma$ -glutamylcysteine synthetase subunit expression in the rat. Hepatology, 30: 209-214.
- Meera, S., V.S.S.S.G. Atyam and N.S. Kumar, 2008. Immunomodulatory and antioxidant activity of a polyherbal formulation. Int. J. Pharmacol., 4: 287-291.
- Moling, O., E. Cairon, G. Rimenti, F. Rizza, R. Pristera and P. Mian, 2006. Sever hepatotoxicity after therapeutic doses of acetaminophen. Clin. Ther., 28: 755-760.
- Mortazavi, R., M. Nassiri-Asl, Z. Farahani-Nick, S. Savad and S.K. Farzam, 2007. Protective effects of *Fumaria vaillantii* extract on carbon tetrachloride induced hepatotoxicity in rats. Pharmacologyonline, 3: 385-393.



- Natanzi, A.E., M.H. Ghahremani, H.R. Monsef-Esfahani, B. Minaei, H. Nazarian and O. Sabzevari, 2009. An experimental model for study of the hepatoprotective activity of *Nasturtium officinale* (Watercress) against acetaminophen toxicity using in situ rat liver system. Eur. J. Sci. Res., 38: 556-564.
- Natanzi, A.R.E., M.H. Ghahremani, H.R.M. Esfehmi, M.B. Minaei, H. Nazarian and O. Sabzevari, 2010. Evaluation of antihepatotoxic effect of watercress extract and its fractions in rats. Int. J. Pharmacol., 6: 896-902.
- Odukoya, O.A., S.I. Inya-Agha and O.O. Ilori, 2007. Immune boosting herbs: Lipid peroxidation in liver homogenate as index of activity. J. Pharmacol. Toxicol., 2: 190-195.
- Olaleye, M.T. and B.T. Rocha, 2008. Acetaminophen-induced liver damage in mice: Effects of some medicinal plants on the oxidative defense system. Exp. Toxicol. Pathol., 59: 319-327.
- Oyagbemi, A.A. and A.A. Odetola, 2010. Hepatoprotective effects of ethanolic extract of *Cnidocolus aconitifolius* on paracetamol-induced hepatic damage in rats. Pak. J. Biol. Sci., 13: 164-169.
- Prasanna, G.S. and A. Purnima, 2011. Protective effect of leaf extract of *Trichilia comaroides* on hypercholesterolemia induced oxidative stress. Int. J. Pharmacol., 7: 106-112.
- Ramellini, G. and J. Meldolesi, 1976. Liver protection by silymarin: *In vitro* effect on dissociated rat hepatocytes. Arzneimittelforschung, 26: 69-73.
- Rao, K.S. and S.H. Mishra, 1996. Hepatoprotective activity of the whole plants of *Fumaria indica*. Indian J. Pharm. Sci., 59: 165-170.
- Rao, K.S. and S.H. Mishra, 1998. Antihepatotoxic activity of monomethyl fumarate isolated from *Fumaria indica*. J. Ethnopharmacol., 60: 207-213.
- Saller, R., R. Meier and R. Brignoli, 2001. The use of silymarin in the treatment of liver diseases. Drugs, 61: 2035-2063.
- Sonnenbichler, J. and I. Zetl, 1986. Biochemical effects of the flavonolignan silibinin on RNA, protein and DNA synthesis in rat liver. Progr. Clin. Biol. Res., 213: 319-331.
- Suau, R., B. Cabezudo, R. Rico, F. Najera and J.M. Lopez-Romero, 2002. Direct determination of alkaloid contents in *Fumaria* species by GC-MS. Phytochem. Anal., 13: 363-367.
- Valenzuela, A., C. Lagos, K. Schmidt and L.A. Videla, 1985. Silymarin protection against hepatic lipid peroxidation induced by acute ethanol intoxication in the rat. Biochem. Pharmacol., 34: 2209-2212.
- Velussi, M., A.M. Cernigoi, A. De Monte, F. Dapas, C. Caffau and M. Zilli, 1997. Long-term (12 months) treatment with an anti-oxidant drug (silymarin) is effective on hyperinsulinemia, exogenous insulin need and malondialdehyde levels in cirrhotic diabetic patients. J. Hepatol., 26: 871-879.
- Wellington, K. and B. Jarvis, 2001. Silymarin: A review of its clinical properties in the management of hepatic disorders. BioDrugs, 15: 465-489.
- Zargari, A., 1989. Medical Plants. Tehran University Press, Tehran, pp: 170-171.
- Zhang, Q., Z. Melnikov and D.E. Feerman, 2004. Characterization of the acetaminophen-induced degradation of cytochrome p450-3A4 and the proteolytic pathway. Basic Clin. Pharmacol. Toxicol., 94: 191-200.