



International Journal of Pharmacology

ISSN 1811-7775

science
alert

ansinet
Asian Network for Scientific Information

Fennel "*Foeniculum vulgare*" Treatment Protects the Gastric Mucosa of Rats against Chemically-induced Histological Lesions

¹Ibrahim Al-Mofleh, ¹Mohamed Al-Sobaihani, ²Saleh Alqasoumi, ²Mansour Al-Said,
²Mohammed Al-Dosari, ²Mohamed Al-Yahya and ²Syed Rafatullah

¹Department of Medicine and Pathology, Gastroenterology Unit, College of Medicine,
King Khalid University Hospital, P.O. Box 2925, Riyadh-11461, Saudi Arabia

²Medicinal, Aromatic and Poisonous Plants Research Center (MAPPRC), Department of Pharmacognosy,
College of Pharmacy, P.O. Box 2457, King Saud University, Riyadh 11451, Saudi Arabia

Abstract: This study evaluated anti-gastric ulcer and anti-secretory effects of folkloric medicinal plant, *Foeniculum vulgare* L., (Family:Apiaceae) in rats. The gastric ulcer protective potential of an aqueous suspension of 'Fennel' *Foeniculum vulgare* (FVS) was evaluated against different acute gastric ulcer models in rats induced by pyloric ligation (Shay), hypothermic restraint stress, indomethacin and by necrotizing agents (80% ethanol, 0.2 M NaOH and 25% NaCl). Fennel suspension, 250 and 500 mg kg⁻¹ b.wt. administered orally (intraperitoneally in Shay rat model) showed a dose-dependent ulcer protective effects in all the above models. Besides, the FVS offered protection against ethanol-induced depletion of Gastric Wall Mucus (GWM); replenished the reduced nonprotein sulfhydryls (NP-SH) concentration and modulated malondialdehyde (MDA) contents in the gastric tissue. Ethanol induced histopathological lesions of the stomach wall characterized by mucosal hemorrhages and edema that was reversed by FVS. Pretreatment of rats with FVS provided significant protection of gastric mucosa through its antioxidant capacity and/or by attenuating the offensive and by enhancing the defensive factor.

Key words: Fennel, *Foeniculum vulgare*, cytoprotection, gastric ulcers, Arab traditional medicine

INTRODUCTION

Fennel "*Foeniculum vulgare* Miller" (Family:Apiaceae) is a typical aromatic plant, long been used as a medicinal and spice herb in traditional medicine of many countries including Saudi Arabia. Fennel is used for the treatment of liver, gall bladder and gastric ailments such as indigestion, colicky pain, nausea and flatulence. Fennel essential oils are used in cosmetics, including soaps, detergents, creams, lotions and perfumes (Leung, 1980; Chomdler and Hawkes, 1984; Grieve, 1971). It is often used with various purgatives to reduce their tendency to cause gripping (Abdul-Ghani and Amin, 1988). The boiled water extract of fennel leaves is known to cause decrease in blood pressure of experimental animals (Ageel *et al.*, 1987). The ethanolic extract of fennel is known to have significant anti-inflammatory, analgesic and antipyretic activity and is reported to increase bile flow (Mascolo *et al.*, 1987). Fennel water is commonly given to infants to relieve colic. In an earlier study on

Ehrlich ascites carcinoma cells in paw of mice, anethol a major component of fennel oil was found to be anticarcinogenic, cytotoxic and non-clastogenic (Al-Harbi *et al.*, 1995). In a recent study fennel extract showed beneficial against ethanol-induced gastric mucosal injury (Birdane *et al.*, 2007). Clinical studies also revealed anethole to possess no carcinogenic risk for humans (Newberne *et al.*, 1989; Truhaut *et al.*, 1989). Fennel Generally Regarded as Safe (GRAS) status for human consumption. In a study fennel extract has been reported to contain anti-oxidant components (Garga *et al.*, 2009). Several compounds including trans-anethole, estragole, fenchone and polyphenolics have been found in this plant (Ghanem *et al.*, 2012).

To substantiate the claimed gastric antiulcer activity of fennel in the powdered dosage form (a commonly used dosage form in Arab, Ayurveda and Unani medicine practices); the present study was carried out to evaluate antiulcerogenic potential of Fennel aqueous suspension (FVS) on various *in vivo* experimental gastric ulcer models in rats.

Corresponding Author: Mohamed Al-Yahya, Medicinal, Aromatic and Poisonous Plants Research Center (MAPPRC), Department of Pharmacognosy, College of Pharmacy, P.O. Box 2457, King Saud University, Riyadh 11451, Saudi Arabia Tel: 00966-1-4677262 Fax: 00966-1-4677245

MATERIALS AND METHODS

Plant material and preparation of dosage form: The fennel fruits were purchased from a local crude drugs supplier in Riyadh. The fennel was identified by an expert taxonomist; the specimen was deposited in the herbarium of the Department of Pharmacognosy, College of Pharmacy, King Saud University, Riyadh, Saudi Arabia. The fennel fruits were pulverized to a very fine powder to a particle size (mesh # 75 μ) and freshly dissolve in distilled water just before the administration to the animals.

Animal and protocol: Wistar albino rats of either sex, approximately of the same age, weighing 150-200 g and fed standard chow diet were used. They were divided into groups of six animals each. The distribution of animals in groups, the sequence of trials and the treatments were randomized. The solutions of the ulcerogenic drugs and necrotizing agents were freshly prepared and the animals were killed by ether euthanasia. The stomachs were removed, opened along the greater curvature, washed with saline and examined with a 6.4 x binocular magnifier and the gastric tissues were also used for biochemical estimations and histological assessment. Lesions were also assessed by two observers unaware of experimental protocols. The animal study protocol was approved by the Research and Ethics Committee of the Experimental Animal Care Society, College of Pharmacy, King Saud University, Riyadh, Saudi Arabia.

Pylorus ligated (Shay) rats: The animals were fasted for 36 h with access to water *ad libitum* before the pylorus was ligated under light ether anesthesia, care being taken not to cause bleeding or to occlude blood vessels (Shay *et al.*, 1945). FVS administered immediately after pylorus ligation by intraperitoneal injection. The animals were sacrificed 6 h after the pylorus ligation, stomachs were removed and contents were collected, measured, centrifuged and subjected to analysis for titratable acidity against 0.01 N NaOH to pH 7. Each stomach was examined for lesions.

Hypothermic restraint stress-induced ulcers: The method of Levine (1971) was followed with slight modification. The animals were fasted for 36 h with access to water *ad libitum*. One hr after receiving oral drug (FVS) treatment, they were immobilized in restraint cages and placed inside a ventilated refrigerator maintained at a temperature of 2-4°C. After 3 h they were taken out and sacrificed. The stomachs were excised and examined for

the severity of intraluminal bleeding according to the following arbitrary scale: 0, no blood detectable; 1, thin blood follows the rugae; 2, thick blood follows the rugae; 3, thick blood follows the rugae with blood clots in certain areas and 4, thick blood (Chiu *et al.*, 1984). After wiping the blood off, the total area of lesions in each stomach was scored.

Indomethacin-induced gastric ulcers: Indomethacin was suspended in 1% Carboxy-methyl Cellulose (CMC) in water and administered orally to the 36 h fasted rats at a dose of 30 mg kg⁻¹ b.wt. Control rats were treated similarly with an equivalent amount of vehicle (Bhargava *et al.*, 1973). FVS was given 30 min prior to indomethacin administration at a dose of 250 and 500 mg kg⁻¹. The animals were sacrificed 6 h after treatment. The stomachs were excised, rinsed with normal saline and examined for ulceration.

Gastric lesions induced by necrotizing agents: Each rat was administered 1 mL of a necrotizing agent (80% ethanol, 0.2 M NaOH or 25% NaCl). Fennel suspension was given 30 min before the administration of necrotizing agents. One hour after the administration of ethanol and the alkalis, the rats were sacrificed and examined for stomach lesions. The scoring of stomach lesions was as follows: Patchy lesions of the stomach induced by ethanol and hypertonic solutions were scored according to the method described by Robert *et al.* (1983) using the following scale: 0 = normal mucosa; 1 = hyperemic mucosa or up to 3 small patches; 2 = from 4 to 10 small patches; 3 = more than 10 small or up to 3 medium-sized patches; 4 = from 4 to 6 medium-sized or up to 3 large patches; 6 = from 4 to 6 large patches; 7 = from 7 to 10 large patches; 8 = more than 10 large patches or extensive necrotic zones. "Small" was defined as up to 2 mm across (max. diameter), "medium-sized" between 2 and 4 mm across and "large" more than 4 mm across.

Determination of gastric wall mucus (GWM): Gastric wall mucus was determined according to the modified procedure of Corne *et al.* (1974). The glandular segment of the stomach was separated from the rumen of the stomach, weighed and transferred immediately to 10 mL of 0.1% w/v Alcian blue solution (in 0.16 mmol L⁻¹ sucrose solution buffered with 0.05 mL sodium acetate at pH 5). Tissue was stained for 2 h in Alcian blue and excess dye was removed by two successive rinses with 10 mL of 0.25 mmol L⁻¹ sucrose, firstly after 15 min and then after 45 min. Dye complexed with the gastric wall mucus was extracted with 10 mL of 0.5 mmol L⁻¹ magnesium chloride

which was intermittently shaken for 1 at 30 min intervals for 2 h. Four milliliters of blue extract were then vigorously shaken with an equal volume of diethyl ether. The resulting emulsion was centrifuged at 4000 rpm min⁻¹ for 10 min and the absorbance of the aqueous layer was recorded at 580 nm. The quantity of Alcian blue extracted per gram of wet glandular tissue was then calculated.

Estimation of non-protein sulfhydryl (NP-SH) in gastric tissue: Gastric mucosal non-protein sulfhydryls were measured according to the method of Sedlak and Lindsay (1968). The glandular part of the stomach was homogenized in ice-cold 0.02 mmol L⁻¹ ethylenediaminetetraacetic acid (EDTA). Aliquots of 5 mL of the homogenates were mixed in 15 mL test tubes with 4 mL of distilled water and 1 mL of 50% Trichloroacetic Acid (TCA). The tubes were shaken intermittently for 10 min and centrifuged at 3000 rpm min⁻¹. Two milliliters of supernatant were mixed with 4 mL of 0.4 mol L⁻¹ Tris buffer at pH 8.9. 0.1 mL of 5,5'-dithio-bis(2-nitrobenzoic acid) (DTNB) was added and the sample was shaken. The absorbance was measured within 5 min of DTNB addition at 412 nm against a reagent blank.

Estimation of malondialdehyde (MDA) in gastric tissue: The method reported by Utley *et al.* (1967) followed. The animals were killed 1 h after ethanol administration. The stomachs were removed and each was homogenized in 0.15 mol L⁻¹ KCl (at 4°C) in a Potter-Elvehjem type C homogenizer to give a 10% w/v homogenate. Aliquots of homogenate 1 mL in volume were incubated at 37°C for 3 h in a metabolic shaker. Then 1 mL of 10% aqueous TCA was added and mixed. The mixture was then centrifuged at 800 g for 10 min. One milliliter of the supernatant was removed and mixed with 1 mL of 0.67% 2-thiobarbituric acid in water and placed in a boiling water bath for 10 min. The mixture was cooled and diluted with 1 mL distilled water. The absorbance of the solution was then read at 535 nm. The content of malondialdehyde (nmol/g wet tissue) (index of the magnitude of lipid peroxidation) was then calculated, by reference to a standard curve of malondialdehyde solution.

Histopathological evaluation: Gastric tissue samples were fixed in neutral buffered formalin for 24 h. Sections of gastric tissue were histopathologically examined to study the ulcerogenic and/or anti-ulcerogenic activity of FVS. The tissues were fixed in 10% buffered formalin and processed using a tissue processor. The processed tissues were embedded in paraffin blocks and sections about 5 µm thick were cut using an American optical

rotary microtome. These sections were stained with haematoxylin and eosin using routine procedures (Culling, 1974). The slides were examined microscopically for pathomorphological changes such as congestion hemorrhage, edema and erosions using an arbitrary scale for severity assessment of these changes.

Statistical analysis: Values in tables and figures are given as Mean±SE. Data were analyzed by using one-way Analysis of Variance (ANOVA) followed by Dunnett's multiple comparison tests.

RESULTS

An increased accumulation of gastric secretory volume, titratable acidity and ulceration in 6 h, pylorus ligated Shay rats were shown significant inhibition of gastric secretory volume, acidity and ulceration in the animals treated with fennel aqueous suspension evident by ulcerative index which is 0.83±0.30, 0.33±0.21 and 0, respectively (Table 1).

Animals subjected to restraint plus cold for 3 h showed the presence of considerable ulcerogenicity as indicated by ulcerative index (18.343±0.94) in the form of hemorrhagic mucosal lesions in the stomach which were confined to the glandular segment only. There was also evidence of intraluminal bleeding in these animals. Treatment with FVS 250 and 500 mg kg⁻¹ produced a significant and dose-dependent inhibition of ulceration and intraluminal bleeding as indicated ulcerative index (13.33±1.11 and 5.66±2.07) of both group (Table 2).

Administration of indomethacin resulted in the production of gastric lesions mainly in the glandular

Table 1: Effect of Fennel aqueous suspension (FVS) on the volume of gastric secretion, titratable acidity and the degree of ulceration in 6 h pylorus ligated (Shay) rats

Treatments	Dose (mg kg ⁻¹ , i.p.)	Mean±SE		
		Volume of gastric content (mL)	Titratable acid (mEq L ⁻¹)	Ulcer index
Control	-	8.33±0.39	88.33±4.190	0.83±0.30
FVS	250	5.00±0.68**	61.66±2.540	0.33±0.21
FVS	500	3.00±0.44***	53.88±17.32	00***

Six animals were used in each group. **p<0.05; ***p<0.001. ANOVA, followed by Dunnett's multiple comparison tests

Table 2: Effect of Fennel aqueous suspension (FVS) on hypothermic restraint stress-induced intraluminal bleeding and gastric lesion in rats

Treatments	Dose (mg kg ⁻¹)	Intraluminal bleeding score	Gastric ulcer index
Control (distilled water)	-	1.66±0.21	18.343±0.94
FVS suspension	250	1.33±0.33	13.330±1.11**
FVS suspension	500	0.66±0.33*	5.660±2.07***

Six rats were used in each group. *p<0.05, **p<0.01, ***p<0.001. ANOVA, followed by Dunnett's multiple comparison tests

segment of the stomach of rats its ulcerative index was 37.16 ± 2.24 . Pretreatment of animals with FVS significantly decrease the intensity of gastric mucosal damage induced by indomethacin as indicated by ulcerative index in higher dose group (Table 3). However, in the lower dose (250 mg kg^{-1}) group the protection was not statistically significant.

Lowered gastric wall mucus was observed in the animals treated with 80% ethanol and this depletion of wall mucus was significantly reversed by pretreatment with fennel suspension (Fig. 1).

Necrotic patches of the stomach, induced by noxious chemicals were found to be significantly reduced in the groups of animals pretreated with aqueous suspension of fennel as indicated by ulcerative index of (5.66 ± 1.05 , 2.66 ± 0.42 and 1.66 ± 0.16) of control, FVS 250 mg kg^{-1} and FVS 500 mg kg^{-1} (Table 4).

The gastric mucosal NP-SH contents were 34% decreased as compare to control after the administration of 80% ethanol. While treatment with FVS 250 and 500 mg kg^{-1} dose replenished ethanol-induced decrease in NP-SH level from 23 to 12% as compare with control (Fig. 2).

As depicted in Fig. 3, MDA levels in the gastric mucosa used as an index of lipid peroxidation were significantly higher in the ethanol only treated group than in the untreated control group. FVS at the dose of 500 mg kg^{-1} significantly decreased the MDA content of the gastric tissue.

Table 3: Effect of Fennel aqueous suspension (FVS) on the gastric mucosal damage induced by indomethacin in rats

Treatments (n = 6)	No. of animals	Dose (mg kg^{-1} , p.o.)	Ulcer index (Mean±SE)
Control	6	-	37.16 ± 2.24
FVS	6	250	35.66 ± 3.48
FVS	6	500	$21.00 \pm 4.95^*$

* $p < 0.05$. Dunnett's multiple comparison tests

Table 4: Effect of Fennel aqueous suspension (FVS) on the gastric lesions induced by various necrotizing agents in rats

Treatments (n = 6)	Dose (mg kg^{-1} , p.o.)	Ulcer index (Mean±SE)		
		80% EtOH	0.2M NaOH	25% NaCl
Control	-	8.00 ± 0.00	7.83 ± 0.16	5.66 ± 1.05
FVS	250	$5.00 \pm 0.51^{***}$	7.16 ± 0.40	$2.66 \pm 0.42^*$
FVS	500	$2.66 \pm 0.49^{***}$	$5.50 \pm 0.50^{**}$	$1.66 \pm 0.16^{**}$

* $p < 0.05$, ** $p < 0.01$, *** $p < 0.001$. ANOVA, followed by Dunnett's multiple comparison tests

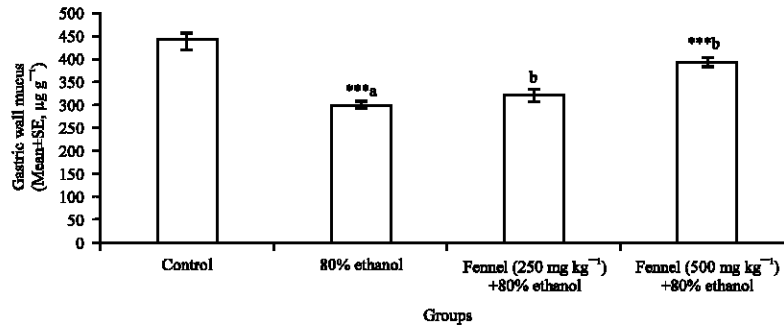


Fig. 1: Effect of Fennel aqueous suspension (FVS) on 80% ethanol-induced gastric wall mucus changes in rats. All values represent Mean±SEM. *** $p < 0.001$; ANOVA, followed by Dunnett's multiple comparison tests. ^aAs compared with control group. ^bAs compared with 80% ethanol group

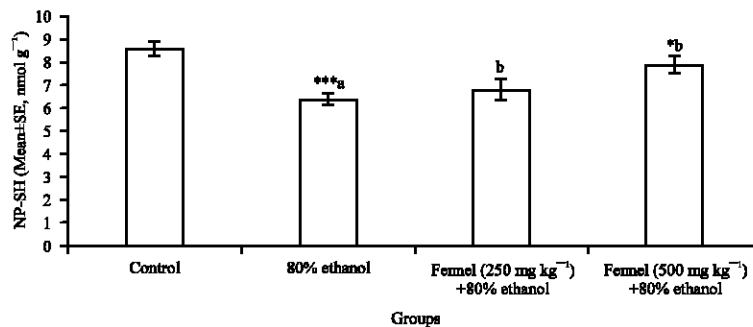


Fig. 2: Effect of Fennel aqueous suspension (FVS) on glutathione (NP-SH) concentration in gastric tissue of rats. All values represent Mean±SEM. * $p < 0.05$; *** $p < 0.001$; ANOVA, followed by Dunnett's multiple comparison test. ^aAs compared with control group. ^bAs compared with 80% ethanol group

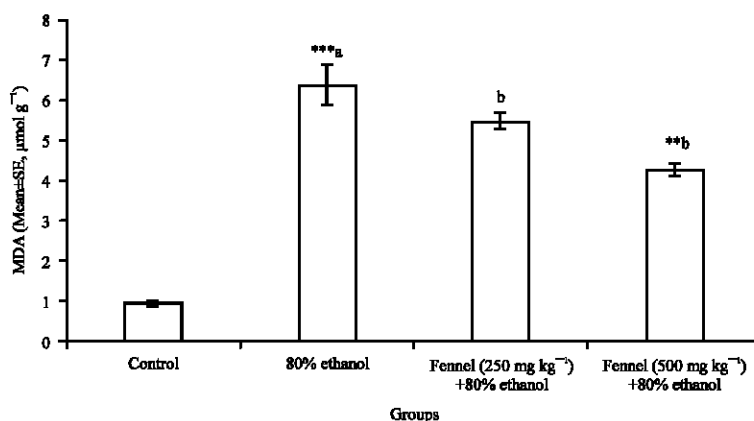


Fig. 3: Effect of Fennel aqueous suspension (FVS) on malondialdehyde (MDA) concentration in gastric tissue of rats. All values represent Mean±SEM. ** $p < 0.01$; *** $p < 0.001$; ANOVA, followed by Dunnett's multiple comparison test. ^aAs compared with control group. ^bAs compared with 80% ethanol group

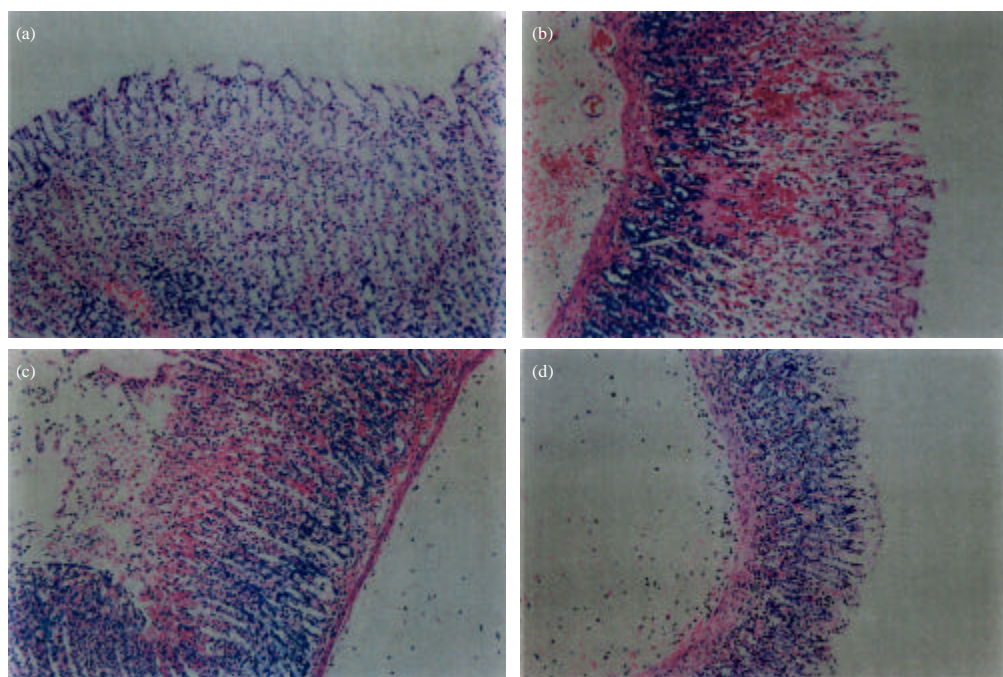


Fig. 4(a-d): Section through gastric mucosa of (a) Control rat showing normal appearance, (b) Rat treated with ethanol (80%, 1 mL) showing evidence of mucosal erosions, intramucosal haemorrhage and edema. A haemorrhagic focus is also seen in the submucosal layer, (c) *Foeniculum vulgare* (250 mg kg^{-1}) and ethanol (80%, 1 mL) showing the presence of mucosal ulceration and haemorrhage. The submucosa is edematous and (d) *Foeniculum vulgare* (500 mg kg^{-1}) and ethanol (80%, 1 mL) showing superficial ulceration, vascular congestion and submucosal edema. Haematoxylin and Eosin stain $\times 100$

Histopathological studies (Fig. 4a-d) further confirmed that pretreatment with FVS reduces the intensity of ethanol-induced various indices of the gastric mucosa.

DISCUSSION

The present study demonstrated that the aqueous suspension of fennel strongly inhibits basal gastric acid

secretion by pylorus ligation and ulceration induced by hypothermic restraint stress induced and various necrotizing agents and indomethacin. It is well known that gastric acid is involved in the pathogenesis of peptic ulcer disease and a correlation has been established (Howden, 2004; Hara *et al.*, 1991) between increased gastric acid secretion and gastric lesions in animals; in addition to that some drugs have shown their antiulcer effect mainly via., their potent antisecretory action (Kinoshita *et al.*, 1997; Heim *et al.*, 1991). The vagus-vagal activation by stimulation of antral gastric mucosal receptors in pylorus ligated Shay model is believed to exacerbate the gastric acid secretion (Baggio *et al.*, 2003). The current data demonstrated that, fennel suspension possesses the ability to inhibit the basal gastric acid secretion and ruminal ulceration. These findings substantiate the use of fennel alone or in combination with other herbs for the management or treatment of hyperacidity and gastralgia in Unani System of Medicine (Kabiruddin, 1921). It has been reported by Bhargava *et al.* (1980) that simultaneous cold (2-4°C) and restraint stress provoke gastric ulceration in rats. The cold plus restraint-induced ulcers are probably mediated by an increased secretion (Kitagawa *et al.*, 1979), reduced mucus generation (Koo *et al.*, 1986), impaired gastric microcirculation (Guth, 1972). The stress-over-activity which results in gastric hypersecretion is often termed as 'aggressive factor' (Goa and Monk, 1987).

The data revealed that pre-treatment with FVS significantly protected gastric mucosa against cold plus restraint induced ulcers which could be due to the inhibition of gastric mucus coat depletion and/or diminishing basal gastric acid secretion. Earlier, File and Pearce, 1981 have suggested that sedatives, anxiolytic and antisecretory substances have the ability to protect gastric ulcer inflicted by stress. Fennel suspension, in this study has shown to have antigastric ulcer potential in cold plus stress model, as fennel is known to possess soothing and calming effects (Al-Harbi *et al.*, 1995). Results on indomethacin induced gastric mucosal damage showed inhibition of gastric lesions by fennel suspension. A significant increase in gastric wall mucus in fennel suspension treated animals might be responsible for its gastroprotective effect against indomethacin-induced gastropathy. The gastric mucus coat is thought to be important in both preventing damage and to facilitate repair of the gastric epithelium (Wallace and Whittle, 1986; Rainsford and Willis, 1982). Evidence is accumulating that Nonsteroidal Anti-inflammatory Drugs (NSAIDs) are linked to ulceration of the stomach

(Odabasoglu *et al.*, 2006). The mechanism of action seems to be both topical damage to the mucosal barrier and the systemic effect of reduction in levels of mucosal prostaglandins (Firulescu *et al.*, 2010). The ability of fennel suspension to protect gastric mucosa, possibly, through prostaglandin mediation cannot be ruled out.

On the other hand, decreased levels of endogenous non-protein sulfhydryls (NP-SH) have been associated with gastric mucosal lesions produced by various chemicals (Robert *et al.*, 1983; Szabo *et al.*, 1981; Rafatullah *et al.*, 1994). Hence, the replenishment of (NP-SH) levels in gastric mucosa by fennel suspension may contribute to its antiulcer activity. The chemical constituents of fennel responsible for its gastric protective activity are not known. However, fennel was found to contain essential oil which possesses a strong antioxidant property (Marotti *et al.*, 1994). The above findings are in accordance with a previous study which has shown that Fennel extract possesses strong antiulcer activity (Wiseman *et al.*, 1987). Natural antioxidants have been shown to possess the ability to protect the cellular damage (Marotti *et al.*, 1994). Fennel suspension also significantly protected gastric mucosa against several known necrotizing agents including ethanol and strong alkalis. These necrotizing agents cause an insult to gastric mucosal cell which resulted in the generation of free radicals and oxidative stress (Repetto and Llesuy, 2002). Pretreatment of rats with fennel suspension significantly protected gastric lesions produced by necrotizing agents. These findings further indicate the ability of FVS to enhance the gastric mucosal defensive factor.

On the other hand, the treatment of rats with FVS significantly decreased the induced elevated concentration of MDA; an end product of lipid peroxidation caused by a free radical mediated injury in gastric tissue. This finding further confirms that fennel possesses an antioxidant potential. Recently, Ghanem *et al.* (2012) have reported an *in vitro* antioxidant activity of fennel extract.

The histopathological results showed that ethanol treatment caused mucosal erosion, edema, intramucosal hemorrhage. Pretreatment with FVS showed vascular congestion, superficial ulceration and submucosal edema. These results partially support the pharmacological and biochemical observations.

CONCLUSION

The present observations demonstrate the gastro-protective efficacy of the FVS probably due to its antisecretory and antioxidant nature by which it strengthens mucosal defensive factor.

ACKNOWLEDGMENTS

The authors are thankful to the Research Center of the College of Pharmacy, King Saud University and the Deanship of the Scientific Research, King Saud University, Riyadh, Saudi Arabia for their support.

REFERENCES

- Abdul-Ghani, A.S. and R. Amin, 1988. The vascular action of aqueous extracts of *Foeniculum vulgare* leaves. *J. Ethnopharmacol.*, 24: 213-218.
- Ageel, A.M., M.A. Al-Yahya, M. Tariq, S. Babhair, M.S. Al-Said, A. Khatibi and A. Angary, 1987. Report entitled Scientific evaluation of merits and demerits of crude drugs used in Saudi folk medicine. King Abdulaziz City for Science and Technology, Riyadh, on the Experimental Evaluation of Saudi Folk Medicine, pp: 6-8
- Al-Harbi, M.M., S. Qureshi, M. Raza, M.M. Ahmed, A.B. Giangreco and A.H. Shah, 1995. Influence of anethol treatment on the tumor induced by *Ehrlich ascites* carcinoma cells in paw of Swiss albino mice. *Eur. J. Cancer Prev.*, 4: 307-318.
- Baggio, C.H., C.S. Freitas, L. Rieck and M.C.A. Marques, 2003. Gastroprotective effects of a crude extract of *Baccharis illinita* DC in rats. *Pharmacol. Res.*, 47: 93-98.
- Bhargava, K.P., M.G. Gupta and K.K. Tanvir, 1973. Mechanism of ulcerogenic activity of indomethacin and oxyphenbutazone. *Eur. J. Pharmacol.*, 22: 191-195.
- Bhargava, K.P., M. Dass, G.P. Gupta and M.B. Gupta, 1980. Study of central neurotransmitters in stress-induced gastric ulceration in albino rats. *Br. J. Pharmacol.*, 68: 765-772.
- Birdane, F.M., M. Cemek, Y.O. Birdane, I. Gulcin and M.E. Buyukokuroglu, 2007. Beneficial effects of *Foeniculum vulgare* on ethanol-induced acute gastric mucosal injury in rats. *World J. Gastroenterol.*, 13: 607-611.
- Chiu, P.J.S., C. Gerhart, A.I. Brown and A. Barnett, 1984. Effects of a gastric antisecretory-cytoprotectant 2-methyl-8-(phenylmethoxy) imidazo (1,2-a) pyridine-3-acetanitrile (Sc 28 080) o-cysteamine, reserpine and stress ulcers in rats. *Arzneimittelforschung*, 34: 783-786.
- Chomdler, R.F. and D. Hawkes, 1984. Aniseed: Spice, flavour, drug. *Can. Pharm. J.*, 117: 28-29.
- Corne, S.J., S.M. Morrissey and R.J. Woods, 1974. A method for the quantitative estimation of gastric barrier mucus. *J. Physiol.*, 242: 116-117.
- Culling, C.F.A., 1974. Handbook of Histopathological and Histochemical Techniques. 3rd Edn., Butterworth and Co., London, UK., ISBN-13: 9780407729018, pp: 73, 126, 159.
- File, S.E. and J.B. Pearce, 1981. Benzodiazepines reduce gastric ulcers induced in rats by stress. *Br. J. Pharmacol.*, 74: 593-599.
- Firulescu, S., S. Negres and D. Mihele, 2010. Experimental pharmacological researches evaluating the analgesic activity for novel hybrid prodrugs obtained by esterification of NSAIDs compounds with prostaglandinic compounds. *Farmacologia*, 58: 695-702.
- Garga, C., S.A. Khan, S.H. Ansari, A. Suman and M. Garg, 2009. Chemical composition, therapeutic potential and perspectives of *Foeniculum vulgare*. *Pharmacogn. Rev.*, 3: 346-352.
- Ghanem, M.T.M., H.M.A. Radwan, E.S.M. Mahdy, Y.M. Elkholy, H.D. Hassanein and A.A. Shahat, 2012. Phenolic compounds from *Foeniculum vulgare* (Subsp. *Piperitum*) (Apiaceae) herb and evaluation of hepatoprotective antioxidant activity. *Pharmacogn. Res.*, 4: 104-108.
- Goa, K.L. and J.P. Monk, 1987. A preliminary review of its pharmacodynamics and pharmacokinetic properties and therapeutic efficacy in the treatment of peptic ulcer disease. *Drugs*, 3: 539-559.
- Grieve, M., 1971. A Modern Herbal. Vol. 1, Dover Publications, New York, USA., pp: 293-297.
- Guth, P.H., 1972. Gastric blood flow in restraint stress. *Digestive Dis.*, 17: 807-813.
- Hara, N., Y. Hara, Y. Natsume and Y. Goto, 1991. Gastric hyperacidity and mucosal damage caused by hypothermia correlate with increase in GABA concentrations of the rat brain. *Eur. J. Pharmacol.*, 194: 77-81.
- Heim, H.K., A. Oestmann and K.F. Sewing, 1991. Effects of histamine and activators of the cyclic AMP system on protein synthesis in and release of high molecular weight glycoproteins from isolated gastric non-parietal cells. *Br. J. Pharmacol.*, 104: 526-530.
- Howden, C.W., 2004. Management of acid-related disorders in patients with dysphagia. *Am. J. Med. Suppl.*, 117: 44-48.
- Kabiruddin, M., 1921. Bayaz-e-kabir. Part II, Hikmat Book Depot, Hyderabad, India.
- Kinoshita, Y., C. Kawanami, K. Kishi, H. Nakata, Y. Seino and T. Chiba, 1997. *Helicobacter pylori* independent chronological change in gastric acid secretion in the Japanese. *Gut*, 41: 452-458.
- Kitagawa, H., M. Fjuwara and Y. Osumi, 1979. Effect of water immersion stress on gastric secretion and mucosal blood flow in rats. *Gastroenterology*, 77: 298-302.

- Koo, M.W.L., C.W. Ogle and C.H. Cho, 1986. Effects of verapamil, carbenoxolone and n-acetylcysteine on gastric wall mucus and ulceration in stressed rats. *Pharmacology*, 32: 326-334.
- Leung, Y.A., 1980. *Encyclopedia of Common Natural Ingredients Used in Food Drug and Cosmetics*. John Wiley and Sons, New York, USA., pp: 409.
- Levine, R.J., 1971. A Method for Rapid Production of Stress Ulcers in Rats. In: *Peptic Ulcer*, Pfeiffer, C.J. (Ed.). Munksgaard, Copenhagen, pp: 92-97.
- Marotti, M., R. Piccaglia, E. Giovanellio, S.G. Deans and E. Eaglesham, 1994. Effects of variety and ontogenic stage on the essential oil composition and biological activity of fennel (*Foeniculum vulgare* Mill.). *J. Essent. Oil Res.*, 6: 57-62.
- Mascolo, N., G. Autore, F. Capasso, A. Menghini and M.P. Fasulo, 1987. Biological screening of Italian medicinal plants for anti-inflammatory activity. *Phytother. Res.*, 1: 28-31.
- Newberne, P.M., W.W. Carlton and W.R. Brown, 1989. Histopathological evaluation of proliferative liver lesions in rats fed trans-anethole in chronic studies. *Food Chem. Toxicol.*, 27: 21-26.
- Odabasoglu, F., A. Cakir, H. Suleyman, A. Aslan, Y. Bayir, M. Halici and C. Kazaz, 2006. Gastroprotective and antioxidant effects of usnic acid on indomethacin-induced gastric ulcer in rats. *J. Ethnopharmacol.*, 103: 59-65.
- Rafatullah, S., M.A. Al-Yahya, M.S. Al-Said, K.U. Abdul Hameed Taragan and J.S. Mossa, 1994. Gastric anti-ulcer and cytoprotective effects of *Cyamopsis tetragonoloba* (Guar) in rats. *Int. J. Pharmacogn.*, 32: 163-170.
- Rainsford, K.D. and C. Willis, 1982. Relationship of gastric mucosal damage induced in pigs by antiinflammatory drugs to their effects on prostaglandin production. *Digestive Dis. Sci.*, 27: 624-635.
- Repetto, M.G. and S.F. Llesuy, 2002. Antioxidant properties of natural compounds used in popular medicine for gastric ulcers. *Braz. J. Med. Biol. Res.*, 35: 523-534.
- Robert, A., J.E. Nezamis, C. Lancaster, J.P. Daris, S.O. Field and A.J. Hanchar, 1983. Mild irritants prevent gastric necrosis through adaptive cytoprotection mediated by prostaglandins. *Am. J. Physiol.*, 245: G113-G121.
- Sedlak, J. and R.H. Lindsay, 1968. Estimation of total protein bound and non protein sulfhydryl groups in tissue with Ellman's reagent. *Anal. Biochem.*, 25: 192-205.
- Shay, H., S.A. Komarov, S.S. Fels, D. Meranze, M. Gruenstein and H. Sipler, 1945. A simple method for the uniform production of gastric ulceration in the rat. *Gastroenterology*, 4: 43-61.
- Szabo, S., J.S. Trier and P.W. Frank, 1981. Sulfhydryl compounds may mediate gastric cytoprotection. *Science*, 214: 200-202.
- Truhaut, R., B. Le Bourhis, M. Atlia, R. Glomot, J. Newman and J. Galdwell, 1989. Chronic toxicity/carcinogenicity study of trans-anethole in rats. *Food Chem. Toxicol.*, 27: 11-20.
- Utley, H.G., F. Bernheim and P. Hochstein, 1967. Effect of sulfhydryl reagents on peroxidation in microsomes. *Arch. Biochem. Biophysics*, 118: 29-32.
- Wallace, J.L. and B.J. Whittle, 1986. Role of mucus in the repair of gastric epithelial damage in the rat inhibition of epithelial recovery by mucolytic agents. *Gastroenterology*, 91: 603-611.
- Wiseman, R.W., E.C. Miller, J.A. Miller and A. Liem, 1987. Structure-activity studies of the hepatocarcinogenicities of alkenylbenzene derivatives related to estragole and safrole on administration to preweaning male C57BL/6J x C3H/HeJ F1 mice. *Cancer Res.*, 47: 2275-2283.