International Journal of Pharmacology

ISSN 1811-7775

science alert

ansinet
Asian Network for Scientific Information

OPEN ACCESS International Journal of Pharmacology

ISSN 1811-7775
DOI: 10.3923/ijp.2017.934.945

Research Article

Date Extract Prevent Hypogonadism In Rat Suffering From Liver Damage Induced By Carbon Tetrachloride

[1,2]Abdeldayem Zakaria, [2]Aida El-Sayed Bayad, [3]Sherief Mohamed Abdel-Raheem, [4]Marwa Farouk Ali, [1]Khalid Ahmed Al-Busadah, [1]Ibrahim Fahd Albokhadaim, [1]Mohammed Hamad Al-Nazawi and [1]Abdullah Yousif Al-Taher

[1]Department of Physiology, Biochemistry and Pharmacology, College of Veterinary Medicine, King Faisal University, PO Box 400, 31982 Al Ahsa, Kingdom of Saudi Arabia
[2]Faculty of Veterinary Medicine, Alexandria University, Rosetta Line, 22758 Behera Province, Egypt
[3]Department of Veterinary Public Health and Animal Husbandry, College of Veterinary Medicine, King Faisal University, PO Box 400, 31982 Al Ahsa, Kingdom of Saudi Arabia
[4]Department of Pathology and Clinical Pathology and [6]Department of Animal Nutrition and Clinical Nutrition, Faculty of Veterinary Medicine, Assiut University, 71526, Egypt

Abstract

Background: There is a relationship between hypogonadism and liver cirrhosis caused by chronic hepatitis. Date palm are widely used in traditional medicine for treatment of different diseases including, liver troubles. **Objective:** The objective of the study was to evaluate the role of date flesh or pit aqueous extract in prevention of hypogonadism resulted from liver damage. In addition, to determine the most effective extract and the exact time of its application. **Materials and Methods:** Sixty rats were divided into 6 equal groups. Control treated daily orally and intraperitoneally with distilled water and olive oil respectively. Group 2: injected on the days 1, 2 and 3 of the treatment period I/P with CCl_4. Groups 3 and 5: (Pretreatment date flesh or date pit groups) were administrated aqueous extract of date flesh or pit orally and treated with CCl_4 on day 30, 31 and 32 of the treatment period. Group 4 and 6: (Post treatment date-flesh or date-pit group) were administrated aqueous extract of date flesh or date-pit orally and treated with CCl_4 on the days 1, 2 and 3 of the treatment period. The experimental period was 60 days. The data were analyzed statistically using one-way analysis of variance procedures and Duncan's test. **Results:** Rat treated with CCl_4 showed significant $p \leq 0.01$ decrease in final body (g), reproductive organs (index weight), liver (index weight) and kidney weights (gm), serum testosterone, gonadotrophins, testicular zinc and testosterone, semen characteristics, total protein, albumin, glucose, antioxidative enzymes and showed significant $p \leq 0.01$ increase in serum estrogen, prolactin and testicular cholesterol, sperm abnormalities, urea, creatinine, lipid profile, bilirubin, liver enzymes and malondialdehyde. Treatment with date flesh or date pit extracts before or after CCl_4 treatment caused reverse to these results. **Conclusion:** Pre and post oral treatment with the aqueous extracts of date pits or flesh at the same time with CCl_4 has hepatoprotective effect, which in turn prevent hypogonadism due to liver damage.

Key words: CCl_4, date flesh or pit extract, hypogonadism, liver damage, oxidative stress

Received: April 24, 2017 Accepted: July 05, 2017 Published: October 15, 2017

Citation: Abdeldayem Zakaria, Aida El-Sayed Bayad, Sherief Mohamed Abdel-Raheem, Marwa Farouk Ali, Khalid Ahmed Al-Busadah, Ibrahim Fahd Albokhadaim, Mohammed Hamad Al-Nazawi and Abdullah Yousif Al-Taher, 2017. Date extract prevent hypogonadism in rat suffering from liver damage induced by carbon tetrachloride. Int. J. Pharmacol., 13: 934-945.

Corresponding Author: Abdeldayem Zakaria, Department of Physiology, Biochemistry and Pharmacology, College of Veterinary Medicine, King Faisal University, PO Box 400, 31982 Al Ahsa, Kingdom of Saudi Arabia Tel: 00966506812296

Competing Interest: The authors have declared that no competing interest exists.

Data Availability: All relevant data are within the paper and its supporting information files.

INTRODUCTION

Carbon tetrachloride (CCl_4) is recognized to be nephrotoxic and hepatotoxic to both experimental animals and humans[1-3]. It was established that one of the most potent environmental hypotoxin is CCl_4[4]. One of the worldwide health problem is liver cirrhosis, in the developing countries it is believed to be the seventh leading cause of death[5].

The hypogonadism is combined in both non-alcohol-induced and alcohol induced cirrhosis, demonstrated by low testosterone level, impotence, small testes, infertility, higher serum levels of prolactin and 17ß-estradiol and lower FSH[6-7]. There is a relationship between hypogonadism and liver cirrhosis caused by chronic hepatitis[8]. Testicular size reduction, drastic histopathological changes and absence of germinal layer were observed in advanced cirrhosis caused by CCl_4 in rats[9-10].

Date palm (*Phoenix dactylifera* L.) has been cultivated since long time in the Middle East especially at the countries around the Arabian Gulf. The different parts of this plant are widely used in traditional medicine for treatment of different diseases including, liver troubles and to frustrate alcohol intoxication[11]. It is proved scientifically that the date palm possess many pharmacological activities, which suggest that it can used for treatment of various types of diseases and disorders.

Whereas research tend to treat liver troubles without reference to the testes will return to normal or not therefore, the present study has been designed to evaluate the protective activity of aqueous extract of date flesh or pit for reproductive system against the hypogonadism in rats with liver damage induced by CCl_4.

MATERIALS AND METHODS

Experimental animals: Sixty adult male Wister rats, with average weight 200 grams were obtained from King Faisal University Experimental Station at Al-Ahsa, Kingdom of Saudi Arabia, they housed in plastic cages at Laboratory of Physiology Department. The experiment was performed following the ethics guidelines of King Faisal University and the National Committee of Medical and Bioethics (KFU-REC/2017-02-02). The animals were accommodated in controlled environment (temperature: 20-24°C and relative humidity 65% and a 12 h light-dark cycle). The standard rat pellet and water were offered to the rats as ad libitum. The chemical composition of standard rat pellets was 12% moisture, 4.15 kcal g^{-1} metabolizable energy, 22% crude protein, 5% crude fat, 4 and 6% ash, 1% calcium, 0.74% phosphorus and 28% starch.The chemical analysis of feed samples was performed by food scan (near infrared spectroscopy).

Experimental design: The rats were divided randomly into six groups each of 10 rats as the following: Group 1: normal control treated orally for 60 consecutive days and intraperitoneally for 3 days with equivalent amount of the vehicle (distilled water and olive oil, respectively). Group 2: CCl_4 treated group were injected I/P on the days 1, 2 and 3 of the treatment period with 0.2 mL/100 g body weight (equal volume of olive oil and CCl_4)[12]. Group 3: (Pretreatment date flesh group) were administered 4 mL of aqueous extract of date flesh/kg body weight[2] for 60 consecutive days and treated as group 2 on day 30, 31 and 32 of the treatment period. Group 4: (Post treatment flesh group): were administrated 4 mL of aqueous extract of date flesh for 60 consecutive days and treated as group 2 on the days 1, 2 and 3 of the treatment period. Group 5 (pretreatment date-pit group): were administrated 4 mL of aqueous extract of date-pit for 60 consecutive days and treated as group 2 on day 30, 31 and 32 of the treatment period. Group 6: (Post treatment date-pit group) were administrated 4 mL of aqueous extract of date-pit for 60 consecutive days and treated as group II on day 1, 2 and 3 of the treatment period.

Date and pits extract preparation: The pits were manually separated from date flesh then the flesh and the pit powder were soaked separately in cold distilled water for 2 days[12] (3:1 volume: weight) at 4°C. The water extract of both date flesh or pit powder were prepared freshly and were administrated orally to the rats.

Samples preparation: The body weight of each rat was recorded at the beginning and at the end of the experimental period. Twenty-four hours after the end of the experimental period, all rats were anaesthetized with xylazine and ketamine. Individual blood samples were collected and once serum samples were gathered, immediate biochemical analysis was performed. Immediately after blood collection, testes, epididymis, prostate, seminal vesicle, kidney and liver were collected, grossly examined, blot dry and weighed in grams. One testis from each animal was stored at-70°C until used for antioxidant, biochemical and hormonal assay.

Histopathological examination: Fresh specimens from the liver, kidney and the testes of all experimental groups were

fixed in 10% neutral buffered formalin pH 7. The tissues were dehydrated in a graded analytical alcohol series (60, 70, 80, 90 and 100%) cleared with analytical methyl benzoate, embedded in analytical paraffin wax, sectioned at 4 μm thickness and stained with hematoxylin and eosin for histopathological examination by light microscopy (Leitz Wetzlar, Germany)[13].

Biochemical investigation: Serum glucose (mg dL^{-1}) (EP37L-600), alanine aminotrasnaminase (U L^{-1}) (ALT, EP07-500), aspartate aminotransaminase (U L^{-1}) (AST, EP15-500), Alkaline phosphatase (U L^{-1}) (ALP, EP04L-660), albumin (g dL^{-1}) (EP03-570), Total protein (g dL^{-1}) (EP56-660), Creatinine (mg dL^{-1}) (EP33K-660), blood urea nitrogen (mg dL^{-1}) (BUN, EP20-420). Cholesterol (mg dL^{-1}) (EP24-660), Triglyceride (mg dL^{-1}) (EP59-660) were estimated by kits supplied by United Diagnostic Industry (UDI), Dammam, Saudi Arabia. Lactic acid dehydrogenase (U dL^{-1}) by kits purchased from Reactivos GPL (Spain), LDL (mg dL^{-1}) and LDH (mg dL^{-1}) using standard AMP diagnostic kits (Graz, Austria) and total bilirubin (mg dL^{-1}) using kits supplied by Diamond Diagnostics, Egypt. All assay were done according to manufacture guide using ELIPSE full-automated chemistry analyzer (Rome, Italy).

Oxidative stress assay: One testis from each animal was homogenized in cold potassium phosphate buffer (pH 7.4) then centrifuged at 5000 rpm at 4°C for 10 min, the supernatant was used for estimation of Superoxide dismutase (μ g^{-1} tissue) (SOD, Catalog No. 706002); Glutathione (μM) (GSH, Catalog No. 703002). Malodialdehyde (μM) (MDA Catalog No. 10009055); Glutathione-S-transferase (nmol min^{-1} g^{-1} tissue) (GST, Catalog No. 703302) and Catalase (nmol min^{-1} g^{-1} tissue) (CAT, Catalog No. 707002) according to the manufacture guides of commercial available kits (Cayman Chemical Company, USA), using ELISA reader (Absorbance Microplate Reader ELx 800TM BioTek®, USA).

Zinc and cholesterol content in the testes: Zinc (μ g^{-1}) content in the testes was estimated colorimetrically following the manufacture guides of commercial kits purchased from (Quinica Clinica Alpicada, SA, Spain). Also, Cholesterol (mg g^{-1}) (EP24-660) content was estimated in the testes.

Hormonal assay: Serum estradiol 17ß level (pg mL^{-1}), Follicle-Stimulating Hormone (FSH) (ng mL^{-1}) and Luteinizing Hormone (LH) (ng mL^{-1}), serum (ng mL^{-1}) and testicular testosterone (ng g^{-1}) were determined using ELISA technique using rat specific kits supplied by BioVendor (Gunma, Japan). Prolactin (PRL) level (ng mL^{-1}) was estimated by immunoradiometric assay using liquid phase MAIAclone kits (Adaltis Italia S.P.A., Rome Italy). All hormone were assayed according to the manufacture guide of each kit.

Semen analysis: Modified method of Yokoi *et al.*[14] was used for epididymal sperm count. The epididymis was cut into its three parts head, body and tail, then they were grind in 5 mL phosphate buffer (pH 7.4) then they were shake vigorously. In the counting chamber of the haemocytometer, an aliquot (10 μL) of epididymal sperm suspension was placed and was count under a microscope (200× magnification). The sperm heads were counted and expressed as million mL^{-1}. On a clean slide, a thin film of epididymal content of each rat mixed with an equal drop of eosin-nigrosine stain. The viability percent was taken as an average from 200 sperms examined per slide. The progressive motility was evaluated. The cauda epididymis content was obtained with a pipette and diluted with tris buffer solution to 2 mL. At 400× magnification, the motility was evaluated, in each sample the average final motility score was estimated from 3 different fields. The percentages of abnormal spermatozoa were recorded using light microscope (400×), 10 μL of 1% eosin and nigrosine was mixed with 40 μL of sperm suspension, a total of 200 sperm were examined on each slide and the average was taken in each sample.

Statistical analysis: The data obtained were statistically analyzed using one-way analysis of variance procedures of the Statistical Analysis System computer package[15]. Duncan test[16] was used to detect differences among means of different groups.

RESULTS

Body, reproductive organs, liver and kidney weights: Rat treated with CCl_4 showed significant ($p \leq 0.01$) decrease in final body, reproductive organs, liver and kidney weights compared with control group. The same parameters were increased significantly ($p \leq 0.01$) in groups treated with date flesh or date pit extracts before or after CCl_4 treatment as compared to CCl_4 (Table 1).

Hormonal change and testicular zinc and cholesterol: As shown in Table 2 treatment of rats with CCl_4 caused a significant ($p \leq 0.01$) decrease in serum testosterone, Luteinizing Hormone (LH), Follicle-Stimulating Hormone (FSH) and testicular testosterone, while it caused a significant

Table 1: Effect of CCl_4, date flesh and date pit extracts on body, reproductive organs, liver and kidney weights in male rats

Parameters*	Control	CCl_4	CCl_4+date extract	CCl_4+pit extract	Date extract+CCl_4	Pit extract+CCl_4
Initial body weight (g)	198.30±1.63	197.20±2.10	198.40±1.66	197.50±2.01	200.00±1.90	197.30±1.27
Final body weight (g)	229.00±1.80^{a}	213.00±1.53^{b}	229.00±1.40^{a}	227.30±1.30^{ac}	227.70±1.60^{ac}	224.00±1.63^{c}
Testes (index weight)	1.33±0.04^{a}	0.70±0.02^{b}	1.00±0.02^{c}	0.90±0.05^{d}	0.94±0.02^{cd}	0.88±0.05^{d}
Epididymis index weight	0.13±0.00^{a}	0.04±0.00^{b}	0.09±0.00^{c}	0.07±0.01^{d}	0.07±0.00^{d}	0.06±0.01^{d}
Prostate index weight	0.27±0.02^{ac}	0.16±0.02^{b}	0.21±0.01^{abc}	0.25±0.05^{ac}	0.29±0.04^{c}	0.19±0.01^{ab}
Seminal vesicle index weight	0.73±0.04^{a}	0.58±0.02^{b}	0.62±0.02^{b}	0.61±0.01^{b}	0.63±0..02^{b}	0.59±0.02^{b}
Liver weight	12.87±0.24^{a}	9.47±0.26^{b}	10.45±0.31^{c}	9.73±0.21^{bc}	10.16±0.21^{cd}	9.76±0.16^{bc}
Kidney index weight	0.023±0.001^{a}	0.033±0.001^{b}	0.024±0000^{ac}	0.027±0.00^{d}	0.025±0.000^{c}	0.028±0.000^{d}

*Means SEM: Standard Errors of the Means. $^{a-d}$Means in the same raw having different superscript letters are significantly different ($p \leq 0.01$). Number = 10

Table 2: Effect of CCl_4, date flesh and date pit extracts on serum and testicular testosterone, testicular zinc and cholesterol, serum estrogen, FSH, LH and PRL and semen characteristic in male rats

Parameters	Control	CCl_4	CCl_4+date extract	CCl_4+pit extract	Date extract+CCl_4	Pit extract+CCl_4
Serum testosterone (ng mL^{-1})	2.92±0.08^{a}	0.69±0.04^{b}	1.63±0.05^{c}	1.39±0.09^{d}	1.61±0.03^{c}	1.31±0.08^{d}
Testicular testosterone (ng gm^{-1})	9062.10±38.8^{a}	805.00±11.60^{b}	8102.20±9.22^{c}	7779.60±52.91^{d}	8059.00±13.7^{c}	6184.70±19.6^{e}
Testicular zinc (μ g^{-1})	19.22±0.15^{a}	8.78±0.12^{b}	16.27±0.13^{c}	13.14±0.31^{d}	16.17±0.10^{c}	13.07±0.31^{d}
Testicular cholesterol (mg g^{-1})	16.79±0.24^{a}	46.07±0.24^{b}	21.38±0.14^{c}	24.64±0.21^{d}	21.42±0.21^{c}	24.87±0.23^{d}
LH (ng mL^{-1})	3.32±0.07^{a}	1.19±0.05^{b}	2.08±0.11^{c}	1.79±0.05^{d}	1.84±0.05^{d}	1.79±0.06^{d}
PRL (ng mL^{-1})	10.28±0.14^{a}	23.25±0.68^{b}	14.29±0.14^{c}	14.90±0.14^{c}	14.44±0.26^{c}	15.95±0.29^{d}
FSH (ng mL^{-1})	45.65±0.50^{a}	23.86±0.68^{b}	35.94±0.22^{c}	32.35±0.58^{d}	34.64±0.34^{e}	31.78±0.19^{d}
Estrogen (pg mL^{-1})	15.66±0·28^{a}	32.12±0·37^{e}	19.75±0.26^{b}	21.52±0·37^{cd}	20.72±0.31^{c}	22.00±0.18^{d}
Sperm concentration ($X10^{6}$)	107.20±3.63^{a}	63.60±2.05^{b}	94.80±1.20^{c}	91.80±1.12^{c}	92.10±1.40^{c}	90.70±1.72^{c}
Sperm motility (%)	91.40±1.05^{a}	66.50±1.25^{c}	84.90±1.15^{d}	82.40±1.5^{d}	84.00±0.98^{d}	77.10±1.48^{e}
Live sperm (%)	91.20±0.49^{a}	66.50±1.04^{b}	83.80±0.49^{c}	73.80±0.53^{d}	76.70±0..54^{e}	71.80±0.39f
Sperm abnormality (%)	5.80±0.36^{a}	26.70±1.33^{b}	12.70±0.56^{c}	13.20±0.79^{c}	12.90±0.75^{c}	13.70±0.45^{c}

$^{a-d}$Means in the same raw having different superscript letters are significantly different ($p \leq 0.01$). Number = 10, SEM: Standard Errors of the Means

Table 3: Effect of CCl_4, date flesh and date pit extracts on biochemical parameters in male rats

Parameters	Control	CCl_4	CCl_4+date extract	CCl_4+pit extract	Date extract+CCl_4	Pit extract+CCl_4
BUN (mg dL^{-1})	19.12±0.48^{a}	47.88±0.51^{b}	25.02±0.14^{c}	25.41±0.23^{c}	25.46±0.21^{c}	25.90±0.19^{c}
Creatinine (mg dL^{-1})	0.84±0.04^{a}	2.81±0.18^{b}	1.16±0.04^{c}	1.44±0.06^{de}	1.31±0.04^{cd}	1.60±0.03^{e}
Albumin (g dL^{-1})	4.73±0.05^{a}	3.27±0.06^{d}	4.22±0.04^{b}	3.88±0.12^{c}	4.04±0.10^{bc}	3.42±0.13^{d}
Total protein (g dL^{-1})	7.68±0.09^{a}	4.61±0.17^{b}	6.33±0.05^{c}	6.03±0.34^{c}	6.21±0.11^{c}	6.03±0.18^{c}
Cholesterol (mg dL^{-1})	52.42±0.30^{a}	71.61±0.43^{b}	59.51±0.39^{c}	63.41±0.44^{d}	60.79±0.41^{e}	65.93±0.65^{f}
HDL (mg dL^{-1})	14.94±0.27^{a}	21.81±0.28^{b}	16.33±0.27^{c}	16.84±0.20^{c}	16.62±0.36^{c}	18.34±0.25^{d}
LDL (mg dL^{-1})	33.37±0.24^{a}	43.19±0.32^{b}	36.12±0.12^{c}	36.52±0.19^{c}	36.44±0.20^{c}	37.60±0.32^{d}
Glucose (mg dL^{-1})	95.07±0.56^{a}	63.94±0.58^{e}	84.30±0.71^{b}	72.22±0.35^{d}	74.05±0.56^{c}	71.84±0.95^{d}
LDH (U dL^{-1})	0.39±0.01^{a}	0.92±0.01^{b}	0.59±0.01^{c}	0.54±0.01^{d}	0.57±0.01^{c}	0.53±0.01^{d}
Triglyceride (mg dL^{-1})	8.60±0.14^{a}	16.70±0.28^{b}	11.75±0.15^{c}	12.14±0.17^{cd}	12.03±0.23^{c}	12.64±0.17^{d}
Bilirubin (mg dL^{-1})	0.15±0.01^{a}	2.61±0.11^{d}	0.26±0.01^{ab}	0.31±0.02^{b}	0.29±0.02^{ab}	0.36±0.02^{b}
ALT (μ L^{-1})	32.70±0.88^{a}	66.12±1.21^{b}	36.10±0.41^{c}	37.56±0.30^{c}	36.61±0.52^{c}	37.62±0.29^{c}
AST (μ L^{-1})	45.67±0.58^{a}	74.30±0.66^{b}	54.56±0.42^{c}	56.43±0.39^{d}	57.51±0.19^{de}	58.04±0.52^{e}
ALP (μ L^{-1})	66.24±0.74^{a}	181.0±11.37^{b}	76.43±0.75^{c}	87.54±0.58^{d}	83.96±0.80^{e}	87.93±0.41^{d}

$^{a-d}$Means in the same raw having different superscript letters are significantly different ($p \leq 0.01$). Number = 10, SEM: Standard Errors of the Means

($p \leq 0.01$) increase in serum estrogen, prolactin and testicular cholesterol as compared to control group. However, treatment with date flesh or date pit extracts before or after CCl_4 treatment caused significant ($p \leq 0.01$) increase in serum testosterone, LH, FSH and testicular testosterone, while it caused significant ($p \leq 0.01$) decrease in serum estrogen, prolactin and testicular cholesterol as compared to CCl_4 group.

Semen characteristics: The same Table 2 shows that treatment with CCl_4 caused significant ($p \leq 0.01$) decrease of sperm concentration, sperm motility and sperm viability, while it significantly ($p \leq 0.01$) increased sperm abnormalities as compared to control rats. However, treatment with date flesh or date pit extracts before or after CCl_4, treatment caused significant ($p \leq 0.01$) increase in serum testosterone, LH, FSH and testicular testosterone, while it caused significant ($p \leq 0.01$) increase in sperm concentration, sperm motility and sperm viability, while it decreased sperm abnormalities as compared to CCl_4 group.

Biochemical parameters: The mean values of serum creatinine, BUN, albumin, total protein, cholesterol, HDL, LDL, LDH, glucose, triglyceride, bilirubin, ALT, AST and ALP are shown in Table 3 after treatment with CCl_4, the mean values of

Table 4: Effect of CCl_4, date flesh and date pit extracts on the oxidative stress markers in male rats

Parameters	Control	CCl_4	CCl_4+date extract	CCl_4+pit extract	Date extract+CCl_4	Pit extract+ CCl_4
MDA (μM)	8.33 ± 0.13^{a}	16.77 ± 0.43^{b}	10.45 ± 0.20^{c}	11.23 ± 0.24^{cd}	10.75 ± 0.18^{c}	11.82 ± 0.29^{d}
CAT (nmol min^{-1} g^{-1} tissue)	44.60 ± 0.65^{a}	28.50 ± 0.39^{b}	38.64 ± 0.21^{c}	36.30 ± 0.25^{d}	36.85 ± 0.25^{d}	35.81 ± 0.26^{d}
GSH (μM)	7.42 ± 0.11^{a}	4.23 ± 0.12^{b}	5.46 ± 0.10^{c}	5.17 ± 0.16^{c}	5.30 ± 0.11^{c}	$4.49\pm0.24^{b'}$
GST (nmol min^{-1} g^{-1} tissue)	36.91 ± 1.05^{a}	18.31 ± 0.32^{b}	24.00 ± 0.45^{c}	23.42 ± 0.48^{c}	23.44 ± 0.23^{c}	23.21 ± 0.35^{c}
SOD (μ g^{-1} tissue)	66.81 ± 0.43^{a}	24.1 ± 0.32^{b}	53.96 ± 0.39^{c}	52.12 ± 0.40^{d}	52.8 ± 0.39^{cd}	48.62 ± 0.53^{e}

$^{a-d}$Means in the same raw having different superscript letters are significantly different ($p\leq0.01$). Number = 10, SEM: Standard Errors of the Means

Table 5: Effect of CCl_4, date flesh and date pit extracts on histopathological findings in liver in male rat

	Extensive necrosis of liver cells	Vacuolar degeneration in hepatocytes	Lymphocytic cell infiltration	Congestion of blood vessels
Group 1				
No. of rats	0	0	0	0
Severity	NO	No	No	No
Group 2				
No. of rats	8 rats	5 rats	3 rats	5 rats
Severity	Very high	Moderate	Low	Moderate
Group 3				
No. of rats	1 rat	5 rats	9 rats	2 rats
Severity	Very low	Low	Very high	Very low
Group 4				
No. of rats	0	7 rats	4 rats	9 rats
severity	No	Moderate	Low	Very high
Group 5				
No. of rats	0	3 rats	1 rat	10 rats
severity	No	Very low	Very low	Very high
Group 6				
No. of rats	0	6 rats	7 rats	2 rats
severity	No	Moderate	Very high	Low

serum creatinine, BUN, cholesterol, HDL, LDL, triglyceride, bilirubin, ALT, AST and ALP were significantly ($p\leq0.01$) increased as compared to control, while total protein, albumin, glucose and LDH were significantly ($p\leq0.01$) decreased as compared to control group. However, treatment with date flesh or date pit extracts before or after CCl_4 treatment caused significant ($p\leq0.01$) decrease of serum creatinine, BUN, cholesterol, HDL, LDL, triglyceride, bilirubin, ALT, AST and ALP as compared to CCl_4, while total protein, albumin, glucose and LDH were significantly ($p\leq0.01$) increased as compared to CCl_4 group.

Oxidative stress and antioxidants: Table 4 shows that MDA levels were increased significantly ($p\leq0.01$) while CAT, GSH, GST and SOD were significantly ($p\leq0.01$) decreased in CCl_4 treated group as compared to control group. Date flesh or date pit extracts treatment before or after CCl_4, treatment reversed these results where it caused significant ($p\leq0.01$) decrease in MDA while it caused significant ($p\leq0.01$) increase in CAT, GSH, GST and SOD when compared to the CCl_4 treatment.

Histopathological examination

Liver: Control rat showed normal structure of hepatic lobule (Fig. 1a). Histopathological examination of liver from rats post intraperitoneal injection by carbon tetrachloride showed focal areas of extensive necrosis of liver cells, which were present in most samples of this group (Fig. 1b). This necrosis decreased in the pretreated group with date flesh extract. In this group liver showed mild fragmentation and lysis of the cytoplasm of hepatocyte associated with karyolysis in nucleus. There were focal areas of lymphocytic cell infiltration (Fig. 1c). While in post treated group with date flesh extract, hepatocytes swollen due to intracellular accumulation of small to moderate amounts of small to medium-sized, clear, round vacuoles (interpreted as microvesicular lipid droplets) around nucleus in the cytoplasm combined with severe congestion of blood vessels (Fig. 1d). In pretreated group with date pit extract, there were focal areas of hepatic necrosis associated with congestion of the blood vessels which became very obvious in this group (Fig. 1e). The last group which post treated with date pit; there were severe proliferation of kuppfur cells in portal areas with vacuolar degeneration in hepatocytes. Vacuolar degeneration manifested by clear vacuoles in some hepatocytes in this group (Fig. 1f). The effect of CCl_4, date flesh and date pit extracts on histopathological findings in liver in male rat (the severity, extensive, necrosis of the liver cell, vacular degeneration of hepatocyte, lymphocyte infilteration and the number of animals show histopathological changes) was summarized in Table 5.

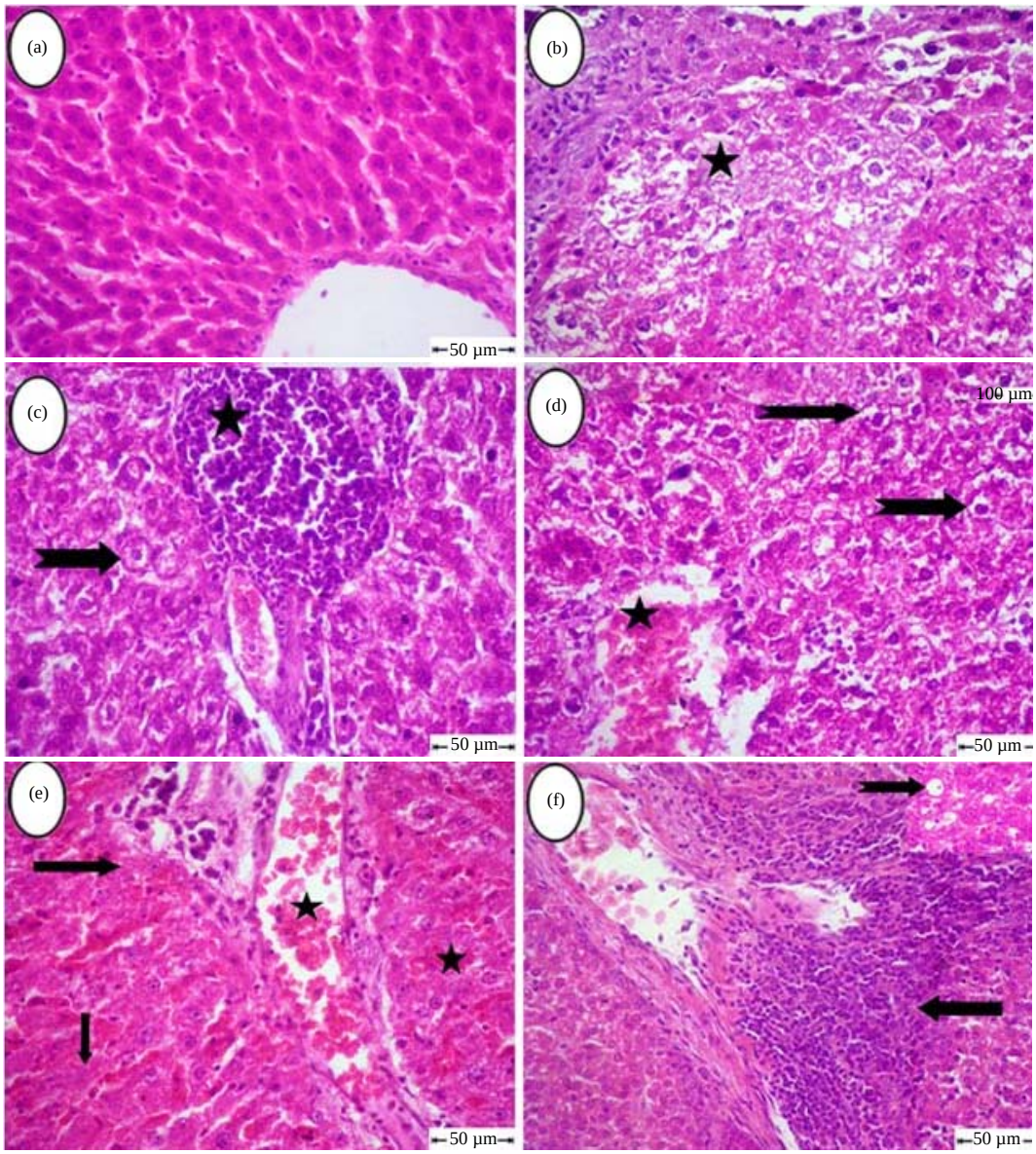

Fig. 1(a-f): Liver of rat (H and E) 50X, (a) Control showed normal structure, (b) Group 2 showing focal areas of necrosis (star), (c) Group 3 showing cytoplasmic vacuolation (notched arrow) and lymphocytic infiltration (star), (d) Group 4 showing swollen hepatocytes (notched arrow) and congestion (star), (e) Group 5 showing necrosis (arrow) and congestion X100 and (f) Group 6 showing proliferation of kupffur cells (arrow) and vacuolar degeneration (notched arrow)

Kidney: Control kidney showed the normal appearance of glomerulous and numerous proximal and distal convoluted tubules (Fig. 2a). Compared to kidney of intraperitoneal injected rats with carbon tetrachloride showed vacuolar degeneration in the proximal and distal convoluted tubules (Fig. 2b). In the pretreated group with date flesh extract, there was interstitial nephritis characterized by inflammatory cellular infiltration in the interstitial tissue accompanied with hyperemia between renal tubules (Fig. 2c). Vascular changes include interstitial hemorrhage in cortical and medullary areas became very characteristic in post treated group with date flesh extract (Fig. 2d). In other treated groups with date pit extract either before or after toxicity with carbon tetrachloride, kidney showed interstitial hemorrhage in cortical areas and congestion of blood vessels associated with proliferation of interstitial inflammatory cells between renal tubules (Fig. 2e).

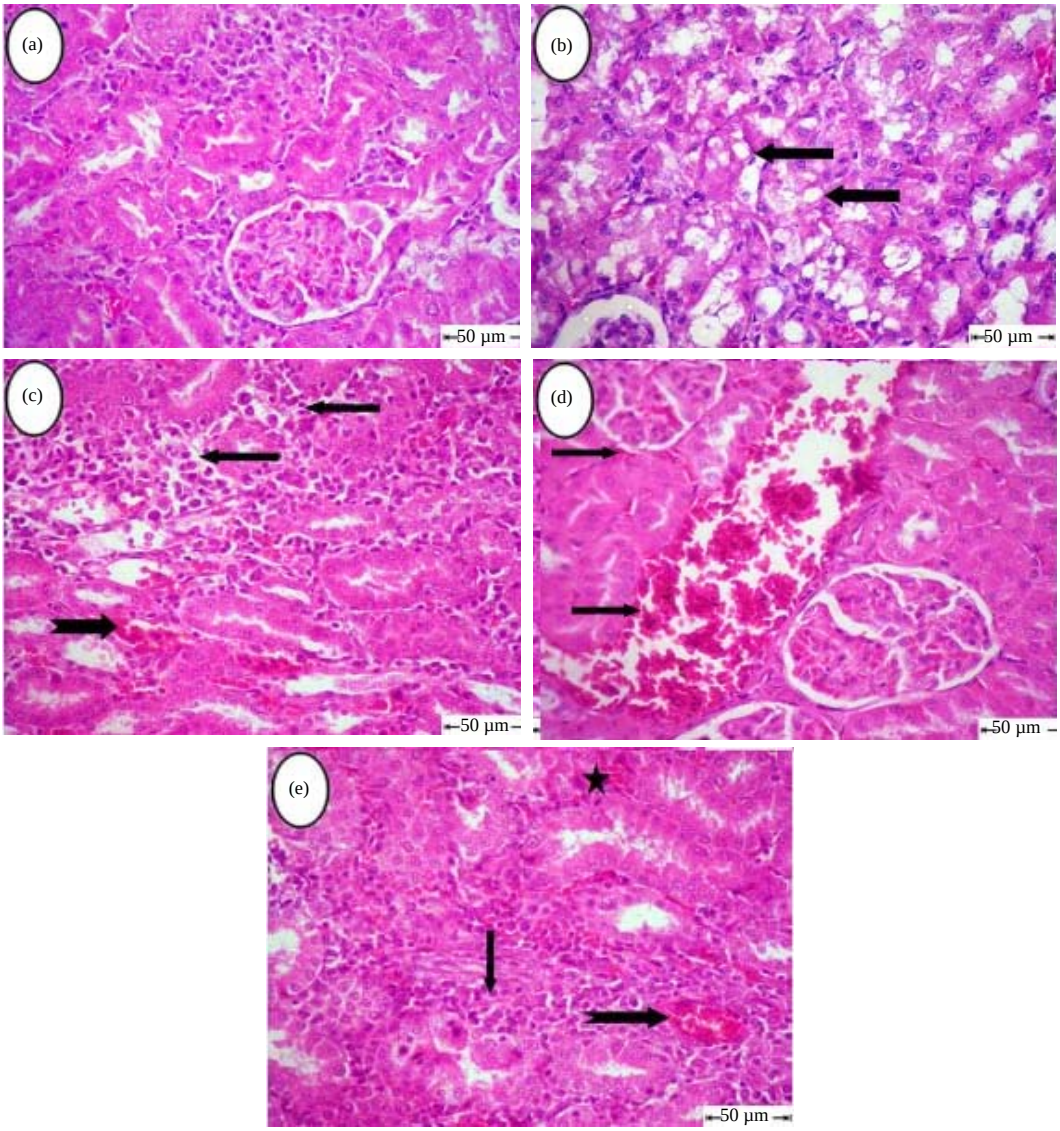

Fig. 2(a-e): Kidney of rat (H and E) X50, (a) Control showed normal structure, (b) Group 2 showing vacuolar degeneration in renal tubules (arrow), (c) Group 3 showing lymphocytic infiltration in the interstitial tissue (arrow) and hyperemia (notched arrow), (d) Group 4 showing hemorrhage (arrow) and (e) Group 6 showing interstitial hemorrhage (star) and congestion (notched arrow) with inflammatory cells (arrow)

Testes: Testes of control group showed no changes in structure of semineferous tubules with interstitial connective tissue (Fig. 3a). All layers of semineferous tubules are complete in the control rat (Fig. 3b). Testes from rats post intraperitoneal injection by carbon tetrachloride showed loss of germ cells in some seminiferous tubules (Fig. 3c). This loss expressed by little decrease in spermatogenesis to two or three layers of germ layers of seminiferous tubule (Fig. 3d). These changes in semineferous tubules became absent in treated groups with date flesh or pit extracts.

DISCUSSION

In the present investigation serum, hepatic biomarkers ALT and AST were significantly ($p \leq 0.01$) increased in CCl_4 treated group in comparison to control group. Since the place of these enzymes is cytoplasmic area of the cell and liberated into blood in case of cellular injury[17]. The increase in hepatic biomarkers ALT and AST could be attributed to liver injury. The histopathological examination in the present study revealed liver necrosis. These results are in line with the results of other

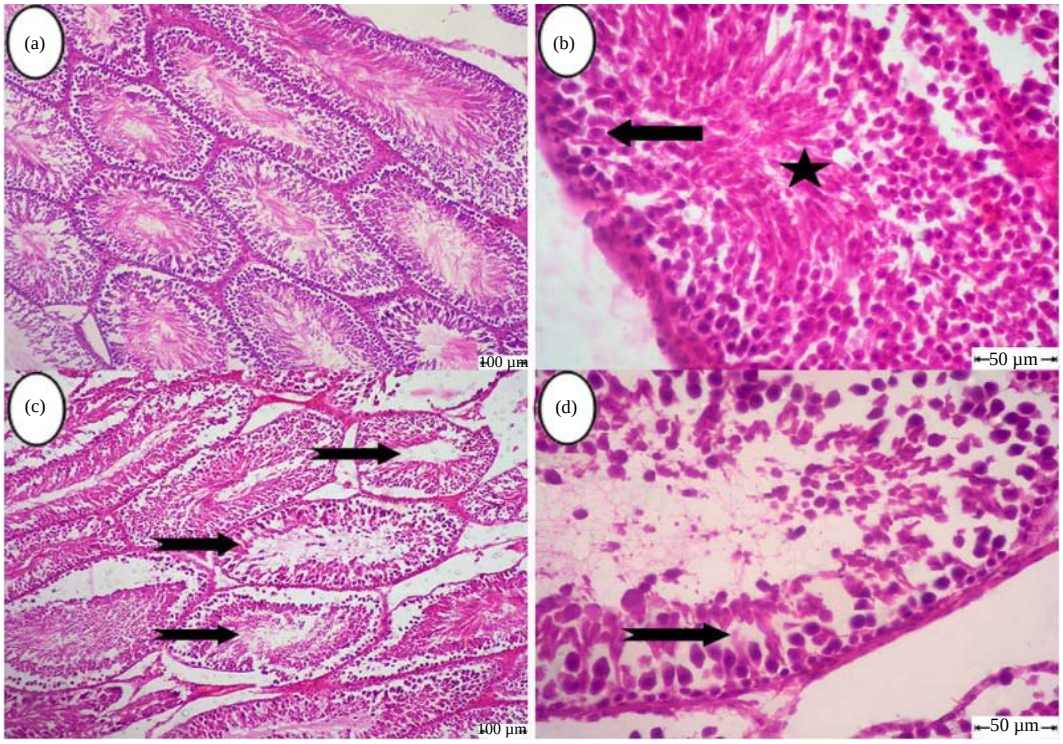

Fig. 3(a-d): Testes of rat (H and E) 100X, (a) Control showed normal structure, (b) Higher magnification showed normal spermatogonia (arrow) and spermatids (star) 50X, (c) Group 2 showing loss of germ cells (notched arrow) and (d) group 2 showing decrease in spermatogenesis (notched arrow)50X

researchers[18,19] who reported that these enzymes were significantly ($p \leq 0.05$) increased in CCl_4 treated animals and this increase has accompanied with increased necrosis of the liver. The hepatotoxic effect of CCl_4 is through lipid peroxidation, which is due to CCl_3 the active metabolite of CCl_4, which leads to cell injury and finally liver damage[20].

In accordance with the present finding, preceding studies have shown that serum ALP, creatinine and urea increased significantly ($p \leq 0.05$)[21] and the total protein and albumin decreased significantly ($p \leq 0.05$)[19,21] after CCl_4 treatment. The decrease in total protein may be attributed to proteinurea[22]. The decrease in serum albumin indicating impaired synthesis or poor liver functions, either primary as in the damage of the liver cells or secondary to decrease protein intake and diminish of amino acids absorption as a result of malabsorption syndrome or malnutrition or protein loss due to chronic glomerulonephritis or nephritic syndrome[23]. In the present study, the histopathological examination of the kidney revealed vascular degeneration in the proximal and distal convoluted tubules. There is a direct relationship between elevated blood urea and protein catabolism or the conversion of ammonia to urea[24]. Furthermore, the increase in serum creatinine and urea in CCl_4 treated group may be due to kidney dysfunction as suggested by histopathological examination.

In the present study, there was significant decrease ($p \leq 0.01$) in sperm count, viability, motility and morphology in the rats treated with CCl_4, the testes histopathology of these animals showed loss of germinal epithelium and decrease in spermatogenesis. This testicular degeneration is evidence by decrease in the testicular weight. Rat with compensated CCl_4 induced cirrhosis show some testicular alterations and gonadal dysfunction, from early stages of liver cirrhosis[9], the testosterone production in these individuals is about 25% of that of normal persons[25]. Sinclair *et al.*[26] stated that low plasma levels of non-protein bound, non-steroid hormones binding globulin bound testosterone and testosterone accompanied with decreasing liver function. This may elucidate increased propagation of testicular atrophy. Our results revealed that there was decrease in the levels of Luteinizing Hormone (LH), testosterone and Follicle Stimulating Hormone (FSH) and increased estrogen and prolactin levels in-group treated with CCl_4 when compared with the control one. These results are in line with the results

of Sahreen *et al.*[18] and Usman *et al.*[27] who investigate the effect of liver cirrhosis on endocrine disturbances. The decrease in testosterone levels signalizes either a direct action of CCl_4 at interstitial cells (Leydig cells) concentrations or an indirect action by disturbing the hormonal secretion at hypothalamus level[28]. Reduction in testosterone concentration in the testes suppresses spermatogenesis[29]. LH stimulates testosterone production by Leydig cells, which in turn stimulates FSH to bind with Sertoli cells to activate sperm formation[30]. In the present study, the CCl_4 suppressed FSH level in treated rats and this was in line with the results of Khan and Ahmed[9] who found significant ($p \leq 0.01$) decrease in FSH level in CCl_4 treated rats. The LH stimulate testosterone elevation that is the primary exciter for initiation of spermatogenesis[31]. Estrogen excites adenohypophysis directly by determining prolactinemia with malfunction of the hypothalamus in hypogonadism. Consequently, in the present study, the increased levels of prolactin and estrogen may also be appropriate principle of hypogonadism. Though, all these reduction in the andrological variable may not be due to consequences of hepatic damage alone. It could be assumed to CCl_4 toxic effect that able to produce free radicals resulting in oxidative stress that influence testicular germ cells, reducing the weight of the testes or even influence the secretion of LH and FSH from pituitary gland[27]. Also, it could be due to inhibition of binding of androgens to their receptors within the testes (vascular endothelial cells, Leydig cells, pretubular myoid cells and Sertoli cells)[32]. Androgen receptors expression in the Sertoli cells is essential for spermatogenesis; there are no production of sperm in animal with targeted Sertoli cell androgen receptors expression deletion. In the present study, MDA was increased while GSH, SOD, CAT and GS T were decreased in CCl_4 treated group. The present results are in accordance with the results of Khan and Ahmed[9] and Sahreen *et al.*[18] who reported that CCl_4 caused oxidative damage to DNA and proteins of the rat testes. Abdou *et al.*[33], Khan *et al.*[34] and Yuce *et al.*[35] reported that chronic or acute CCl_4 treatment caused functional, morphological and morphological damages in male laboratory animals reproductive system through oxidative stress. Oral administration of CCl_4 caused significant ($p \leq 0.01$) increases in lipid peroxidation, abnormal sperm percentage, index of apoptotic cells, beside some histopathological alteration in the testes and significant decrease ($p \leq 0.01$) in testicular catalase and glutathione peroxidase, along with significant decrease ($p \leq 0.01$) in sperm concentration and motility beside decrease in both absolute and relative weights of the reproductive organs[36].

ALT, AST and ALP activities reduced in rats pre and post-treated with the aqueous extracts of date pits or flesh plus CCl_4, showed their capability to restore, the normal functional status of the injured liver and to conserve against subsequent hepatotoxicity. This finding is confirmed by histopathological where the necrosis decreased in the pretreated group with date flesh extract, while in post treated group with date flesh extract, hepatocytes are swollen due to intracellular accumulation of small to moderate amounts of small to medium sized clear round vacuoles (interpreted as microvesicular lipid droplets). In the pretreated group with date pit extract, there were no changes of hepatocytes but congestion of blood vessels became obvious, this associated with hemosidrosis. While in the group post treated with date pit extract there were severe proliferation of Kupffur cells with vacuolar degeneration in some hepatocytes. The mechanism by which the aqueous extract of date flesh or pit exerts its hepato-protective action may be due to ß-sitosterol, vitamins A, C and E constituent which act as antioxidant or due to minerals like zinc. An additional and important factor in the liver protection of any drug is the capability of its compounds to suppress Cytochrome P-450 aromatase activity. That way support hepatic regeneration. On that foundation, it is proposed that flavonoids in Phoenix dactylifera L. might be a factor participate in its ability to protect liver through suppressing of the activities of aromatase of cytochrome P-450. Furthermore, the flavonoids (quercetin) protects also the anti-oxidative defense mechanism through rising the vitamin C absorption[37]. Quercetin has the ability to inhibit the oxidation of low-density lipoproteins by scavenging free radicals and chelating transition metal ions, therefore assisting in the prevention of different diseases. Moretti *et al.*[38] and Zribi *et al.*[39] reported that quercetin protects the male reproductive organs through as antioxidant aa well as pro-oxidant effect. It has been reported that quercetin provide significant improvements in case of high LOP level and low enzymatic and non-enzymatic antioxidants in the tissue of the testes as well as testicular histopathological lesions, deteriorated sperm parameters, decreased testosterone level and DNA damage[38,40]. Moreover, the vitamin C content in the date pits or flesh may perform a role in hepato protection. In the present study, either pit extract or date flesh extract administration improved the activities of the antioxidant enzymes (SOD, CAT and GST) as well as non-enzymatic (GSH).

There is significant ($p \leq 0.01$) amelioration in the reproductive parameters in pre or post treatment in date flesh or pit extracts in comparison to CCl_4 treated group. All sperm characteristics (concentration, viability, morphology and motility) were significantly improved. The observed improvement in reproductive variable and the reduction in liver damage are in consistent with the results of

Zacharias *et al.*[41] who reported that the abnormalities in cirrhosis of the liver is changeful. There were significant ($p \leq 0.01$) change between the LH, testosterone and FSH levels in group's pre and post treated with the aqueous extracts of date pits or flesh at the same time with CCl_4 in comparison to CCl_4 treated group. Mehraban *et al.*[42] stated that date extracts increased the sperm count, enhanced spermatogenesis and increased testosterone, LH and FSH levels in rats. The phytochemicals vitamin A[43] genistein[44] and selenium[45] have all been reported to possess gonadotrophic effect and protected testicular functions against various stress. Moreover, the powder date pits has probably caused an increase in sperm density and increased testosterone level[46].

The results of the present study indicate that date fruit or pit extracts can be used as palliative for the people who have hypogonadism resulted from liver damage or intoxication of CCl_4 without limitation.

CONCLUSION AND FUTURE RECOMMENDATION

It can be concluded from the present study that pre and post oral-treatment with the aqueous extracts of date pits or flesh at the same time with CCl_4 has hepatoprotective effect, which in turn prevent hypogonadism due to liver damage and the most effective one is aqueous extracts of date flesh post CCl_4 treatment.

It is recommended that from the current study to use the aqueous extracts of date pits or flesh to prevent hypogonadism and liver damage resulted from CCl_4 intoxication.

SIGNIFICANCE STATEMENTS

This study discovers the possible use of aqueous extracts of date pits or flesh in treatment hypogonadism resulted from either direct effect of CCl_4 on the testes or indirect effect through liver damage. This study will help the researcher to uncover the role of date in prevent hypogonadism resulted from liver damage that many researchers were not able to explore. Thus, this a new theory on the treatment of hypogonadism may be arrived at.

ACKNOWLEDGEMENTS

The authors are thankful to Scientific Research Deanship, King Faisal University, Saudi Arabia for supporting and funding this study (grant #140137).

REFFERENCES

1. Khan, M.R. and T. Younus, 2011. Prevention of CCl_4-induced oxidative damage in adrenal gland by *Digera muricata* extract in rat. Pak. J. Pharm. Sci., 24: 469-473.
2. Abdel Moneim, A.E. and K.M. El-Deib, 2012. The possible protective effects of *Physalis peruviana* on carbon tetrachloride-induced nephrotoxicity in male albino rats. Life Sci. J., 9: 1038-1052.
3. Al-Olayan, E.M., M.F. El-Khadragy, M.S. Othman, A.M. Aref, R.B. Kassab and A.E. Abdel Moneim, 2014. The potential protective effect of *Physalis peruviana* L. against carbon tetrachloride-induced hepatotoxicity in rats is mediated by suppression of oxidative stress and downregulation of MMP-9 expression. Oxidative Med. Cell. Longevity, 10.1155/2014/381413
4. Sarkar, K., A. Ghosh, M. Kinter, B. Mazumder and P.C. Sil, 2006. Purification and characterization of a 43 kD hepatoprotective protein from the herb *Cajanus indicus* L. Protein J., 25: 411-421.
5. Heidelbaugh, J.J. and M. Sherbondy, 2006. Cirrhosis and chronic liver failure: Part II. Complications and treatment. Am. Family Physician, 74: 767-776.
6. Tadic, S.D., M.S. Elm, V.M. Subbotin and P.K. Eagon, 2000. Hypogonadism precedes liver feminization in chronic alcohol-fed male rats. Hepatology, 31: 1135-1140.
7. Baker, H.W.G., 2000. Testicular Dysfunction in Systemic Disease. In: Principles and Practice of Endocrinology and Metabolism, Becker, K.L. (Ed.). 3rd Edn., Chapter 116, Lippincott Williams & Wilkins, Philadelphia, PA., USA., pp: 1150-1158.
8. Gursoy, S., M. Baskol, O. Ozbakir, K. Guven, F. Kelestimur and M. Yucesoy, 2004. Hypothalamo-pituitary gonadal axis in men with chronic hepatitis. Hepatogastroenterology, 51: 787-790.
9. Khan, M.R. and D. Ahmed, 2009. Protective effects of *Digera muricata* (L.) Mart. on testis against oxidative stress of carbon tetrachloride in rat. Food Chem. Toxicol., 47: 1393-1399.
10. Khan, M.R., G.N. Khan and D. Ahmed, 2011. Evaluation of antioxidant and fertility effects of *Digera muricata* in male rats. Afr. J. Pharm. Pharmacol., 5: 688-699.
11. Barh, D. and B.C. Mazumdar, 2008. Comparative nutritive values of palm saps before and after their partial fermentation and effective use of wild date (*Phoenix sylvestris* Roxb.) sap in treatment of Anemia. Res. J. Med. Med. Sci., 3: 173-176.
12. Al-Qarawi, A.A., H.M. Mousa, B.E.H. Ali, H. Abedl-Rahman and S.A. El-Mougy, 2004. Protective effect of extracts from dates (*Phoenix dactylifera* L.) on carbon tetrachloride-induced hepatotoxicity in rats. Int. J. Rev. Vet. Med., 2: 176-179.

13. Lillie, R.D., 1965. Histopathologic Technic and Practical Histochemistry. 3rd Edn., McGraw-Hill, New York.
14. Yokoi, K., E.O. Uthus and F.H. Nielsen, 2003. Nickel deficiency diminishes sperm quantity and movement in rats. Biol. Trace Elem. Res., 93: 141-154.
15. SAS., 2001. SAS User's Guide: Statistics. SAS Institute, Carry, USA.
16. Duncan, D.B., 1955. Multiple range and multiple F tests. Biometrics, 11: 1-42.
17. Thapa, B.R. and A. Walia, 2007. Liver function tests and their interpretation. Indian J. Pediatr., 74: 663-671.
18. Sahreen, S., M.R. Khan and R.A. Khan, 2011. Hepatoprotective effects of methanol extract of Carissa opaca leaves on CCl4-induced damage in rat. BMC Complement. Altern. Med., Vol. 11. 10.1186/1472-6882-11-48
19. El-Bahr, S.M., 2014. Camel milk regulates gene expression and activities of hepatic antioxidant enzymes in rats intoxicated with carbon tetrachloride. Asian J. Biochem., 9: 30-40.
20. Park, W.H., S.K. Lee and C.H. Kim, 2005. A Korean herbal medicine, *Panax notoginseng*, prevents liver fibrosis and hepatic microvascular dysfunction in rats. Life Sci., 76: 1675-1690.
21. Khan, A.A. and M.A. Alzohairy, 2011. Hepatoprotective effects of camel milk against CCl_4-induced hepatotoxicity in rats. Asian J. Biochem., 6: 171-180.
22. Bellizzi, V., A. Cupisti, F. Locatelli, P. Bolasco and G. Brunori *et al*., 2016. Low-protein diets for chronic kidney disease patients: The Italian experience. BMC Nephrol., Vol. 17. 10.1186/s12882-016-0280-0
23. Al-Fartosi, K.G., A. Majid, M.A. Auda and M.H. Hussein, 2012. The role of camel's milk against some oxidant-antioxidant markers of male rats treated with CCl_4. Int. J. Res. Pharmaceut. Biomed. Sci., 3: 385-389.
24. Eckersall, P.D., 2008. Proteins, Proteomics and the Dysproteinemias. In: Clinical Biochemistry of Domestic Animals, Kaneko J.J., J.W. Harvey and M.L. Bruss (Eds.). 6th Edn., Chapter 5, Academic Press, San Diego, pp: 117-155.
25. Morley, J.E. and G.A. Wittert, 2007. Male Hormones and Systemic Disease. In: Male Reproductive Dysfunction: Pathophysiology and Treatment, Kandeel, F.R., R.S. Swerdloff and J.L Pryor (Eds.). Taylor and Francis Group, Boca Raton, FL., USA., ISBN-13: 9781420018813.
26. Sinclair, M., M. Grossmann, P.J. Gow and P.W. Angus, 2015. Testosterone in men with advanced liver disease: Abnormalities and implications. J. Gastroenterol. Hepatol., 30: 244-251.
27. Usman, J.D., A.A. Fasanmade and N. Kester, 2015. Effects silymarin on reproductive variables on male Wistar rats with carbon tetrachloride (CCl_4)-induced liver fibrosis. Am. J. Innov. Res. Applied Sci., 1: 214-221.
28. Latif, R., G.M. Lodhi and M. Aslam, 2008. Effects of amlodipine on serum testosterone, testicular weight and gonado-somatic index in adult rats. J. Ayub Med. Coll. Abbottabad, 20: 8-10.
29. Tohda, A., K. Matsumiya, Y. Tadokoro, K. Yomogida and Y. Miyagawa *et al*., 2001. Testosterone suppresses spermatogenesis in juvenile spermatogonial depletion (*jsd*) mice. Biol. Reprod., 65: 532-537.
30. Plant, T.M., 2008. Hypothalamic control of the pituitary-gonadal axis in higher primates: Key advances over the last two decades. J. Neuroendocrinol., 20: 719-726.
31. Chang, C., 2002. Androgens and Androgen Receptor: Mechanisms, Functions and Clinical Applications. 1st Edn., Springer, New York, USA., ISBN: 978-1-4615-1161-8, Pages: 503.
32. Welsh, M., R.M. Sharpe, L. Moffat, N. Atanassova and P.T. Saunders *et al*., 2010. Androgen action via testicular arteriole smooth muscle cells is important for Leydig cell function, vasomotion and testicular fluid dynamics. PLoS ONE, Vol. 5. 10.1371/journal.pone.0013632
33. Abdou, H.S., S.H. Salah, H.F. Booles and E.A. Abdel Rahim, 2012. Effect of pomegranate pretreatment on genotoxicity and hepatotoxicity induced by carbon tetrachloride (CCl_4) in male rats. J. Med. Plants Res., 6: 3370-3380.
34. Khan, R.A., M.R. Khan, M. Ahmed, S. Sahreen and N.A. Shah, 2012. Protective effects of *Launaea procumbens* on rat testis damage by CCl_4. Lipids Health Dis., Vol. 11, 10.1186/1476-511X-11-103
35. Yuce, A., G. Turk, S. Ceribasi, M. Guvenc and M. Ciftci *et al*., 2014. Effectiveness of cinnamon (*Cinnamomum zeylanicum*) bark oil in the prevention of carbon tetrachloride-induced damages on the male reproductive system. Andrologia, 46: 263-272.
36. Sonmez, M., G. Turk, S. Ceribasi, M. Ciftci and A. Yuce *et al*., 2014. Quercetin attenuates carbon tetrachloride-induced testicular damage in rats. Andrologia, 46: 848-858.
37. Rajesh, M.G. and M.S. Latha, 2004. Protective activity of *Glycyrrhiza glabra* Linn. On carbon tetrachloride-induced peroxidative damage. Indian J. Pharmacol., 305: 284-287.
38. Moretti, E., L. Mazzi, G. Terzuoli, C. Bonechi and F. Iacoponi *et al*., 2012. Effect of quercetin, rutin, naringenin and epicatechin on lipid peroxidation induced in human sperm. Reprod. Toxicol., 34: 651-657.
39. Zribi, N., N.F. Chakroun, F.B. Abdallah, H. Elleuch and A. Sellami *et al*., 2012. Effect of freezing-thawing process and quercetin on human sperm survival and DNA integrity. Cryobiology, 65: 326-331.
40. Kanter, M., C. Aktas and M. Erboga, 2012. Protective effects of quercetin against apoptosis and oxidative stress in streptozotocin-induced diabetic rat testis. Food Chem. Toxicol., 50: 719-725.

41. Zacharias, B.T., J.C.U. Coelho, M.B. Parolin, J.E.F. Matias, A.C.T. de Freitas and J.L. de Godoy, 2014. Hypothalamic-pituitary-gonadal function in men with liver cirrhosis before and after liver transplantation. Revista Colegio Brasileiro Cirurgioes, 41: 421-425.
42. Mehraban, F., M. Jafari, M.A. Toori, H. Sadeghi, B. Joodi, M. Mostafazade and H. Sadeghi, 2014. Effects of date palm pollen (*Phoenix dactylifera* L.) and *Astragalus ovinus* on sperm parameters and sex hormones in adult male rats. Iran. J. Reprod. Med., 12: 705-712.
43. Li, H., K. Palczewski, W. Baehr and M. Clagett-Dame, 2011. Vitamin A deficiency results in meiotic failure and accumulation of undifferentiated spermatogonia in prepubertal mouse testis. Biol. Reprod., 84: 336-341.
44. Eustache, F., F. Mondon, M.C. Canivenc-Lavier, C. Lesaffre and Y. Fulla *et al*., 2009. Chronic dietary exposure to a low-dose mixture of genistein and vinclozolin modifies the reproductive axis, testis transcriptome and fertility. Environ. Health Perspect., 117: 1272-1279.
45. Jana, K., P.K. Samanta, I. Manna, P. Ghosh, N. Singh, R.P. Khetan and B.R. Ray, 2008. Protective effect of sodium selenite and zinc sulfate on intensive swimming-induced testicular gamatogenic and steroidogenic disorders in mature male rats. Applied Physiol. Nutr. Metab., 33: 903-914.
46. Shariati, M., E. Sharifi and M. Kaveh, 2007. The effect of *Phoenix dactylifera* (date-palm) pit powder on testosterone level and germ cells in adult male rats. J. Zanjan Univ. Med. Sci. Health Serv., 15: 21-28.