



International Journal of Pharmacology

ISSN 1811-7775

science
alert

ansinet
Asian Network for Scientific Information



Research Article

Protective Effect of Ginsenoside Rg1 Against Ethanol-Induced Male Infertility in Sprague-Dawley Rats

¹Zhenzhen Jin, ¹Min Zhang, ¹Aijun Yang, ²Yafei Shi, ¹Huanfu Niu, ¹Qin Wang, ¹Chunna Yu, ¹Zefeng Wei and ¹Xuenan Wang

¹Department of Reproductive Medicine, Affiliated Hospital of Jining Medical University, Guhuai Road 89, 272029 Jining, Shandong, People's Republic of China

²Department of Breast and Thyroid Surgery, Affiliated Hospital of Jining Medical University, Guhuai Road 89, 272029 Jining, Shandong, People's Republic of China

Abstract

Background and Objective: Ginsenoside Rg1 (GRg1) is the most abundant and active steroid saponin of *Panax notoginseng* with several pharmaceutical properties. The present study was undertaken to evaluate the effect of ginsenoside Rg1 (GRg1) on ethanol-induced male infertility in rat model. **Materials and Methods:** Thirty-two male rats were divided into four groups. One group (control) received saline (2 mL/day), while another group was given ethanol (EtOH, 4 g kg⁻¹ b.wt./day). One treatment group received 20 mg GR1 kg⁻¹ b.wt./day, while another treatment group was given 40 mg GR1 kg⁻¹ b.wt./day. Both treatment groups were also given 4 g EtOH kg⁻¹ b.wt./day. All treatment were given orally for 28 days. The significant differences between the groups were determined using one-way ANOVA and data were analyzed using SPSS software followed by Tukey's test. **Results:** The weights of epididymis, testis and seminal vesicles, as well as testicular sperm count, viability, motility and serum testosterone levels were significantly elevated ($p < 0.01$) by exposure to GRg1 at each of the two doses (20 and 40 mg kg⁻¹ b.wt./day), when compared to the EtOH-treated groups. The two doses of GRg1 also led to significant ($p < 0.01$) increases in the activities of testicular antioxidant enzymes (SOD, CAT) and the steroidogenic enzymes 3 β hydroxy steroid dehydrogenase (3 β HSD) and 17 β hydroxy steroid dehydrogenase (17 β HSD), as well as lower levels of MDA. Histomorphological lesions such as thickening of seminiferous tubules and disintegration of leydig and sertoli cells were ameliorated by both doses of GRg1. However, 40 mg kg⁻¹ GRg1 showed better anti-infertility effect. **Conclusion:** Co-administration of ethanol and 40 mg kg⁻¹ GRg1 to rats produced anti-infertility effects by suppressing alcohol-induced sperm oxidative stress and testicular toxicity.

Key words: Ethanol, ginsenoside Rg1, testosterone, leydig cells, steroidogenic enzymes, anti-infertility

Received: July 07, 2017

Accepted: October 13, 2017

Published: April 15, 2018

Citation: Zhenzhen Jin, Min Zhang, Aijun Yang, Huanfu Niu, Qin Wang, Chunna Yu, Zefeng Wei and Xuenan Wang, 2018. Protective effect of ginsenoside Rg1 against ethanol-induced male infertility in sprague-dawley rats. Int. J. Pharmacol., 14: 513-521.

Corresponding Author: Xuenan Wang, Department of Reproductive Medicine, Affiliated Hospital of Jining Medical University, Guhuai Road 89, 272029 Jining, Shandong, People's Republic of China Tel/Fax: +86 537 290 3399

Copyright: © 2018 Zhenzhen Jin *et al.* This is an open access article distributed under the terms of the creative commons attribution License, which permits unrestricted use, distribution and reproduction in any medium, provided the original author and source are credited.

Competing Interest: The authors have declared that no competing interest exists.

Data Availability: All relevant data are within the paper and its supporting information files.

INTRODUCTION

Infertility is a major health issue that affects nearly 15% of couples worldwide¹. The prevalence rate of male infertility in China has increased enormously in recent times². Almost 50% of infertility cases are due to male factors such as genetic disorder (hormonal imbalance), infection, duct obstruction, cryptorchidism, trauma or oxidative stress, excessive smoking and alcohol intake^{3,4}. Several scientists have pointed out that long term or short term consumption of alcohol could alter the metabolic pattern and morphology of testes (testicular atrophy) and thus results in low sperm count and infertility^{5,6}. Hence, in the present study, an ethanol-induced animal infertility model was used.

Synthetic drugs like Clomid, Letrozole and Imipramine are currently recommended for treating male infertility after a surgical procedure. However, prolonged intake of these synthetic drugs might lead to severe adverse effects⁵. Therefore, many researchers are focusing on using complementary and alternative medicines especially plant-derived products to treat infertility due to lower cost and fewer adverse effects⁷.

Panax notoginseng (*P. notoginseng*) or *Korean ginseng* or *Chinese ginseng* (C. A. Meyer; *Araliaceae*) is a popular herbal medicine used all over the world for its various biological properties⁸. The roots of ginseng are extensively used in Asian traditional medicine for many years to treat various disorders or dysfunction especially for sexual dysfunction^{9,10}. The major active phytochemical components of *P. ginseng* are ginsenosides (tetracyclic triterpenoid saponins). However, only six major ginsenosides (Rb1, Rb2, Rd, Rc, Rg1 and Re) are extensively used¹¹. Among those ginsenosides, GRg1 is the most abundant and active steroid saponin that has a similar structural identity with several sex hormones¹². It has been shown that GRg1 possesses antioxidant, anti-inflammatory and anti-cancer properties^{13,14}. In addition, GRg1 has been reported to exhibit neuroprotective, immunoprotective, cardioprotective and hepatoprotective properties^{12,15,16}.

Previously, ginseng has shown to possess anti-infertility or male gonad protective activity in animals models as well as in human^{10,17,18}. Ginsenosides have also been reported to enhance sperm production and sperm motility in various *in vitro* models^{19,20}. However, till date, no *in vivo* studies have been conducted to investigate the anti-infertility effect of GRg1 against ethanol-induced testicular damage or male infertility. Therefore, the present research was carried out to study the anti-infertility effect of GRg1 by assessing sperm count, sperm viability, sperm motility, antioxidant status, steroidogenic enzymes and associated histological changes in a rat model of ethanol-induced infertility.

MATERIALS AND METHODS

Chemicals: GRg1 (CAS No: 22427-39-0), Triton X 100, ethanol (95%), eosin and nigrosine stain (100 mL); Tris buffer solution (10X), nicotinamide adenine dinucleotide (NAD; CAS No: 53-84-9), nicotinamide adenine dinucleotide phosphate hydrate (NADPH; CAS No: 53-59-8), dehydroepiandrosterone (CAS No: 53-43-0) and androstenedione (CAS No: 63-05-8) were bought from Sigma-Aldrich (St. Louis, MO, USA). Xylene (CAS No: 1330-20-7), formalin (CAS No: 50-00-0), paraffin wax (10%), hematoxylin and eosin (H and E), physiological saline (0.9%) and hydrogen peroxide (CAS No: 7722-84-1) were purchased from Beijing Zhongshan Golden Bridge Biotechnology Co. Ltd, (Beijing City, Beijing, China).

Experimental animals: Male adult healthy Wistar strain albino rats weighing 260-280 g were used for this study. All the rats were maintained in steel rat cages (4 rats in each cage) under a 12/12 light/dark cycle at 22°C with 72-74% humidity. They were allowed free access to water and food (*ad libitum*) and acclimatized to the experimental environment for 2 weeks before the study. This pre-clinical (animal) study was conducted from January 2016-March, 2016 with approved from the Ethical Committee of Affiliated Hospital of Jining Medical University (JMU2017-372). The experimental protocols and procedures were done under controlled conditions in accordance with the guidelines proposed by NIH (USA).

Study design: Thirty-two healthy male adult Wistar albino rats were randomly chosen after 2 weeks of acclimatization period and divided into four groups, each with eight rats. Rats in the control group received only saline (2 mL/day) orally for 28 days (group I). Group II rats were given EtOH at a dose of 4 g kg⁻¹ b.wt./day orally for 28 days. Groups III and IV rats (treatment groups) received orally 20 mg GRg1 and 40 mg GRg1 kg⁻¹ b.wt./day, respectively, in addition to 4 g EtOH kg⁻¹ b.wt./day, for 28 days. The GRg1 was dissolved in normal saline prior to administration.

Sample collection: At the end of the experimental period (day 29), all rats were weighed and sacrificed by cervical dislocation under diethyl ether anesthesia. Blood samples were collected through cardiac puncture and centrifuged at 3000 rpm for 10 min to obtain sera. The testes, cauda epididymis and seminal vesicles were excised immediately and weighed. The left testes were de-capsulated and 10% homogenate of the parenchyma was prepared in physiological saline containing Triton X100 solution. The homogenate was centrifuged (Eppendorf-5810 centrifuge; Hamburg, Germany) at 3000 rpm for 10 min at 4°C and the

resultant clear supernatant was used for assay of testicular antioxidants and lipid peroxidation products. The microsomal fraction of testis was prepared using differential centrifugation technique according to the method of Himabindu *et al.*²¹ and used for assaying the steroidogenic enzymes, 3 β HSD and 17 β HSD. Protein content was estimated by BCA protein kit (Sigma; St. Louis, MO, USA).

Semen analysis: Sperm count was carried out by the method of Yokoi *et al.*²². Caudal epididymis (distal end) was isolated immediately after rat sacrifice, minced in physiological saline and thoroughly shaken using an agitator for 10 min at 37°C to separate (swim out) the spermatozoa (sperm) from the epididymal tubules. The sperm suspension (10 μ L) was transferred onto each chamber of a hemocytometer and counted under a Nikon Eclipse 80i light microscope (Nikon, Co., Tokyo city, Tokyo, Japan). Sperm count was expressed as million mL⁻¹. Sperm viability test was carried out by the method of Wyrobek *et al.*²³, with slight modifications. In essence, 20 μ L of diluted sperm suspension was mixed with 20 μ L of eosin and nigrosine stain to detect viable sperm. Viable sperm was expressed as percentage (%) of the total sperm count using Nikon Eclipse 80i light microscope (Nikon, Co., Tokyo city, Tokyo, Japan). In this test, live sperm was unstained (colorless) but dead sperm was stained pink. Sperm motility was assessed by Sonmez *et al.*²⁴, method. About 500 μ L of sperm suspension was added to 2 mL of Tris-buffered solution. The percentage of sperm motility was determined microscopically within 3-4 min using Nikon Eclipse 80i light microscope (Nikon, Co., Tokyo city, Tokyo, Japan). Sperm motility was calculated as a percentage of motile sperms relative to the total sperm count.

Lipid peroxidation, antioxidants and steroid hormone: Levels of malondialdehyde (MDA) and the activities of superoxide dismutase (SOD) and catalase (CAT) were assayed in testicular tissue using a commercial kit (Nanjing Jiancheng Bioengineering Institute (Nanjing City, Nanjing, China). Serum testosterone was quantified by enzyme-linked immunosorbent assay (ELISA) kit from Cayman Chemicals (Ann Arbor, MI, USA) based on the manufacturer's protocol.

Steroidogenic enzymes: The activities of 3 β -HSD and 17 β -HSD were assayed in the testicular microsomal fraction by the method of Bergmeyer²⁵. In brief, 2 mL of the reaction mixture containing 0.5 μ mol of cofactors like NAD (3 β -HSD) or NADPH (17 β -HSD), 100 μ mol of sodium pyrophosphate buffer (pH 7.4), 0.10 μ mol of substrate (dehydro-epiandrosterone for 3 β -HSD; or androstenedione for 17 β -HSD) to this 100 μ L of sample were added. The absorbance was measured at

340 nm at 20 sec intervals for 3 min using UV-Vis spectrophotometer-2600 (Shimadzu, Kyoto city, Kyoto, Japan). The enzyme activity was expressed as nmol of NAD converted to NADH/mg protein/min (3 β -HSD) or nmol of NADPH converted to NADP/mg protein/min (17 β -HSD)002E.

Histological evaluation: The testis were removed immediately after sacrifice and a portion were fixed with Bouin's solution and then with 4% buffered formalin solution (phosphate buffer) for 12 h at 37°C. They were thereafter dehydrated through upgraded ethanol, cleared with xylene. and embedded in paraffin wax (sectioning purpose) to make fine 5 μ m diameter tissue slices using ultra-microtome (Cryo Leica EM, Leica Microsystem Inc., Buffalo, IL, USA). The tissue slices were mounted onto a microscopic slide followed by staining with H and E stain for 10 h at 37°C. They were examined under the microscope (magnification 200X) and photographed with a high-resolution digital camera attached to Nikon Eclipse 80i light microscope (Nikon, Co., Tokyo city, Tokyo, Japan) and examined by Image Pro-Plus software (6.1 ver) from Media Cybernetics (Rockville, MD, USA) for evidence of testicular lesions.

Statistical analysis: Data are expressed as the Mean \pm Standard Deviation (SD). The significant differences between the groups were determined using one-way ANOVA, followed by Tukey's test (for multi comparison) with the aid of SPSS software (Ver 23; IBM Corp., NY, USA). Differences were considered statistically significant at $p < 0.05$ ²⁶.

RESULTS

Effect of GRg1 on body weight and reproductive tissues: The effect of GRg1 on body weight and reproductive tissues in experimental rats are represented in Table 1. No significant changes were noted in body weight gain in any of the experimental group. However, the weights of epididymis, testes and seminal vesicles were considerably ($p < 0.01$) reduced in the EtOH-treated rats. The decreases in weights of epididymis, testes and seminal vesicles were significantly reversed by co-treatment with GRg1 at both doses ($p < 0.05$ for 20 mg GRg1 and $p < 0.01$ for 40 mg GRg1).

Effect of GRg1 on sperm characterization: The effect of GRg1 on sperm characterization (sperm count, motility and viability) in experimental rats were shown in Table 2. Sperm count (78.15 down to 41.67 million mL⁻¹), viability (85.44 down to 66.87%) and motility (79.13 down to 60.21%) were significantly ($p < 0.01$) lowered in the EtOH-intoxicated rats when compared with control rats. In the groups

Table 1: Effect of GRg1 on body weight and reproductive tissues in experimental rats

Group	Body weight (g)	Testis (g)	Cauda epididymis (g)	Seminal vesicle (g)
Control	269.44±22.93	1.95±0.11	0.38±0.04	0.41±0.04
EtOH induced	272.35±29.18	1.03±0.16 ^{a***}	0.21±0.02 ^{a***}	0.24±0.03 ^{a***}
GRg1 20+EtOH	270.92±31.14	1.46±0.12 ^{b*}	0.29±0.02 ^{b*}	0.31±0.03 ^{b*}
GRg1 40+EtOH	274.78±37.92	1.81±0.21 ^{b**}	0.36±0.03 ^{b**}	0.39±0.04 ^{b**}

Data are expressed as the Means±Standard Deviation (SD). **p<0.01, *p<0.05, (a) EtOH group compared with the control group, (b) GRg1 treated groups (20 and 40)+EtOH compared with EtOH alone group

Table 2: Effect of GRg1 on sperm characterization (Sperm count/viability and motility) in experimental rats

Group	Sperm count (Millions mL ⁻¹)	Viable sperm (%)	Motile sperm (%)
Control	78.15±8.03	85.44±5.18	79.13±9.82
EtOH induced	41.67±6.10 ^{a***}	66.87±6.79 ^{a**}	60.21±0.02 ^{a**}
GRg1 20+EtOH	62.56±9.19 ^{b**}	74.46±8.21 ^{b*}	68.80±8.52 ^{b**}
GRg1 40+EtOH	74.77±10.98 ^{b**}	82.65±10.08 ^{b**}	76.34±10.26 ^{b**}

Data are expressed as the Means±Standard Deviation (SD). **p<0.01, *p<0.05, (a) EtOH group compared with the control group. (b) GRg1 treated groups (20 and 40)+EtOH compared with EtOH alone group

Table 3: Effect of GRg1 on testicular antioxidant activities and lipid peroxidation products in experimental rats

Group	SOD (U mg ⁻¹ ptn)	CAT (U mg ⁻¹ ptn)	MDA (µmol mg ⁻¹ ptn)
Control	3.98±0.44	62.53±10.51	0.69±0.05
EtOH induced	2.48±0.29 ^{a***}	38.10±4.10 ^{a***}	1.24±0.13 ^{a**}
GRg1 20+EtOH	3.20±0.55 ^{b**}	47.05±5.92 ^{b*}	0.88±0.09 ^{b**}
GRg1 40+EtOH	3.67±0.46 ^{b**}	58.73±6.40 ^{b**}	0.76±0.11 ^{b**}

Data are expressed as the Means±Standard Deviation (SD). **p<0.01, *p<0.05, EtOH group compared with the control group. (b) GRg1 treated groups (20 and 40)+EtOH compared with EtOH alone group, One unit (U) of SOD activity was equal to the amount of enzyme that required for inhibiting 50% of xanthine-xanthine oxidase. One U of CAT activity was equal to the amount of enzyme that required to decompose 1 µmol of H₂O₂ sec⁻¹

Table 4: Effect of GRg1 on testicular steroidogenic enzymes in experimental rats

Group	3β-HSD	17β-HSD
Control	18.56±1.94	14.03±2.15
EtOH induced	11.72±1.49 ^{a***}	7.73±1.82 ^{a***}
GRg1 20+EtOH	14.43±2.11 ^{b*}	10.94±1.04 ^{b*}
GRg1 40+EtOH	17.25±2.07 ^{b**}	13.89±1.65 ^{b**}

Data are expressed as the Means±Standard Deviation (SD). **p<0.01, *p<0.05, EtOH group compared with the control group. (b) GRg1 treated groups (20 and 40)+EtOH compared with EtOH alone group 3,β-HSD was expressed as nmol of NAD converted to NADH mg⁻¹ protein min⁻¹. 17β-HSD was expressed as nmol of NADPH converted to NADP mg⁻¹ protein min⁻¹

where EtOH was co-administered with 20 and 40 mg GRg1 kg⁻¹ b.wt./day, there were significant increases (p<0.01) in sperm count (62.56 and 74.77 million mL⁻¹), viability (74.46 and 82.65%) and motility (68.80 and 76.34 %), respectively, relative to those of EtOH-treated rats.

Effect of GRg1 on testicular antioxidant activities: The effects of GRg1 on testicular antioxidant status and MDA are shown on Table 3. Compared with saline-treated rats (control), MDA levels were significantly elevated (p<0.01), while the activities of the antioxidant enzymes SOD and CAT were significantly decreased (p<0.01) in EtOH-exposed rats. However, co-administration of 20 or 40 mg GRg1+EtOH for 28 days markedly reversed (p<0.01) the toxic effect of ethanol by lowering MDA levels and raising the activities of SOD and CAT.

Effect of GRg1 on testicular steroidogenic enzymes: The effect of GRg1 on testicular steroidogenic enzymes in

experimental rats were epitomized in Table 4. The activities of 3β HSD and 17β HSD were significantly decreased (p<0.01) in the EtOH-treated rats (by 57 and 49%, respectively) when compared with control rats. Co-administration of EtOH and GRg1 at 20 and 40 mg kg⁻¹ significantly increased the activities of 3β HSD and 17β HSD (p<0.05 for 20 mg GRg1; p<0.01 for 40 mg GRg1).

Effect of GRg1 on serum testosterone concentration: Serum testosterone concentration was significantly reduced (p<0.01) in the EtOH group (2.65-1.23 ng mL⁻¹; Fig. 1). However, pronounced increases in serum testosterone were seen in the rats co-administered EtOH and GRg1 (from 1.23-2.02 ng mL⁻¹ for 20 mg GRg1; p<0.05 and from 1.23-2.49 ng mL⁻¹ for 40 ng GRg1; p<0.01).

Effect of GRg1 on histology of testes: The photomicrographs represent H and E stained sections of testes from control and treatment rats (Fig. 2). Testicular sections of control rats

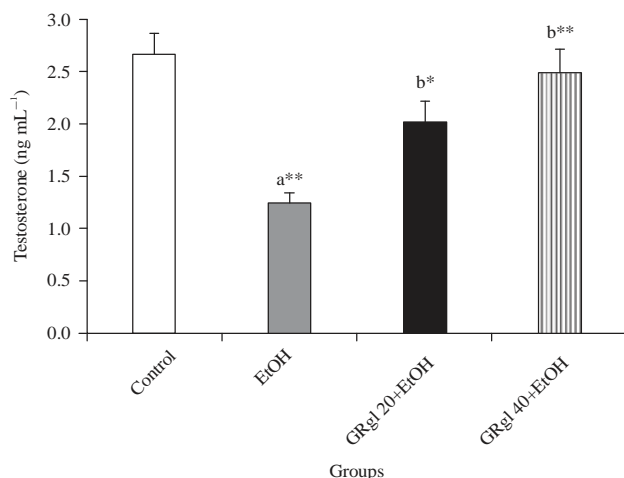


Fig. 1: Effect of GRg1 on serum testosterone concentration in experimental rats

¹Data are expressed as the Means \pm Standard Deviation (SD). ** $p < 0.01$, * $p < 0.05$ (a) EtOH group compared with the control group, (b) GRg1 treated groups (20 and 40) +EtOH compared with EtOH alone group

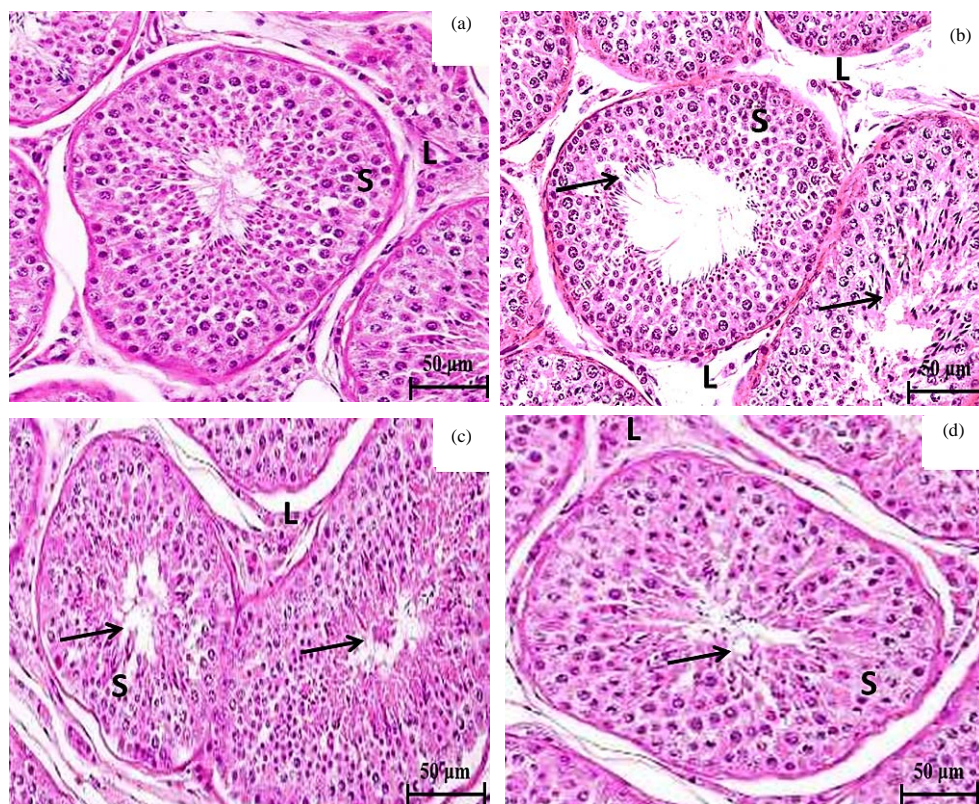


Fig. 2(a-d): H and E stained testis section of control and experimental rats (200), (a) Testicular sections of control rats showing normal architecture of seminiferous tubules with matured Sertoli cells (S) and Leydig cells (L), (b) Testicular section of EtOH-exposed rats displaying thickened seminiferous tubules with many disrupted spermatogonia (arrow mark). In addition, many necrotized Sertoli cells (S) and disintegrated interstitial Leydig cells (L) are evident, (c) GRg1 20 treated group showing mild thickened seminiferous tubules with moderate number of spermatogonia along with less altered Sertoli and Leydig cells and (d) GRg1 40 treated rats showing normal seminiferous tubules with a significant number of spermatogonia (arrow mark) along with prominent Sertoli and Leydig cells

showed normal architecture of seminiferous tubules lined with complete sets of spermatogenic series (spermatogonia, spermatocytes and spermatozoa). In addition, mature Sertoli cells (S) with well-developed interstitial Leydig cells (L) (Fig. 2a) were seen. In contrast, testicular section of the EtOH-exposed rats displayed thickened seminiferous tubules with many disrupted or degenerated spermatogonia as well as dead or elongated spermatid (arrowed). In addition, many necrotized Sertoli cells (S) and disintegrated interstitial Leydig cells (L) were seen (Fig. 2b). The 20 mg GRg1-treated group (Fig. 2c) showed mildly thickened seminiferous tubules with a moderate increase in the number of spermatogonia (arrowed). In the 40 mg GRg1-treated rats (Fig. 2d), normal seminiferous tubules with a significant number of spermatogonia (arrow mark) and prominent Sertoli and Leydig cells were seen.

DISCUSSION

A growing body of evidence has demonstrated that steroidal constituents like phytoestrogen or saponins found in the plants possess anti-fertility or aphrodisiac properties, due to the fact that they mimics several sex hormones^{27,28}. Therefore, for the current study, a popular phytocomponent like GRg1 was used to assess the anti-infertility activity by checking epididymis sperm count, viability, motility, antioxidant status, steroidogenic enzymes and histological changes in the ethanol-induced animal model.

No significant changes were noted in body weight gain in any of the experimental groups. However, the weight of epididymis, testis and seminal vesicles were significantly decreased $p < 0.05$ in EtOH-induced rats. This can be attributed to the EtOH-induced attenuation of the functions of the Leydig and germ cells (testicular atrophy), leading to decreased testosterone concentration²⁹. Co-treatment with GRg1 considerably improved the weight of epididymis, testes and seminal vesicles. A similar outcome was reported by Jang and his coworkers, who observed increases in the weights epididymis, testes and seminal vesicles due to treatment with saponins (ginsenosides) of *P. ginseng*, owing to increased secretion of testosterone¹⁰.

Semen analysis (sperm characteristic) is a pivotal procedure to check the anti-fertility property of any drug. Sperm count, sperm viability and sperm motility were reduced in the EtOH-intoxicated rats, probably due to excessive free radical generation (oxidative stress). This is so because alcohol consumption reduces sperm count, sperm viability and sperm motility owing to increased oxidative stress³⁰. The rats co-administered EtOH and GRg1 for 28 days had significant

elevations in count, viability and motility of sperm when compared with rats given EtOH alone. Another *in vitro* study also reported that treatment with GRg1 considerably increased the motility and integrity (viability) of post-thawed miniature pig sperm¹⁹.

Ample amount of reports indicated that overproduction of free radicals (ROS) and subsequent oxidative stress are considered as the major etiological factors for ethanol-induced testicular changes and eventually results in infertility^{3,31}. Testes and sperm are highly susceptible to ethanol-induced damage owing to overproduction of free radicals. Sperm contains a high concentration of polyunsaturated fatty acids (PUFA) and abundant endogenous antioxidant enzymes and its high metabolic rate and replicating properties make it highly vulnerable to lipid peroxidation-induced damage⁴.

Levels of MDA were significantly elevated $p < 0.05$ while SOD and CAT were considerably decreased in the EtOH-exposed rats. These results are in agreement with the results of Akbari and his colleagues, who also indicated that consumption of ethanol could significantly lower the activities of antioxidants like SOD and CAT while raising MDA production³². However, administration with either 20 or 40 mg of GRg1 could significantly lower $p < 0.05$ the MDA levels with increased activities of SOD and CAT. Korivi *et al.*¹² hinted that treatment with GRg1 could substantially improve the activities of SOD and CAT with lowered MDA levels against exercise-induced oxidative stress in the rat¹². In addition, it has been reported that administration of GRg1 significantly upregulated the protein expression of nuclear factor Nrf2 which modulates the expression of endogenous antioxidants such as SOD and CAT¹⁶. Hence, it can be hypothesized that as a protective mechanism, GRg1 could up-regulate Nrf2-related signaling pathway, thereby enhancing the production of testicular SOD and CAT in EtOH intoxicated rats. However, further studies are required to confirm the above statement.

The rate of limiting enzymes in the steroidogenic pathway are 3β HSD and 17β HSD. These enzymes play pivotal roles in the production of 4-Androstenedione from dehydroepiandrosterone and in the production of testosterone from 4-Androstenedione^{33,34}. The activities of 3β HSD and 17β HSD were significantly decreased $p < 0.05$ in EtOH-induced rats due to elevated oxidative stress. Balamurugan and his co-workers have demonstrated that consumption of ethanol could significantly decrease the activities of 3β HSD and 17β HSD owing to excessive free radical generation, thereby reducing the production of testosterone²⁷. Supplementation of EtOH with either GRg1 20 or 40 could markedly improve the activities of HSD both 3β HSD and 17β HSD owing its antioxidative property.

Testosterone is an essential male sex hormone used to maintain and control the action of various male accessory sex gland function particularly testes and epididymis to favor spermatogenesis¹⁰. The serum testosterone concentration was significantly suppressed in EtOH group due to reduced testicular cholesterol production and toxic effect of EtOH on the Hypothalamus-Pituitary-Gonadal (HPG) axis³⁵. A pronounced increase in the concentration of testosterone were noted in GRg1 (20 or 40) supplemented rats. These effects are due to modulation of HPG axis by the neuroprotective property of GRg1, as well as its ability to up-regulate the expression of 3β HSD and 17β HSD. Previously, Wang and his co-workers reported that consumption of GRg1 significantly increased the concentration of serum testosterone in a rat model³⁶.

Testicular sections of control rats showed the normal architecture of seminiferous tubules lined with complete sets of spermatogenic series (stages of maturation) like spermatogonia, spermatocytes and spermatozoa, in addition to mature Sertoli cells (S) with well-developed interstitial Leydig cells (L). However, testicular section of the EtOH-exposed rats displayed thickened seminiferous tubules with many disrupted or degenerated spermatogonia. In addition, many necrotized Sertoli cells (S) and disintegrated interstitial Leydig cells (L) were present. Similar abnormalities in testicular tissue of alcohol intoxicated animals have been reported previously³⁷. The lesions due to EtOH treatment were reversed by GRg1, resulting in normal seminiferous tubules with a significant number of spermatogonia along with prominent Sertoli and Leydig cells. Thus, GRg1 exerted protective effect against toxic assault imposed by ethanol in testicular tissue. Recently, a study conducted by Omar and Abdalhafid found that treatment with *Panax ginseng* (150 or 300 mg kg⁻¹) produced improved seminiferous tubules with increased concentration of spermatozoa³⁸.

CONCLUSION

Taking together, supplementation of both GRg1 20 and 40 displayed significant anti-infertility or spermatogenesis effect by enhancing gonads weight, sperm count, motility, viability and antioxidant status (lowering MDA) and steroidogenic enzymes and testosterone levels as well as improving the testicular morphology on EtOH-intoxicated rats. However, GRg1 40 showed better anti-infertility activity than GRg1 20.

SIGNIFICANCE STATEMENTS

This experiment discovers the new anti-infertility agent (GRg1) which can be recommended for treating ethanol

induced infertility with other standard fertility agents. The outcome of this animal study would help the researcher to discover new novel anti-infertility drug and thus help to improve the quality of infertility couples.

ACKNOWLEDGMENT

This study was supported by Jining Science and Technology development program (Project No. JIKEZ[2015]57-121) and Natural Science Foundation Projects of Shandong Province (No. ZR2013HL013).

REFERENCES

1. Rasekhjahromi, A., M. Maalhigh, F. Alipour, M. Hosseinpoor and S. Sobhanian, 2015. Assessing an optimal regimen in treatment of infertility (clomiphene citrate, tamoxifen and vit. E Versus Estrogen, Letrozole and Tamoxifen): A double blind control trial. *Int. J. Pharmacol.*, 11: 377-381.
2. Meng, Q., A. Ren, L. Zhang, J. Liu and Z. Li *et al.*, 2015. Incidence of infertility and risk factors of impaired fecundity among newly married couples in a Chinese population. *Reprod. Biomed. Online*, 30: 92-100.
3. Gaur, D.S., M.S. Talekar and V.P. Pathak, 2010. Alcohol intake and cigarette smoking: Impact of two major lifestyle factors on male fertility. *Indian J. Pathol. Microbiol.*, 53: 35-40.
4. Olayemi, F.O., 2010. Review on some causes of male infertility. *Afr. J. Biotechnol.*, 9: 2834-2842.
5. Akomolafe, S.F., G. Oboh, A.A. Akindahunsi and A.J. Afolayan, 2017. Ethanol-induced male infertility: Effects of aqueous leaf extract of *Tetracarpidium conophorum*. *Andrologia*, 10.1111/and.12759.
6. Talebi, A.R., A.A. Sarcheshmeh, M.A. Khalili and N. Tabibnejad, 2011. Effects of ethanol consumption on chromatin condensation and DNA integrity of epididymal spermatozoa in rat. *Alcohol*, 45: 403-409.
7. Mohammadi, F., H. Nikzad, A. Taherian, J.A. Mahabadi and M. Salehi, 2013. Effects of herbal medicine on male infertility. *Anatom. Sci. J.*, 10: 3-16.
8. Hassan, A.M. and MA. Abdel-Wahhab, 2006. Antioxidant effect of parsley oil and *Panax ginseng* extract standardized with ginsenosides Rg3 against alteration induced in reproductive functions in male mice. *Egypt. J. Hospit. Med.*, 22: 60-72.
9. Hong, B., Y.H. Ji, J.H. Hong, K.I.Y. Nam and T.Y. Ahn, 2002. A double-blind crossover study evaluating the efficacy of korean red ginseng in patients with erectile dysfunction: A preliminary report. *J. Urol.*, 168: 2070-2073.
10. Jang, D.J., M.S. Lee, B.C. Shin, Y.C. Lee and E. Ernst, 2008. Red ginseng for treating erectile dysfunction: A systematic review. *Br. J. Clin. Pharmacol.*, 66: 444-450.

11. Hu, J.N., J.H. Lee, J.A. Shin, J.E. Choi and K.T. Lee, 2008. Determination of ginsenosides content in Korean ginseng seeds and roots by high performance liquid chromatography. *Food Sci. Biotechnol.*, 17: 430-433.
12. Korivi, M., C.W. Hou, C.Y. Huang, S.D. Lee and M.F. Hsu *et al.*, 2012. Ginsenoside-Rg1 protects the liver against exhaustive exercise-induced oxidative stress in rats. *Evidence-Based Complement. Altern. Med.*, 10.1155/2012/932165.
13. Xie, C.L., W.W. Wang, X.D. Xue, S.F. Zhang, J. Gan and Z.G. Liu, 2015. A systematic review and meta-analysis of Ginsenoside-Rg1 (G-Rg1) in experimental ischemic stroke. *Scient. Rep.*, Vol. 5. 10.1038/srep07790.
14. Song, Y., F. Zhao, L. Zhang, Y. Du, T. Wang and F. Fu, 2013. Ginsenoside Rg1 exerts synergistic anti-inflammatory effects with low doses of glucocorticoids *in vitro*. *Fitoterapia*, 91: 173-179.
15. Zhu, D., L. Wu, C.R. Li, X.W. Wang and Y.J. Ma *et al.*, 2009. Ginsenoside Rg1 protects rat cardiomyocyte from hypoxia/reoxygenation oxidative injury via antioxidant and intracellular calcium homeostasis. *J. Cell. Biochem.*, 108: 117-124.
16. Li, J.P., Y. Gao, S.F. Chu, Z. Zhang and C.Y. Xia *et al.*, 2014. Nrf2 pathway activation contributes to anti-fibrosis effects of ginsenoside Rg1 in a rat model of alcohol-and CCl₄-induced hepatic fibrosis. *Acta Pharmacol. Sin.*, 35: 1031-1044.
17. Yang, W.M., S.Y. Park, H.M. Kim, E.H. Park, S.K. Park and M.S. Chang, 2011. Effects of *Panax ginseng* on glial cell derived neurotrophic factor (GDNF) expression and spermatogenesis in rats. *Phytother. Res.*, 25: 308-311.
18. Kopalli, S.R., S.Y. Hwang, Y.J. Won, S.W. Kim and K.M. Cha *et al.*, 2015. Korean red ginseng extract rejuvenates testicular ineffectiveness and sperm maturation process in aged rats by regulating redox proteins and oxidative defense mechanisms. *Exp. Gerontol.*, 69: 94-102.
19. Kim, D.Y. and Y.J. Hwang, 2013. Effects of Ginsenoside-Rg1 on post-thawed miniature pig sperm motility, mitochondria activity and membrane integrity. *J. Embryo Transfer*, 28: 63-71.
20. Chen, J.C., L.D. Chen, W. Tsauer, C.C. Tsai, B.C. Chen and Y.J. Chen, 2001. Effects of Ginsenoside Rb2 and Rc on inferior human sperm motility *in vitro*. *Am. J. Chinese Med.*, 29: 155-160.
21. Himabindu, B., P. Madhu and P.S. Reddy, 2015. Diabetes and alcohol: Double jeopardy with regard to oxidative toxicity and sexual dysfunction in adult male Wistar rats. *Reprod. Toxicol.*, 51: 57-63.
22. Yokoi, K., E.O. Uthus and F.H. Nielsen, 2003. Nickel deficiency diminishes sperm quantity and movement in rats. *Biol. Trace Elem. Res.*, 93: 141-154.
23. Wyrobek, A.J., L.A. Gordon, J.G. Burkhardt, M.W. Francis and R.W. Kapp *et al.*, 1983. An evaluation of the mouse sperm morphology test and other sperm tests in nonhuman mammals: A report of the U.S. environmental protection agency Gene-Tox program. *Mutat. Res./Rev. Genet. Toxicol.*, 115: 1-72.
24. Sonmez, M., G. Turk and A. Yuces, 2005. The effect of ascorbic acid supplementation on sperm quality, lipid peroxidation and testosterone levels of male Wistar rats. *Theriogenology*, 63: 2063-2072.
25. Bergmeyer, M., 1974. Steroid dehydrogenases. *Met. Enzym. Anal.*, 1: 476-477.
26. Haeri, S., B. Minaie, G. Amin, S. Nikfar and R. Khorasani *et al.*, 2006. Effect of *Satureja khuzestanica* essential oil on male rat fertility. *Fitoterapia*, 77: 495-499.
27. Balamurugan, G., P. Muralidharan and S. Polapala, 2010. Aphrodisiac activity and curative effects of *Pedaliium murex* (L.) against ethanol-induced infertility in male rats. *Turk. J. Biol.*, 34: 153-163.
28. Gupta, R.S., R. Chaudhary, R.K. Yadav, S.K. Verma and M.P. Dobhal, 2005. Effect of saponins of *Albizia lebbbeck* (L.) Benth bark on the reproductive system of male albino rats. *J. Ethnopharmacol.*, 96: 31-36.
29. Uygur, R., M. Yagmurca, O.A. Alkoc, A. Genc, A. Songur, K. Ucok and O.A. Ozen, 2014. Effects of quercetin and fish n-3 fatty acids on testicular injury induced by ethanol in rats. *Andrologia*, 46: 356-369.
30. Gentry-Nielsen, M.J., E.V. Top, M.U. Snitily, C.A. Casey and L.C. Preheim, 2004. A rat model to determine the biomedical consequences of concurrent ethanol ingestion and cigarette smoke exposure. *Alcoholism: Clin. Exp. Res.*, 28: 1120-1128.
31. Alirezaei, M., A. Kheradmand, R. Heydari, N. Tanideh, S. Neamati and M. Rashidipour, 2012. Oleuropein protects against ethanol-induced oxidative stress and modulates sperm quality in the rat testis. *Mediterr. J. Nutr. Metabol.*, 5: 205-211.
32. Akbari, A., K. Nasiri, M. Heydari, S.H. Mosavat and A. Irajli, 2017. The protective effect of hydroalcoholic extract of *Zingiber officinale* Roscoe (Ginger) on ethanol-induced reproductive toxicity in male rats. *J. Evidence-Based Complement. Alternat. Med.* 10.1177/2156587216687696.
33. Peretz, J., R.K. Gupta, J. Singh, I. Hernandez-Ochoa and J.A. Flaws, 2010. Bisphenol A impairs follicle growth, inhibits steroidogenesis, and downregulates rate-limiting enzymes in the estradiol biosynthesis pathway. *Toxicol. Sci.*, 119: 209-217.
34. Bashandy, A.E.S., 2007. Effect of fixed oil of *Nigella sativa* on male fertility in normal and hyperlipidemic rats. *Int. J. Pharmacol.*, 3: 27-33.

35. He, Y., F. Zeng, Q. Liu, W. Ju and H. Fu *et al.*, 2010. Protective effect of magnesium isoglycyrrhizinate on ethanol-induced testicular injuries in mice. *J. Biomed. Res.*, 24: 153-160.
36. Wang, X., S. Chu, T. Qian, J. Chen and J. Zhang, 2010. Ginsenoside Rg1 improves male copulatory behavior via nitric oxide/cyclic guanosine monophosphate pathway. *J. Sexual Med.*, 7: 743-750.
37. Adaramoye, O.A. and M. Arisekola, 2013. Kolaviron, a biflavonoid complex from *Garcinia kola* seeds, ameliorates ethanol-induced reproductive toxicity in male wistar rats. *Niger. J. Physiol. Sci.*, 28: 9-15.
38. Omar, T.Y. and Y.K. Abdalhafid, 2016. Effect of *Panax ginseng* root powder on fertility and antioxidant enzymes in male rabbits. *Eur. J. Pharm. Med. Res.*, 3: 76-83.