



International Journal of Pharmacology

ISSN 1811-7775

science
alert

ansinet
Asian Network for Scientific Information



Research Article

Ficus carica (Fig) Fruit Extract Attenuates CCl₄-induced Hepatic Injury in Mice: A Histological and Immunohistochemical Study

Mohammed A. Alsahli, Ahmad Almatroudi, Amjad Ali Khan, Fahad Abdulrahman Alhumaydhi, Faris Alrumaihi and Arshad Husain Rahmani

Department of Medical Laboratories, College of Applied Medical Sciences, Qassim University, Buraidah, Saudi Arabia

Abstract

Background and Objective: Figs are recognised to contain a number of pharmacological properties without any adverse effect. The present study aimed to evaluate the protective role of fig fruit extract on CCl₄-induced hepato-toxicity. **Materials and Methods:** The mice were randomly divided into 4 groups, Group I mice, vehicle treated were kept on normal diet and served as normal control. Group II mice, received fig extract only, Groups III, received CCl₄ only and served as disease control group. Group IV mice, labelled as treatment group, received CCl₄+fig fruit extract (100 mg kg⁻¹ b.wt.). **Results:** CCl₄-induction causes significant increase in alanine aminotransferase (ALT), aspartate aminotransferase (AST), alkaline phosphatase (ALP) level and decrease in antioxidant enzymes levels. Administration of fig extract significantly restore the CCl₄-induced alterations in the liver enzymes and antioxidant enzymes and such differences were statically significant ($p < 0.05$). Histopathology of the liver tissue revealed that administration of fig fruits extract reduced inflammatory cell infiltration and blood vessel dilation and showed role in the maintenance of hepatocytes architecture whereas, severe tissue alterations was noted in CCl₄ treated group. **Conclusion:** The overall findings, indicate that fig fruit extract is useful in preventing liver injury against CCl₄-induced hepato-toxicity through its antioxidant enzyme activities and shows role in the maintenance of hepatocyte architecture.

Key words: Fig, antioxidant activity, hepatocyte architecture, p53 protein, liver function enzymes

Received: November 29, 2018

Accepted: December 25, 2018

Published: March 15, 2019

Citation: Mohammed A. Alsahli, Ahmad Almatroudi, Amjad Ali Khan, Fahad Abdulrahman Alhumaydhi, Faris Alrumaihi and Arshad Husain Rahmani, 2019. *Ficus carica* (Fig) fruit extract attenuates CCl₄-induced hepatic injury in mice: A histological and immuno-histochemical study. Int. J. Pharmacol., 15:370-376.

Corresponding Author: Arshad Husain Rahmani, Department of Medical Laboratories, College of Applied Medical Sciences, Qassim University, Buraidah, Saudi Arabia

Copyright: © 2019 Mohammed A. Alsahli *et al.* This is an open access article distributed under the terms of the creative commons attribution License, which permits unrestricted use, distribution and reproduction in any medium, provided the original author and source are credited.

Competing Interest: The authors have declared that no competing interest exists.

Data Availability: All relevant data are within the paper and its supporting information files.

INTRODUCTION

The liver plays a vital role in protecting an organism from potentially toxic chemical abuses through its ability to convert lipophilic into more water-soluble metabolites, that can be efficiently eliminated out from the body through the urine¹. Several factors that damage the liver are viruses and alcohol use, toxin and drugs. Carbon tetrachloride (CCl₄) is, a commonly used laboratory reagent manifest by its toxicity leading to liver lesion and fibrosis, has been broadly applied in liver related studies². It is considered that CCl₄ toxicity results from bioactivation of CCl₄ into trichloro-methyl free radical by cytochrome P450 system in liver microsomes and subsequently causes lipid peroxidation of membranes³⁻⁴. Moreover, CCl₄ shows a role in the induction of the production of several types of reactive oxygen species (ROS), thus causing liver injury and increase the activities of liver enzymes including L-alanine aminotransferase, L-aspartate amino transferase and alkaline phosphatase (ALP)⁵.

Medicinal plants or some natural product show role in disease prevention through modulation of various biological activities. In this regards, *Ficus carica*, commonly known as fig, a member of Moraceae family, is a small deciduous tree native to Asia Minor, Persia, Syria and the Mediterranean regions⁶. Phytochemical studies have shown that *F. carica* contain various bioactive compounds including phenolic compounds, phytosterols, organic acids, anthocyanins, triterpenoids, coumarins and some volatile compounds such as hydrocarbons, aliphatic alcohols and few other classes of secondary metabolites from different parts of *F. carica*⁷⁻⁸. Phytochemical studies have shown that medicinal properties of figs are due to the presence of phenolic compounds and other constituents. The previous findings have demonstrated a significant reversal of biochemical, histological and functional changes induced by rifampicin treatment through petroleum ether extract, representing promising hepato-protective activity⁹. Another study, performed to find the potential health-promoting constituents of fig fruits and commercial fig varieties were analyzed for total polyphenols, total flavonoids and antioxidant capacity. These findings revealed that the fruits contained the highest levels of polyphenols, flavonoids and anthocyanins and exhibited the highest antioxidant capacity¹⁰. In this study, the hepato-protective effects of fig fruit were investigated in mice models of liver injury.

MATERIALS AND METHODS

Reagents and animals: All the kits for this study were purchased from Abcam (UK). The albino male mice were

purchased from the animal house of King Saud University, Saudi Arabia. The mice were kept for 2 weeks for acclimatization to the standard housing conditions (25±2°C temperature and 12 h light/dark cycle) and were supplied with standard chow and tap water *ad libitum*.

Ethics statement: This study was conducted in accordance with the guidance of ethical committee for animal handling at Qassim University. The experimental procedure was approved by the Bioethics Review Committee of the College of Applied Medical Science, Qassim University.

Experimental design: Thirty-two mice were randomly divided into 4 groups with 8 mice in each group. The animal experiment was run for 8 weeks. Group I, labelled as vehicle treated mice were kept on normal diet and served as control. Group II mice, received only fig fruit extract at 100 mg kg⁻¹ b.wt. day⁻¹. Group III, labelled as disease control, received CCl₄ (0.04 cc of a 40% solution of CCl₄ in olive oil) orally, thrice a week⁸. Group IV, labelled as treatment group, received CCl₄+fig fruit crude extract (100 mg kg⁻¹ b.wt. day⁻¹). After the completion of treatment, all the mice were sacrificed and the blood and tissue samples were collected for analysis.

Measurement of liver function enzyme biomarkers: The blood samples obtained from each mice were allowed to clot for about 30 min and was centrifuged at 3000 rpm for 10 min to get the serum. The serum was stored at 4°C for the analysis of the alanine aminotransferase, aspartate aminotransferase and alkaline phosphatase levels.

Evaluation of antioxidant enzymes levels: The liver tissue samples were homogenized and centrifuged at 3000×g for 15 min at 4°C. The supernatants were collected to measure the levels of catalase.

Measurement of the total anti-oxidant capacity (TAC): The total anti-oxidant capacity was also measured with a commercially available assay kit (Abcam, UK) and the results were interpreted accordingly.

Haematoxylin and eosin (H and E) staining: The livers were excised and fixed in 10% neutral buffered formalin to avoid the autolysis of tissues. The fixed tissues were further processed, embedded in paraffin wax, sectioned into 5 µm thickness, de-paraffinised and rehydrated. All the sections were stained with haematoxylin and eosin (H and E) stain to analyze the alterations in the tissues.

Expressional evaluation of certain proteins through immuno-histochemistry:

Expression of different types of proteins including PTEN and P53 was evaluated as by earlier described method¹¹. The sectioned liver tissues were stained using a monoclonal antibody according to the manufacturer's protocol (Abcam, UK). The secondary antibody and DAB were added accordingly. The tissue was considered as positive staining for marker when more than 5% of the cells showed positivity for marker or less than 5% positivity was considered as negative case¹².

Statistical analysis: All the data was expressed as the mean \pm SE. Statistical analysis was done by using analysis of variance. The level of significance was at $p < 0.05$.

RESULTS

Effects of fig extracts on serum ALT, AST and ALP level:

In the current study, a significant increase in the activities of serum ALT, AST and ALP levels were observed in the CCl₄-treated group (diseases control) as compared with the control

group ($p < 0.05$). Whereas, the mice treated with fig fruit extract in addition to CCl₄ showed significant reduction in the serum ALT, AST and ALP levels as compared with mice treated by CCl₄ only ($p < 0.05$) (Fig. 1).

Effect of fig extract on the antioxidant enzyme level and total anti-oxidant capacity:

Carbon tetrachloride treated mice group showed significant reduction in the catalase level in liver tissue as compared to control group ($p < 0.05$) (Fig. 2a). Whereas, mice group treated with the extract of fig fruit showed significant ($p < 0.05$) enhancement of catalase. Moreover, CCl₄ treated mice group showed significant reduction in the total anti-oxidant capacity as compared to control group. Whereas, fig fruits extract treated group showed increase in the total anti-oxidant capacity ($p < 0.05$) (Fig. 2b).

Histopathological studies:

Histo-pathological analysis of liver tissue of control group revealed normal cellular architecture with distinct hepatic cells, sinusoidal spaces and central vein (Fig. 3a). The mice group treated with CCl₄ revealed the

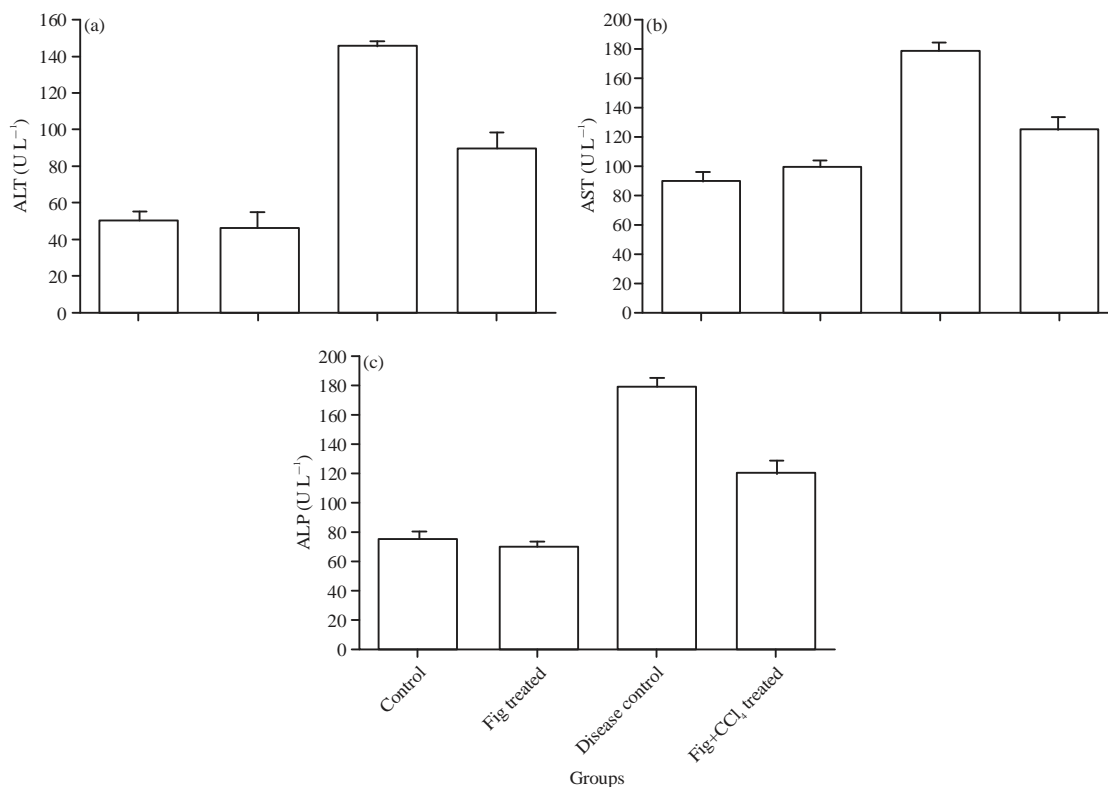


Fig. 1: Serum ALT, AST and, ALP levels in normal control, only fig treated group, disease control (CCl₄) and treatment group (CCl₄ plus fig fruits extract). A considerably increased level of these enzymes in CCl₄ treated group whereas CCl₄ plus fig fruits extract treated group showed reduction in these enzymes levels ($p < 0.05$)

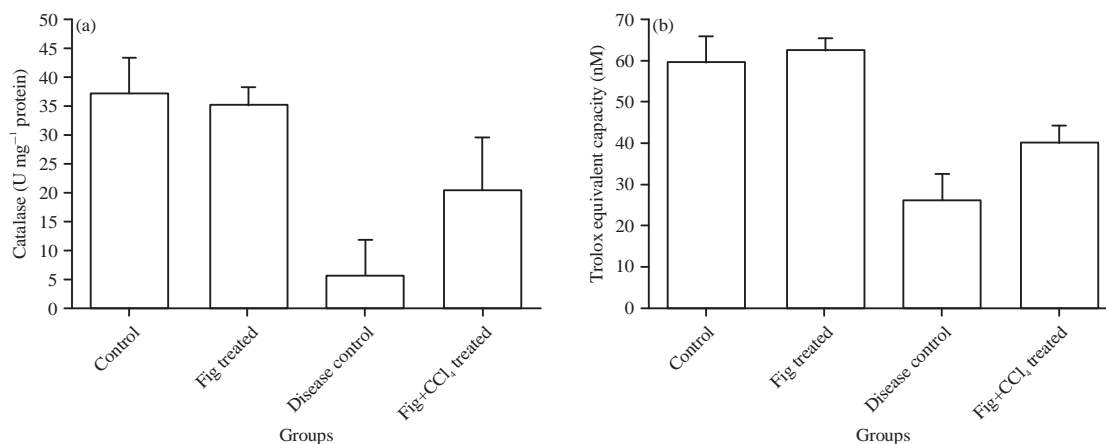


Fig. 2(a-b): Catalase and total antioxidant capacity level were considerably decreased in CCl₄ treated group whereas CCl₄ plus fig fruits extract treated group showed increase in the antioxidant enzymes levels ($p < 0.05$)

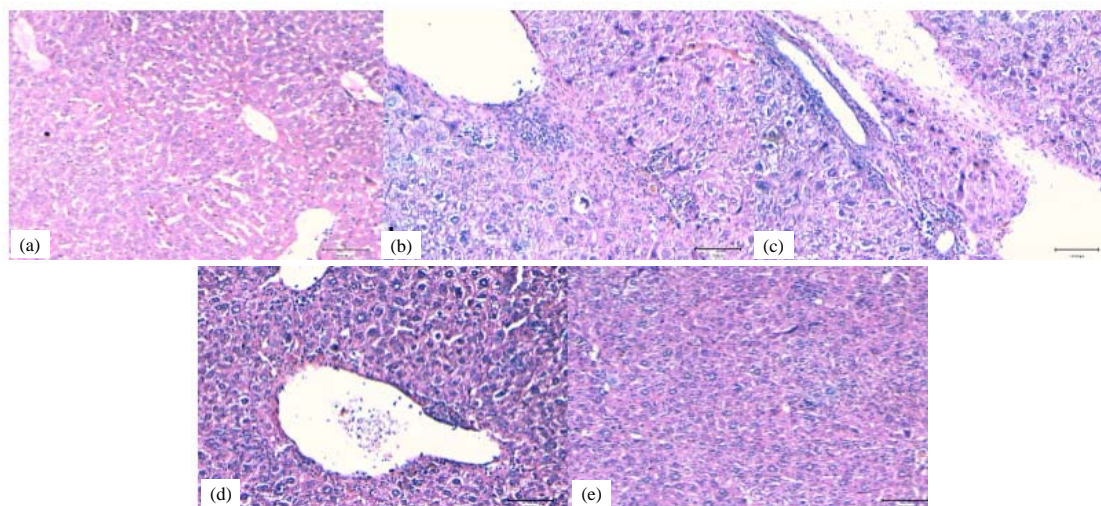


Fig. 3(a-e): (a) Control group, (b-d) CCl₄ treated group showed infiltration of lymphocytes, congestion and blood vessel dilation and (e) CCl₄+fig extract reduced inflammatory cell infiltration and blood vessel dilation and maintain of hepatocytes architecture

infiltration of lymphocytes, congestion, haemorrhage, blood vessel dilation and necrosis (Fig. 3b-d). These pathological changes were found to be lesser in the group of CCl₄+Fig extract treated group. Moreover, inflammation, congestion and haemorrhage and blood vessel dilation was reduced remarkably in fig extract treated group ($p < 0.05$) (Fig. 3e).

Effect of fig extract on PTEN protein expression:

Immuno-histochemistry staining was performed to evaluate the expression pattern of PTEN protein in all experimental groups. The results revealed that PTEN expression was found in all experimental groups including control group, disease

control group and fig extract treated group. Moreover, expression pattern of PTEN among the different group was statistically insignificant ($p > 0.05$) (Fig. 4a-c).

Effect of fig extract on p53 protein:

Expressional analysis of p53 protein was made through immuno-histochemistry staining on all experimental groups. It was revealed that control group showed very low expression for p53 protein. The CCl₄ treated group showed high expression of p53 whereas CCl₄+fig extract also showed expression but intensity of expression was low. Expression pattern of p53 among the different groups was statistically significant ($p < 0.05$) (Fig. 5a-c).

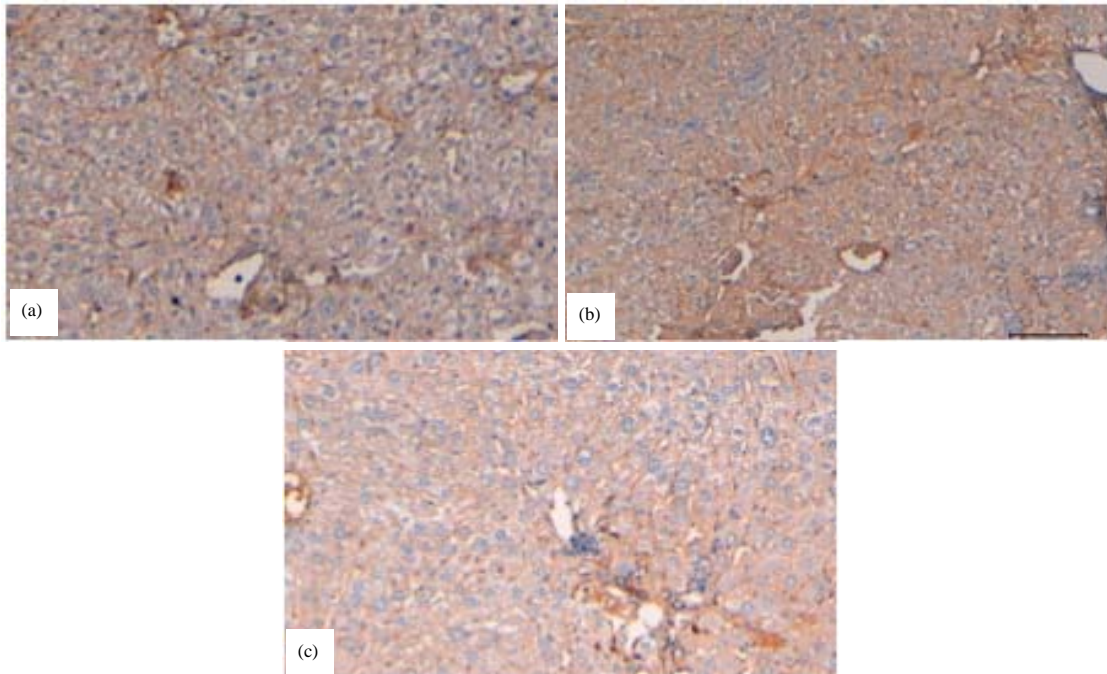


Fig. 4(a-c): (a) PTEN protein expression in control case, (b) PTEN protein expression observed in CCl₄ treated group and (c) PTEN protein expression detected in CCl₄ plus fig extract group (Orig. X mag40)

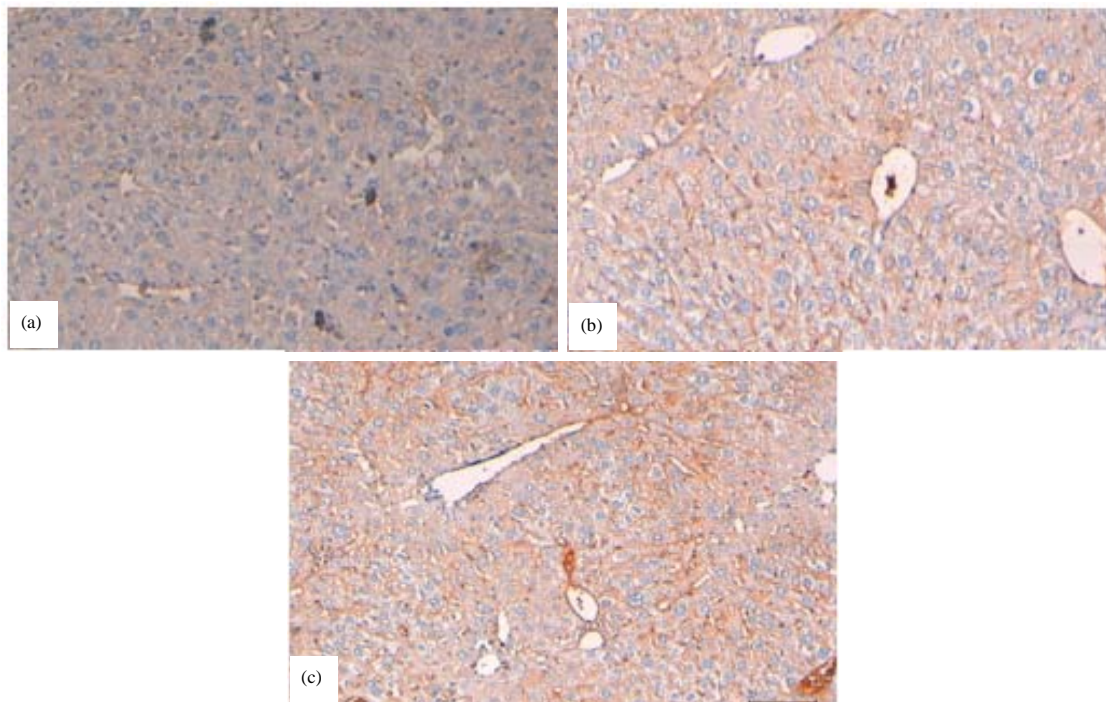


Fig. 5(a-c): (a) P53 protein expression was very low in control group, (b) p53 protein expression detected in CCl₄ plus fig extract group but intensity of positivity was low and (c) P53 protein expression detected in CCl₄ group and intensity of positivity was high (Orig. X mag. 40)

DISCUSSION

The natural product or herbs constituents showed a vital role in the diseases cure and prevention. As per the World Health Organization survey, it has designated that around 70-80% of the population worldwide depend on alternative medicines, chiefly from herbal sources, for their primary health care¹³. However, medicinal plants and their chief constituents with high anti-oxidant activity have concerned significant interest as a source for the development of liver-curing drugs¹⁴. In the current study, it was observed that significant increase in the liver function enzymes in the CCl₄ treated group compared with the control group. Whereas, fig fruit extract plus CCl₄ treated group showed significant reduction in the liver function enzymes levels as compared with mice treated by CCl₄ only. In this regards, previous findings demonstrated that levels of marker enzymes such as alanine aminotransferase (ALT) and aspartate aminotransferase (AST) were increased significantly in CCl₄ treated mice. Pre-treated with the plant extract with different concentration of *Ficus carica* and intoxicated with CCl₄, decreased activities of the enzymes were observed¹⁵. Another study, in the accordance of this finding reported that administration of olive oil with fig and date-palm fruit extracts (OFD) to doxorubicin (DOX) and/or irradiated rats significantly ameliorated the oxidative stress markers and liver function parameters as compared with DOX and/or irradiated rats¹⁶.

The level of catalase was measured in the control, CCl₄ and CCl₄ plus fig fruit extract group and it was noticed that a significant reduction in the level of catalase in the group of mice treated with CCl₄ (p<0.005) as compared to control group. Whereas, mice group treated with the extract of fig showed significant (p<0.05) increase in catalase. Moreover, CCl₄ treated mice group showed significant reduction in the total anti-oxidant capacity as compared to control group. Whereas, fig extract treated group showed increase in the total anti-oxidant capacity (p<0.05). The previous finding supported the current finding and reported that (doxorubicin) DOX and/or irradiated groups received 2 weeks pre-treatment with olive oil with fig and date-palm fruit extracts (OFD) showed a significant decrease in the hepatic TBARS, AOPPs and a significant increase in the hepatic GSH, SOD and CAT as compared with the doxorubicin and/or groups not treated by OFD, respectively¹⁶. Another study, reported that elevation of serum enzyme level in rifampicin treated group was noticed as compared to control group, indicating that rifampicin induced liver damage. Additionally, significant reduction in the level of SGPT, SGOT levels in the group treated with extract of *Ficus carica* was noted⁹.

In the current study, it was reported that CCl₄ treated group causes various types of tissue alterations including infiltration of lymphocytes, congestion, the haemorrhage and blood vessel dilation. Moreover, inflammation, congestion and haemorrhage and blood vessel dilation was reduced remarkably in fig extract treated group. Earlier study, reported in accordance with current finding, demonstrated that CCl₄ induced group causes severe fatty changes, necrosis, ballooning degeneration and broad infiltration of the lymphocytes and kupffer cells around the central vein whereas architecture of liver sections of mice treated with different *Ficus carica* leaf extracts showed a more or less normal lobular pattern with a mild degree of fatty change, necrosis and lymphocyte infiltration¹⁵. Other study reported, that animal group treated with extract of *Ficus carica* had livers which were similar to that found in the normal rats and were healthy in appearance⁹.

Expression pattern of p53 protein among the different group was statistically significant. Medicinal plants or constituents of herbs showed pivotal role in inhibition of pathogenesis through modulation of cell signalling pathways. In this regards, study based on *Actinidia valvata*, dunn root (TSAV) reported that expression of p53 in CCl₄ group was up-regulated compared with the control group and the levels were significantly decreased in TSAV high-dosed group and silymarin group. Additionally, TSAV at high dose was more reactive in upregulating Bcl-2 protein and down-regulating p53 protein¹⁷. Another finding, revealed that BAX, p53, caspase 3 and CYP2E1 were significantly up regulated and Bcl2 was down-regulated in INH and RIF treated rats. Concomitant application of polyherbal formulation Hepato plus (HP) prevented the modulation of these gene expressions¹⁸. Chrysin attenuated goblet cell disintegration, expression of phospho-p38MAPK and p53 and apoptotic tissue damage which were induced by CDDP¹⁹.

CONCLUSION

The findings indicate that fig fruit extract is useful in preventing liver injury against CCl₄-induced hepato-toxicity including the biochemical and histo-pathological aspects. Current results designate that fig ameliorated liver injury via its anti-oxidant properties.

SIGNIFICANCE STATEMENT

To our knowledge, this is the first study, performed to evaluate the expression pattern of PTEN and p53 proteins among the different group of mice through immuno-histochemisry staining. Expression pattern of

PTEN proteins among the different treatment group of mice was statistically insignificant ($p > 0.05$). A novel finding regarding p53 protein was noted, as control group showed very low expression for p53 protein while the CCl_4 treated group showed high expression of p53 protein. Moreover, the mice treated with CCl_4 plus fig extract also showed expression of p53 but the intensity of this protein was low as compared to CCl_4 treated group only. The expression pattern of p53 protein among the different treatment group was statistically significant ($p < 0.05$).

ACKNOWLEDGMENT

The authors acknowledge the Department of Medical Laboratories, College of Applied Medical Sciences, Qassim University, Saudi Arabia for providing the instruments facilities, chemicals and other items used in the study.

REFERENCES

1. Grant, D.M., 1991. Detoxification pathways in the liver. *J. Inher. Metab. Dis.*, 14: 421-430.
2. Huang, Z.G., W.R. Zhai, Y.E. Zhang and X.R. Zhang, 1998. Study of heteroserum-induced rat liver fibrosis model and its mechanism. *World J. Gastroenterol.*, 4: 206-209.
3. Cui, C.P., P. Wei, Y. Liu, D.J. Zhang, L.S. Wang and C.T. Wu, 2009. The protective role of Hepatopoietin Cn on liver injury induced by carbon tetrachloride in rats. *Hepatol. Res.*, 39: 200-206.
4. Ohta, Y., K. Ohashi, T. Matsura, K. Tokunaga, A. Kitagawa and K. Yamada, 2008. Octacosanol attenuates disrupted hepatic reactive oxygen species metabolism associated with acute liver injury progression in rats intoxicated with carbon tetrachloride. *J. Clin. Biochem. Nutr.*, 42: 118-125.
5. Tada, S., N. Nakamoto, K. Kameyama, S. Tsunematsu, N. Kumagai, H. Saito and H. Ishii, 2003. Clinical usefulness of edaravone for acute liver injury. *J. Gastroenterol. Hepatol.*, 18: 851-857.
6. Anonymous, 2002. *The Wealth of India*. Vol. IV, National Institute of Science and Communication, New Delhi, India, pp: 26-31.
7. Mawa, S., K. Husain and I. Jantan, 2013. *Ficus carica* L. (Moraceae): phytochemistry, traditional uses and biological activities. *Evid.-Based Complement. Altern. Med.*, Vol. 2013. 10.1155/2013/974256.
8. Rahmani, A.H. and Y.H. Aldebasi, 2017. *Ficus carica* and its constituents role in management of diseases. *Asian J. Pharm. Clin. Res.*, 10: 49-53.
9. Gond, N.Y. and S.S. Khadabadi, 2008. Hepatoprotective activity of *Ficus carica* leaf extract on rifampicin-induced hepatic damage in rats. *Indian J. Pharm Sci.*, 70: 364-366.
10. Solomon, A., S. Golubowicz, Z. Yablowicz, S. Grossman and M. Bergman *et al.*, 2006. Antioxidant activities and anthocyanin content of fresh fruits of common fig (*Ficus carica* L.). *J. Agric. Food Chem.*, 54: 7717-7723.
11. Husain, N.E.O., A.Y. Babiker, A.S. Albutti, M.A. Alsahli, S.M. Aly and A.H. Rahmani, 2016. Clinicopathological significance of vimentin and cytokeratin protein in the genesis of squamous cell carcinoma of cervix. *Obstetr. Gynecol. Int.*, Vol. 2016. 10.1155/2016/8790120.
12. Rahmani, A.H., A.Y. Babiker, W.M. AlWanian, S.A. Elsididig, H.E. Faragalla and S.M. Aly, 2015. Association of cytokeratin and vimentin protein in the genesis of transitional cell carcinoma of urinary bladder patients. *Dis. Markers*, Vol. 2015. 10.1155/2015/204759.
13. Sateesh, B. and A. Veeranjanyulu, 2009. Toxicological studies on ayurvedic formulation *Mersinain* albino rats. *Arch. Pharm. Sci. Res.*, 1: 130-137.
14. Singh, D., P.V. Arya, A. Sharma, M.P. Dobhal and R.S. Gupta, 2015. Modulatory potential of α -amyrin against hepatic oxidative stress through antioxidant status in Wistar albino rats. *J. Ethnopharmacol.*, 161: 186-193.
15. Aghel, N., H. Kalantari and S. Rezazadeh, 2011. Hepatoprotective effect of *Ficus carica* leaf extract on mice intoxicated with carbon tetrachloride. *Iran. J. Pharm. Res.*, 10: 63-68.
16. Fathy, A.H., M.A. Bashandy, A.M. Mansour, K.S. Azab and S.A. Bashandy, 2017. Hepatoprotective effects of olive oil with fig and date-palm fruit extracts in rats treated with doxorubicin and gamma radiation. *Adv. Pharm. Ethnomed.*, 5: 8-15.
17. Qu, L., H. Xin, G. Zheng, Y. Su and C. Ling, 2012. Hepatoprotective activity of the total saponins from *Actinidia valvata* dunn root against carbon tetrachloride-induced liver damage in mice. *Evid.-Based Complement. Altern. Med.*, Vol. 2012. 10.1155/2012/216061.
18. Sankar, M., J. Rajkumar and J. Devi, 2015. Hepatoprotective activity of hepatoplus on isoniazid and rifampicin induced hepatotoxicity in rats. *Pak. J. Pharm. Sci.*, 28: 983-990.
19. Khan, R., A.Q. Khan, W. Qamar, A. Lateef and M. Tahir *et al.*, 2012. Chrysin protects against cisplatin-induced colon toxicity via amelioration of oxidative stress and apoptosis: Probable role of p38MAPK and p53. *Toxicol. Applied Pharmacol.*, 258: 315-329.