



# International Journal of Pharmacology

ISSN 1811-7775

**science**  
alert

**ansinet**  
Asian Network for Scientific Information



## Research Article

# Protective Effect of *Rosmarinus officinalis* Essential Oil Against Genotoxic and Histopathological Alterations Induced by Paracetamol

<sup>1</sup>Fawzia Abd Elfatah Aly, <sup>1</sup>Ayman Ali Farghaly<sup>1</sup>, <sup>1,4</sup>Asmaa Saad Salman, <sup>2</sup>Emad Mohamed Hassan, <sup>1</sup>Entesar Elsayed Hassan, <sup>3</sup>Enayat Abdel Aziz Omara and <sup>2</sup>Adel Bayoumi Salama

<sup>1</sup>Department of Genetics and Cytology, National Research Centre, Dokki, Cairo, Egypt

<sup>2</sup>Department of Medicinal and Aromatic Plants Research Department, National Research Centre, Dokki, Cairo, Egypt

<sup>3</sup>Department of Pathology, National Research Centre, Dokki, Cairo, Egypt

<sup>4</sup>Department of Biology, Faculty of Science and Arts girls-Khulais, University of Jeddah, Saudi Arabia

## Abstract

**Background and Objective:** Rosemary is a fragrant evergreen herb. It has been hailed since ancient times for its medicinal properties. This work aimed to evaluate the biosafety and the protective role of rosemary essential oil (REO) against the genotoxic and histopathological alterations induced by paracetamol (PC). **Materials and Methods:** Gas chromatography-mass spectrometry (GC-MS) was performed to evaluate the chemical constituents of the extract. The biosafety and genotoxicity of REO were determined 24 h after oral treatment with the doses 0.2, 0.4 and 0.6 mL kg<sup>-1</sup> for 5 successive days. The genotoxic effect of PC was evaluated after a single oral treatment with the dose 300 mg kg<sup>-1</sup> and the protective role of REO was determined at the three tested doses administrated for 5 consecutive days and at the last day of treatment, PC was administrated and samples were collected after 24 h for chromosomal aberrations and histopathological investigation. With respect to morphological sperm abnormalities, treatment of mice were performed with the tested materials for five successive days and samples were taken after 35 days from the first treatment. **Results:** Paracetamol induced significant genotoxic effect and testicular damage while REO has safe bioactivity at the tested doses. In addition, it prohibits the percentage of chromosomal and DNA damage. The percentage of sperm abnormalities induced by PC was also inhibited after treatment with REO. The histological alterations induced by PC in testicular tissue were positively restored especially in animals pre-treated with the doses (0.4 and 0.6 mL kg<sup>-1</sup>) and the tissue maintained a histological picture nearly similar to that of the control group. **Conclusion:** This study showed important bioactivities and safety potential of rosemary essential oil. It can modulate genetic damage and histological alterations induced by PC.

**Key words:** *Rosmarinus officinalis* L., chromosomal aberrations, genetic damage, sperm abnormalities, testicular histopathology, rosemary essential oil, DNA damage

**Received:** January 14, 2019

**Accepted:** April 21, 2019

**Published:** August 01, 2019

**Citation:** Fawzia Abd Elfatah Aly, Ayman Ali Farghaly, Asmaa Saad Salman, Emad Mohamed Hassan, Entesar Elsayed Hassan, Enayat Abdel Aziz Omara and Adel Bayoumi Salama, 2019. Protective effect of *Rosmarinus officinalis* essential oil against genotoxic and histopathological alterations induced by paracetamol. Int. J. Pharmacol., 15: 686-695.

**Corresponding Author:** Entesar Elsayed Hassan, Department of Genetics and Cytology, National Research Centre, Dokki, Cairo, Egypt

**Copyright:** © 2019 Fawzia Abd Elfatah Aly *et al.* This is an open access article distributed under the terms of the creative commons attribution License, which permits unrestricted use, distribution and reproduction in any medium, provided the original author and source are credited.

**Competing Interest:** The authors have declared that no competing interest exists.

**Data Availability:** All relevant data are within the paper and its supporting information files.

## INTRODUCTION

Rosemary (*Rosmarinus officinalis* L., Lamiaceae) is a woody perennial herb, cultivated in many countries all over the world as an ornamental and aromatic plant. Recently, essential oils of plants and their active compounds have a great interest due to their pharmacological and biological activities<sup>1</sup>. Rosemary essential oil (REO) possesses various health benefits and therapeutic effects<sup>2</sup>.

Paracetamol (N-acetyl-p-aminophenol, paracetamol, PC) is an effective analgesic and antipyretic drug. Several studies showed that over doses of PC can lead to severe damage in the liver and may cause liver failure<sup>3</sup>. The toxic metabolite of PC named N-acetyl-p-benzoquinoneimine (NAPB) forms in the liver and is the main reason of hepatotoxicity. This metabolite is detoxified by endogenous glutathione (GSH). However, if PC is taken in over doses, it depletes GSH stores and leads to an inability to detoxify NAPB<sup>4</sup>. Also, the increase of lipid peroxidation associated with PC treatment, may lead to a decrease in the antioxidant enzymes and to release of free radicals that cause oxidative stress, DNA damage and cancer<sup>5</sup>. Over doses of PC were also reported to induce testicular atrophy and a decrease in testosterone hormone<sup>6</sup>, implicated in chronic renal disease<sup>7</sup>, necrotic changes in lung<sup>8</sup> and asthma in children<sup>9</sup>.

According to the extensive use of PC and its side effects on human health, there is a need to evaluate natural compounds that have a protective role. This study was aimed to investigate the biosafety of REO, its ability to inhibit PC-induced testicular and DNA damage and giving a highlight on its chemical constituents.

## MATERIALS AND METHODS

**Chemicals:** Paracetamol and chemicals used in the extraction were purchased from El Nasr Pharmaceutical Chemicals Co. ADWIC, Cairo, Egypt, normal melting agarose (NMA, Panreac Quimica SA, Barcelona, Spain), low-melting agarose (LMA; Bio Basic Inc., Canada), fetal bovine serum (FBS: Biowest, Nuaillé, France).

**Extraction of rosemary essential oil (REO):** The leaves of *Rosmarinus officinalis* L., were collected from the Experimental Agricultural Station, Faculty of Agriculture, Cairo University and Giza Governorate during the season of 2016-2017. The plant was subjected to botanical identification at Medicinal and Aromatic Plants Research Department, National Research Centre (Dokki, Cairo, Egypt). The volatile oil of fresh rosemary leaves was extracted using the water distillation method for 3 h in a Clevenger's apparatus<sup>10</sup>. The extraction process was

done in triplicate and the mean values of the oil content (%) were recorded.

### Gas chromatography-mass spectrometry analysis (GC-MS):

The GC-MS system (Agilent Technologies) was equipped with gas chromatograph (7890B) and mass spectrometer detector (5977A) at Central Laboratories Network, National Research Centre (Cairo, Egypt). The plant sample was diluted with hexane (1:19, v/v). The GC was equipped with HP-5MS column (30 m×0.25 mm internal diameter and 0.25 µm film thickness). Analyses were carried out using helium as the carrier gas at a flow rate of 1.0 mL min with a split ratio of 1:30 and injection volume of 1 µL. The following temperature program was used: 40°C for 1 min; rising at 4°C min to 150°C and held for 6 min; rising at 4°C min to 210°C and held for 1 min. The injector and detector were held at 280 and 220°C, respectively. Mass spectra was obtained by electron ionization (EI) at 70 eV and using a spectral range of m/z 50-550. Identification of different constituents was determined by comparing the spectrum fragmentation pattern with those stored in Wiley and NIST Mass Spectral Library data.

**Experimental animals:** Male Swiss Albino mice (*Mus musculus*) three months old weighing about 25-30 g were obtained from animal house colony of the National Research Centre ( Dokki, Cairo, Egypt). The animals were housed in stainless steel wire mesh cages on a bedding of wood shavings. Ambient temperature was controlled at 25±3°C with relative humidity of 50±15% and a light/dark cycle of 12/12 h. Food and water were provided *ad libitum*. All groups of mice were allowed to adapt the laboratory conditions for 1 week earlier to the experiments setup. The present research plane was approved by the Institutional Animal Ethics Committee (IAEC) of the National Research Centre in Egypt.

**Experimental design:** After 1 week of acclimation in the lab, the animals were fasted overnight before treatment. Total of 120 mice were used in all experiments. Eighty mice (10/group) were used for cytogenetic and histopathological end points and then divided randomly into the following groups:

- **Group 1:** Normal control (Negative control)
- **Group 2:** Mice received oral PC at 300 mg kg<sup>-1</sup> for 24 h
- **Groups (3-5):** Mice received oral REO at 0.2, 0.4 and 0.6 mL kg<sup>-1</sup> for 5 consecutive days
- **Groups (6-8):** Mice received oral REO at 0.2, 0.4 and 0.6 mL kg<sup>-1</sup> for 5 consecutive days and at the last day of treatment PC at 300 mg kg<sup>-1</sup> was orally administrated and samples were collected 24 h after the last treatment

Forty mice were used to evaluate sperm abnormalities (5 mice/each group). Mice were treated with the tested materials for 5 consecutive days and samples were collected after 35 days started from the first day of treatment. Groups were randomly divided as follows:

- **Group 9:** Negative control group
- **Group 10:** Mice treated with PC
- **Groups (11-13):** Mice treated with different doses of REO
- **Groups (14-16):** Mice treated with REO plus PC

### Experimental procedure

**Micronucleus test:** The epiphyses were cut and the bone marrow was flushed out by gentle flushing and aspiration with fetal calf serum<sup>11</sup>. The cell suspension was centrifuged at 1000 rpm for 10 min and the supernatant was discarded. A small drop of the suspended cell pellet was spread on to clean glass slides and air-dried. The bone marrow smears were made in five replicates and fixed in absolute methanol for 10 min and stained with May-Grünwald/Giemsa at pH 6.828. Scoring the polychromatic erythrocytes and the percentage of micronucleated polychromatic erythrocytes (MNPCEs) was determined by analyzing the number of MN cells from 1000 PCEs per animal.

**Chromosomal aberrations analysis in bone marrow cells and mouse spermatocytes:** Mice were i.p injected with colchicine 2.5 h before sacrificed. Bone marrow chromosomes were prepared according to the technique developed by Fahmy *et al.*<sup>12</sup>. One hundred well spread metaphases were analyzed per mouse describing different kinds of abnormalities. Scoring was performed under 2500× magnification with a light microscope. Spermatocyte chromosomes were prepared from the testes of the same animals according to El-Sawi *et al.*<sup>13</sup>. About 100 well spread diakinesis-metaphase I cells were analyzed per animal scoring different types of abnormalities.

**Sperm shape abnormalities:** Sperm were prepared according to the recommended method of Fahmy *et al.*<sup>12</sup>, smears were stained with 1% Eosin Y. A total of 1000 sperm were counted per animal (5000/ each treatment), scoring different types of sperm abnormalities (Head and Tail abnormalities). Sperm preparations were examined by light microscopy at 1000× magnification.

**Comet assay:** The comet assay was performed as described by Abo-Zeid *et al.*<sup>14</sup>. Cell suspensions of bone marrow were mixed with molten low melting point agarose and 75 µL of the mixture were rapidly spread on comet slides. After gelling for 10 min at 4°C in the dark, 70 µL of 0.5% Low Melting Point agarose (LMP agarose) were added to cover the cell layer. Slides were put in a tank filled with lysis solution (2.5 M NaCl, 0.1 M EDTA, 10 mM Tris base, 1% sodium lauryl sarcosinate and 1% Triton X-100) for 1 h at 4°C in the dark. Slides were washed three times with neutralization buffer (0.4 M Tris, pH 7.5) for 5 min and were incubated in fresh alkaline buffer (0.3M NaOH and 1 mM EDTA, pH>13) for 20 min at room temperature to allow unwinding of DNA. Electrophoresis was carried out at room temperature in fresh ice-cold alkaline electrophoresis buffer for 30 min (at 25 V and 300 mA). After electrophoresis slides were gently washed three times for 5 min in fresh neutralization buffer. Slides were stained with 25 µL of ethidium bromide solution (20 µg/mL) and covered with a cover slip. The comets were examined using a fluorescence microscope. A total of 50 comets were scored for each animal. The comet tail length was measured with a calibrated ocular micrometer disk. The quantification of the DNA damage was calculated as:

$$\text{Comet tail length } (\mu\text{m}) = \text{Total length of comet-head diameter} \quad (1)$$

### Histopathological examination (Testicular histopathology):

After sacrificing, parts of the testis tissue were collected for histological studies. The tissue was washed in normal saline and fixed immediately in 10% formalin for a period of at least 24 h, dehydrated with alcohol, embedded in paraffin, cut into 4-5 m thick sections and stained with haematoxylin-eosin dye for histopathological investigation<sup>15</sup>. Images were captured and processed using Adobe Photoshop Version 8.

**Statistical analysis:** Data were computerized and analyzed using Statistical Package of Social Science (SPSS Inc., version 20, Armonk, New York: IBM Corp). One way analysis of variance (ANOVA) followed by Duncan's multiple comparison test was used to determine the difference among the means. The level of statistical significance was set at  $p < 0.05$ .

Evaluation of the effect of REO to inhibit DNA damage induced by PC was carried out according to Al-Ashaal *et al.*<sup>16</sup>:

$$\text{Inhibitory index (II)} = \frac{1 - (\text{REO plus PC control})}{(\text{PC-control})} \times 100 \quad (2)$$

## RESULTS

**Analysis of chemical constituents by GC/MS:** The yield of REO obtained from fresh leaves by water distillation was 0.25%. According to GC/MS investigation, 16 components including Camphene,  $\beta$ -Pinene,  $\beta$ -Myrcene, p-Cymene, Eucalyptol, Linalool, Camphor, endo-Borneol, Terpinen-4-ol,  $\alpha$ -Terpineol, Bornyl acetate, Glycerol 1,2-diacetate, Caryophyllene, Humulene, Caryophyllene oxide were identified that comprised 99.28% of the oil Table 1.

### Cytogenetic study

**Micronucleus test:** Treatment with REO alone was found to be safe and did not induce any significant damage. The elevation of MN was observed in PC treated mice, reached  $4.2 \pm 0.68$  ( $p < 0.05$ ) and the positive effect of REO in decreasing the

reflected in Table 2. The results indicated significant protective role at all doses of REO. The percentage of reduction of MNPCE was dose-dependent.

### Chromosomal aberrations analysis in bone marrow and spermatocyte cells:

The results in Table 3 and 4 showed that REO at the tested doses reduced chromosomal abnormalities induced by PC in a dose-dependent manner. The inhibitory index with the highest tested dose of REO reached 87 and 89% in bone marrow and spermatocytes, respectively.

**Sperm shape abnormalities:** The percentage of sperm abnormalities after treatment with REO at the three tested doses was nearly close to the control. In addition it was significantly inhibited the abnormalities induced by PC in a dose dependent manner (Table 5).

**Comet assay analysis:** The data in Table 6 represented the percentages of comet tails for bone marrow cells. The results showed that PC increased the percentage of cells with comet tail to 12.8% compared with 1.2% in the negative control.

Table 1: GC/MS analysis of leaves of *Rosmarinus officinalis* essential oil (REO)

Peak	Compounds	Rt	Conc. (%)
1	$\alpha$ -Pinene	8.16	17.55
2	Camphene	8.61	7.93
3	$\beta$ -Pinene	9.55	4.74
4	$\beta$ -Myrcene	10.12	1.15
5	p-Cymene	11.28	2.20
6	Eucalyptol	11.57	28.04
7	Linalool	14.05	1.60
8	Camphor	15.62	18.80
9	endo-Borneol	16.00	1.30
10	Terpinen-4-ol	16.33	2.99
11	$\alpha$ -Terpineol	17.24	2.16
12	Bornyl acetate	20.53	0.45
13	Glycerol 1,2-diacetate	22.85	3.06
14	Caryophyllene	24.88	5.60
15	Humulene	25.92	0.63
16	Caryophyllene oxide	29.94	0.70
	Unknown		0.72
	Oxygenated compounds		59.10
	Non-oxygenated compounds		40.90

Table 2: Effect of REO on PC-induced micronuclei in mouse bone marrow cells

Treatments and doses	No. of MN	MNPCE (Mean $\pm$ SE)	Inhibitory index (II)
Negative control	55	$1.1 \pm 0.58^a$	-
PC (300 mg kg <sup>-1</sup> )	210	$4.2 \pm 0.68^d$	-
<b>REO (mL kg<sup>-1</sup>)</b>			
0.2	60	$1.2 \pm 0.20^a$	-
0.4	54	$1.08 \pm 0.18^a$	-
0.6	53	$1.06 \pm 0.10^a$	-
<b>REO+PC</b>			
0.2+300	110	$2.2 \pm 0.32^{ab}$	47.6
0.4+300	95	$1.9 \pm 0.20^a$	54.7
0.6+300	80	$1.6 \pm 0.10^a$	61.9

Total No. of scored cells is 5000 (5 animals/group). The values having different superscript letters in each column are significantly different from one to another as calculated by ANOVA. The data were presented as mean  $\pm$  SE (n = 5)

Table 3: Effect of REO on PC-induced chromosomal aberrations in mouse bone marrow cells

Treatments and doses	Total abnormal metaphases		No. of different types of abnormal metaphases				Inhibitory index (II)
	No.	Mean% $\pm$ SE	Gap	Fragment	Break	Deletion	
Negative control	18	$3.60 \pm 0.60^a$	9	6	3	0	0
PC (300 mg kg <sup>-1</sup> )	56	$11.20 \pm 0.67^e$	19	13	17	7	0
<b>REO (mL kg<sup>-1</sup>)</b>							
0.2	23	$4.60 \pm 0.44^a$	8	9	4	2	0
0.4	20	$4.00 \pm 0.40^a$	7	7	3	3	0
0.6	17	$3.40 \pm 0.58^a$	4	5	5	3	0
<b>REO+PC</b>							
0.2+300	28	$5.60 \pm 0.50^{ab}$	7	10	7	4	74
0.4+300	24	$4.80 \pm 0.58^a$	6	8	4	6	84
0.6+300	23	$4.60 \pm 0.50^a$	4	10	6	3	87

Number of examined metaphases is 500 (100 metaphase/animal-5 animals/group). The values having different superscript letters in each column are significantly different from one to another as calculated by ANOVA. The data were presented as mean  $\pm$  SE (n = 5)

Table 4: Effect of REO on PC-induced chromosomal abnormalities in mouse spermatocyte cells

Treatments and doses	Total abnormal metaphases		No. of different types of abnormal metaphases			
	No.	Mean%±SE	XY-uni.	Auto.uni.	XY-uni.+Auto.uni.	Inhibitory index (II)
Negative control	15	3.00±0.44 <sup>a</sup>	11	4	0	0
PC (300 mg kg <sup>-1</sup> )	50	10.00±0.70 <sup>e</sup>	22	28	2	0
<b>REO (mL kg<sup>-1</sup>)</b>						
0.2	13	2.60±0.67 <sup>a</sup>	10	3	0	0
0.4	12	2.40±0.40 <sup>a</sup>	8	4	0	0
0.6	10	2.00±0.31 <sup>a</sup>	7	3	0	0
<b>REO+PC</b>						
0.2+300	30	6.00±0.44 <sup>b</sup>	16	13	1	57
0.4+300	22	4.40±0.50 <sup>ab</sup>	15	7	0	80
0.6+300	19	3.80±0.58 <sup>a</sup>	10	9	0	89

Number of examined metaphases = 500 (100 metaphase/animal-5 animals/group), XY-uni: XY-univalent, Auto. uni.: Autosomal univalent, The values having different superscript letters in each column are significantly different from one to another as calculated by ANOVA. The data were presented as Mean±SE (n = 5)

Table 5: Effect of REO on PC-induced mouse sperm abnormalities

Treatments and doses	Abnormal sperms		No. of different types of sperm abnormalities							Inhibitory index (II)
	No.	Mean%±SE	Triangular	Banana shape	Amorphous	Without hook	Big head	Small head	Coiled tail	
Negative control	148	2.96±0.44 <sup>a</sup>	40	7	48	42	3	0	8	0
PC (300 mg kg <sup>-1</sup> )	366	7.32±0.40 <sup>d</sup>	75	17	114	84	17	4	55	0
<b>REO (mL kg<sup>-1</sup>)</b>										
0.2	151	3.02±0.38 <sup>a</sup>	31	6	51	43	8	0	12	0
0.4	142	2.82±0.60 <sup>a</sup>	22	8	45	54	6	0	7	0
0.6	138	2.76±0.50 <sup>a</sup>	18	9	53	44	4	0	10	0
<b>REO+PC</b>										
0.2+300	255	5.10±0.45 <sup>b</sup>	55	8	71	55	10	4	52	51
0.4+300	218	4.36±0.69 <sup>b</sup>	34	10	45	58	15	7	49	68
0.6+300	191	3.82±0.63 <sup>a</sup>	37	7	64	30	8	5	40	80

Total number of examined sperm 5000 (1000 sperm/animal-5 animals/group). The values having different superscript letters in each column are significantly different from one to another as calculated by ANOVA. The data were presented as Mean±SE (n = 5)

Table 6: Effect of REO on comet assay in bone marrow cells of mice treated with PC

Treatments and doses	Comet tail length (µm)	No. of cells show comet tail	Mean of cells show comet tail (%)	Inhibition of cells show comet tail (%)
Negative control	0.91±0.11 <sup>a</sup>	6	1.20±0.1 <sup>a</sup>	-
PC (300 mg kg <sup>-1</sup> b.wt.)	5.1±0.39 <sup>e</sup>	64	12.8±0.7 <sup>ef</sup>	-
<b>REO (mL kg<sup>-1</sup>)</b>				
0.2	0.89±0.13 <sup>a</sup>	7	1.4±0.12 <sup>a</sup>	-
0.4	0.9±0.1 <sup>a</sup>	7	1.4±0.1 <sup>a</sup>	-
0.6	0.88±0.14 <sup>a</sup>	6	1.2±0.2 <sup>a</sup>	-
<b>REO+PC</b>				
0.2+300	2.98±0.2 <sup>ab</sup>	44	8.8±0.4 <sup>cd</sup>	31.2
0.4+300	2.66±0.23 <sup>ab</sup>	38	7.6±0.5 <sup>bc</sup>	40.6
0.6+300	2.1±0.23 <sup>ab</sup>	32	6.4±0.3 <sup>b</sup>	50.0

Number of examined cells = 250 (50 cells/animal, 5 animals-group). The values having different superscript letters in each column are significantly different from one to another as calculated by ANOVA. The data were presented as Mean±SE (n = 5)

Concurrent administration of REO with PC reduced the percentage of tailing cells in a significant and dose dependent manner. The inhibitory index reached 50% after treatment with the highest tested dose of REO.

**Histopathological examination (testicular histopathology):**

Control mice showed testicular parenchyma with closely

packed seminiferous tubules and normal arrangement pattern of spermatogenic cells (spermatogonia, spermatocytes and spermatids). In between the tubules narrow interstitium was noticed containing interstitial cells and blood vessels (Fig. 1a). Also, REO (at different doses) showed almost normal testicular architecture and active spermatogenesis was appeared in number of the seminiferous tubules (Fig. 1b-d).

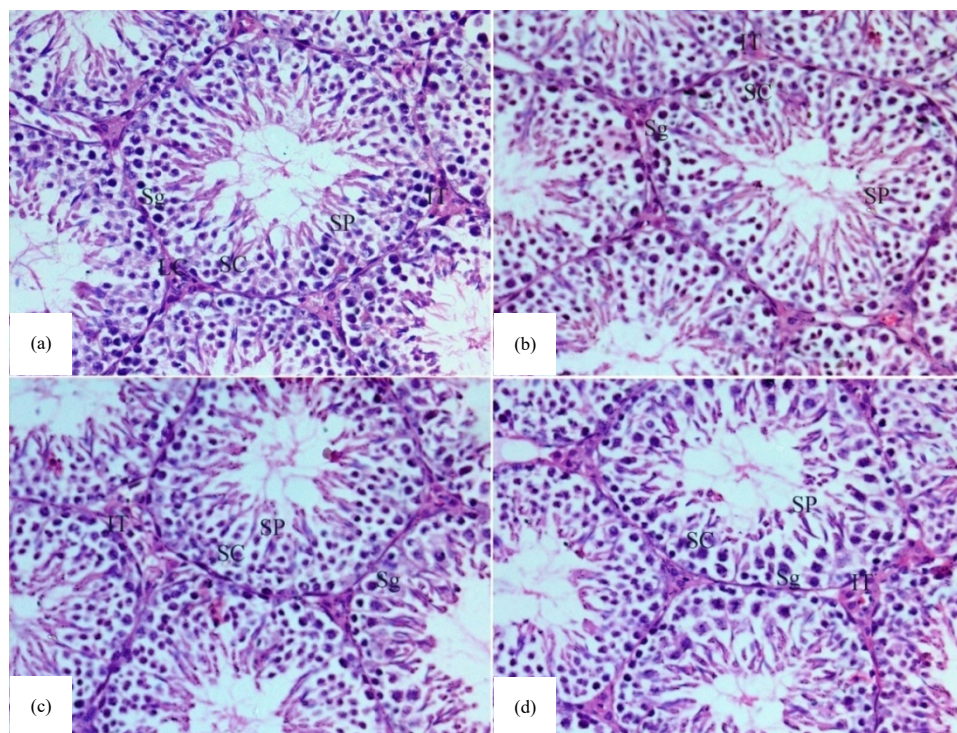


Fig. 1(a-d): Testicular histopathology of mice treated with repeated REO and single PC ( $300 \text{ mg kg}^{-1} \text{ b.wt.}$ ), (a) Photomicrograph of the testis of mice from the control group showing normal seminiferous tubule with different stages of spermatogenic cells [spermatogonia (Sg), spermatocytes (SC) and spermatids (SP)]. The intertubular tissue appears rich of interstitial cells (IT). (b-d) Photomicrographs of the testis of mice from the groups treated with REO at doses  $0.2, 0.4$  and  $0.6 \text{ mL kg}^{-1} \text{ b.wt.}$ , showing almost normal cellular architecture with appearance of active spermatogenesis in number of the seminiferous tubules

Paracetamol treatment caused testicular tissue damage, marked interruption of spermatogenesis, different degenerative changes and necrosis together with disorganization of spermatogonial cell layers as compared to normal control (Fig. 2a).

However, the co-administration of REO at all doses attenuated the PC-induced spermatogenic cell loss from seminiferous tubules (Fig. 2b-d). Partial improvement was recorded with the lowest tested dose, while with the doses  $0.4$  and  $0.6 \text{ mL kg}^{-1}$  REO the histological integrity of the testis was maintained, showing almost normal characteristic of seminiferous tubules and in the interstitial spaces of the testis compared with PC.

## DISCUSSION

Paracetamol (PC) is a widely used analgesic and antipyretic drug. Overdoses of PC were found to induce liver/kidney and other organ damage<sup>3</sup>. Herein the

cytogenetic and histopathological effects of PC were evaluated. The PC (single oral dose,  $300 \text{ mg kg}^{-1}$ ) induced significant frequency of micronuclei, CAs and double strand breaks in mice bone marrow cells. Also, Yoshida *et al.*<sup>17</sup> reported that PC induced chromosome aberrations in mice bone-marrow and Chinese hamster CHO-K1 cells. The same results obtained in CHO cells *in vitro*<sup>18</sup>. The SCE was detected in mice bone-marrow cells after PC treatment<sup>19</sup>.

Similarly to Current results, it was found that the pre-treatment of hamster lung (V79) cells and human colon cancer (CaCo-2) with rosemary extract reduced the level of oxidative damage and DNA strand breaks associated with  $\text{H}_2\text{O}_2$  and visible light-excited methylene blue<sup>20</sup>. Horvathova *et al.*<sup>21</sup> showed that rosemary oil, supplemented for 14 days to hepatocytes isolated from rats, decreased the level of DNA damage. It was also observed that rosemary extract revealed significant protection against DNA damage induced by the pro-carcinogens BaP and PhIP in bacterial and HepG2 human cells<sup>22</sup>.

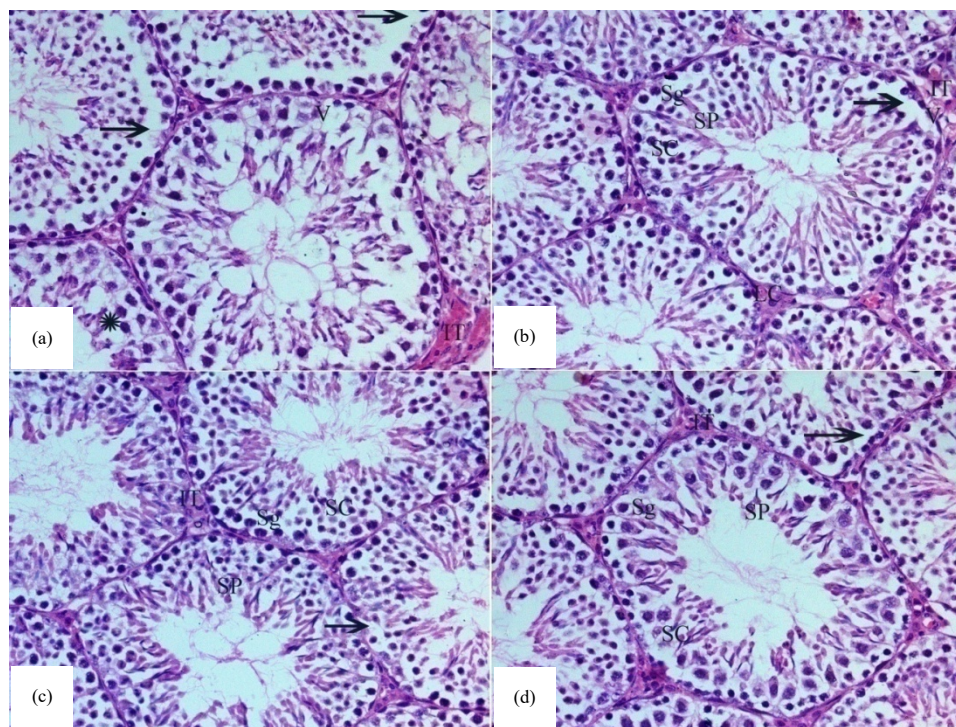


Fig. 2(a-d): (a) Photomicrograph of the testis of mice from the group treated with paracetamol at dose  $300 \text{ mg kg}^{-1}$  b.wt., showing distorted testicular parenchyma, degeneration of spermatocyte (SC)/spermatogonia (Sg) vacuolization (V) and decreased number of spermatids (SP) with congestion of interstitium (IT), (b) Photomicrograph of the testis of mice from group treated with paracetamol and REO ( $0.2 \text{ mL kg}^{-1}$ ) showing moderate improvement and still have degeneration spermatocyte (SC)/ spermatogonia (Sg) and decreased number of spermatids with congestion of interstitium (IT). (c, d) Photomicrographs of the testis of mice from groups treated with paracetamol and REO ( $0.4$  and  $0.6 \text{ mL kg}^{-1}$ ) showing almost normal cellular architecture with appearance of active spermatogenesis in number of the seminiferous tubules (H and E,  $\times 400$ )

In the present study, the effect on male germ cells was examined by analysis of morphological sperm deformities, chromosomal abnormalities in primary spermatocytes and testicular histopathology which are tools used as indicators for paternal transmission of genetic alterations to offspring<sup>23</sup>. The present results revealed a significant percentage of chromosomal and sperm abnormalities after single oral treatment with PC. Farghaly<sup>24</sup> reported the same effect with dose and time relationship. Also, Oyedeji *et al.*<sup>25</sup> revealed a decrease in sperm motility, sperm count and morphologically normal spermatozoa in PC-treated rats. Such effect may be related to deleterious impact of PC on testis and epididymis. Similarly, Abedi *et al.*<sup>26</sup> observed impact sperm parameters and chromatin/DNA integrity in mice after short and long term of PC consumption which found to be related to doses.

These results are supported by testicular histopathological findings detected in the present study where many changes were observed: marked interruption of spermatogenesis, different degenerative alterations and necrosis together with disorganization of spermatogonial cell

layers. Previous research reported degenerative changes in spermatids in mice as early as 6 h post-treatment with the dose<sup>27</sup>  $600 \text{ mg kg}^{-1}$ .

The explanation for cytogenetic DNA damage following PC treatment is that it caused an inhibition of both DNA replication and DNA repair by a specific inhibition of the ribonucleotide reductase enzyme<sup>28</sup>. These effects may provide reasons for PC's ability to induce chromosomal aberrations, micronuclei, sister chromatid exchanges, sperm abnormalities and apoptosis<sup>29</sup>.

Pre-administration of REO at different doses significantly reduced DNA damage induced by PC in all groups. The same results observed by Slamenova *et al.*<sup>30</sup>, who demonstrated that REO protects DNA and testicular cell damage in rats induced after treatment with  $\text{H}_2\text{O}_2$  and DMNQ. Also, Superchi *et al.*<sup>31</sup> reported that supplementing boar diet with REO resulted in an increase in sperm concentration, viability and live spermatozoa. In addition, rosemary oil alleviated heat stress-induced testicular structural and functional damage in growing Japanese quail through lipid peroxidation<sup>32</sup>.



The protective effect of REO may be due to its potent antioxidant activity (capture free radical agents and/or activation of detoxifying enzymes such as GSH)<sup>33</sup> or through the strong inhibitory effect against PC metabolite, N-acetyl-p benzoquinoneimine (NAPQI). Such metabolite is extremely toxic substance (formed via cytochrome P 450 isoenzymes) leads to the formation of reactive oxygen and nitrogen species and initiates lipid peroxidation resulting in cellular and DNA damage<sup>34</sup>.

Essential oils of plants are volatile and liquid aroma compounds. The essential oil of rosemary is a complex of several secondary metabolites which in a combination play a significant antioxidant role protecting big molecules of the cells such as; proteins, membrane lipids and nucleic acids against xenobiotics and their metabolites. In the present work, GC/MS of REO revealed the presence of 16 compounds where eucalyptol represents the major fragrance followed by camphor,  $\alpha$ -Pinene, camphene, caryophyllene and  $\beta$ -Pinene. The monoterpene eucalyptol (1, 8-cineole), a terpenoid oxide is a promising compound that showed strong anti-inflammatory and antioxidant effects in various diseases. It reduced the oxidative stress through the regulation of signaling pathways and radical scavenging activities<sup>35,36</sup>. Camphor,  $\alpha$ -pinene,  $\beta$ -pinene, camphene were previously reported to have antioxidant and anti-inflammatory activities<sup>37</sup>. Antioxidants and anti-inflammatory agents demonstrated to play a critical role against chemicals intoxication by scavenging reactive oxygen species and free radicals and neutralizing lipid peroxides<sup>38</sup>. The results also demonstrated the biosafety of REO at the examined doses and revealed that REO reduced DNA damage induced by PC and further studies are still required concerning their mechanisms of action.

### CONCLUSION

The present results demonstrated that REO has safe bioactivity and exerts beneficial effects in preventing PC-induced genotoxicity and testis histopathological alterations. GC/MS studies showed the presence of many bioactive compounds which play a vital role in preventing DNA damage.

### SIGNIFICANCE STATEMENTS

This study discovers the remarkable bioactivity of *Rosmarinus officinalis* essential oil that can be beneficial in therapeutic applications. Our study will help the researcher to uncover the critical areas of medical application for natural

products that many researchers were not able to explore. Thus, a new theory on the therapeutic effects of rosemary essential oil may be successful in treating many diseases.

### ACKNOWLEDGMENT

This work was supported by the project in National Research Centre, under grant number: 11010345, Cairo, Egypt. The authors would like to express their deep thanks to professor Dr. Maha Aly Fahmy, the principle author of the project for her support during the work and her valuable revision of the manuscript.

### REFERENCES

1. Zairi, A., S. Nour, N. M'hamdi, M. Bennani and I. Bergaoui *et al.*, 2018. Antioxidant, antimicrobial and the phenolic content of infusion, decoction and methanolic extracts of thyme and *Rosmarinus* species. *Curr. Pharm. Biotechnol.*, 19: 590-599.
2. European Medicines Agency, 2010. Community herbal monograph on *Rosmarinus officinalis* L., aetheroleum. July 15, 2010, pp: 1-6. [https://www.ema.europa.eu/documents/herbal-monograph/final-community-herbal-monograph-rosmarinus-officinalis-l-aetheroleum\\_en.pdf](https://www.ema.europa.eu/documents/herbal-monograph/final-community-herbal-monograph-rosmarinus-officinalis-l-aetheroleum_en.pdf)
3. Larson, A.M., J. Polson, R.J. Fontana, T.J. Davern and E. Lalani *et al.*, 2005. Acetaminophen-induced acute liver failure: Results of a united states multicenter, prospective study. *Hepatology*, 42: 1364-1372.
4. Klein-Schwartz, W. and S. Doyon, 2011. Intravenous acetylcysteine for the treatment of acetaminophen overdose. *Expert Opin. Pharmacother.*, 12: 119-130.
5. Kisaoglu, A., B. Ozogul, M.I. Turan, I. Yilmaz and I. Demiryilmaz *et al.*, 2014. Damage induced by paracetamol compared with *N*-acetylcysteine. *J. Chin. Med. Assoc.*, 77: 463-468.
6. Van den Driesche, S., J. Macdonald, R.A. Anderson, Z.C. Johnston and T. Chetty *et al.*, 2015. Prolonged exposure to acetaminophen reduces testosterone production by the human fetal testis in a xenograft model. *Sci. Trans. Med.*, Vol. 7. 10.1126/scitranslmed.aaa4097.
7. Vliegenthart, A.D.B., J.M. Shaffer, J.I. Clarke, L.E.J. Peeters and A. Caporali *et al.*, 2015. Comprehensive microRNA profiling in acetaminophen toxicity identifies novel circulating biomarkers for human liver and kidney injury. *Sci. Rep.*, Vol. 5.
8. Smith, G.J., J.A. Cichocki, B.J. Doughty, J.E. Manautou, S.E. Jordt and J.B. Morris, 2015. Effects of acetaminophen on oxidant and irritant respiratory tract responses to environmental tobacco smoke in female mice. *Environ. Health Perspect.*, 124: 642-650.

9. Sordillo, J.E., C.V. Scirica, S.L. Rifas-Shiman, M.W. Gillman and S. Bunyavanich *et al.*, 2015. Prenatal and infant exposure to acetaminophen and ibuprofen and the risk for wheeze and asthma in children. *J. Allergy Clin. Immunol.*, 135: 441-448.
10. Guenther, E., 1953. The Essential Oil. Vol. 5, D. Van Nostrand Company, Inc., New York, USA.
11. Valette, H., F. Dolle, M. Bottlaender, F. Hinnen and D. Marzin, 2002. Fluoro-A-85380 demonstrated no mutagenic properties in *in vivo* rat micronucleus and Ames tests. *Nucl. Med. Biol.*, 29: 849-853.
12. Fahmy, M.A., A.A. Farghaly, N.H.A. Hassan and K.A.E. Diab, 2015. Molecular and cytogenetic evaluation for potential genotoxicity of hydrocortisone. *Asian Pac. J. Trop. Dis.*, 5: 726-731.
13. El-Sawi, S.A., H.M. Motawae, M.A. Sleem, O. Abdel-Rahman, H.W. Usama, A.A. Farghaly and M.A. Maamoun, 2016. Antiproliferative effect of extracts and flavonoids of *Juniperus phoenicea* L. growing in Egypt. *Mintage J. Pharm. Med. Sci.*, 5: 1-7.
14. Abo-Zeid, M.A.M., N.S. Abdel-Samie, A.A. Farghaly and E.M. Hassan, 2018. Flavonoid fraction of *Cajanus cajan* prohibited the mutagenic properties of cyclophosphamide in mice *in vivo*. *Mutat. Res./Genet. Toxicol. Environ. Mutagen.*, 826: 1-5.
15. Drury, R.A.B. and E.A. Wallington, 1980. Carleton's Histological Technique. 5th Edn., Oxford University Press, Oxford New York Toronto, ISBN-13: 978-0192613103, Pages: 520.
16. Al-Ashaal, H.A.A.H., H.F.A. Abdullah, A.A. Farghaly, S.A. Ali, N.S. El-Rega and M.A.E.A. Hamed, 2017. *In vitro* produced glycoalkaloids from *Solanum nigrum* L. and evaluation of their potential role as antibilharziasis. *Asian Pac. J. Trop. Dis.*, 7: 169-180.
17. Yoshida, S., S. Nawai and K. Hiraga, 1980. Cytogenetic studies of acetaminophen and its related compounds. *Annu. Rep. Tokyo Metr. Res. Lab. P.H.*, 31-32: 102-108.
18. Sasaki, M., S. Yoshida and K. Hiraga, 1983. Additional effect of acetaminophen on the mutagenicity and clastogenicity of *N*-methyl-*N*-nitro-*N*-nitrosoguanidine in cultured Chinese hamster CHO-K1 cells. *Mutat. Res. Lett.*, 122: 367-372.
19. Giri, A.K., S.S. Sivam and K.A. Khan, 1992. Sister-chromatid exchange and chromosome aberrations induced by paracetamol *in vivo* in bone-marrow cells of mice. *Mutat. Res./Genet. Toxicol.*, 278: 253-258.
20. Slamenova, D., K. Kuboskova, E. Horvathova and S. Robichova, 2002. Rosemary-stimulated reduction of DNA strand breaks and FPG-sensitive sites in mammalian cells treated with H<sub>2</sub>O<sub>2</sub> or visible light-excited methylene blue. *Cancer Lett.*, 177: 145-153.
21. Horvathova, E., D. Slamenova and J. Navarova, 2010. Administration of rosemary essential oil enhances resistance of rat hepatocytes against DNA-damaging oxidative agents. *Food Chem.*, 123: 151-156.
22. Zegura, B., D. Dobnik, M.H. Niderl and M. Filipic, 2011. Antioxidant and antigenotoxic effects of rosemary (*Rosmarinus officinalis* L.) extracts in *Salmonella typhimurium* TA98 and HepG2 cells. *Environ. Toxicol. Pharmacol.*, 32: 296-305.
23. Beal, M.A., C.L. Yauk and F. Marchetti, 2017. From sperm to offspring: Assessing the heritable genetic consequences of paternal smoking and potential public health impacts. *Mutat. Res./Rev. Mutat. Res.*, 773: 26-50.
24. Farghaly, A.A., 2003. Mutagenic evaluation of paracetamol in somatic and germ cells of mice. *Cytologia*, 68: 133-139.
25. Oyedeji, K.O., A.F. Bolarinwa and S.S. Ojeniran, 2013. Effect of paracetamol (Acetaminophen) on haematological and reproductive parameters in male albino rats. *Res. J. Pharmacol.*, 7: 21-25.
26. Abedi, N., A. Nabi, E. Mangoli and A.R. Talebi, 2017. Short and long term effects of different doses of paracetamol on sperm parameters and DNA integrity in mice. *Middle East Fertil. Soc. J.*, 22: 323-328.
27. Placke, M.E., D.S. Wyand and S.D. Cohen, 1987. Extrahepatic lesions induced by acetaminophen in the mouse. *Toxicol. Pathol.*, 15: 381-387.
28. Rodrigues, R.M., A. Heymans, V. de Boe, A. Sachinidis and U. Chaudhari *et al.*, 2016. Toxicogenomics-based prediction of acetaminophen-induced liver injury using human hepatic cell systems. *Toxicol. Lett.*, 240: 50-59.
29. Wiger, R., J.K. Hongslo, D.P. Evenson, P. de Angelis, P.E. Schwarze and J.A. Holme, 1995. Effects of acetaminophen and hydroxyurea on spermatogenesis and sperm chromatin structure in laboratory mice. *Reprod. Toxicol.*, 9: 21-33.
30. Slamenova, D., E. Horvathova, Z. Kovacikova, K. Kozics and L. Hunakova, 2011. Essential rosemary oil protects testicular cells against DNA-damaging effects of H<sub>2</sub>O<sub>2</sub> and DMNQ. *Food Chem.*, 129: 64-70.
31. Superchi, P., L. Talarico, V. Beretti and A. Bonomi, 2005. Effect of dietary administration of oil extract from rosemary on reproductive efficiency in boars. *Ital. J. Anim. Sci.*, 4: 479-481.
32. Turk, G., A.O. Ceribasi, U.G. Simsek, S. Ceribasi and M. Guvenc *et al.*, 2016. Dietary rosemary oil alleviates heat stress-induced structural and functional damage through lipid peroxidation in the testes of growing Japanese quail. *Anim. Reprod. Sci.*, 164: 133-143.
33. Raskovic, A., I. Milanovic, N. Pavlovic, T. Cebovic, S. Vukmirovic and M. Mikov, 2014. Antioxidant activity of rosemary (*Rosmarinus officinalis* L.) essential oil and its hepatoprotective potential. *BMC Compl. Alter. Med.*, Vol. 14. 10.1186/1472-6882-14-225.

34. Singh, H., A. Prakash, A.N. Kalia and A.B. Abdul Majeed, 2016. Synergistic hepatoprotective potential of ethanolic extract of *Solanum xanthocarpum* and *Juniperus communis* against paracetamol and azithromycin induced liver injury in rats. *J. Tradit. Complement. Med.*, 6: 370-376.
35. Huang, M.T., C.T. Ho, Z.Y. Wang, T. Ferraro and Y.R. Lou *et al*, 1994. Inhibition of skin tumorigenesis by rosemary and its constituents carnosol and ursolic acid. *Cancer Res.*, 54: 701-708.
36. Seol, G.H. and K.Y. Kim, 2016. Eucalyptol and its Role in Chronic Diseases. In: *Drug Discovery from Mother Nature*, Gupta, S.C., S. Prasad and B.B. Aggarwal (Eds.). Springer, New York, pp: 389-398.
37. El Jemli, M., R. Kamal, I. Marmouzi, Z. Doukkali and E.H. Boudida *et al.*, 2017. Chemical composition, acute toxicity, antioxidant and anti-inflammatory activities of Moroccan *Tetraclinis articulata* L. *J. Tradit. Complement. Med.*, 7: 281-287.
38. Murugesan, G.S., M. Sathishkumar, R. Jayabalan, A.R. Binupriya, K. Swaminathan and S.E. Yun, 2009. Hepatoprotective and curative properties of kombucha tea against carbon tetrachloride-induced toxicity. *J. Microbiol. Biotechnol.*, 19: 397-402.