

ISSN 1682-8356
ansinet.org/ijps



INTERNATIONAL JOURNAL OF
POULTRY SCIENCE

ANSI*net*

308 Lasani Town, Sargodha Road, Faisalabad - Pakistan
Mob: +92 300 3008585, Fax: +92 41 8815544
E-mail: editorijps@gmail.com

Occurrence of Marek's Disease in Vaccinated Poultry Flocks of Haryana (India)

Kamaldeep¹, P.C. Sharma², N. Jindal² and G. Narang²

¹Department of Veterinary Microbiology

²Department of Veterinary Epidemiology and Preventive Medicine,
College of Veterinary Sciences, CCS Haryana Agricultural University, Hisar-125 004, India

Abstract: Marek's Disease (MD), which is a lymphoproliferative disease of chickens, remains one of the most important diseases. In the present study, occurrence of Marek's disease virus in ten vaccinated poultry flocks of Haryana (India) from different geographical locations was determined on the basis of clinical signs, gross and histopathology and precipitation test. The vaccines used were either HVT alone or in combination with SB-1. Samples from all the flocks had gross and histopathological lesions suggestive of Marek's disease. Grossly, visceral tumors in liver, spleen, kidney and ovary were observed. The characteristic histopathological lesions included infiltration of pleomorphic lymphoid cells such as lymphoblasts, small and large lymphocytes, plasma cells and occasionally MD cells in different organs. The lesions were non-capsulated and infiltrative type. In immunodiffusion test, feather follicle tip samples from five flocks gave a positive precipitation reaction.

Key words: Marek's disease, vaccinated poultry, diagnosis

Introduction

Marek's Disease (MD), recently classified as OIE list B disease, is a lymphoproliferative disease of chickens. The disease is characterized by number of conditions such as lymphomas of visceral organs (ovaries, liver, spleen and kidneys), unilateral or bilateral enlargement of nerves particularly sciatic nerve and brachial nerve due to infiltration of lymphoblasts; graying of iris due to lymphoblastoid cell infiltration (ocular form) and cutaneous form characterized by nodular lesions at the base of feather follicles. Generally, young birds at any age are susceptible but in most cases susceptibility is seen at four weeks of age. Clinical signs appear at about 2-5 months of age in sexually immature birds. But the disease has also been reported in adult birds (Ahmed, 1982).

Marek's disease is caused by *Gallid herpesvirus 2*, an *alphaherpesvirus*. Of the three serotypes of MDV (serotype-1, 2 and 3), serotype-1 only is capable of inducing tumors. The disease has a tremendous economic impact, firstly because of cost of vaccination and secondly because of continuing losses due to the disease. The annual losses caused by MD prior to introduction of the vaccination in 1970 were estimated to be \$150 million in U.S. and \$ 40 million in U.K. (Fenner *et al.*, 1993). The annual losses due to this disease world over have been estimated at more than 1 billion US dollars (Nair, 2005). The vaccination can prevent formation of tumor but generation of infectious virus is not prevented. The virus is shed in the environment as dander dust after maturation in the feather follicle epithelium. For this reason, this disease remains one of the most economically important diseases of poultry in

all countries of the world where intensive rearing of poultry is undertaken. We present here the occurrence of MD in the vaccinated poultry flocks of six districts of Haryana (India) employing the conventional approach of diagnosis i.e. clinical signs and symptoms, gross and histopathology and precipitation reaction using feather follicle tips as source of virus in single radial immunodiffusion assay.

Materials and Methods

Collection of epidemiological data: Data regarding total strength, number of affected birds, number of birds reported dead due to MD, clinical findings, vaccination status etc. were collected from all the poultry farms (Table 1).

Collection of tissue specimens: Tissues like liver, spleen, ovaries, kidneys and nerves were collected in 50% buffered glycerol from 10 field outbreaks of MD observed during June 2005-March 2006 from different parts of Haryana viz. Hisar, Karnal, Panipat, Jind, Sonapat and Rohtak (Table 1). Feather follicles from affected birds were also collected and stored at -20°C until their use.

Diagnosis of Marek's disease: Diagnosis of MD was done on the basis of clinical signs, post-mortem lesions, gross and histopathology and gel precipitation test.

Pathology: Grossly, the birds were examined for tumors in various visceral organs and enlargement of nerves. Tissue specimens like liver, spleen and nerves of the

Kamaldeep et al.: Occurrence of Marek's Disease in Vaccinated Poultry Flocks

Table 1: Epidemiological data of Marek's disease affected poultry flocks of Haryana state

Sample No.	Place	Type of birds	Total strength and Age	No. affected (% morbidity)	No. died (% mortality)	Vaccination status	Age of vaccination	Age of start of disease
A	Hisar	Broiler Breeder	6000 (9 wk)	100 (1.66%)	40 (0.66%)	HVT+SB1	10 th day	8 th wk
B	Sonepat	Layer	9000 (24 wk)	60 (0.66%)	30 (0.33%)	HVT+SB1	0 day; 12 th day	23 rd wk
C	Jind	BroilerBreeder	13000 (22 wk)	250 (1.92%)	50 (0.38%)	HVT+SB1	0 day; 10 th day	19 th wk
D	Karnal	BroilerBreeder	5700 (10 wk)	130 (2.28%)	25 (0.43%)	HVT+SB1	10 th day	8 th wk
E	Sonepat	BroilerBreeder	4500 (15 wk)	200 (4.44%)	15 (0.33%)	HVT+SB1	12 th day	13 th wk
F	Hisar	Layer	8000 (10 wk)	140 (1.75%)	40 (0.50%)	HVT+SB1	12 th day	8 th wk
G	Panipat	BroilerBreeder	4800 (8 wk)	175 (3.64%)	35 (0.72%)	Cell free HVT	18 th day	6 th wk
H	Rohtak	BroilerBreeder	3500 (10 wk)	150 (4.28%)	35 (1.00%)	Cell free HVT	4 th wk	9 th wk
I	Jind	BroilerBreeder	12,500 (18 wk)	500 (4.00%)	30 (0.24%)	HVT+SB1	0 day; 10 th day	17 th wk
J	Karnal	BroilerBreeder	6300 (10 wk)	150 (2.38%)	20 (0.31%)	Cell free HVT	18 th day	8 th wk

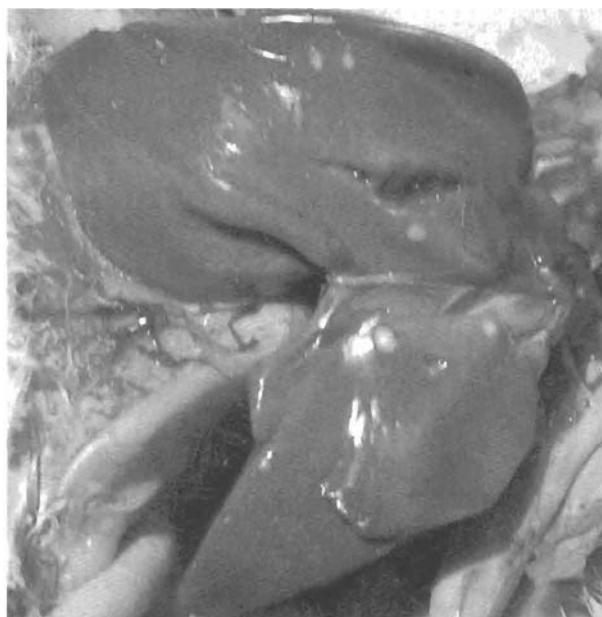

Fig. 1: Liver of MD affected bird showing small whitish tumors

affected birds were collected in 10% formal saline for histopathological studies. The paraffin wax blocks of the tissues were prepared and thin sections cut. The sections were then glued on clean grease-free glass slides, stained in haematoxylin and eosin (H and E) stain (Luna, 1968) and examined for histopathological lesions under light microscope.

Precipitation test: Single radial immunodiffusion method was used to demonstrate precipitation reaction using feather follicles obtained from the affected birds. MD-specific serum was kindly provided by Dr. D.S. Shivdekar, Indovax Pvt. Ltd., Hisar. The release of MDV from feather follicles was studied following the method of Marquardt (1972) with suitable modifications. One percent agarose suspension was prepared in 0.2M PBS (pH 7.2), containing 8% sodium chloride. This suspension was heated to melt the agarose and then placed in a water bath at 56°C for 1 hour in order to bring

the temperature of the suspension to 56°C. Decomplementation of MD positive antiserum was done in water bath at 56°C for 30 minutes. This antiserum was added in 1% agarose suspension to a final concentration of 20%. Five milliliter of this agarose serum suspension was then spread uniformly on 7.5 cm×2.5 cm clean grease-free glass slide with the help of a warm pipette, allowed to solidify. Piece of each feather follicle tip (0.5-1 cm in length) was embedded in agarose gel slide and incubated in a humidified chamber at 37°C for 18-24 hours. The development of a white precipitation ring around the feather follicle indicated a positive precipitation reaction.

Results

Occurrence of MD: Ten poultry flocks in six districts of Haryana state with a total population of 73,300 were examined for MD during the period from June 2005 to March 2006 (Table 1). These included eight breeder flocks and two layer flocks. The age of the affected birds ranged from 8 weeks to 24 weeks. The disease first appeared at an age ranging from 6 weeks to 23 weeks. As shown in the Table 1, all the birds were vaccinated between 0 day to 4 weeks of age. The morbidity and mortality ranged from 0.66% to 4.44% and 0.24% to 1.00%, respectively. The data reflect that the disease is prevalent in all the six districts of Haryana under study. However, the sampling at each farm is one-time only.

Gross pathology

Liver: Tumorous nodules (pin-point to 2 mm in diameter), grayish-white in color were seen on the liver parenchyma which were firm in consistency and smooth when cut (Fig. 1).

Spleen: Numerous lymphomas, 1 mm to 2mm in diameter, were scattered all over the surface of the spleen. These were whitish in color and firm in consistency (Fig. 2).

Besides liver and spleen, tumorous nodules were also observed in ovary and kidney. Diffuse enlargement of these organs was observed frequently in MD affected birds.

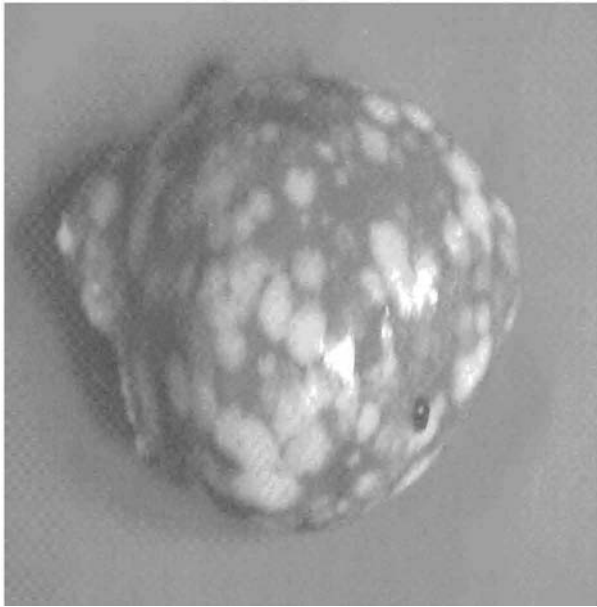


Fig. 2: Spleen of MD affected bird showing numerous whitish tumors

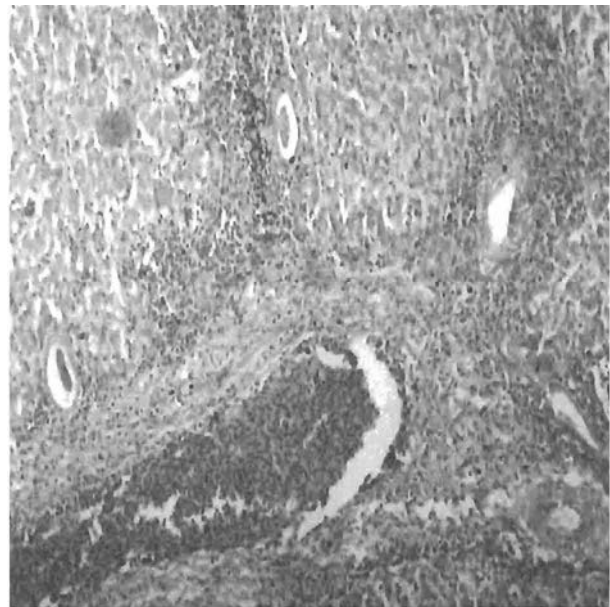


Fig. 4: Section of liver of a bird showing extensive lymphoid cell proliferation due to MD resulting in obliteration of normal hepatic architecture (H and E 50x)

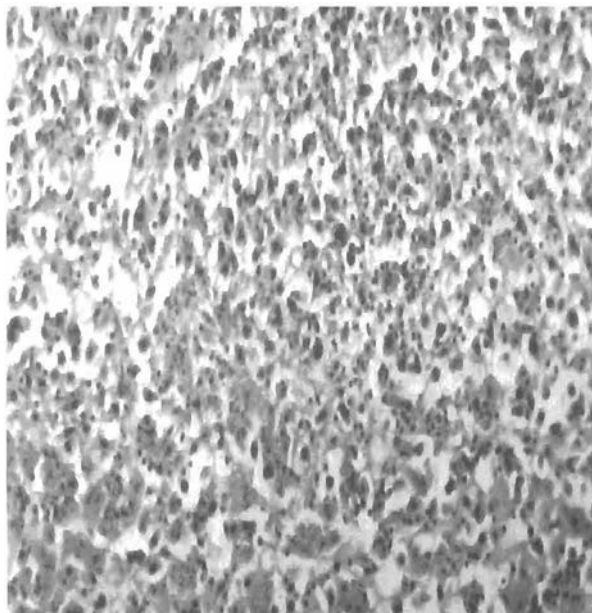


Fig. 3: Liver section of a bird showing diffused lymphoid cell infiltration in parenchyma due to MD (H and E 100x)

Histopathology: The characteristic lesions comprised of infiltration of pleomorphic lymphoid cells such as lymphoblasts, small and large lymphocytes, plasma cells and occasionally MD cells. The lesions were non-capsulated and infiltrative type. The detailed microscopic lesions observed in various organs are as follows:

Liver: Diffuse and massive accumulation of small and large lymphocytes and lymphoblasts was extensively present in the liver (Fig. 3). The massive infiltration and proliferation of neoplastic lymphoid cells resulted into distortion of hepatic architecture, atrophy and obliteration/replacement of the parenchymal cells at and in the vicinity of these accumulations (Fig. 4).

Spleen: Massive proliferation of lymphoblasts and infiltration of small and large lymphocytes were observed in the splenic parenchyma (Fig. 5). The involvement was moderate to extensive. In birds showing extensive involvement of spleen, the differentiation between splenic corpuscles and their germinal centres was completely lost. In milder type of lesions, the proliferation of lymphoid and reticular cells was comparatively less pronounced.

Kidney: Diffuse proliferation and infiltration of lymphoblastic cells was observed in the interstitial connective tissue, accompanied by partial to complete obliteration of renal tubules of cortex and medulla (Fig. 6). In mild cases, there was focal lymphoblastic proliferation in the parenchyma.

Ovary: In affected birds, massive infiltration and proliferation of pleomorphic lymphocytes, plasma cells and undifferentiated mononuclear cells was observed which obliterated the normal parenchyma (Fig. 7). In

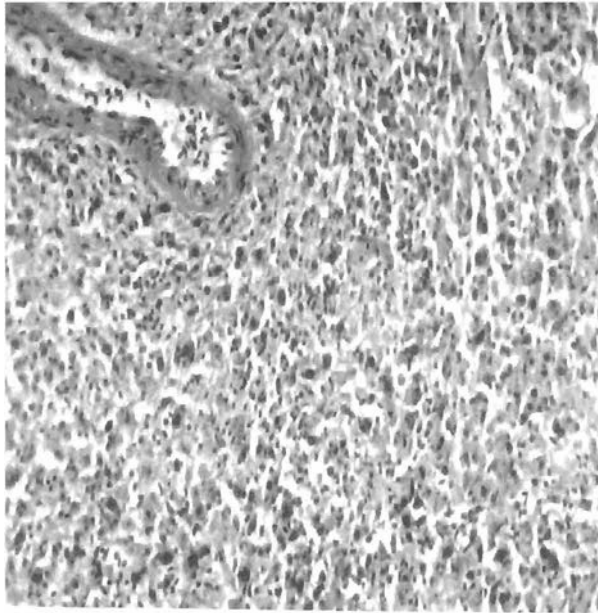


Fig. 5: Spleen tissue of a bird showing pleomorphic lymphoid cell infiltration in parenchyma due to MDV infection H and E 100

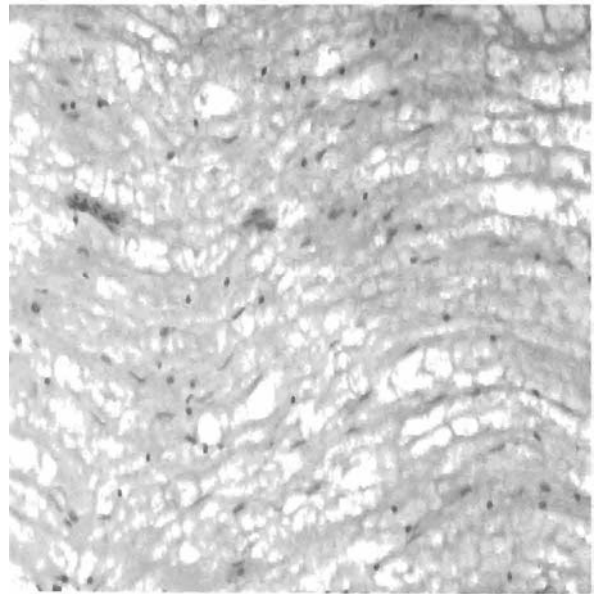


Fig. 7: Section of sciatic nerve of a bird showing diffused infiltration of pleomorphic lymphocytes in endoneurium due to MD H and E 50

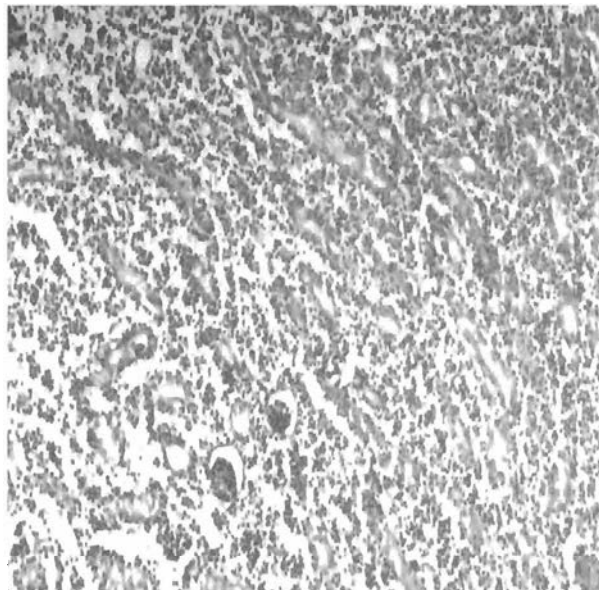


Fig. 6: Section of kidney of a bird showing diffused infiltration of lymphoid cells in interstitial connective tissue due to MD leading to compression of renal tubules and glomeruli H and E 50

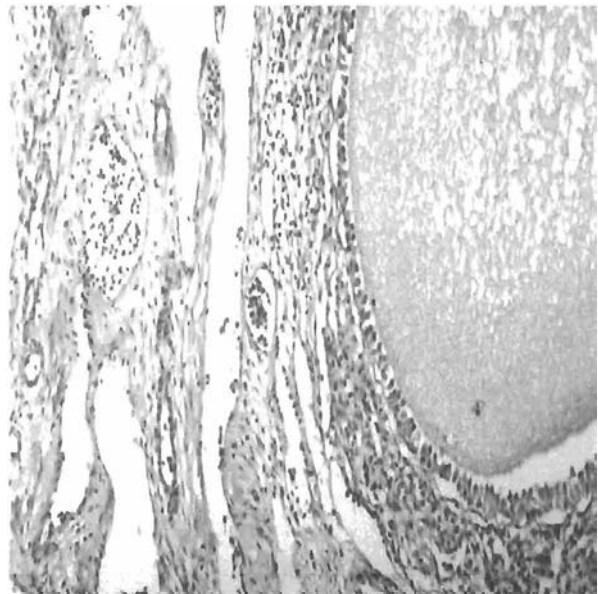


Fig. 8: Section of ovary of a bird showing extensive lymphoid cell infiltration obliterating ovarian parenchyma due to MD (H and E 50)

less severe cases, there was focal infiltration of lymphoid cells and plasma cells in the stromal tissues around the Graffian follicles.

Nerve: Lesions in peripheral nerves consisted of mild to extensive infiltration and proliferation of lymphocytes and lymphoblasts in the endoneurium. The extensive infiltration by mixed (small and large) lymphocytes resulted in complete obliteration of normal architecture of the sciatic nerve (Fig. 8).

Precipitation test: A white precipitating ring around feather follicle tips was observed in agarose gel in samples A, B, E, G and I indicating positive reaction whereas, no precipitation ring was observed in samples C, D, F, H and J.

Discussion

The present study utilizes one-time data regarding the occurrence of Marek's disease in the selective poultry flocks in six districts of Haryana. These poultry flocks had been vaccinated with HVT alone or bivalent vaccine containing HVT (MDV serotype-3) plus SB-1 (MDV serotype-2). Occurrence of the disease in vaccinated poultry flocks calls for investigations into the vaccination failures. We observed morbidity ranging from 0.66%-4.44% and mortality ranging from 0.24%-1.0% in six districts of Haryana during the period of 10 months. The assessment is on the basis of one-time visit at the poultry farms. In fact, such studies on surveillance need to be conducted on regular and continuous basis in order to assess the exact magnitude of the problem and resulting economic losses thereof, in a more meaningful way.

The positivity for MDV in these flocks has been diagnosed by conventional methods (pathological lesions and precipitation reaction). Grossly, tumorous nodules (pin-point to 2 mm in diameter), grayish-white in color, were seen on the liver, spleen, ovary and kidney parenchyma which were firm in consistency. Such nodular or miliary lymphoid tumors in liver, spleen, heart, kidney, proventriculus and gonads in birds suffering from acute MD without involvement of peripheral nerves have been demonstrated by Fugimoto *et al.* (1971). MD lymphomas in visceral organs have been reported by several workers (Purchase and Biggs, 1967; Ahmed, 1982; Rathore *et al.*, 1985; Narang *et al.*, 2003).

Proliferation and infiltration of lymphoblasts and lymphocytes in the sections of liver, spleen, kidney, sciatic nerve and ovary of the affected birds were observed on histopathological examination. These observations are consistent with others (Frazier, 1974; Lobago and Woldemeskel, 2004; Goyal *et al.*, 2006). Payne *et al.* (1976) reviewed the histopathology of lesions of MD as degenerative or proliferative type due to presence of pleomorphic lymphoid cells. We did not observe degenerative type of changes in our study. Mild to extensive infiltration and proliferation of lymphocytes and lymphoblasts in the endoneurium was observed in the peripheral nerves. The extensive infiltration by mixed (small and large) lymphocytes resulted in complete obliteration of normal architecture of the sciatic nerve. However, we did not observe demyelination of sciatic nerve as reported by other workers (Payne, 1985; Cho *et al.*, 1999). Intramyelinic vacuolation has additionally been reported in brain tissue and such vacuolation along with infiltration of macrophages, CD4⁺ and CD8⁺ T-

cells play important role in paralysis (Gimeno *et al.*, 2001; Barrow *et al.*, 2003). Although pathology induced by MDV-1 is rarely pathognomonic and every bird suffering from the disease may not have tumors on skin and visceral organs. But in the present study, visceral tumors on different organs were observed in all the cases and paralysis was also observed in some of the birds.

Another conventional method used in the present study to diagnose MD has been to demonstrate the presence of viral antigens in the feather follicular epithelium of the tips taken from affected birds by immunodiffusion test in agarose gel using a final concentration of 20% HVT antiserum. Since HVT and MDV serotype-1 share cross-reactive antigens, the precipitation reaction was demonstrated but only in five out of ten samples. While all the ten samples were positive for MDV-1 specific nucleotide sequences by PCR assay (data not shown), only five out of these could be detected by precipitation reaction. It is possible that the virus shedding in the negative cases might be due to quite low amount of the virus which may not fall within the detection limit of the precipitation test. On the other hand, PCR being exquisitely sensitive can detect virus with very low copy number of the viral genome. Viral DNA up to the level of picograms can be amplified in the PCR assay.

The precipitation reaction has been used for mass diagnosis of MD (Surtmadzhiev *et al.*, 1980). The other methods include agar gel double-diffusion test (Haider *et al.*, 1970). Onuma *et al.* (1975) demonstrated that an agar-gel precipitation antigen prepared from the skin (feather-Ag) of chicken infected with JM strain of MDV and cell extracts of cultures infected with turkey herpesvirus (HVT-Ag) had one precipitation line in common as the hyperimmune sera to the common antigen is neutralized to a greater extent by homologous antiserum. Surtmadzhiev *et al.* (1980) found precipitation in agar gels was the most convenient method for mass diagnosis of MD when compared to immunofluorescence and indirect haemagglutination tests.

In the PCR assays, we utilized the primer pairs specific to MDV-1 serotypes as well as HVT in a single reaction using DNA extracted from feather follicles. But in all the cases, MDV-1 DNA was amplified and not HVT. This suggests active replication of serotype-1 DNA in the feather follicle epithelium. In the light of this observation, combined with clinical history and lesions, it may be presumed that the precipitation reaction occurred due to MDV-1.

The nucleotide sequence analysis of selective samples suggest that virulent serotype of MDV-1 has emerged in the field (unpublished data) in Haryana and this calls for review of the vaccination strategy in light of the reports of MD in the field in vaccinated flocks and observations made by us based on nucleotide sequencing.

References

- Ahmed, S.I., 1982. Pathology of spontaneous cases of Marek's disease with special reference to nervous system and experimental studies on some aspects of pathogenesis. PhD Thesis, University of Agricultural Sciences, Hebbal, Bangalore.
- Barrow, A.D., S.C. Burgess, K. Howes and V.K. Nair, 2003. Monocytosis is associated with the onset of leukocyte and viral infiltration of the brain in chickens infected with the very virulent Marek's disease virus strain C12/130. *Avian Pathol.*, 32: 183-191.
- Cho, K.O., D. Endoh, M. Onuma and C. Itakura, 1999. Analysis of transcriptional and translational activities of Marek's Disease (MD) virus genes in MD central nervous system lesions in chickens. *Avian Pathol.*, 28: 47-53.
- Fenner, F.J., E.P.J. Gibbs, F.A. Murphy, R. Rott, M.J. Studdert and D.O. White, 1993. *Veterinary Virology* (2nd Ed.), Academic Press, Inc., New York, pp: 359-363.
- Frazier, J.A., 1974. Ultrastructure of lymphoid tissue from chicks infected with Marek's disease virus. *J. Natl. Cancer Inst.*, 52: 829-837.
- Fugimoto, Y., N. Nakagawa, K. Okada, M. Okada and K. Matsukawa, 1971. Pathological studies of Marek's disease. I. The histopathology of field cases in Japan. *Jap. J. Vet. Res.*, 19: 7-26.
- Gimeno, I.M., R.L. Witter, H.D. Hunt, L.F. Lee, S.M. Reddy and U. Neumann, 2001. Marek's disease virus infection in the brain: virus replication, cellular infiltration and major histocompatibility complex antigen expression. *Vet. Pathol.*, 38: 491-503.
- Goyal, D., A. Singh, N. Sood, K. Gupta and N.K. Sood, 2006. Adenocarcinoma of liver with Marek's disease in poultry. *Indian Vet. J.*, 83: 562-563.
- Haider, S.A., R.F. Lapen and S.G. Kenzy, 1970. Use of feathers in a gel precipitation test. *Poult. Sci.*, 49: 1654-1657.
- Lobago, F. and M. Woldemeskel, 2004. An outbreak of Marek's disease in chickens in central Ethiopia. *Trop. Anim. Hlth. Prodn.*, 36: 397-406.
- Luna, L.G., 1968. *Manual of Histologic Staining Methods of the Armed Forces Institute of Pathology*. McGraw Hill Book Company, New York.
- Marquardt, W.W., 1972. Radial immunodiffusion: A simple and rapid method for detection of Marek's disease antigen. *Appl. Microbiol.*, 23: 942-945.
- Nair, V., 2005. Evolution of Marek's disease-a paradigm for incessant race between the pathogen and the host. *Vet. J.*, 170: 175-183.
- Narang, G., N. Jindal and S. Kumar, 2003. Occurrence of Marek's disease in vaccinated layer flocks in Haryana. *Indian Vet. J.*, 80: 590.
- Onuma, M., T. Mikami, T.T. Hayashi, K. Okada and Y. Fujimoto, 1975. Studies of Marek's disease herpesvirus and turkey herpesvirus specific common antigen which stimulates the production of neutralizing antibodies. *Arch. Virol.*, 48: 85-97.
- Payne, L.N., 1985. Pathology. In: *Marek's Disease*, L.N. Payne, (Ed.) Martinus Nijhoff Publishing, Boston, pp: 43-75.
- Payne, L.N., J.A. Frazier and P.C. Powell, 1976. Pathogenesis of Marek's disease. *Int. Rev. Exp. Pathol.*, 16: 59-153.
- Purchase, H.G. and P.M. Biggs, 1967. Characterization of five isolates of Marek's disease. *Res. Vet. Sci.*, 8: 440-449.
- Rathore, B.S., R. Singh and S.S. Khera, 1985. Survey of cases of poultry mortality in India: Based on post-mortem examinations conducted at ten diagnostic centres. *Indian J. Poult. Sci.*, 20: 135-139.
- Surtmadzhiev, K., G. Gerganov, R. Kasabov and B. Kolarova, 1980. Obtaining a specific antigen for the comparative testing of immunological methods in the diagnosis of Marek's disease. *Vet. Med. Nauki.*, 17: 82-88.