

ISSN 1682-8356  
ansinet.org/ijps



INTERNATIONAL JOURNAL OF  
**POULTRY SCIENCE**

**ANSI***net*

308 Lasani Town, Sargodha Road, Faisalabad - Pakistan  
Mob: +92 300 3008585, Fax: +92 41 8815544  
E-mail: editorijps@gmail.com

## Pathological Findings of Highly Pathogenic Avian Influenza Virus A/Duck/Vietnam/12/2005 (H5N1) in Turkeys

M.J. Mehrabanpour<sup>1</sup>, H. Dadras<sup>2</sup>, A. Khodakaram-Tafti<sup>2</sup>, A. Rahimian<sup>1</sup> and A. Toffan<sup>3</sup>

<sup>1</sup>Razi Vaccine and Serum Research Institute, Shiraz, Iran

<sup>2</sup>Poultry Research Center, School of Veterinary Medicine, Shiraz University, Shiraz, Iran

<sup>3</sup>Institute Zooprofilattica Sperimentale Delle Venezie and OIE/FAO and National Reference Laboratory, Italy

**Abstract:** The aim of present study was to identify the clinical signs, gross and histopathological findings in turkeys experimentally infected with highly pathogenic avian influenza virus A/duck/Vietnam/12/2005 (H5N1). Specific pathogens free of white turkeys having 6 weeks old were inoculated with 0.1 mL of the virus with  $10^5$  EID<sub>50</sub>. Death was event at 3 DPI. Gross lesions observed after necropsy were splenomegaly, pulmonary edema, severe congestion in lungs, hyperemia in brain as well as cecal-tonsil and congestion in skeletal muscle. Histopathological finding were multi organ necrosis and/or inflammation. The most consistent and severely affected organs were spleen, lungs, brain, pancreas and cecal-tonsil. It would be worth to mention that the lungs and spleen were most affected organs, among the others grossly and histopathologically, However to our knowledge, this is the first description of histopathological finding of highly pathogenic avian influenza virus A/Duck/Vietnam/12/2005 (H5N1) in turkey.

**Key words:** Influenza, H5N1, pathology, turkeys

### Introduction

Avian Influenza (AI) which is also known as fowl plague is a zoonotic viral disease characterized with respiratory, gastrointestinal and nervous system finding with high morbidity and mortality in the avian species (Jordan, 1996). Birds, especially water birds are the natural reservoir of influenza A viruses and many species of birds, domesticated and wild, can be infected with this virus (Astorg *et al.*, 1994; Swayne, 1997). Virus of 16 hemagglutinin (HA) and 9 neuraminidase subtypes have been identified in aquatic birds. All Avian Influenza (AI) viruses belong to influenza virus a genus from orthomyxoviridae family with segmented, single strand and negative sense RNA genome (Alexander, 2002). The principal replication site of avian influenza virus in birds is in the gastrointestinal tract, where infection typically causes minimal disease and viruses are transmitted faeco-orally. It is reported that there are numerous subtypes of influenza A viruses that infect poultry can be subdivided into two groups, Low Pathogenic Avian Influenza (LPAI) and Highly Pathogenic Avian Influenza (HPAI) viruses, on the basis of severity of the disease produced after experimental infection (Alexander, 2002). Both H5 and H7 subtypes have the ability to evolve into highly pathogenic forms and cause systemic infection (Horimoto and kawaoka, 2001). In the HPAI viruses, the deduced amino acid sequence of the region coding for the cleavage site of precursor hemagglutinin molecule, HA0, contains multiple basic amino acids (Wood *et al.*, 1996). This characteristic appears to be responsible for the virulence of these strains by enabling the virus to replicate throughout the

host body, damaging vital organs, tissues and thus bring about the death of the bird (Rott, 1992). In contrast, Low Pathogenicity Avian Influenza viruses (LPAI) have only two basic amino acids in the cleavage site motif and are capable of replicating only in limited tissues and organs, mainly the respiratory and digestive tracts and do not invade the rest of the body. Evidence collected from recent influenza outbreaks indicate that LPAI may mutate and become HPAI, probably after introduction to poultry (Gracia *et al.*, 1996; Perdue *et al.*, 1997), resulting in extremely complex situations that may have dramatic effects on the poultry industry (Capua *et al.*, 2000). Over the last 30 years, sporadic outbreaks of Highly Pathogenic Avian Influenza (HPAI) viruses among poultry have occurred throughout the world causing significant economic damage to agriculture. HPAI due to H5N1 first occurred in poultry in Hong Kong on three chicken farms in March to May 1997 and then reemerged in November (Shortridge, 1999). Since 2003, over 100 million birds have been destroyed or died during outbreaks and economic costs are estimated to run into several billion dollars (<http://www.FAO.org>). The typical signs and symptoms manifested by poultry infected with highly pathogenic avian influenza viruses include decreased egg production, respiratory signs, rales, excessive lacrimation, sinusitis, cyanosis of skin (especially the combs and wattles), edema of the head and face, ruffled feathers, diarrhea and nervous system disorders. The number of presenting features depends on the species and age of the bird, the virus strain and accompanying infections. Occasionally, a bird will die without showing any signs of illness. Since infected poultry is the source

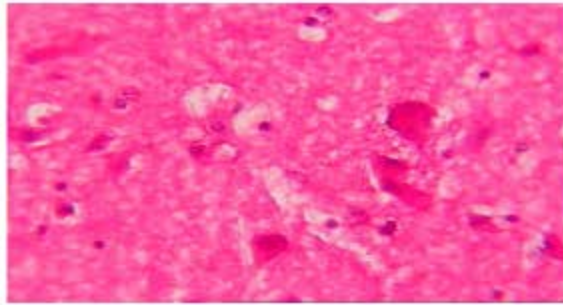


Fig. 1: Brain, 3 DPI. Congestion and neuronal degeneration (H and E,  $\times 200$ )

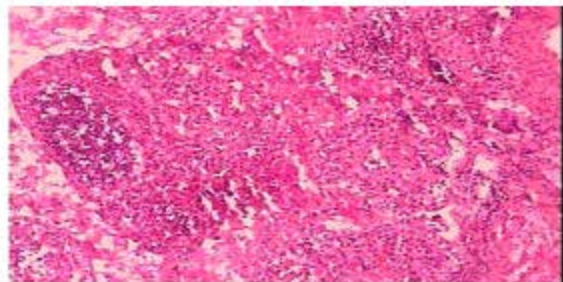


Fig. 2: Intestine, 3 DPI. Hyperemia, edema, mononuclear cell and heterophilic infiltration and lymphoid depletion (H and E,  $\times 80$ )

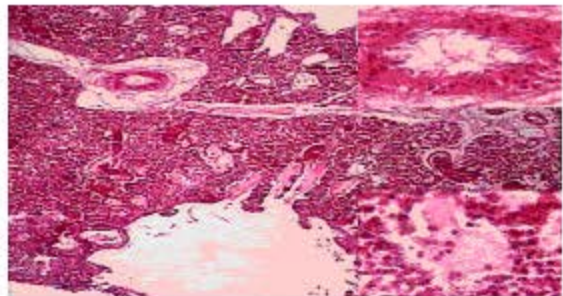


Fig. 3: Lung, 3 DPI. Severe acute exudative interstitial pneumonia with congestion, edema and hemorrhage. (H and E,  $\times 80$ )

of virus for human, mammals and birds, early detection and control of this disease in poultry is mandatory to avoid expansion of the virus in the environment and reduce the risk of viral transmission to humans and other species. The objective of this study was assessing the mortality rate and histopathological lesions in turkeys that inoculated with H5N1. This paper describes the gross and histopathological findings of highly pathogenic A/duck/Vietnam/12/2005 (H5N1) virus in turkeys.

#### Materials and Methods

**Virus:** The influenza A virus (A/duck/Vietnam/12/2005) with Genebank code, ABJ 51676, was obtained from

istituto zooprofilattica sperimentale delle venezie and OIE/FAO and national reference laboratory of Italy. The virus titer was determined by calculating the 50% egg infectious dose ( $EID_{50}$ ) per mL of virus stock, using the method of Reed and Munch. All experimental work with H5N1 viruses was performed in istituto zooprofilattica sperimentale delle venezie and OIE/FAO and national Reference laboratory under a biosafety level 3.

**Turkeys:** Four white turkeys were obtained from istituto zooprofilattica sperimentale delle venezie and OIE/FAO and national Reference laboratory. All birds were inoculated at 6 weeks of age. Serum sample were collected from them prior to inoculation to ensure that the birds were serologically negative for AI as determined with Agar Gel Precipitin (AGP) test. Procedure for AGP followed those previously described (Bread, 1970). All turkeys were housed in stainless steel cabinets ventilated under negative pressure with HEPA-filtered air and maintained under continues lighting. Feed and water were provided ad libitum. General care, was provided as required by the institutional animal care and use committee, as outlined in the guide for the care and use of agricultural animals in agricultural research teaching. All experiments were performed in an USDA certified biosafety level 3 agriculture facilities in istituto zooprofilattica sperimentale delle venezie and OIE/FAO and national Reference laboratory, Italy.

**Animal inoculation and sampling:** All turkeys were divided into two groups: A control group includes one turkey and sample group include 3 turkeys. The turkeys in the sample group were inoculated intranasally with 0.1 ml of inoculums containing  $10^5$   $EID_{50}$  of A/duck/Vietnam/12/2005 (H5N1) virus. Birds of sample group died during 3 DPI and were necropsied for determination of gross lesions. Tissue samples for histopathological examination were collected in 10% buffer formalin. At 14 DPI, serum was collected from controlled bird for AGP to ensure that control remained serology negative to the AIV. The control group was slaughtered after take blood sampling and tissue samples were collected for histopathological examination as described for the sample group.

**Histopathology:** Tissues were fixed by submersion in 10% neutral buffered formalin, routinely processed and embedded in paraffin (Perkins and Swayne, 2003). Sections were made at 7  $\mu$ m and stained with hematoxylin and eosin (H and E).

#### Results

**Saline inoculated control:** There was no mortality in the saline inoculated control bird. Histopathologically, control bird lacked lesions. Control bird sampled at day 14 DPI did not seroconvert to AIV NP as determined by AGP.



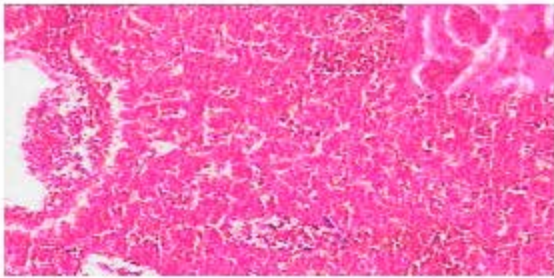


Fig. 4: Liver, 3DPI. Hyperemia and hepatocellular degeneration. Presence of picnotic to karyorrhetic debris, kuppfer cell, hypertrophy and increased numbers of mononuclear cells in the sinusoids (H and E,  $\times 80$ )

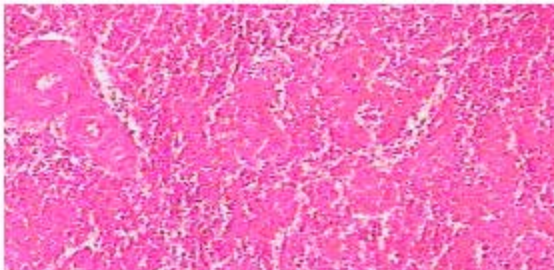


Fig. 5: Spleen, 3 DPI. Severe hyperemia, heterophilic infiltration in sinusoids, fibrinous deposits, lymphoid depletion, necrosis of peri\_ellipsoidal and peri\_arteriolar lymphoid sheets (H and E,  $\times 80$ )

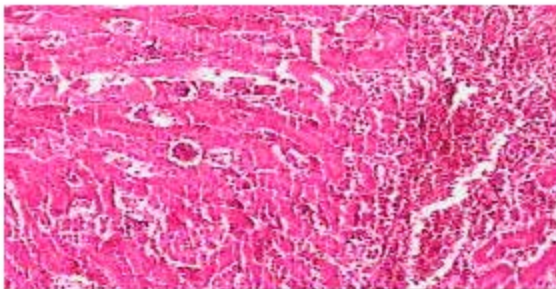


Fig. 6: Kidney, 3DPI. Hyperemia, hemorrhagic and acute cell swelling of proximal tubules (H and E,  $\times 200$ )

**Mortality:** Intranasal administration of A/duck/Vietnam/12/2005 (H5N1) influenza virus resulted in 100% mortality in all turkeys of sample group inoculated in this study. The death was event during at 3 DPI.

**Gross lesions:** In postmortem examinations the turkeys were dehydrated and showed poor physical condition. The livers were enlarged and congested. The lungs were very congested and/or hemorrhagic and the brains showed hyperemia. Splenomegaly and pulmonary edema were observed. Skeletal muscles were congested.

### Histopathology

**Brain:** Congestion, neuronal degeneration and necrosis were determined in the brains, specially, in the substantia grisea region. Privascular edema with lymphocyte and macrophage infiltration, hyperemia and edema were observed in the brains. In medulla midbrain and cerebral and molecular layer there were microgliosis and endothelial swelling. Mild disseminated foci of neuronal and the glial cell necrosis were diagnosed.

**Intestine:** Lesions in the alimentary tract largely confined to lymphoid association areas including esophageal preventricular Junction. The peyer's patches in small intestine and cecal-tonsils were severely affected. Hyperemia, edema, mononuclear cell and heterophilic infiltration were observed in the lamina propria. Degenerative changes were also determined in the crypt epithelial cells in the mucosa. Lymphoid depletion by necrosis was seen.

**Lung:** Severe acute diffuse exudative interstitial pneumonia with congestion and hemorrhage were seen in lungs of the turkeys. Heterophilic and mononuclear infiltrates remained confining within the vascular capillary lumens and interstitium. Also infiltration of macrophages, lymphocytes and few heterophils were seen in the interstitial area in the lung. Inflammatory necrotic and hemorrhagic lesions were present in the lungs.

**Liver:** There was an increase sinusoidal cellularity that was attributed to combined presence of piknotic to karyorectic debris, kuppfer cells hypertrophy and increased numbers of mononuclear cells in the sinusoids. Hyperemia, hepatocellular degeneration and active hepatitis were seen in the affected livers.

**Spleen:** The spleen was one of the most affected organs. Spleen lesions included severe hyperemia, heterophilic infiltration associated with remarkable deposition of fibrinous materials in the red pulp. Mildly lymphocytic depletion and necrosis of peri\_ellipsoidal and peri\_arteriolar sheets were observed in the affected spleens.

**Kidneys:** Hyperemia, severe cell swelling of epithelium of proximal tubules and mononuclear cell infiltration in interstitial tissues especially around of proximal tubules were observed. Degenerative changes and coagulation necrosis of proximal tubules were found in the kidneys.

**Cecal\_tonsils:** Acute hemorrhagic inflammation, edema, lymphoid depletion and diffuse necrosis were seen in the cecal\_tonsils. Necrosis of lymphoid cells in the cecal\_tonsils were prominent.

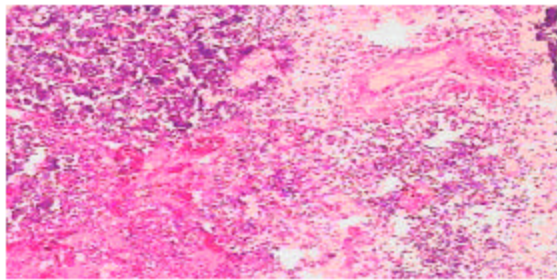


Fig. 7: cecal\_tonsil, 3DPI. Edema, hyperemia, hemorrhage, necrosis of lymphoid cells and lymphoid depletion (H and E,  $\times 200$ )

### Discussion

The results of this study confirm the systemic spread of highly pathogenic influenza virus A/duck/Vietnam/12/2005 in turkeys. This virus affects organs particularly lungs, brain and spleen and the infection is not limited to intestinal tract or respiratory tract. Since infected poultry is the source of virus for mammals, humans and birds, early detection and control of this disease in poultry is mandatory to avoid expansion of the virus in the environment and reduce the risk of viral transmission to human and other mammals (Horimoto and Kawakami, 2001). It had been generally considered that avian influenza viruses characterized as highly pathogenic in chickens did not cause clinical disease or death in ducks or wild aquatic bird (Swayne, 1997; Suarez, 2000) but in turkey cause clinical signs and deaths. Specific histopathologic description for experimental studies vary with individual viruses as a result of variations in inoculum doses, species and strain of bird, route of inoculation and passage history of the virus. Basically, the histological lesion consists of multi organ necrosis and/or inflammation. The most consistent and severely affected organs were lung, brain, pancreas and cecal tonsils. Earlier studies showed that the highly pathogenic avian influenza viruses that were fatal in chicken could replicate in the intestinal tract without showing signs of disease in ducks. Systemic replication of AIV in chickens and turkeys largely defined by the presence of multiple basic amino acids at the hemagglutinin cleavage site. Despite this molecular conformity among H5 and H7 HPAI viruses, considerable variation has been observed in the pathogenicity and transmissibility of these viruses in different avian species, even within the avian order Galliformes. For example, the A/turkey/Ontario/7732/66 (H5N9) influenza virus is moderately pathogenic for chickens and quail, highly pathogenic in turkeys and apathogenic in pheasants, pigeons and ducks. Because of the differences in virulence of AIV demonstrated in domesticated avian species, it is important to consider possible ramifications of interspecies transmission of influenza viruses when different poultry species are

commingled. In the experimental setting, the highly pathogenic H5N1 influenza virus (HK/220) replicated in turkeys and other six gallinaceous species (Perkins and Swayne, 2001). In turkeys, this isolate produced 75% to 100% mortality within 10 days. Depression, mucoid diarrhea and neurological dysfunction were common clinical manifestations of disease. Grossly, the most severe and consistent lesions included splenomegaly, pulmonary edema and congestion and hemorrhages in enteric lymphoid areas, on serosal surfaces and in skeletal muscles. Histological findings of turkeys infected by HK/220 include nasal epithelial necrosis, rhinitis, sinusitis, interstitial pneumonia, lymphoid depletion in spleen, bursa and thymus, Splenitis, phagocyte hyperplasia in bursa and thymus (Perkins and Swayne, 2001). In the present study acute and histopathological, lesions in brain, lungs, spleen, liver and kidneys were observed. In fact the frequency and severity of the lesions in each organ were probably related to tissue tropism, host species and how long the turkeys had survived before deaths. Parenchymal necrosis of multiple organs such as brain, heart and pancreas in turkeys were similar to findings in chicken, quail and ostriches infected with HPAI viruses (Kwon *et al.*, 2005). Some investigators have suggested that the observed tropism of a virus may depend on the site of entry as well as the pathway of spreading the infected host (Young *et al.*, 2006). In this study, severe pathological lesions in the lungs may be due to the way of inoculation. H5N1 viruses have been reported to infect the CNS and cause microscopic changes in the brain of different species of domestic poultry and birds, as well as in mammalian models (Guan *et al.*, 2002; Cauthen *et al.*, 2000; Matrosovich *et al.*, 1999; Lu *et al.*, 1999). In the brain, edema, severe hyperemia and neuronal degeneration were observed. These findings are consistent with non-suppurative meningoencephalitis and myelitis of viral etiology. Enterovirus encephalitis, Newcastle disease or Marek's disease can produce similar lesion in the brain, but widespread systemic infection along with simultaneous outbreak of H5N1 in poultry makes the presumptive diagnosis of HPAI most correct. Probably pathological findings in organs are the results of cytopathic effect of virus. Lymphocellular depletion may have important repercussions for birds that survive infection with the A/duck/Vietnam/12/2005, HK/220 virus or other influenza viruses in that immunosuppression and increased susceptibility to other potential pathogen would result (Wood *et al.*, 1996). In this study we found that A/Duck/Vietnam/12/2005 (H5N1) is highly pathogenic in turkeys. However to our knowledge, this is the first description of histopathological findings of highly pathogenic influenza virus A/duck/Vietnam/12/2005 in the turkey.

### Acknowledgement

This study has been supported by Instituto zooprofilattico sperimentale delle venezie and OIE/FAO and national Reference laboratory Italy. The authors also

like to appreciate Dr Ilaria Capua, Dr. William Dundun, Dr Raffaella Nisi and Dr Philipho Cilloni for their kindly advice and supports. We are also grateful to Razi vaccine and serum research institute, Tehran, Iran for financial support.

## References

- Alexander, D.J., 2002. A review of avian influenza in different bird species. *Vet. Microbiol.*, 74: 3-13.
- Astorge, R.J., M.J. Leon, A. Cubero, A.M. Arenas, M.C. Tradas and A. Perea, 1994. Avian influenza in wild water flow and shorebirds in the Donana national park: serological survey using the enzyme-linked immunosorbent assay. *Avian Pathol.*, 23: 339-344.
- Bread, C.W., 1970. Avian influenza antibody detection immunodiffusion. *Avian Dis.*, 14: 337-341.
- Capua, I., F. Mutinelli, S. Marangon and D.J. Alexander, 2000. H7N1 avian influenza in Italy (1999 to 2000) in intensively reared chickens and turkeys. *Avian Pathol.*, 29: 537-543.
- Cauthen, A.N., D.E. Swayne, S. Schultz-Cherry, M.L. Perdue and D.L. Suarez, 2000. Continued circulation in China of highly pathogenic avian influenza viruses encoding the hemagglutinin gene associated with the 1997 H5N1 outbreak in poultry and humans. *J. Virol.*, 74: 6592-6599.
- Gracia, M., J.M. Crawford, J.W. Latimer, E. Rivera-Cruz and M.L. Perdue, 1996. Heterogeneity in the hemagglutinin gene and emergence of the highly pathogenic phenotype among recent (H5N1) avian influenza viruses from Mexico. *J. Gen. Virol.*, 77: 1493-1504.
- Guan, Y., J.S. Peiris, A.S. Lipatov, T.M. Ellis, K.C. Dyrting, S. Krauss, L.J. Zhang, R.G. Webster and K.F. Shortridge, 2002. Emergence of multiple genotypes of H5N1 avian influenza viruses in Hong Kong SAR. *Proceedings of the National Academy of Sciences*, 99: 8950-8955.
- Horimoto, T. and Y. kawaoka, 2001. Pandemic threat posed by Avian Influenza A viruses. *Clin. Microbiol. Rev.*, 14: 129-149.
- Jordan, F.T.W., 1996. Orthomyxoviridae (Avian influenza). In: Jordan, F.T.W. and M. Pattison. *Poul. Dis.* 4th Edt. W.b. Saunders, London, pp: 156-165.
- Kwon, Y.K., S.J. Joh and M.C. Kim, 2005. Highly pathogenic avian influenza (H5N1) in the commercial domestic ducks of South Korea. *Avian. Pathol.*, 34: 367-370.
- Lu, X., T.M. Tumpey, T.S. Morken, R.N. Zaki, J. Cox and J.M. Katz, 1999. A mouse model for the evaluation of pathogenesis and immunity to influenza A (H5N1) viruses isolated from humans. *J. Virol.*, 73: 5903-5911.
- Matrosovich, M., N. Zhou, Y. Kawaoka and R. Webster, 1999. The surface glycoproteins of H5 influenza viruses isolated from humans, chickens and wild aquatic birds have distinguishable properties. *J. Virol.*, 73: 1146-1155.
- Perdue, M.C., M. Gracia, D. Senne and M. Fraire, 1997. Virulence associated sequence duplication at the hemagglutinin cleavage site of avian influenza viruses. *Virus. Res.*, 49: 173-186.
- Perkins, L.E. and D.E. Swayne, 2003. Varied pathogenicity of a Hong Kong-origin H5N1 avian influenza virus in four passerine species and budgerigars. *Vet. Pathol.*, 40: 14-24.
- Perkins, L.E. and D.E. Swayne, 2001. Pathology of A/CK/HK/220/97 (H5N1) avian influenza virus in seven gallinaceous species. *Vet. Pathol.*, 38: 149-146.
- Rott, R., 1992. The pathogenic determinant of influenza virus. *Vet. Microbiol.*, 33: 303-310.
- Shortridge, K.F., 1999. Poultry and the influenza (H5N1) outbreak in Hong Kong 1997: A bridged chronology and virus isolation. *Vaccine*, 17: 526-529.
- Suarez, D.L., 2000. Evolution of avian influenza viruses. *Vet. Microbiol.*, 74: 15-27.
- Swayne, D.E., 1997. Pathology of H5N2 Mexican avian influenza virus infections of chickens. *Vet. Pathol.*, 34: 557-567.
- Wood, G.W., L. Banks, I. Strong, G. Parosons and D.J. Alexander, 1996. An avian influenza virus of H10 subtype that is highly pathogenic for chicken but lacks multiple basic amino acids at the hemagglutinin cleavage site. *Avian. Pathol.*, 25: 799-806.
- Young, Y., T. Songsern and M. Uprasertkul, 2006. Comparison of pathologic manifestations of influenza A H5N1 Disease in humans and domestic ducks. *J. Hlth. Sci.*, 15: 4-14.