

ISSN 1682-8356  
ansinet.org/ijps



INTERNATIONAL JOURNAL OF  
**POULTRY SCIENCE**

**ANSI***net*

308 Lasani Town, Sargodha Road, Faisalabad - Pakistan  
Mob: +92 300 3008585, Fax: +92 41 8815544  
E-mail: editorijps@gmail.com

## ***In ovo* Vaccine Against Infectious Bursal Disease**

L. Moura,<sup>1,2</sup> V. Vakharia,<sup>2,3</sup> M. Liu<sup>3</sup> and H. Song<sup>3</sup>

<sup>1</sup>Department of Pathobiology, School of Veterinary Medicine, Ross University,  
PO Box 5334, Saint Kitts, West Indies

<sup>2</sup>Center for Agricultural Biotechnology of University Maryland,  
University of Maryland, College Park, Maryland, USA-20742

<sup>3</sup>VA-MD Regional College of Veterinary Medicine, University of Maryland,  
College Park, Maryland, USA-20742

**Abstract:** A recombinant attenuated vaccine against infectious bursal disease virus (IBDV) was administered *in ovo* to 18-day-old embryos. The vaccine was genetically tailored to protect from challenges in the field against classic and variant strains of IBDV. The vaccine virus contains neutralizing epitopes from both classic (D78) and variant strain (GLS), and abrogates expression of the nonstructural protein, VP5 of IBDV. Specific-pathogen-free (SPF) and fertile broiler eggs obtained from a local poultry farm were vaccinated and used to evaluate protection against IBDV-STC challenge. A full dose of the vaccine consisting of  $5.6 \times 10^3$  plaque forming units (pfu) was administered to SPF and broiler embryos. In addition, a half dose of the vaccine containing  $2.3 \times 10^3$  pfu 21 was injected into SPF embryos. The vaccine had no effect on hatchability or first week survival in either broilers or SPF birds, even when high doses were administered. The vaccine generated high antibody titers in chickens with either dosage. All vaccinated groups were protected against mortality. The vaccine did not cause bursal damage and fully protected SPF chickens vaccinated *in ovo* with half dose of the vaccine and broiler chicks that received a full dose of the recombinant vaccine *in ovo*.

**Key words:** Infectious bursal disease virus, vaccine, *in ovo* vaccination, serology, histopathology, chickens

### **Introduction**

Infectious bursal disease (IBD) is an acute, contagious disease caused by a double-stranded RNA virus of the *Birnaviridae* family, IBDV. IBDV genome consists of two segments, A and B. The larger segment A contains two overlapping open reading frame (ORF) that encodes a polyprotein VP2-VP4-VP3 and a nonstructural protein, VP5. Segment B encodes a 97-kDa protein, designated VP1, which represents the viral RNA-dependent RNA polymerase. The virus targets the lymphoid tissue of chickens mainly the BF, causing severe bursal damage, and consequently immunosuppression. Thus, IBD is of major economic importance to the poultry industry.

A strategy for the control of IBD in chicks involves hyper immunization of breeders, which allows them to transmit high levels of maternal antibodies to progeny during the critical first few weeks of life. Although maternal antibodies provide protection during this period, continued protection against IBDV must be maintained before the maternal immunity reaches sub-protective levels by the administration of live vaccines. However, maternal antibodies can neutralize vaccine virus and reduce the viral load needed to induce immunity (Sharma, 1987). In addition, new antigenic variants of IBDV, which appeared during the 1980's, introduced new problems for poultry production. These new field isolates were able to break through neutralizing maternal antibodies induced by standard IBDV vaccines

(Snyder *et al.*, 1992). Since then, these variant strains have been incorporated into commercial inactivated vaccines for broiler breeders. Unfortunately, despite these vaccination measures, IBDV continues to be a problem. Very virulent strains of IBDV, have caused outbreaks of disease with high mortality in Europe and Asia (Nunoya *et al.*, 1992; Van den Berg *et al.*, 1991) despite vaccination programs. In addition, live vaccines that are available for mass vaccination of broilers in the first few weeks of life are not suitable for *in ovo* administration. These vaccines may induce immunosuppression during late stages of incubation, when the embryo is highly susceptible to infection.

Therefore, in an effort to aid in the control of this disease, a recombinant IBD vaccine virus that can protect against both classical and variant strains was created in our laboratory, using reverse genetics system (Liu, 2003). This virus, designated as rD78GLSNSÄ, is deficient in the expression of VP5 nonstructural protein (NS). It grows one log lower than the parental viruses, and exhibits decreased cytotoxic and apoptotic effects in cell culture. This virus fails to induce any pathological lesions in the bursa of infected three-week-old chickens. In addition, vaccinated birds challenged with classic (STC) and variant (GLS) strains of IBDV were fully protected.

In this report, we evaluate the potential use of this recombinant attenuated virus *in ovo* to protect SPF as

Table 1: Experimental design and effect of *in ovo* vaccination of rIBDV on hatchability and first week survival of hatched chicks

Group	Egg type	Vaccine dose <sup>a</sup> (pfu)	No. of eggs	No. of chicks hatched (%)	1 <sup>st</sup> week survival rate (%)
A	SPF <sup>b</sup>	5.6x10 <sup>3</sup>	27	25/27 (92.5)	24 (96)
B		2.3x10 <sup>3</sup>	27	25/27 (92.5)	25 (100)
C		NV/CH <sup>c</sup>	17	16/17 (94.1)	16 (100)
D		NV/NCH <sup>d</sup>	17	17/17 (100)	17 (100)
E	Broilers <sup>e</sup>	5.6x10 <sup>3</sup>	24	18/24 (75)	17 (94.4)
F		NV/CH	9	7/9 (77.8)	7 (100)
G		NV/NCH	9	8/9 (88.8)	8 (100)

<sup>a</sup>18-day-old embryos received 0.2 mL of rIBDV vaccine containing either 5.6x10<sup>3</sup> or 2.3x10<sup>3</sup> pfu.

<sup>b</sup>specific-pathogen-free fertile eggs. <sup>c</sup>non-vaccinated, challenged control group. <sup>d</sup>non-vaccinated, non-challenged control group.

<sup>e</sup>fertile broiler eggs from a poultry farm.

well as commercial chicks from IBDV challenges. Fertile eggs were obtained from a local poultry farm that routinely immunizes broiler breeders with live and inactivated vaccines to confer high levels of maternal antibodies to the progeny. The vaccination program for these breeders consisted of one live IBDV vaccination at 4 weeks of age, and booster vaccinations at 10 and 18 weeks of age with an inactivated oil-emulsion vaccine containing standard and variant strains of IBDV.

Two different doses of this recombinant vaccine were evaluated in SPF eggs in the absence of maternal antibodies. A full dose was used to vaccinate broiler embryos with maternal antibodies to verify its ability to break through antibody barrier and generate a protective immune response against IBDV challenges.

## Materials and Methods

**Cells and viruses:** Vero cells were maintained in medium 199 (M199) supplemented with 5% fetal bovine serum (FBS) at 37°C in a humidified 5% CO<sub>2</sub> incubator and used for propagation of the virus. Primary chicken embryo fibroblast (CEF) cells were prepared as described previously (Mundt and Vakharia, 1996). Briefly, ten-day-old embryos from SPF chickens were aseptically removed and cut into pieces. The tissues were rinsed in HBSS and digested with 0.2% trypsin at 37°C for one h to produce a single cell suspension. The suspension was filtered through gauze and washed twice with HBSS. The cells were grown in M199 and F10 (1:1 v/v) with 10% FBS. Secondary CEF cells, used for virus titration, were maintained in growth medium consisting of M199 and F10 with 5% FBS.

**Propagation and purification of IBDV:** The recombinant IBD vaccine virus, rD78GLSNSA, was prepared as described (Liu, 2003). Large amounts of this virus were grown in Vero cells as stock for *in ovo* inoculations, and stored at -20°C.

**Plaque assays:** Virus stocks propagated in cell culture were titered by plaque assay as described earlier (Mundt and Vakharia, 1996). Briefly, the infected supernatant was diluted in ten-fold increments in MEM without fetal calf serum (FCS). Confluent monolayers of CEFs were

infected with serial dilutions of viruses (10<sup>-4</sup> to 10<sup>-7</sup>, 0.1 mL/well). After 1 h adsorption at RT, the media was removed and the monolayer overlaid with 3 mL of 1% SeaPlaque agarose (Difco) containing 10% tryptose phosphate broth, 2% FCS, 0.112% NaHCO<sub>3</sub>, 100 unit/mL penicillin, 100 µg/mL streptomycin and 0.25 µg/mL fungizone. On day 3, the agarose overlay was removed and cells were fixed with formalin. After fixing, the cells were stained with crystal violet and plaques were counted and expressed as plaque forming units (pfu/mL).

**Experimental design:** The experimental groups and controls are shown in Table 1. A larger number of eggs were utilized for treatment groups A, B, and E (vaccinated) because of a possible adverse effect due to vaccination. Sample size was calculated accordingly to protocol previously approved. SPF and commercial fertile broiler eggs of 18 days of embryonation were inoculated using a full dose of rIBDV (group A, and E). Each embryo received 5.6x10<sup>3</sup> pfu/0.2 mL of rD78GLSNSA. Another group of SPF eggs received only half a dose of this virus, which was 2.3x10<sup>3</sup> pfu/0.2 mL (group B). The negative controls consisted of non-vaccinated, unchallenged SPF and commercial embryos (groups D, and G). The challenge control groups consisted of SPF and commercial eggs, which did not receive the vaccine and were challenged two weeks post-vaccination (groups C, and F). After *in ovo* vaccination, all eggs were sealed with adhesive tape and re-incubated.

The SPF embryos were free of any other immunosuppressive diseases that could compromise our results, such as adenoviruses, and chicken anaemia virus. The commercial eggs were obtained from Sunrise farms, Catskill, NY.

After 21 days of incubation, all hatched chicks were housed in BL-2 isolators at Gudelsky Veterinary Center, University of Maryland. Two weeks post-hatch, all birds were bled and challenged with STC strain (0.2 mL by the ocular and nasal route - 10<sup>3</sup> EID<sub>50</sub>) of IBDV, except group D, and G. At ten days post-challenge, all the remaining birds were anesthetized, bled, and humanely euthanized. Spleen and bursa were collected and

Table 2: Protection indices from birds vaccinated with rIBDV-attenuated vaccine and challenged with the classic STC strain of IBDV

Group	VN Log <sub>2</sub> <sup>a</sup>	AC ELISA <sup>b</sup>	B/B weight <sup>c</sup>	Lesion Score	VN Log <sub>2</sub> <sup>d</sup>	Birds w/ clinical signs/challenged <sup>e</sup>	ELISA (GMT) <sup>f</sup>
A	8.76	2/12	6.04 ± 1.2 <sup>g</sup>	2.0	7.90	0/20 (100) <sup>h</sup>	6200/10000
B	9.25	0/11	5.27 ± 1.5	0	5.47	0/18 (100)	6800/11300
C	4.00	11/12	4.31 ± 1.1	5.0	2.33	12/12 (NA) <sup>i</sup>	0/150
D	3.16	0/12	5.35 ± 1.2	0	4.00	0/12 (NA)	0/0
E	9.46	0/11	2.14 ± 0.8	0	7.58	0/17 (100)	9100/6050
F	5.3	8/9	1.48 ± 0.6	4.6	6.8	10/12 (NA)	3800/900
G	5.4	0/9	2.31 ± 0.5	0	6.8	0/12 (NA)	3820/2200

<sup>a</sup>virus neutralization results two weeks post-vaccination. <sup>b</sup>number of birds that had antigen detected as measured by antigen capture ELISA. <sup>c</sup>(bursa weight/body weight) × 1000. <sup>d</sup>virus neutralization results ten days post-challenge. <sup>e</sup>at two weeks post-vaccination birds received 0.2 mL of 10<sup>3</sup>EID<sub>50</sub>% of IBDV-STC challenge. <sup>f</sup>ELISA geometric mean titers. <sup>g</sup>mean of bursa/body weight ratios and standard deviation. <sup>h</sup>percentage of protected birds. <sup>i</sup>not applicable.

bursa/body weight recorded. The bursae were sectioned in half. Spleen and bursa halves were placed in 10% buffered formalin for histology. The other half of the bursa was stored frozen for later testing by antigen capture-ELISA (AC-ELISA).

The antibody levels in serum samples collected at 2 weeks post-vaccination, and 10 days post-challenge, were determined by ELISA and virus neutralization (VN). A commercial ELISA kit was used (Synbiotics, San Diego, CA). The frozen bursae were processed as described earlier and probed for antigen detection by AC-ELISA (Synbiotics, San Diego, CA). Fixed tissues were sectioned at American Histolabs (Gaithersburg, MD) and stained by hematoxylin-eosin (HE).

**Virus neutralization assay (VN):** Serum samples were heat-inactivated at 56°C for 1 h and diluted in serial two-fold dilutions. Each dilution was mixed with 100 TCID<sub>50</sub> of rIBDV and incubated for 1 h at 37°C. The mixture was added to 85-90% confluent monolayer of Vero cells, grown in 96-well tissue culture plates (Costar, Ithaca, NY). All plates were incubated for 5-6 days until the presence of CPE was detected in the virus control wells. Normal serum from SPF birds was used as a negative control and a polyclonal anti-IBDV (SPAFAS) was used as a positive control. Anti-IBDV titers were determined 5-6 days later, averaged, and expressed as log<sub>2</sub>.

## Results

**Vaccine safety - Hatchability and first week survival rates** are shown in Table 1. The hatchability rates in SPF eggs from group A and B were similar (92.5%), indicating that the vaccine is safe even when higher doses were administered. The percentages of hatched birds and first week survival were not significantly different from vaccinated groups and control non-vaccinated. The hatchability rates in broilers were lower than SPF embryos. However, we do not believe the vaccine caused these changes, since non-vaccinated birds also exhibited lower hatchability (88.8%). We attributed it to stress caused by temperature shock during transportation. Embryonated eggs were removed from incubators at 37°C and transported at 22°C for 2 h. The

hatchability in this experiment is much higher than the average observed in the poultry industry (83%) because all unviable eggs were discarded prior to *in ovo* vaccination.

**Vaccine protection:** Results of the IBDV challenge studies are shown in Table 2. All vaccinated birds were fully protected against IBDV-STC. The bursa/body weight ratio was calculated as bursa weight/body weight × 1000. The vaccinated group was considered protected if all bursa/body weight ratios were equal or higher than 2SD (standard deviation) of the non-vaccinated, non-challenged control group. The mean for the SPF control (group D) was 5.35 (2SD=2.48). Thus, all SPF vaccinated birds with either dose were considered protected. Additionally, vaccinated broilers were also considered fully protected.

Table 2 also shows results from antigen detection assessed by AC-ELISA (Synbiotics, San Diego, CA) seven days post-challenge. IBDV antigen was detected in two SPF birds that were vaccinated with full dose of the vaccine. Viral antigens could not be detected in the BF of birds that received half dose of the vaccine or in broilers that received full dose. Antigen was detected in SPF challenge control group (11/12). As expected, no IBDV antigen could be detected in the negative control birds (group D, and G), whereas non-vaccinated, challenged broilers (8/9) were positive by AC-ELISA at 10 days post-challenge.

**Antibody responses:** The antibody responses as measured by commercial ELISA are shown in Table 2 as geometric mean titer. At two weeks post-vaccination, all vaccinated groups had significantly higher antibody titers ( $p < 0.05$ ) than non-vaccinated groups by either test. As expected, all non-vaccinated SPF birds had negative titers for IBDV at 2 weeks post-vaccination. The non-vaccinated, commercial broilers had maternal antibody titers ranging from 455 to 5455 at 2 weeks of age. At 10 days post-challenge, all SPF vaccinated groups (full and half dose) showed significantly ( $p < .05$ ) higher titers than the same groups at two weeks post-vaccination. However, broilers receiving a full vaccine dose did not

show an antibody increase after challenge as measured by ELISA. Antibody responses at 2 weeks post-vaccination in SPF birds that received half dose of the vaccine were relatively higher than SPF birds vaccinated with a full dose. The level of protective maternal antibodies in the non-vaccinated, unchallenged broilers seemed to wane slightly after challenge. Antibody responses were not detected in SPF non-vaccinated, challenged control birds after 10 days of challenge. This result is expected considering that a primary immune response would take at least 2 weeks to be detected.

The results from virus neutralization assay are expressed as Log<sub>2</sub> in Table 2. All vaccinated groups showed protective levels (between 4-6 Log<sub>2</sub>) of antibodies 2 weeks post-vaccination. Non - vaccinated control broilers showed maternal antibody levels (4.8 Log<sub>2</sub>) lower than normal for the first few weeks of life. All control groups continued to exhibit only low levels of antibodies 10 days post-challenge. As expected, all vaccinated SPF birds showed higher humoral responses after challenge. Vaccinated broilers also showed higher antibody response 10 days post-challenge (7.5 to 9.46).

**Histopathology:** The averages of microscopic lesions are shown in Table 2. At 2 weeks post-vaccination, birds from the control and treatment groups that received either full dose or half dose did not show microscopic lesions in the BF. At 10 days post-challenge, SPF non-vaccinated birds that were challenged showed severe lymphocyte depletion, undulation in the epithelium, intra and interfollicular epithelial cysts, and degeneration of follicular structure (Fig. 1A, Table 2 group C). SPF birds that received full dose of the vaccine (Fig. 1B) showed a mild degree of B-cell depletion, localized in a few follicles. The lesion score for this group was 2.0. SPF birds vaccinated with a half dose of the vaccine did not show histopathological lesions in the bursa (Fig. 1C, Table 2 group B). The control non-vaccinated, challenged broilers showed bursal lesions. However, they were much milder than SPF challenged controls (Fig. 1D, Table 2 group F). In addition, broilers that received a full dose of the vaccine showed normal bursae after 10 days post IBDV challenge (Fig. 1E, Table 2 group E).

The spleens of SPF non-vaccinated, challenged birds showed hemorrhages and lymphocytic depletion. Non-vaccinated broilers that were challenged showed a milder but more generalized reduction of lymphocytes throughout the entire organ. No lesions were observed in the spleens from vaccinated groups (data not shown).

## Discussion

IBD in chickens was first described in 1962 (Cosgrove, 1962). IBDV is a lymphotropic virus able to cause mainly humoral immunosuppression in chickens infected before

three weeks of age (Sharma and Lee, 1983). Efficacy studies with commercial live vaccines *in ovo* against IBDV caused acute clinical signs of the disease when administered in a full dose. Additionally, hatchability was severely decreased (Sharma *et al.*, 2001). Attempts to administer commercial vaccines in a lower dosage induced less mortality, however, microscopic bursal lesions persisted (Lukert and Saif, 1997). In addition, since 1980 new subtypes of serotype I, called 'variant strains' have been isolated in the US (Snyder *et al.*, 1988). Active or passive immunity mediated by vaccination with classic strains do not protect against variant strains (Rosenberger *et al.*, 1985).

In this study, a recombinant live attenuated vaccine that expresses multiple neutralizing epitopes of classical and variant strain of IBDV was evaluated in 18-day-old SPF and commercial embryos. SPF embryos were injected with a full or half dose of the virus through the amniotic cavity. Two weeks post-vaccination, birds were challenged with an IBDV-STC strain. Commercial broilers vaccinated with a full dose and SPF embryos vaccinated with half dose were fully protected. In addition, no significant microscopic bursal lesions were observed in these groups. On the other hand, SPF birds that received a full dose of the vaccine *in ovo* exhibited microscopic lesions similar to non-vaccinated, challenged control group.

No detrimental effects on hatchability with either dosage used were observed. However, histopathological results suggested that a higher dose of the vaccine given to birds that lack sufficient maternal antibody might still be virulent even though clinical signs of IBD were not observed. Our findings agree with previous research in SPF and broiler embryos vaccinated with three commercial intermediate vaccines *in ovo*. Microscopic bursal lesions were observed even when half of the recommended dose was used (Giambone *et al.*, 2001). In a previous report, microscopic lesions were not observed when a full dose of rIBDV live attenuated virus was used to vaccinate two-week-old chickens ocularly (Liu, 2003). In this study, bursal lesions were observed in SPF birds, lacking maternal antibodies that received a full dose of the vaccine when delivered *in ovo*. At 10 and 15 days of embryonation, prebursal stem cells are migrating via the blood supply from the spleen to the BF (Masteller and Thompson, 1994). Consequently, at eighteen days of incubation, when *in ovo* vaccination occurred, the avian immune system was not fully developed and a viral infection that targets this organ may have caused irreversible damage.

A second aim of this study was to evaluate the efficacy of this chimeric virus as a potential vaccine in the presence of maternal antibodies. Commercial broilers were from breeder flocks vaccinated with classic and variant strains of IBDV. Vaccinated broilers had significant higher antibody titers than non-vaccinated broiler control group at two weeks post vaccination. According to



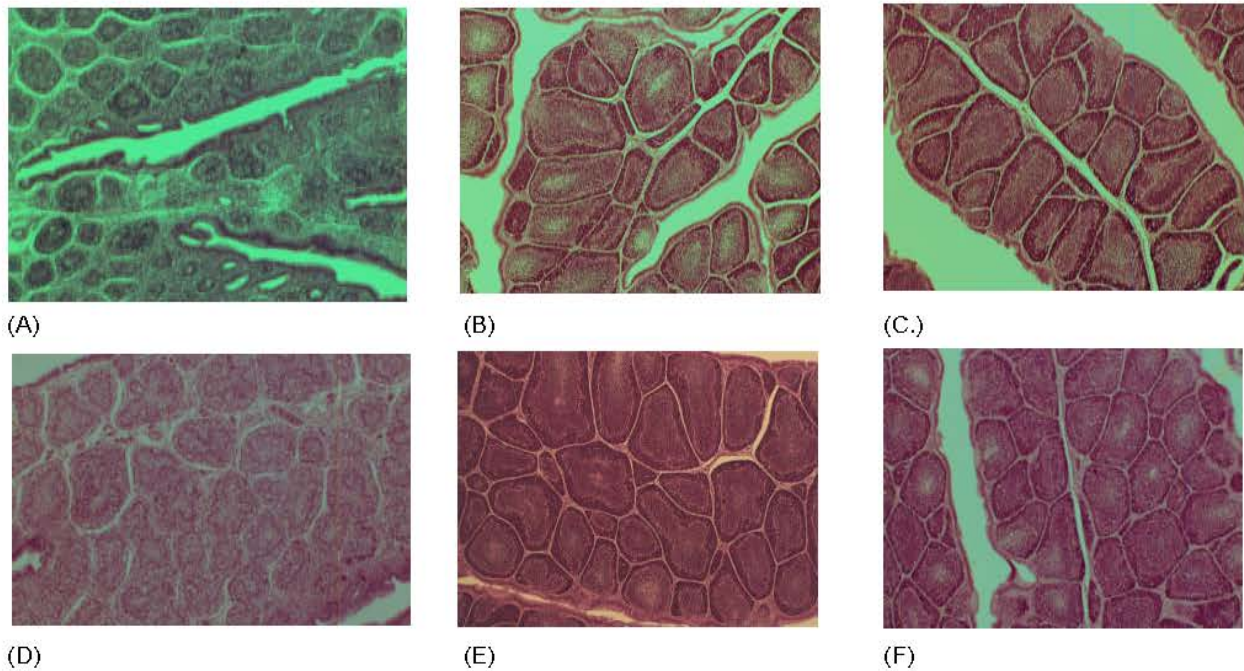


Fig. 1: Sections of the BF stained by hematoxylin-eosin for histopathological examination 10 days post-challenge with IBDV-STC. Eighteen-day-old embryos were inoculated with either  $5.6 \times 10^3$  pfu (full dose) or  $2.3 \times 10^3$  pfu (half dose) of rD78GLSNSÄ. A) non-vaccinated, challenged SPF, shows severe lymphocytic necrosis and heterophilic inflammation; B) vaccinated (full dose) and challenged SPF birds shows lymphocytic depletion (indicated by arrows); C) vaccinated (half dose) and challenged SPF shows no visible microscopic lesions; D) non-vaccinated, challenged broiler shows lymphocytic necrosis and loss of follicular structure; E) unvaccinated, and non-challenged control broiler shows no microscopic lesions; F) vaccinated (full dose) and challenged broiler shows no microscopic lesions.

Lutticken *et al.*, 1994, these findings indicate that the vaccine was able to breakthrough maternal antibody barrier and seroconvert. Similar results were obtained in broilers vaccinated with a chimeric IBDV vaccine 14 days post-vaccination (Mundt *et al.*, 2003). However in their studies, the challenge using classic and variant viruses induced chronic lesions in BF of vaccinated broilers with a chimeric virus expressing classic and variant epitopes of GLS and D78 IBDV strains (Mundt *et al.*, 2003).

**The use of the invention:** The novelty of this work is its use *in ovo* to vaccinate commercial broilers in the presence of maternal immunity against IBDV. This study suggests the potential use of rD78GLSNSÄ as a vaccine candidate for *in ovo* delivery. This vaccine was shown to be safe, highly immunogenic, and protective against STC-IBDV challenge.

## References

- Cosgrove, A.S., 1962. An apparently new disease of chickens-avian nephrosis. *Avian Dis.*, 6: 385-389.
- Giambrone, J.J., T. Domitorio and T. Brown, 2001. Safety and efficacy of *in ovo* administration of infectious bursal disease viral vaccines. *Avian Dis.*, 45: 144-148.
- Liu, M., 2003. Pathogenesis and apoptosis study of infectious bursal disease virus (IBDV) and development of a bivalent IBDV vaccine. Ph.D. dissertation. University of Maryland, College Park, Maryland.
- Lukert, P.D. and Y.M. Saif, 1997. Infectious bursal disease virus. In *Disease of Poultry*, (B.W. Calnek, et al., ed.) 10th Ed., pp 721-738. Iowa State University Press, Ames Iowa.
- Lutticken, D., A.A.W.M. van Loon and M.J.H.S. de Vries, 1994. Determination of the breakthrough titre of IBD vaccines or IBD challenge strains in MDA+ chickens. In *Proceedings of the International Symposium on Infectious Bursal Disease and Chicken Infectious Anaemia*. Rauschholzhausen, Germany, p 272-278.
- Masteller, E.L. and C.B. Thompson, 1994. B cell development in the chicken. *Poult. Sci.*, 73: 998-1011.
- Mundt, E., N. de Haas and A.A.W.M. van Loon, 2003. Development of a vaccine for immunization against classical as well as variant strains of infectious bursal disease virus using reverse genetics. *Vaccine*, 21: 4616-4624.

- Mundt, E. and V.N. Vakharia, 1996. Synthetic transcripts of double-stranded birnavirus genome are infectious. *Proc. Natl. Acad. Sci. USA*, 93: 11131-11136.
- Nunoya, T., Y. Otaki, M. Tajima, M. Hiraga and T. Saito, 1992. Occurrence of acute infectious bursal disease with high mortality in Japan and pathogenicity of field isolates in specific-pathogen-free chickens. *Avian Dis.*, 36: 597-609.
- Rosenberger, J.K., S.S. Cloud, J. Gelb, E. Odor and S.E. Dohms, 1985. Sentinel birds survey of Delmarva broiler flocks. In: *Proceedings of the 20th National Meeting on Poultry Health and Condemnation*. Ocean City, MD, p: 94-101.
- Sharma, J.M., 1987. Embryo vaccination of chickens with turkey herpesvirus: characteristics of the target cell of early viral replication in embryonic lung. *Avian Path.*, 16: 567-579.
- Sharma, J.M. and L.F. Lee, 1983. Effect of infectious bursal disease on natural killer cell activity and mitogenic response of chicken lymphoid cells: role of adherent cells in cellular immune suppression. *Infect. Immun.*, 42: 747-754.
- Sharma, J.M., Y. Zhang, D. Jensen, S. Rautenschlein and H.Y. Yeh, 2001. Field trial in commercial broilers with a multivalent *in ovo* vaccine comprising a mixture of live viral vaccines against Marek's disease, infectious bursal disease, Newcastle disease, and Fowl pox. *Avian Dis.*, 46: 613-622.
- Snyder, D.B., D.P. Lana, P.K. Savage, F.S. Yancey, S.A. Mengel and W.W. Marquardt, 1988. Differentiation of infectious bursal disease viruses directly from infected tissues with neutralizing monoclonal antibodies: evidence of a major antigenic shift in recent field isolates. *Avian Dis.*, 32: 535-539.
- Snyder, D.B., V.N. Vakharia and P.K. Savage, 1992. Naturally occurring-neutralizing monoclonal antibody escape variants define the epidemiology of infectious bursal disease viruses in the United States. *Arch. Virol.*, 127: 89-101.
- Van den Berg, T.P., M. Gonze and G. Meulemans, 1991. Acute infectious bursal disease virus in poultry: isolation and characterization of a highly virulent strains. *Avian Pathol.*, 20: 133-143.

---

**Abbreviations:** ORF = open reading frame; IBDV = infectious bursal disease virus; BF = bursa of Fabricius; SPF = specific pathogen free; FBS = fetal bovine serum; BL-2 = biological safety level 2.