

ISSN 1682-8356
ansinet.org/ijps



INTERNATIONAL JOURNAL OF
POULTRY SCIENCE

ANSI*net*

308 Lasani Town, Sargodha Road, Faisalabad - Pakistan
Mob: +92 300 3008585, Fax: +92 41 8815544
E-mail: editorijps@gmail.com

Ochratoxicosis in Broiler Chickens: Functional and Histological Changes in Target Organs

M.A. Elaroussi¹, F.R. Mohamed², M.S. Elgendy³,
E.M. El Barkouky¹, A.M. Abdou² and M.H. Hatab¹

¹Department of Biological Applications, Nuclear Research Center,
Atomic Energy Authority, Abou - Zaabal, Egypt

²Department of Animal Production, Faculty of Agriculture, Cairo University, Cairo, Egypt

³Department of Histology, Faculty of Medicine, Fayoum University, Fayoum, Egypt

Abstract: This experiment was conducted to evaluate the effects of ochratoxin A (OTA) on the function and histology of the liver, kidney and bursa of broiler chickens fed OTA contaminated rations. Two hundred forty one-day-old male Ross broiler chicks were used, they were randomly divided into 3 dietary experimental groups of 80 birds and given rations containing 0 (control), 400 or 800 µg OTA/Kg feed. The chicks were maintained on these treatments through 5 weeks of age with feed and water available for *ad libitum* intake throughout the experimental duration. Dietary OTA contamination at both levels resulted in significant increase ($P < 0.05$) in the relative weights of kidney and liver and in serum glutamic oxaloacetic transaminase (GOT), glutamic pyruvic transaminase (GPT), uric acid and creatinine levels in OTA treated birds as compared to the control. A significant decrease ($P < 0.05$) was found in bursa of Fabricius weight, serum antibody (Ab) titres against Newcastle disease virus (NDV) and in serum total protein, albumin and globulin of the OTA treated groups as compared to the control. Histological examination revealed marked degenerative changes in the kidney and bursa and mononuclear cell infiltration was recorded in the liver of broilers exposed to OTA contamination. All of the above changes became more evident with the higher OTA level and with prolongation of experimental period. Therefore, these results indicate that exposure to OTA at concentration ≥ 400 ppb could adversely affect kidney, liver and bursa function and histology and thus broiler performance and health.

Key words: Broiler, ochratoxin, kidney, liver, bursa of fabricius

Introduction

Ochratoxins is a general term describing a family of toxic compounds consisting of three members, A, B and C, they are structurally related and produced as a secondary metabolites of several species included in the fungal genera *Aspergillus* (Varga *et al.*, 1996; Bayman *et al.*, 2002) and *Penicillium* (Larsen *et al.*, 2001). Ochratoxin A (OTA) is the most commonly detected and most toxic member of that family based on the lethal dose required to kill 50% of birds (LD50) and minimal growth inhibitory concentration (Chang *et al.*, 1979). Variations in sensitivity towards OTA exists among avian species, as LD50 ranges from 0.5 to 16.5 mg/Kg body weight (BW) for ducks and Japanese quail, respectively, with chickens at 2-4 mg/Kg BW (Peckham *et al.*, 1971). O'Brien *et al.* (2001) extended the species-differences in susceptibility to OTA induced disease development to sex- and cell type-differences as well. OTA within a wide range of contamination (130µg-3.9mg OTA/Kg) in poultry diets leads to reduction in growth rate, feed consumption and feed efficiency (Peckham *et al.*, 1971; Huff *et al.*, 1988; Mohiuddin *et al.*, 1993; Raju and Devegowda, 2000; Santin *et al.*, 2003; Stoev *et al.*, 2004; Elaroussi *et al.*, 2006) and increased mortality (Kumar *et al.*, 2003; Elaroussi *et al.*, 2006).

One of the profound effects of OTA is its ability to alter the function of the immune system in avian species, causing severe leucocytopenia (Chang *et al.*, 1979; Stoev *et al.*, 2000; Elaroussi *et al.*, 2006), impaired complement activity (Campbell *et al.*, 1983), reduction in immunoglobulins (Dwivedi and Burns, 1984) and several functional properties of macrophages and heterophils (Politis *et al.*, 2005) and finally it causes atrophy of the lymphoid organs along with depletion of lymphocytes (Stoev *et al.*, 2000 and 2004; Kumar *et al.*, 2004). In contrast, OTA causes enlargement of the kidney and subsequently impairing its function, therefore, considered as a nephrotoxic mycotoxin in birds (Stoev *et al.*, 2004).

OTA contaminates agricultural products and due to its long half life it accumulates in food, representing a serious threat to human and animal health throughout the world since it has been implicated in a diverse range of toxicological effects (O'Brien and Dietrich, 2005). Realizing that OTA is commonly found in cow's milk, human milk and corresponding blood samples (Breitholtz - Emanuelsson *et al.*, 1993), forced many countries to set maximum permissible OTA occurrence in agricultural products. The problem of ochratoxicosis

exists in Egypt, as Abdelhamid (1990) described the occurrence of high OTA and other mycotoxins contamination in various feed stuffs and Wafa *et al.* (1998) examining patients with end stage renal failure, nephritic syndrome and urogenital cancers; found higher levels of OTA in serum of those patients than the control group without renal pathology.

The aim of this study was to elucidate that the mechanism of action of OTA-mediated toxicity in broiler chickens involves inducing renal, hepatic and immunological functional and histological changes. Analysis of the relative parameters in the kidney, liver and bursa of Fabricius were undertaken to establish the fact that these three organs are targets for OTA-induced toxicity. OTA contaminated diets at known concentrations similar to those that occur in the field were fed to broiler chicks for 5 weeks of age to describe the major changes in target organs.

Materials and Methods

Birds, management and diets: Two hundred forty one-day-old male Ross broiler chicks from a commercial hatchery were used in this study that aimed at providing new insight into OTA toxicology when fed for 5 weeks. The chicks were individually weighed, randomly divided into three dietary groups of 80 chicks each and housed in batteries. The first group was fed a diet without OTA supplementation and served as a control, the second group was fed a diet supplemented with OTA at a concentration of 400 parts per billion (ppb) (400µg OTA/Kg diet), while the third group's diet supplemented with 800 ppb (800µg OTA/Kg ration). These levels of dietary OTA supplementations were chosen because they represent contamination that might occur spontaneously in the field. Each dietary group contained extra birds than those employed in the weekly sampling, as mentioned later on, to compensate for mortality that occurred especially in the high OTA fed group (Elaroussi *et al.*, 2006). The chicks were kept under similar standard hygienic and environmental conditions with feed and water available for *ad libitum* consumption throughout the 5th week of age. Birds were vaccinated against Newcastle disease virus (NDV) by intra-conjunctival instillation at 5 and 19 days using Hitchner and LaSota strains according to manufacturer recommendation, respectively. Diets used in this investigation were formulated without medication and tested to be free from any aflatoxin or zearalenone, by immunoaffinity, which showed them to be below the detection limits of 1 and 10 µg/Kg, respectively. The diets to which OTA was added were a starter ration (23.8% crude protein and 3045 Kcal metabolizable energy (ME/Kg) used from day one to 18 days of age, then a grower ration (22.8% crude protein and 3160 Kcal ME/Kg) from day 19 to 5 weeks of age.

Preparation and production of ochratoxin A: Ochratoxin A produced by *Aspergillus ochraceus* NRRL 3174 culture material was prepared by the National Research Center, Cairo-Egypt. Procedures for OTA production, extraction and purification were according to Davis *et al.* (1969) and Nesheim (1969), while OTA determination and mixing with diets were as described previously (Elaroussi *et al.*, 2006).

Measurements: At the end of each week, eight birds from each group were selected at random, weighed, sacrificed humanely and kidney, liver and bursa extracted, weighed and their relative weight to body weight were determined. Blood samples were collected also for subsequent chemical analyses of the following:

- 1: Glutamic oxaloacetic transaminase (GOT) and Glutamic pyruvic transaminase (GPT) enzymes (Reitman and Frankel, 1957), serum albumin and globulin and total proteins (Armstrong and Carr, 1964), were tested as indicators of liver function.
- 2: Serum levels of uric acid (Trinder, 1969) and creatinine (Hare, 1950) were evaluated in this study as indicators of kidney function.
- 3: The humoral immune response was determined, to indicate bursal function, by the haemagglutination inhibition test (HI) against NDV following the second NDV vaccination with the LaSota strain at 19 days of broiler's age (Majiyagbe and Hitchner, 1977). Blood samples were collected from the brachial vein of 10 birds from each treatment after 3, 7 and 10 days of vaccination with LaSota vaccine and these particular times were chosen because we were looking for secondary response. Serum separated from these blood samples was used to determine Ab titres by HI test.

At the end of the 2nd and 4th weeks of experimental period, eight birds from each group were selected, weighed then sacrificed, dissected and the kidney, liver and bursa of Fabricius were extracted with special care and weighed. Organ weights were determined as relative weights with respect to the body weight. Histopathological examination for changes due to OTA feeding was made in kidney, liver and bursa of Fabricius samples. They were fixed in 10% neutral buffered formalin then processed for paraffin wax embedding. The sections were stained with hematoxyline, eosin (HE) and examined for histopathological changes under light microscope. A semi quantitative assessment was performed to assess the extent of tissue injury. For that purpose, 50 proximal tubules and 20 glomeruli were studied for each kidney specimen and severity was graded as follows: Mild, less than 25 % of tubular and glomerular damage; moderate, from 25 to 50% of tubular and glomerular damage and severe, more than 50% tubular and glomerular damage. The occurrence of mononuclear cell infiltration (MNCs) in the liver and follicle depletion in the bursa were noted and reported.

Elaroussi *et al.*: Ochratoxicosis in Broiler Chickens

Table 1: Effect of ochratoxin A (OTA) level of supplementation on relative organ weight of male broiler chicks¹

OTA (ppb)	Age (week)				
	1	2	3	4	5
Relative liver weight (g /100g)					
0	3.70±0.11 ^a	3.04±0.1 ^{cd}	2.43±0.12 ^g	2.29±0.10 ^g	2.14±0.10 ^g
400	3.65±0.12 ^a	3.24±0.14 ^{bcd}	2.84±0.13 ^e	2.89±0.10 ^{de}	2.75±0.13 ^{ef}
800	3.56±0.15 ^{ab}	3.36±0.12 ^{abc}	3.04±0.15 ^{cde}	3.47±0.14 ^{abc}	3.52±0.16 ^{ab}
Relative kidney weight (g /100 g)					
0	0.73±0.01 ^{fedg}	0.69±0.02 ^g	0.65±0.01 ^h	0.63±0.02 ^{hi}	0.58±0.01 ^l
400	0.75±0.01 ^{def}	0.77±0.03 ^{cde}	0.76±0.02 ^{cde}	0.73±0.01 ^{efg}	0.70±0.02 ^g
800	0.78±0.01 ^{cd}	0.77±0.02 ^{cde}	0.80±0.01 ^b	0.83±0.01 ^{ab}	0.87±0.02 ^a
Relative bursa weight (g /100 g)					
0	0.19±0.07 ^g	0.25±0.01 ^{bcd}	0.27±0.01 ^{ab}	0.28±0.01 ^a	0.26 ± 0.01 ^{abc}
400	0.19±0.01 ^g	0.23±0.01 ^{def}	0.24±0.01 ^{cde}	0.26±0.01 ^{abc}	0.23±0.01 ^{cde}
800	0.16±0.01 ^h	0.20±0.01 ^g	0.21±0.01 ^{efg}	0.21±0.01 ^{efg}	0.20±0.07 ^g

¹Data are means ± standard error, ^{a-l}Values for each criteria in a row and column with different superscript are significantly different (P<0.05).

Statistical analyses: The data obtained in this study were analyzed by ANOVA in a two-way classification followed by Duncan's multiple range tests to separate means using the general linear model procedure (GLM) of the statistical analysis system software (SAS, 1992). The statistical model was:

$$Y_{ijk} = U + T_i + A_j + T_i A_j + r_{ijk}$$

It was used to explain the variability among groups for all parameters undertaken in this study, where

- Y_{ijk} : Performance traits measured on the kth broiler in the ith treatment and jth age group.
- U : Overall mean
- T_i : Effect of the ith treatment (i = 1, 2, 3)
- A_j : Effect of the jth age group.
- T_iA_j : Interaction term between treatment and age.
- r_{ijk} : Residual terms assumed normal and independent, N (0, σ²).

Results

Target organ relative weight to body weight: The increase in the kidney relative weight that occurred starting from the second week, was related to OTA level in the diet and exposure duration (Table 1). In the control group, the relative kidney weight decreased as the age of the birds increased, which was quite the opposite of the high OTA group that increased with longer OTA exposure. Liver weight of birds fed 400 ppb OTA decreased similar to controls, however the weights were significantly greater than in controls. For birds fed 800 ppb OTA, liver weights decreased at week 3 then were similar to week 1 at weeks 4 and 5 but significantly higher than the other two groups. Contrary to the kidney and liver, results presented in Table 1 show that the relative weight of the bursa of Fabricius was reduced as a result of the OTA toxin. The significant reduction (P<0.05) that occurred in the relative weight of the bursa

of broilers exposed to this toxin was consistent with increasing OTA level in the diet. Dietary OTA effect on bursal weight reduction was as early as the first week of treatment for the group receiving 800 ppb OTA and continued to the end of the study.

Liver function: Serum levels of Glutamic oxaloacetic transaminase (GOT) and Glutamic pyruvic transaminase (GPT) were estimated and used as physiological indicators for liver function during ochratoxicosis in broilers. The current results indicated that OTA caused a significant increase in serum transaminases in birds fed OTA, with these changes being more evident with higher OTA and with prolongation of exposure time, Table 2.

Changes in serum total protein, albumin and globulin are very sensitive indicators of ochratoxicosis and also reflects liver function, as OTA is known to inhibit hepatic protein synthesis. Results indicated that compared to control, both groups receiving OTA at 400 and 800 ppb had significantly lower (P<0.05) total protein after 2 weeks of feeding OTA through the 5th week. Serum total protein level decreased weekly when the birds were given the high level of OTA (800 ppb) in the diet, as compared to a weekly increase in the control group. Results presented in Table 3 indicated that the decrease in total protein of the OTA groups was due to the decrease in albumin and globulin fractions. Compared to controls, the decrease in serum albumin of the OTA groups became significant (P<0.05) starting from the 3rd week, while that of globulin from the 2nd week of OTA treatment.

Kidney function: The presence of OTA in broiler diets at both experimental levels (400 and 800 ppb) resulted in a significant increase in serum uric acid and creatinine concentration in the birds of the OTA groups, this increase was more evident with the higher level of OTA and also was more pronounced with prolongation of exposure time (Table 4).

Elaroussi *et al.*: Ochratoxicosis in Broiler Chickens

Table 2: Effect of dietary ochratoxin A (OTA) levels of supplementation on serum GOT And GPT of male broiler chicks¹

OTA (ppb)	Age (week)				
	1	2	3	4	5
GOT (U/L)					
0	170.62±5.66 ⁱ	207.47 ±6.90 ^{fg}	182.48±5.45 ^{hi}	228.16±5.06 ^{cdef}	225.99±5.74 ^{cdef}
400	193.01±6.88 ^{gh}	217.37±7.71 ^{edf}	209.66±6.79 ^{efg}	239.25±8.57 ^{bcd}	247.39±8.27 ^{abc}
800	188.69±8.34 ^{ghi}	230.69±9.63 ^{cde}	252.99±8.13 ^{ab}	265.96±6.79 ^a	245.67±6.00 ^{ab}
GPT (U/L)					
0	14.03±0.68 ^g	13.25±0.95 ^g	14.60±0.47 ^{efg}	14.70±0.66 ^{efg}	15.15±0.58 ^{defg}
400	14.88±0.98 ^{efg}	16.33±1.09 ^{def}	17.43±0.78 ^{cd}	19.34±1.13 ^{bc}	20.67±0.86 ^b
800	15.10±0.63 ^{defg}	16.92±0.77 ^{de}	19.83±0.41 ^b	21.11±0.82 ^b	24.03±0.78 ^a

¹Data are means ± standard error, ^{a-i}Values for each criteria in a row and column with different superscript are significantly different (P< 0.05).

Table 3: Effect of ochratoxin A (OTA) level of supplementation on blood proteins of male broiler chicks¹

OTA (ppb)	Age (week)				
	1	2	3	4	5
Total Protein (g /dl)					
0	3.41±0.23 ^{cd}	3.86±0.19 ^{bc}	4.08±0.26 ^{ab}	4.42±0.17 ^{ab}	4.55±0.18 ^a
400	3.28±0.14 ^{cde}	3.44±0.14 ^{cd}	3.09±0.16 ^{def}	2.98±0.24 ^{def}	2.69±0.16 ^{efg}
800	3.10±0.28 ^{def}	2.75±0.17 ^{efg}	2.66±0.25 ^{efg}	2.45±0.26 ^g	2.22±0.12 ^g
Albumin (g /dl)					
0	1.39±0.08 ^{bc}	1.24±0.12 ^{bcdde}	1.55±0.07 ^{ab}	1.79±0.14 ^a	1.85±0.08 ^a
400	1.33±0.10 ^{bcd}	1.19±0.13 ^{cdef}	1.21±0.07 ^{bc}	1.09±0.13 ^{cdef}	0.92±0.03 ^{ef}
800	1.23±0.10 ^{bcdde}	1.17±0.17 ^{cdef}	0.99±0.04 ^{def}	1.03±0.17 ^{cdef}	0.86±0.08 ^f
Globulin (g /dl)					
0	2.02±0.15 ^{bc}	2.65±0.08 ^a	2.66±0.23 ^a	2.69±0.09 ^a	2.70±0.10 ^a
400	1.95±0.07 ^{bcd}	2.24±0.07 ^b	1.88±0.10 ^{bcd}	1.85±0.12 ^{bcd}	1.76±0.12 ^{de}
800	1.87±0.18 ^{bcd}	1.58±0.08 ^{def}	1.67±0.22 ^{cdef}	1.42±0.10 ^{ef}	1.36±0.06 ^f

¹Data are means ± standard error, ^{a-f}Values for each criteria in a row and column with different superscript are significantly different (P< 0.05).

Table 4: Effect of ochratoxin A (OTA) levels of supplementation on serum content of uric acid and creatinine of male broiler chicks¹

OTA (ppb)	Age (week)				
	1	2	3	4	5
Uric acid (mg/dl)					
0	5.239±0.36 ^{hi}	4.718±0.21 ⁱ	5.685±0.41 ^{hi}	6.215±0.26 ^{gh}	5.567±0.22 ^{hi}
400	6.472±0.38 ^{gh}	7.986±0.52 ^f	9.298±0.33 ^e	11.581±0.49 ^c	13.084±0.57 ^b
800	7.380±0.55 ^g	9.807±0.46 ^{de}	10.890±0.52 ^c	14.141±0.39 ^b	15.886±0.33 ^a
Creatinine (mg/dl)					
0	0.362±0.014 ^{gh}	0.335±0.009 ^h	0.355±0.008 ^{gh}	0.372±0.011 ^{gh}	0.344±0.010 ^h
400	0.389±0.012 ^g	0.404±0.013 ^{ef}	0.431±0.013 ^{de}	0.452±0.011 ^{cd}	0.491±0.011 ^{bc}
800	0.453±0.016 ^{cd}	0.467±0.011 ^{bd}	0.497±0.015 ^b	0.501±0.020 ^b	0.552±0.019 ^a

¹Data are means ± standard error, ^{a-i}Values for each criteria in a row and column with different superscript are significantly different (P<0.05).

Table 5: Effect of ochratoxin A (OTA) levels of supplementation on antibody titre against Newcastle disease virus after 3, 7 and 10 days post immunization¹

OTA (ppb)	Days post immunization		
	3	7	10
0	9.400±0.60 ^{ab}	10.00±0.00 ^a	5.400±0.40 ^d
400	7.400±0.68 ^c	8.200±0.58 ^c	3.200±0.58 ^e
800	5.400±0.60 ^d	5.200±0.19 ^d	2.800±0.37 ^e

¹Data are means ± standard error, ^{a-e}Values for each criteria in a row and column with different superscript are significantly different (P< 0.05).

dependent upon. Therefore, humoral immune response determination could be used as an indicator of the bursa of Fabricius function. Results revealed that both OTA groups showed a significant sharp reduction in Ab titre against NDV when compared to the control group (Table 5). This decrease in Ab titre was significantly more severe with the higher level of OTA, indicating that immunosuppression due to OTA is dose dependent. Moreover, the secondary immune response peaks between 3 and 7 days and on its back to low levels by day 10 in all groups.

Effect of ochratoxin a on humoral immune response:
The bursa represents in the early age the primary lymphoid organ that immunoglobulins production is

Effect of ochratoxin a on histological parameters:
Prominent histological changes related to the dietary OTA treatments employed were observed in the kidney

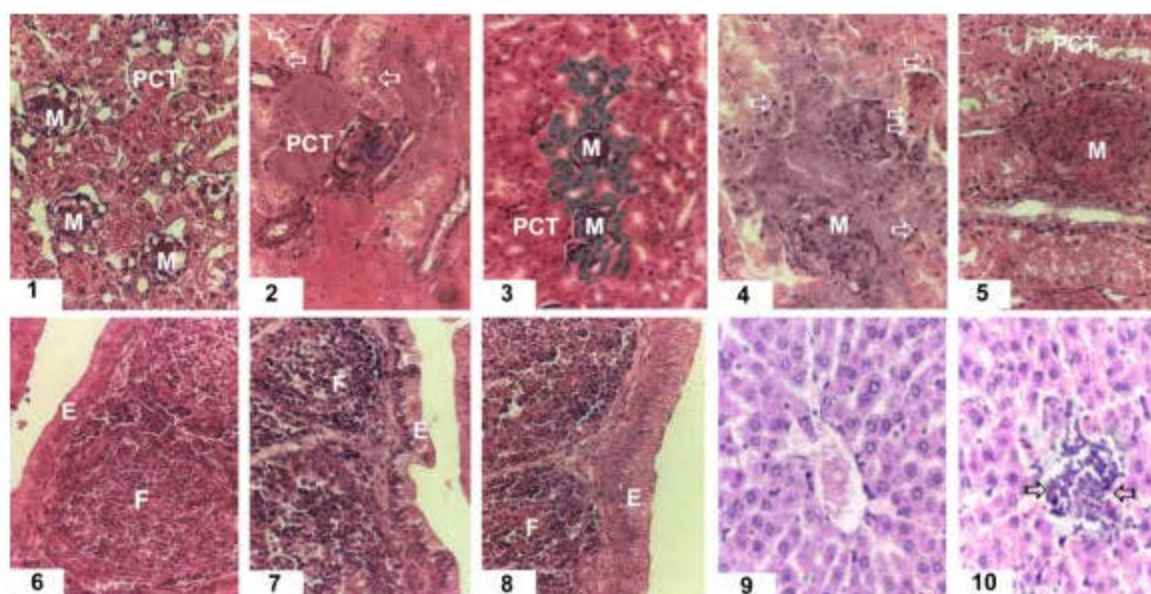


Fig. 1: Legends of photomicrographs:

- 1: Photomicrograph of the kidney of control broiler chick showing the proximal convoluted tubules (PCT) and Malpighian corpuscles (M). (HE x 400).
- 2: Photomicrograph of the kidney of male broiler chick receiving OTA in their diet for 2 weeks at a dose of 400µg/Kg feed, showing cells of PCT with cloudy swelling in the cytoplasm and few degenerating pyknotic nuclei (arrows) (HE x 400).
- 3: Photomicrograph of the kidney of male broiler chick receiving OTA in their diet for 4 weeks at a dose of 400 µg/Kg diet showing cells of PCT with more prominent cloudy swelling in the cytoplasm and few degenerating cells with pyknotic nuclei and decreased capsular space in Bowman's capsule of Malpighian corpuscles (M) (HE x 400).
- 4: Photomicrograph of the kidney of male broiler chick receiving OTA in their diet for 2 weeks at a dose of 800 µg/Kg feed showing more prominent changes in the form of more degenerating cells with pyknotic nuclei (arrows) in cells of (PCT) and obliteration of capsular space in Bowman's capsule of Malpighian corpuscles (M) (HE x 400).
- 5: Photomicrograph of the kidney of male broiler chick receiving OTA in their diet for 4 weeks at a dose of 800 µg/Kg feed showing more prominent changes in the form of degenerating cells with pyknotic nuclei in cells of PCT and Malpighian corpuscles (M) showing marked degeneration, hyalinization and obliteration of the capsular spaces (HE x 400).
- 6: Photomicrograph of a section in the bursa of control male broiler chick showing lymphatic follicles (F) with the follicle associated simple columnar epithelium (E) (HE x 200).
- 7: Photomicrograph of a section in the bursa of a male broiler chick receiving OTA in their diet for 2 weeks in a dose of 800 µg/Kg feed showing the lymphatic follicles (F) and that follicle associated epithelium (E) became disorganized with apical accumulation of secretions, which appeared as vacuolated cytoplasm (HE x 200).
- 8: Photomicrograph of a section in the bursa of a male broiler chick receiving OTA in their diet for 4 weeks in a dose of 800 µg/Kg feed showing swollen follicle associated epithelium (E) and depletion of lymphocytes in lymphoid follicles (F) with larger paler nuclei in cells of the germinal center of the follicle (HE x 200).
- 9: Photomicrograph of a section in the liver of control male broiler chick showing the central vein with the surrounding hepatocytes arranged in plate (HE x 200).
- 10: Photomicrograph of a section in the liver of a male broiler chick receiving OTA in their diet for 4 weeks in a dose of 800 µg/Kg feed showing mild mononuclear cellular infiltration (arrows) (HE x 200).

and bursa of Fabricius and to a lesser extent in the liver, histology of these three target organs are presented in Fig. 1. The only detected change to be reported in the liver of OTA groups receiving 400 or 800 ppb OTA in their feed was mononuclear cellular infiltration (MNCs).

Initially, it was just a mild focal infiltration of MNCs in the liver portal areas of birds fed the OTA for 2 weeks, then it became multifocal at subsequent intervals after 4 weeks of feeding OTA containing diets. There were no detected changes between the low and high doses of

OTA treatment. No degenerative changes or vacuolation in the hepatocytes were observed (Fig. 1: Photomicrograph 9 and 10).

Histological examination of kidney sections from broiler chicks that were fed the OTA contaminated diets at 400 and 800 ppb showed significant changes in comparison with control sections (Fig. 1). These changes were in the form of cloudy swelling and granular degenerative changes in the cytoplasm and Pyknotic nuclei in the epithelial cells of proximal convoluted tubules of kidney (PCT). Furthermore, a decrease in corpuscular space in Bowman's capsule, marked degeneration of Malpighian corpuscles and hyalinization and obliteration of capsular spaces were recorded. These changes were severe in the case of higher dietary level of OTA and also with the prolongation of dietary exposure period (Fig. 1: Photomicrograph 1,2, 3, 4 and 5).

Dietary OTA supplementation to broiler chickens caused dramatic histological changes in this important lymphoid organ. Histopathological findings in the sections of the bursa from broiler chickens fed the contaminated diets with 800 ppb OTA for 2 and 4 weeks showed significant histological changes that were reflected in swelled follicle-associated epithelium with apical accumulation of secretions, which appeared as vacuolated cytoplasm (Fig. 1: Photomicrograph 6, 7 and 8). In addition, Follicles of OTA-exposed broilers receiving a level of 800 ppb for prolonged period of 4 weeks appeared to be atrophic with some lympholysis and lymphoid depletion with larger paler nuclei in the germinal center relative to the control.

Discussion

The results of this study show that when OTA was added to the diet of broiler chickens at concentrations of 400 and 800 µg OTA / Kg diet, the relative weights of kidney and liver were increased and their function was impaired as indicated by the increased serum GOT, GPT, uric acid and creatinine levels in OTA treated groups in comparison to the control. Although OTA is known to be a nephrotoxin in poultry species, results of this investigation lead to conclude that OTA has hepatotoxic properties as well. The increase of the kidney and liver relative weights in OTA treated birds came in agreement with several previous reports using dietary OTA inclusion rates of 2 and 4 mg/Kg (Dwivedi and Burns, 1984); 1, 2 and 4 mg/Kg (Huff *et al.*, 1988); 2 mg/Kg (Santin *et al.*, 2002); 130, 300 and 800 µg/Kg OTA and 1000-5000 µg/Kg penicillic acid (PA) (Stoev *et al.*, 2000 and 2004). While others using OTA at 2 mg/Kg (Raju and Devegowda, 2000) or 4 mg/Kg (Verma *et al.*, 2004) reported an increase only in kidney weights and not liver. Lower OTA rates at 500 µg/Kg (Santin *et al.*, 2003) did not affect the relative weight of either organ. The reported enlargement of the liver and kidney in OTA groups is probably due to the fact that these organs are involved in

detoxification and elimination of OTA. OTA is known to have direct toxic action (Stoev *et al.*, 2000) and high level of accumulation in these two organs (Biro *et al.*, 2002). The current increase in GOT and GPT agrees with previous studies exposing broiler chickens to dietary OTA at 0.5-1 mg/Kg (Agawane and Lonkar, 2004; Raina *et al.*, 1991) and reflects amino acid imbalance (Burnette and Babcock, 1978), a condition that results from protein catabolism and indicates liver cell necrosis. Furthermore, aspartate aminotransferase (AST) was reported to increase by Kumar *et al.* (2003) and Bailey *et al.* (1989) when OTA was supplemented to broiler diets at 2 mg/Kg and 4 mg/Kg, respectively. AST, also called serum GOT, involves intermolecular amino group transfer and exists as a cytoplasmic and mitochondrial enzyme that is most abundant in the heart, liver and skeletal muscles.

Signs of liver disease was further supported by the significant decrease in total protein, albumin and globulin of the OTA treated groups. Similar decrease in total protein, albumin and globulin were reported when OTA was administered alone to broiler chickens at 0.5-4 mg/Kg (Agawane and Lonkar, 2004; Raina *et al.*, 1991; Bailey *et al.*, 1989; Huff *et al.*, 1988) and at 130-790 µg/Kg or 567 µg/Kg in combination with 2000-5000 µg/Kg PA (Stoev *et al.*, 2000) and 927 µg/Kg T-2 toxin (Garcia *et al.*, 2003), respectively. According to O'Brien and Dietrich (2005), several studies have determined OTA to have an extremely high affinity for serum albumin and other macromolecules in the blood. This bond was suggested to be the decisive factor in determining the half-life of OTA in any given species and hence its susceptibility to renal damage (O'Brien and Dietrich, 2005). The low level of albumin and globulin observed in this study in OTA treated birds may be due to decreased synthesis in the liver that suffered hepatic toxicity or may be due to its loss in urine as a result of renal impairment as reflected by the increased serum uric acid and creatinine. Furthermore, the lower globulin was reflected as well by the impaired immune response and lowered levels of antibody titres in OTA groups. The observed change in liver histology due to current low OTA exposure employed in this study was detected as MNC infiltration. It is more likely that the increase in the relative liver weight corresponds to this histopathological change and to epithelial enlargement as in the case of the kidney. This was consistent with Stoev *et al.* (2000) who described slight liver enlargement, degeneration and rarely, vacuolation of the hepatic cells, as well as, perivascular mononuclear cell infiltration on days 42 and 70 of the experiment as a result of the combined effect of dietary OTA at levels of 790 µg/Kg and 2000-5000 µg/Kg PA. Pathological changes in the liver were reported when feeding higher OTA at 2 mg/Kg to broilers (Santin *et al.*, 2002; Kumar *et al.*, 2004). However, despite these reports and others on OTA-mediated

hepatotoxicity and evidence that OTA can accumulate in the liver as well as in the kidney, attempts to define the mechanism of OTA-mediated hepatotoxicity have been relatively few and far between and those that have been carried out have yielded inconclusive and often contradictory results (O'Brien and Dietrich, 2005).

The significantly increased levels of serum uric acid and creatinine in the OTA treated groups in addition to the histological changes detected in these groups are all indicative of impaired renal function and confirms that the kidney is a major and primary site for OTA toxic action. These findings are consistent with previous reports showing that uric acid increases in OTA fed broilers at 567 µg/Kg (Garcia *et al.*, 2003); 130, 305, or 790 µg/Kg with 2000-5000 µg/Kg PA (Stoev *et al.*, 2000); 0.75, 1.5 and 3 mg/Kg (Mohiuddin *et al.*, 1993); 0.5 mg/Kg (Ayed *et al.*, 1991). While creatinine increases at OTA concentrations of 0.5 mg/Kg (Agawane and Lonkar, 2004) both parameters, uric acid and creatinine, were reported to increase when OTA was fed at levels ranging from 1-4 mg/Kg (Kumar *et al.*, 2003; Bailey *et al.*, 1989; Huff *et al.*, 1988).

The pathohistological changes in the kidney of OTA treated birds were more profound in the case of higher dietary level of OTA and also with the prolongation of dietary exposure. The lesions were mainly found in the proximal convoluted tubules of the kidney (PCT) and in the cortex. The high affinities of OTA for PCT induced changes were observed as cloudy swelling and degeneration in the cytoplasm and Pyknotic nuclei of PCT cells. Our results agreed with Stoev *et al.* (2000 and 2004) and Kumar *et al.* (2004) reporting that broilers fed, 130, 300 and 800 µg/Kg OTA with 1000-5000 µg/Kg PA and 2 mg/Kg OTA, respectively, induced PCT to swollen, degeneration of tubular epithelium and interstitial nephritis. Moreover, Biro *et al.* (2002) simulated field conditions by exposing broiler chicks to a total of 0.5 mg OTA/week for 4 weeks and reported microscopically changes in the form of glomerulonephrosis, tubulonephrosis, focal tubular epithelial cell proliferation and multiple adenoma-like structures in the renal parenchyma. In another study, Santin *et al.* (2002) feeding 2 mg/Kg OTA reported that the kidneys of OTA fed chicks showed hypertrophy of the renal proximal tubular epithelium, with thickening of the glomerular basement membrane. These changes in the kidney and in particular the PCT could be explained by apoptotic changes involving a genetic factor activated by OTA. In a study to determine the molecular basis for interpretation of OTA-induced nephrotoxicity, Luhe *et al.* (2003) observed marked OTA treatment-specific transcriptional changes for genes involved in DNA damage response, apoptosis and response to oxidative stress.

There was a significant decrease in antibody titer against NDV throughout the test period in OTA groups compared to the control group. Previous reports showed

that OTA fed to chickens at concentrations 130-790µg/Kg (Stoev *et al.*, 2000); 2mg/Kg (Santin *et al.*, 2002); 4mg/Kg (Verma *et al.*, 2004) or 400 and 800µg/Kg (Elaroussi *et al.*, 2006) reduced either humoral or cellular immune response or both. Suppression of humoral immunity by OTA at both levels employed in this study reduced immune response of broilers to vaccination against Newcastle disease virus strain LaSota and agreed with the results of Santin *et al.* (2002). Depletion of lymphocytes in lymphoid follicles was the main pathohistological feature in the bursa of broiler chickens exposed to OTA in this study and agreed with previous studies (Dwivedi and Burns, 1984; Stoev *et al.*, 2000; Santin *et al.*, 2002; Kumar *et al.*, 2004). An important observation of the current research was that severity of the histopathological changes was directly related to the concentration of OTA in the diet; Peckham *et al.* (1971) reported a similar finding. The decrease in the relative weight of the bursa of Fabricius is likely a consequence of the decrease in the lymphoid tissue and the degenerative changes in OTA treated birds. In addition to previously described lymphoid depletion of the bursa that reflects reduction of antibody producing cells, Santin *et al.* (2002) described a reduction in the bursal mitotic index, possibly resulting from the inhibition of protein synthesis which is essential for the S stage of cell division.

The decreased immune response and depletion of lymphatic follicles in the bursa together with decreased serum proteins and possible loss of albumin in urine after renal impairment could explain the immunosuppressive effects of OTA. These effects may be due to down regulation of the genes responsible for protein synthesis by a similar mechanism to its effects on the kidney as mentioned by Luhe *et al.* (2003). Results of the current report along with previous literature suggest that OTA reduced immunity, decreases the response to vaccination and thereby increases the susceptibility to infections.

Acknowledgment

The authors are grateful to Dr. Kawthar M. Soliman, Marine Toxicology Unit, National Research Center, Cairo-Egypt, for providing *Aspergillus ochraceus* NRRL 3174 culture material and for her suggestions and advice.

References

- Abdelhamid, A.M., 1990. Occurrence of some mycotoxins (aflatoxin, ochratoxin A, citrinin, zearalenone and vomitoxin) in various Egyptian feeds. *Archiv fur Tierernahrung*, 40: 647-664.
- Agawane, S.B. and P.S. Lonkar, 2004. Effect of probiotic containing *Saccharomyces* on experimental ochratoxicosis in broilers: Hematobiochemical studies. *J. Vet. Sci.*, 5: 359-367.

Elaroussi et al.: Ochratoxicosis in Broiler Chickens

- Armstrong, W.D. and C.W. Carr, 1964. Physiological Chemistry Laboratory Directions. 3rd Edn. Burges publishing Co., Minneapolis, Minnesota, pp: 153.
- Ayed, I.A.M., R. Defalla, A.I. Yagi and S.E.I. Adams, 1991. Effect of ochratoxin A on Lohman-type chicks. *Vet. Hum. Toxicol.*, 33: 557-560.
- Bailey, C.A., R.M. Gibson, L.F. Kubena, W.E. Huff and R.B. Harvey, 1989. Ochratoxin A and dietary protein: 2- Effects on hematology and various clinical chemistry measurements. *Poult. Sci.*, 68: 1664-1671.
- Bayman, P., J.L. Barker, M.A. Doster, T.J. Michailides and N.E. Mahoneys, 2002. Ochratoxin production by the *Aspergillus ochraceus* group and *Aspergillus alliaceus*. *Appl. Environ. Microbiol.*, 68: 2326-2329.
- Biro, K., L. Solti, I. Barna - Vetro, G. Bago, R. Glavits, E. Szabo and J. Fink - Gremmela, 2002. Tissue distribution of ochratoxin A as determined by HPLC and ELISA and histopathological effects in chickens. *Avian Pathol.*, 31: 141-148.
- Breitholtz - Emanuelsson, A., M. Olsen, A. Oskarsson, I. Palminger and K. Hult, 1993. Ochratoxin A in cow's milk and in human milk with corresponding human blood samples. *J. AOAC, Int.*, 76: 842-846.
- Burnette, M.A. and M.J. Babcock, 1978. Oral amino acid load test of protein nutrition: Effect of protein quantity and quality in the rat. *J. Nutr.*, 108: 465-474.
- Campbell, M.L., Jr., J.D. May, W.E. Huff and J.A. Doerr, 1983. Evaluation of immunity of young broiler chickens during simultaneous aflatoxicosis and ochratoxicosis. *Poult. Sci.*, 62: 2138-2144.
- Chang, C.F., W.E. Huff and P.B. Hamilton, 1979. A Leucocytopenia induced in chickens by dietary ochratoxin A. *Poult. Sci.*, 58: 555-558.
- Davis, N.D., J.W. Searcy and U.L. Diener, 1969. Production of ochratoxin A by *Aspergillus ochraceus* in a semisynthetic medium. *Appl. Microbiol.*, 17: 742-744.
- Dwivedi, P. and R.B. Burns, 1984. Pathology of ochratoxicosis A in young broiler chicks. *Res. Vet. Sci.*, 36: 92-103.
- Elaroussi, M.A., F.R. Mohamed, E.M. El Barkouky, A.M. Atta, A.M. Abdou and M.H. Hatab, 2006. Experimental ochratoxicosis in broiler chickens. *Avian Pathol.*, 35: 263-269.
- Garcia, A.R., E. Avila, R. Rosiles and V.M. Petrone, 2003. Evaluation of two mycotoxin binders to reduce toxicity of broiler diets containing ochratoxin A and T-2 toxin contaminated grain. *Avian Dis.*, 47: 691-699.
- Hare, R.S., 1950. Endogenous creatinine in serum and urine. *Proc. Soc. Exp. Biol. Med.*, 74: 148-151.
- Huff, W.E., L.F. Kubena and R.B. Harvey, 1988. Progression of ochratoxicosis in broiler chickens. *Poult. Sci.*, 67: 1139-1146.
- Kumar, A., N. Jindal, C.L. Shukla, R.K. Asrani, D.R. Ledoux and G.E. Rottinghaus, 2004. Pathological changes in broiler chickens fed ochratoxin A and inoculated with *Escherichia coli*. *Avian Pathol.*, 33: 413-417.
- Kumar, A., N. Jindal, C.L. Shukla, Y. Pal, D.R. Ledoux and G.E. Rottinghaus, 2003. Effect of ochratoxin A on *Escherichia coli* - challenged broiler chicks. *Avian Dis.*, 47: 415-424.
- Larsen, T.O., A. Svendsen and J. Smedsgaard, 2001. Biochemical characterization of ochratoxin A-producing strains of the genus *Penicillium*. *Appl. Environ. Microbiol.*, 67: 3630-3635.
- Luhe, A., H. Hildebrand, U. Bach, T. Dingermaier and H.J. Ahr, 2003. A new approach to studying ochratoxin A (OTA)-induced nephrotoxicity: Expression profiling in vivo and in vitro employing cDNA microarrays. *Toxicol. Sci.*, 73: 315-328.
- Majiyagbe, K.A. and S.B. Hitchner, 1977. Antibody response to strain combinations of Newcastle disease virus as measured by haemagglutination inhibition. *Avian Dis.*, 21: 576-584.
- Mohiuddin, S.M., S.M.A. Warasi and M.V. Reddy, 1993. Hematological and biochemical changes in experimental ochratoxicosis in broiler chickens. *The Ind. Vet. J.*, 70: 613-617.
- Nesheim, S., 1969. Isolation and purification of ochratoxin A and B and preparation of their methyl and ethyl esters. *J.O.A.C.*, 52: 975-979.
- O'Brien, E. and D.R. Dietrich, 2005. Ochratoxin A: The continuing enigma. *Crit. Rev. Toxicol.*, 35: 33-60.
- O'Brien, E., A.H. Heussner and D.R. Dietrich, 2001. Species-Sex-and cell type-specific effects of ochratoxin A and B. *Toxicol. Sci.*, 63: 256-264.
- Peckham, J.C., B. Doupnik, Jr. and O.H. Jones, 1971. Acute toxicity of ochratoxin A and B in chicks. *Appl. Microbiol.*, 21: 492-494.
- Politis, I., K. Fegeros, S. Nitsch, G. Schatzmayr and D. Kantas, 2005. Use of *Trichosporon mycotoxinivorans* to suppress the effects of ochratoxicosis on the immune system of broiler chicks. *Br. Poult. Sci.*, 46: 58-65.
- Raina, J.S., K.S. Roy and B. Singh, 1991. Biochemical and histochemical studies in experimental mycotoxicosis in chicks. *Ind. J. Anim. Sci.*, 62: 1276-1281.
- Raju, M.V. and G. Devegowda, 2000. Influence of esterified-glucomannan on performance and organ morphology, serum biochemistry and haematology in broilers exposed to individual and combined mycotoxicosis (aflatoxin, ochratoxin and T-2 toxin). *Br. Poult. Sci.*, 41: 640-650.
- Reitman, S. and S. Frankel, 1957. A colorimetric method for the determination of serum glutamic oxaloacetate and glutamic pyruvic transaminase. *Am. J. Clin. Pathol.*, 28: 56-58.

Elaroussi *et al.*: Ochratoxicosis in Broiler Chickens

- Santin, E., A.C. Paulillo, P.C. Maiorka, A.C. Alessi, E.L. Krabbe and A. Maiorka, 2002. The effects of ochratoxin/aluminosilicate interaction on the tissues and humoral immune response of broilers. *Avian Pathol.*, 31: 73-79.
- Santin, E., A.C. Paulillo, L.S.O. Nakagui, A.C. Alessi, W.J.C. Polverio and A. Maiorka, 2003. Evaluation of cell wall yeast as adsorbent of ochratoxin in broiler diets. *Int. J. Poult. Sci.*, 2: 465-468.
- SAS Institute, 1992. SAS[®] User's Guide, version 7 Edn., SAS Institute Inc., Cary, NC.
- Stoev, S.D., G. Anguelov, I. Ivanov and D. Pavlov, 2000. Influence of ochratoxin A and an extract of artichoke on the vaccinal immunity and health in broiler chicks. *Exp. Toxicol. Pathol.*, 52: 43-55.
- Stoev, S.D., M. Stefanov, S. Denev, B. Radic, A.M. Domijan and M. Peraica, 2004. Experimental mycotoxicosis in chickens induced by ochratoxin A and penicillic acid and intervention with natural plant extracts. *Vet. Res. Comm.*, 28: 727-746.
- Trinder, P., 1969. Enzymatic colorimetric method for the determination uric acid. *Ann. Clin. Biochem.*, 6: 24-30.
- Varga, J., E. Kevei, E. Rinyu, J. Teren and Z. Kozakiewicz, 1996. Ochratoxin Production by *Aspergillus* species. *Appl. Environ. Microbiol.*, 62: 4461-4464.
- Verma, J., T.S. Johri, B.K. Swain and S. Ameena, 2004. Effect of graded levels of aflatoxin, ochratoxin and their combination on the performance and immune response of broilers. *Br. Poult. Sci.*, 45: 512-518.
- Wafa, E.W., R.S. Yahya, M.A. Sobh, I. Eraky, M. El - Baz, H.A. El - Gayar, A.M. Betbeder and E.E. Creppy, 1998. Human ochratoxicosis and nephropathy in Egypt: A preliminary study. *Hum. Exp. Toxicol.*, 17: 124-129.