

ISSN 1682-8356
ansinet.org/ijps



INTERNATIONAL JOURNAL OF
POULTRY SCIENCE

ANSI*net*

308 Lasani Town, Sargodha Road, Faisalabad - Pakistan
Mob: +92 300 3008585, Fax: +92 41 8815544
E-mail: editorijps@gmail.com

Toxicopathologic Effects of Artemisinin in Broiler Chickens Following a Single Oral Dose: An LD₅₀ Study

H.A. Arab¹, S.H. Mardjanmehr², A. Shahbazfar², A. Rassouli¹, M. Abdollahi³ and O. Nekouie⁴

¹Department of Pharmacology, Faculty of Veterinary Medicine, University of Tehran, Tehran, Iran

²Department of Pathology, Faculty of Veterinary Medicine, University of Tehran, Tehran, Iran

³Department of Toxicology and Pharmacology, School of Pharmacy,
Tehran University of Medical Science, Tehran, Iran

⁴Department of Food Hygiene and Epidemiology, Faculty of Veterinary Medicine,
University of Tehran, Tehran, Iran

Abstract: The present study aimed to find LD₅₀ of artemisinin and to characterize the single dose toxicity of the drug following oral exposure. 49 day-old Ross broilers divided into 7 groups; one control, one drug vehicle and five treatment groups. The treatment groups received artemisinin alcoholic solution at doses of 10, 50, 250, 1250 and 2500 mg/kg on day 30 by a crop tube. The control and drug vehicle groups received normal saline and ethyl alcohol, respectively. In the period of study just in 1250 and 2500 mg/kg groups there were a few transient neurological signs like depression and unconsciousness. These signs were also observed in drug vehicle group. None of the birds died, so they were euthanised on day 40. In microscopic examination, only in treatment groups a slight degeneration in liver and kidney as intracytoplasmic eosinophilic inclusions, hepatocellular swelling and bile retention in liver were evident. In brain central chromatolysis, scattered neuronal necrosis, spongy change and focal axonal swelling were observed. It is concluded that artemisinin has a good margin of safety in poultry but in very high doses it may cause some adverse effects.

Key words: Artemisinin, broilers, toxicopathology, single dose, neurotoxicity

INTRODUCTION

Coccidiosis is a parasitic disease which causes a huge economic loss every year in poultry industry around the world. The causative protozoa has got different species with different virulence in various hosts. Prevention, control and treatment of poultry coccidiosis with conventional anticoccidial drugs cause daily exposure of environment with noticeable amount of these chemicals. These compounds also may produce human health concerns through their residues in animal origin foods. Artemisinin is a sesquiterpenelactone and is a naturally occurring compound in *Artemisia* plants. It has got an endoperoxide bridge which is the functional part of the drug (Fishwick *et al.*, 1995). *Artemisia* plants are among pasture plants which are found in many parts of the world including Iran. They have been used for centuries to treat malaria, gastrointestinal helminthosis, hemorrhoid, skin rashes, diarrhea and some other diseases especially in oriental medicine. Nowadays purified active substance of the herb, artemisinin and its derivatives are commercially available. The most important usage of these drugs is for resistant malarial. Recent studies report their anti-cancer, anti-leishmania and anti-viral effects (Kaptein *et al.*, 2006; Sen *et al.*, 2007; Singh and Lai, 2004).

The anticoccidial effect of artemisinin in poultry was first reported from USA (Allen *et al.*, 1997). Synthetic and semi-synthetic derivatives of artemisinin have different

solubility in fat and water. Therefore, they have different pharmacokinetic profiles although the most important metabolite of all of them in body is dihydroartemisinin. One of the necessary steps for introduction of drugs as a therapeutic agents such as artemisinin for poultry coccidiosis is acute toxicity study and finding LD₅₀ of the drug in target animal. This experiment was carried out to find LD₅₀ of artemisinin in broilers using a single oral administration of its alcoholic solution and to determine the toxicopathologic effects of the drug in certain organs.

MATERIALS AND METHODS

49 day-old commercial broiler chicks (Ross-308) were used. Chickens had free access to food and water. Light was on 24 h a day. All chickens vaccinated against Infectious bronchitis, Newcastle disease and Infectious bursal disease. They were kept in metal cages.

Artemisinin as colorless crystals with the purity of 99 per cent was obtained (Sichuan Arts and crafts import and export corporation, China). The drug was dissolved in absolute ethyl alcohol using an ultrasound shaker.

The birds were divided into 7 groups; one control, one drug vehicle and five treatment groups on day 29 of their life.

The treatment groups received the alcoholic solution of drug with the dosage of 10, 50, 250, 1250 and 2500 mg/kg on day 30 of their life by a crop tube.

The drug vehicle group received absolute ethyl alcohol alone with the volume equivalent to the amount that was necessary to dissolve 2500 mg/kg of the drug. Control group received the normal saline only.

After a single dose, birds were monitored for probable clinical signs and food and water consumption. Since there was no mortality, just 10 days after drug administration, chickens were euthanised. After inspection of whole carcass for any gross changes, for histopathological examination, liver, kidney, brain, heart, lung and spleen were placed thoroughly in buffered 10 per cent formalin.

Fixative solution was changed 2 times in first 48 h. After 2 weeks specimens were cut for tissue processing and then processed for paraffin embedding. Since brain is reportedly the most affected organ and it is a very complex organ containing many regions with different susceptibility to various chemicals, so the main focus in sectioning was made on the brain. According to neural lesions found in other animals following artemisinin administration, four different areas of the brain were selected for investigation including: motor cortex, mid brain nuclei, hind brain nuclei (in two separate levels) and cerebellar nuclei. Paraffin blocks were made and then sectioned as 5 micrometer thickness. Three sections from each selected area of the brain were prepared with 100 micrometer intervals between them. All sections were stained with a routine hematoxylin and eosin method and studied by a light microscope.

The scoring of the brain lesions was in accordance with the research that had been done on mice (Nontprasert *et al.*, 2002).

Criteria for scoring the lesions in brain based on the findings of whole section observation:

- Unaffected, No changes were observed in microscopic fields with x 400 magnification.
- Very mild changes, Observation of average ≤ 1 degenerated neuron in each microscopic field with x 400 magnification.
- Mild changes, Observation of average $1 >$ and ≤ 2 degenerated neuron in each microscopic fields with x 400 magnifications.
- Moderate changes, Observation of average $2 >$ and ≤ 3 degenerated neuron in each microscopic fields with x 400 magnifications.
- Sever changes, Observation of average $3 >$ degenerated neuron in each microscopic fields with x 400 magnifications.

For statistical analysis, SPSS version 16 program was used. Brain and liver lesions analysis carried out by non-parametric Kruskal-wallis, Mann-Whitney u and chi-square tests.

RESULTS

Clinical findings: None of the birds died in this research after artemisinin administration. Food consumption was

reduced for hours and the decrease was completely dose dependent. Food consumption returned to the normal level slowly. Water consumption was moderately more than the previous days. In the groups that received 1250 and 2500 mg/kg, there were a few neurological signs like depression and unconsciousness in all birds but all of these signs were present in the drug vehicle group. All these neurological signs disappeared on the second day post drug intake.

Gross pathology: No necropsy lesion was found in any carcasses following a complete and systematic inspection.

Microscopic examination: Microscopic sections of spleen, heart and lungs showed no lesions. Kidney, liver and specially the brain showed some pathologic lesions.

A few kidneys from different groups showed eosinophilic intracytoplasmic inclusion bodies in renal tubules epithelium and some eosinophilic materials in the lumen of the tubules. The former one can be a sign of degeneration (Fig. 1).

Liver sections showed intracytoplasmic eosinophilic inclusion bodies, hepatocellular swelling and bile retention (Fig. 2 and 3). These are signs of hepatic degeneration (Randall and Reece, 1996). Using chi-square test, there were no relationship between dosage of the drug and frequency of the lesions occurrence and only the presence of the drug was important. Control and drug vehicle groups did not show such lesions in liver.

In brain sections, signs of neural degeneration including central chromatolysis, scattered neuronal necrosis were evident (Fig. 4, 5 and 6). There was also brain edema and spongy degeneration in some regions of nervous tissue. Comparison of the total scores of lesions in brains among different groups indicated that there was a relationship between dosage of the drug and severity of the lesions ($p = 0.001$).

By comparing the severity of lesions among groups, differences were significant in different parts: motor cortex ($p = 0.001$), cerebellar nuclei ($p = 0.004$), hind brain ($p = 0.003$) and mid brain ($p = 0.006$). The severity of lesions in each part showed a direct relationship with dose enhancement. Control and drug vehicle groups showed no brain lesions. By comparing the severity of the lesions in different parts of the brain in each group no different susceptibility was observed. Table 1 shows the mean \pm standard deviation of lesions scores in different parts of the brain.

DISCUSSION

Artemisinin and its derivatives are of relatively low acute toxicity. Although researchers mostly report definite values for the LD_{50} in animals, the results may have to be regarded with some reservation. In mammals, the

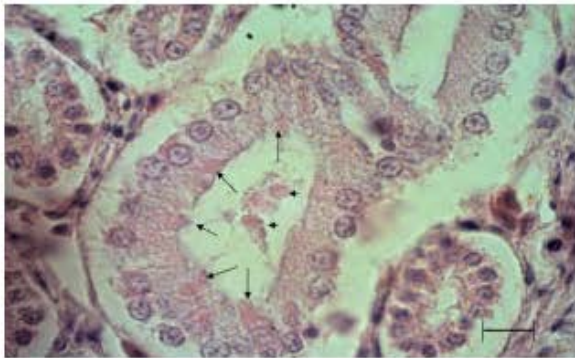


Fig. 1: Renal tubules with eosinophilic materials in lumen (Short arrows) and eosinophilic inclusions in cells (Long arrows). Bar = 10 μ m

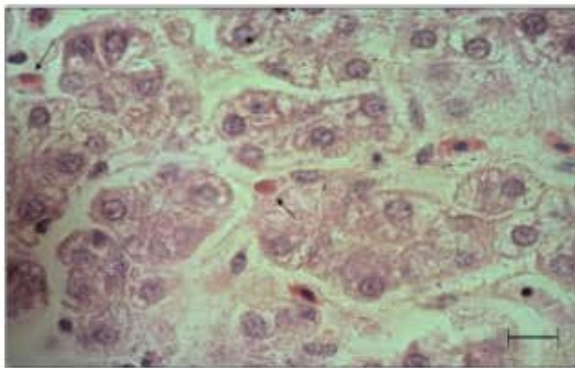


Fig. 2: Intracytoplasmic eosinophilic inclusion bodies a sign for degeneration (Arrows). Bar = 10 μ m

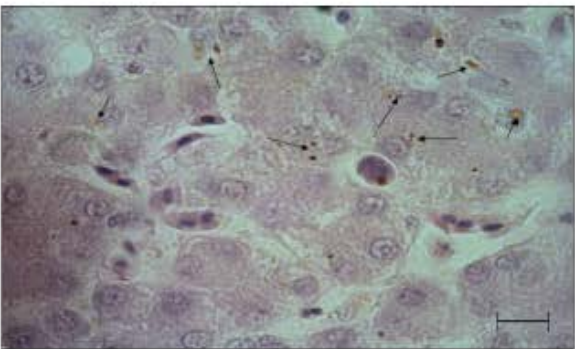


Fig. 3: Bile retention in liver (Arrows) and hepatocellular swelling. Bar = 10 μ m

range of doses in which to expect actually toxic responses is certainly well above therapeutically active doses, therefore, single dose toxicity seems not play a relevant major role in the risk benefit assessment of the artemisinins indeed. In early investigations, therapeutic indices of several hundreds upto over 1000-folds have been found for artemisinin and its derivatives,

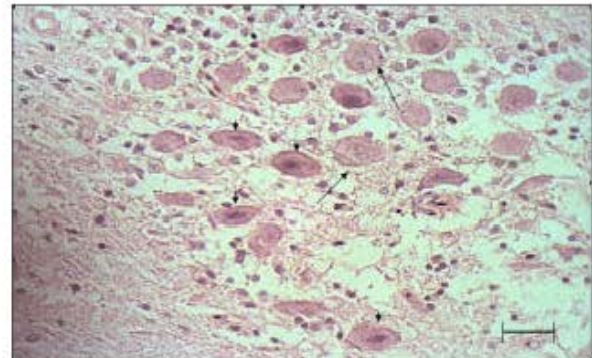


Fig. 4: Necrotic neurons (Short arrows) and alive neurons (Long arrows) in one cerebellar nucleus. Spongy change is also obvious. Bar = 25 μ m

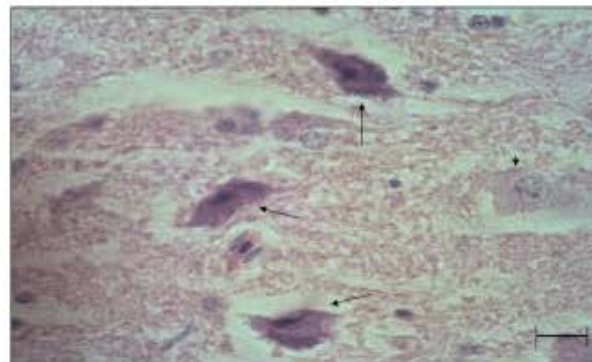


Fig. 5: Three necrotic neurons (Long arrows) and one normal one in cerebral cortex (Short arrow). Bar = 50 μ m

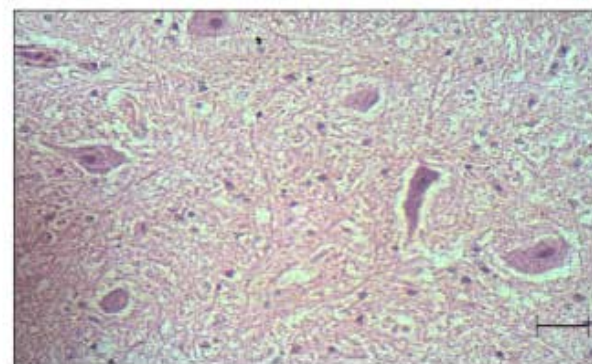


Fig. 6: Some Necrotic neurons in midbrain. Bar = 25 μ m

irrespective of the way of administration (China Cooperative Research Group, 1982). It is helpful to note that in one study the therapeutic dose of artemisinin for treatment of experimental coccidiosis in broilers by oral administration had been determined as 1-2.5 mg/kg daily (Arab *et al.*, 2006).

Table 1: Mean±SD of the lesions scoring in different regions of the brain in treatment groups

Group	Cerebral cortex	Cerebellar nuclei	Hind brain	Mid brain
10 mg/kg	0.6±0.55	0.2±0.45	0.4±0.55	0
50 mg/kg	0.8±0.45	0.6±0.55	0.8±0.44	1±0.7
250 mg/kg	1.67±0.52	1.17±0.75	1.5±0.54	1.2±0.45
1250 mg/kg	1.8±0.45	1.8±0.44	1.6±0.55	1.33±0.52
2500 mg/kg	2.4±0.55	1.8±0.45	2±0	1.6±0.55

None of the birds in the present study died after drug administration. In the higher dose groups, 1250 and 2500 mg/kg, transient neurological signs were completely similar to the drug vehicle group so we referred them to intoxicating effects of ethyl alcohol.

Histopathological examination of kidneys revealed only a very mild degeneration in renal tubules as eosinophilic intracytoplasmic inclusions. Some researches reported more severe disorders in rats such as changing of urine color, increase in blood urea (Shuhua *et al.*, 2002) and mild to moderate renal tubular necrosis (Li *et al.*, 2007). Evidence of eosinophilic inclusion bodies is a characteristic of hepatic degeneration (Randall and Reece, 1996). In our study these inclusions were observed and there was a moderate bile retention that might be due to hepatocyte swelling. Hepatic degeneration has been also reported in rats (Shuhua *et al.*, 2002) and dogs (China Cooperative Research Group 1982; Peys *et al.*, 2005). It can be due to direct action of artemisinin or its metabolites on hepatocytes. Liver is the most important organ of the drug metabolism. A small amount of artemisinin is excreted through kidney without metabolism. Excretion in bile can be another way of drug elimination (Dien *et al.*, 1997). In this research, hepatic degeneration did not show any relationship with artemisinin dosage and just the presence of the drug was important.

In the present experiment no clinical signs of neurological deficits were observed. This finding is clearly different from those of others in which transient convulsion in dogs, dizzy and nausea in humans (Price *et al.*, 1999), unstable gait, convulsion, tremor and respiratory suppression in monkey, rabbit and guinea pig (Zhao, 1985) were reported. This discrepancy may be due to several factors including species differences between mammals and birds, different route of administration, duration and dosage of drug as well as the kind of artemisinin derivative that have been used in different studies. Lipophilic derivatives of artemisinin like artemether, arteether and arteminol are more neurotoxic than hydrophilic compounds like artesunate (Gordi and Lepist, 2004). Acute neuronal necrosis, neuronal vacuolation, focal axonal swelling especially in red and vestibular nucleus and in cerebellum (Kamchonwongpaisan *et al.*, 1997) and death with neural signs (Nontprasert *et al.*, 2000) are among the reported neural lesions. Pathologic findings in the brain in the present study were central chromatolysis, mild spongy change and scattered neuronal necrosis in

different parts of the brain. They are similar to those that reported in mammals like rat (Kamchonwongpaisan *et al.*, 1997) and dog (Brewer *et al.*, 1994a,b). There are some reports from rats in which artemether did not show any clinical signs but in histopathologic examinations animals had signs of CNS abnormality in brain stem and some other parts (Genovese *et al.*, 1995; Genovese *et al.*, 1998). In this experiment we observed pathologic changes in microscopic sections of the brain. Of course, we could not find any different vulnerability in different parts of the brain with single dose administration. In the brain, lesions were dose dependent like those of other researches (Nontprasert *et al.*, 2002).

In cell culture, it has been shown that rat neuroblastoma cell line is susceptible to this drug family but not rat astrocytoma cell line (Wesche *et al.*, 1994). We could not find any alteration in glial cells, too. It seems that the lower susceptibility of glial cells to artemisinin is similar in mammals and birds. Addition of haemin or iron to these cell cultures enhanced the severity of damage but addition of ascorbic acid reduced the damages (Smith *et al.*, 1997; 1998; 2001). These findings established the role of endoperoxide bridge and free radicals in neurotoxicity of artemisinin. The most vulnerable parts of the neurons are cytoskeleton and mitochondria (Schmuck *et al.*, 2002).

Ethyl alcohol is a suitable solvent for artemisinin and in the amount that is needed for dissolving therapeutic doses of the drug, it is completely safe. However, in order to find exact LD₅₀ it's necessary to employ another safe solvent instead of alcohol. Because in too much high doses of the drug the amount of alcohol used as solvent is problematic itself.

Conclusion: Based on our results artemisinin is relatively safe drug to be used for poultry coccidiosis but there are some mild side effects in kidney, liver and particularly in nervous system so its administration must be restricted to necessary situations.

ACKNOWLEDGEMENTS

The authors wish to thank Baninajar A., Agha ebrahim Samani R. and Baharloo M. for their technical support and Pars Animal Feed Co for preparing the birds ration.

REFERENCES

Allen, P.C., J. Lydon and H.D. Danforth, 1997. Effects of components of *Artemisia annua* on Coccidia infections in chickens. *Poult. Sci.*, 76: 1156-1163.

- Arab, H.A., S. Rahbari, A. Rassouli, M.H. Moslemi and F. Khosravirad, 2006. Determination of artemisinin in *Artemisia sieberi* and anticoccidial effects of the plant extract in broiler chickens. *Trop. Anim. Health Prod.*, 38: 497-503.
- Brewer, T.G., S.J. Grate, J.O. Peggins, P.J. Weina, J.M. Petras, B.S. Levine, M.H. Heiffer and B.G. Schuster, 1994a. Fatal neurotoxicity of arteether and artemether. *Am. J. Trop. Med. Hyg.*, 51: 251-259.
- Brewer, T.G., J.O. Peggins, S.J. Grate, J.M. Petras, B.S. Levine, P.J. Weina, J. Swearngen, M.H. Heiffer and B.G. Schuster, 1994b. Neurotoxicity in animals due to arteether and artemether. *Trans. Royal Soc. Trop. Med. Hyg.*, 88: 33-36.
- China Cooperative Research Group, 1982. Studies on the toxicity of quinghaosu and its derivatives. *J. Tradit. Chin. Med.*, 2: 31-38.
- Dien, T.K., D.E. Vries, P.J. Xuan Khanh, N. Koopmans, R. Binh, L.N. Dinh, D. Duc, P.A. Kager and C.J. Van Boxtel, 1997. Effect of food intake on pharmacokinetics of oral artemisinin in healthy Vietnamese subjects. *Antimicrob Agents Chemother.*, 41: 1069-1072.
- Fishwick, J., W.G. Mclean, G. Edwards and S.A. Ward, 1995. The toxicity of artemisinin and related compounds on neuronal and glial cells in culture. *Chem. Biol. Interact.*, 96: 263-271.
- Genovse, R.F., D.B. Newman, Q. Li, J.O. Peggins and T.G. Brewer, 1998. Dose-Dependent brainstem neuropathology following repeated arteether administration in rats. *Brain Res. Bull.*, 45: 199-202.
- Genovse, R.F., J.M. Petras and T.G. Brewer, 1995. Arteether neurotoxicity in the absence of deficits in behavioural performance in rats. *Ann. Trop. Med. Parasitol.*, 89: 447-449.
- Gordi, T. and E.I. Lepist, 2004. Artemisinin derivatives: Toxic for laboratory animals, safe for humans? *Toxicol. Lett.*, 147: 99-107.
- Kamchonwongpaisan, S., P. McKeever, P. Hossler, H. Ziffer and S.R. Meshnick, 1997. Artemisinin neurotoxicity: Neuropathology in rats and mechanistic studies *in vitro*. *Am. J. Trop. Med. Hyg.*, 56: 7-12.
- Kaptein, S.J.F., T. Efferth, M. Leis, S. Rechter, S. Auerochs, M. Kalmer, C.A. Bruggeman, C. Vink, T. Stamminger and M. Marschall, 2006. The anti-malaria drug artesunate inhibits replication of cytomegalovirus *in vitro* and *in vivo*. *Antivir. Res.*, 69: 60-69.
- Li, Q.C., L.H. Xie, T.O. Johnson, Y. Si, A.S. Haeberle and P.J. Weina, 2007. Toxicity evaluation of artesunate and artelinate in *Plasmodium berghei* infected and uninfected rats. *Trans. Royal Soc. Trop. Med. Hyg.*, 101: 104-112.
- Nontprasert, A., S. Pukrittayakamee, A.M. Dondorp, R. Clemens, S. Looareesuwan and N.J. White, 2002. Neuropathologic toxicity of artemisinin derivatives in a mouse model. *Am. J. Trop. Med. Hyg.*, 67: 423-429.
- Nontprasert, A., S. Pukrittayakamee, M. Nosten-Bertrand, S. Vanijanonta and N.J. White, 2000. Studies of the neurotoxicity of oral artemisinin derivatives in mice. *Am. J. Trop. Med. Hyg.*, 62: 409-412.
- Peys, E., J. Vandenkerckhove, J. Van Hemel and B. Sas, 2005. Intermediate-term toxicity of repeated orally administered doses of the antimalarial β -artemether in dogs. *Exp. Toxic. Pathol.*, 57: 299-304.
- Price, R., M. Van Vugt, L. Phaipun, C.H. Luxemburger, J. Simpson, R. McGready, F. Ter Kuile, A.M. Kham, T. Chongsuphajaisiddhi, N.J. White and F. Nosten, 1999. Adverse effects in patients with acute falciparum malaria treated with artemisinin derivatives. *Am. J. Trop. Med. Hyg.*, 60: 547-555.
- Randall, C.J. and R.L. Reece, 1996. 5. Liver. In: *Color atlas of avian histopathology*, 1st Edn. Mosby-Wolfe, London, pp: 82-83.
- Schemuk, G., E. Roehrdanz, R. Haynes and R. Kahl 2002. Neurotoxic mode of action of artemisinin. *Antimicrobial Agents and Chemotherapy*, 46: 821-827
- Sen, R., S. Bandyopadhyay, A. Dutta, G. Mandal, S. Ganguly, P. Saha and M. Chatterjee, 2007. Artemisinin triggers induction of cell-cycle arrest and apoptosis in *Leishmania donovani* promastigotes. *J. Med. Microbiol.*, 56: 1213-1216.
- Shuhua, X., Y. Yanqing, Y. Qiqing, J. Utzinger, G. Huifang, J. Peiying, M. Jinying, G. Jian, R. Bergquist and M. Tanner, 2002. Potential long-term toxicity of repeated orally administered doses of artemether in rats. *Am. J. Trop. Med. Hyg.*, 66: 30-54.
- Singh, N.P. and H.C. Lai, 2004. Artemisinin induces apoptosis in human cancer cells. *Anticancer Res.*, 24: 2277-2280.
- Smith, S.L., J. Fishwick, W.G. Mc Lean, G. Edwards and S.A. Ward, 1997. Enhanced *in vitro* neurotoxicity of artemisinin derivative in the presence of haemin. *Biochem. Pharmacol.*, 53: 5-10.
- Smith, S.L., J.I. Maggs, G. Edwards, S.A. Ward, B.K. Park and W.G. Mc Lean, 1998. The role of iron in neurotoxicity: A study of novel antimalarial drugs. *Neurotoxicology*, 19: 557-560.
- Smith, S.L., C.J. Sadler, C.C. Dodd, G. Edwards, S.A. Ward, B.K. Park and W.G. Mc Lean, 2001. The role of glutathione in the neurotoxicity of artemisinin derivatives *in vitro*. *Biochem. Pharmacol.*, 61: 409-416.
- Wesche, D., M.A. Decoster, F.C. Tortella and T.G. Brewer, 1994. Neurotoxicity of artemisinin analogs *in vitro*. *Antimicrob Agents Chemother.*, 38: 1813-1819.
- Zhao, Y., 1985. Studies on systemic pharmacological effects of artesunate. *J. Trop. Med. Hyg.*, 88: 391-396.