

ISSN 1682-8356
ansinet.org/ijps



INTERNATIONAL JOURNAL OF
POULTRY SCIENCE

ANSI*net*

308 Lasani Town, Sargodha Road, Faisalabad - Pakistan
Mob: +92 300 3008585, Fax: +92 41 8815544
E-mail: editorijps@gmail.com

Outbreak of Velogenic Viscerotropic Newcastle Disease in Broilers

I.W. Musa¹, P.A. Abdu¹, A.K.B. Sackey¹, S.B. Oladele¹, S. Lawal¹ and I.U. Yakubu²

¹Faculty of Veterinary Medicine, Ahmadu Bello University, Zaria, Nigeria

²Ministry of Agriculture, Gombe State, Nigeria

Abstract: This report describes an outbreak of an acute, highly lethal, Newcastle Disease (ND) in two broiler flocks that were intensively managed and vaccinated against Newcastle disease. The broiler flocks (325) were four weeks and (450) were six weeks old at the time of the outbreak. Clinical characteristics of the disease included a 100% morbidity, increasing high mortality i.e. 40 birds (day one), 70 birds (day two), 180 (day three) and the entire flocks consisting of 755 birds were lost by the fifth day. Clinical features observed included severe depression, gasping, anorexia, cyanosis and subcutaneous haemorrhages of the legs and shank. Gross lesions seen were severe congestion of skeletal muscles and visceral organs and severe haemorrhages and congestion of the proventriculus, cecal tonsils and trachea, air sacculitis with severely congested and pneumonic lungs were observed as well. Ten cloacal swabs from dead and sick birds were tested using a Rapid Newcastle Disease and Avian Influenza Antigen Detection Test Kits. This Chromatographic-immunoassay tested positive for ND and negative for AI confirming the presence of ND viral antigen. Four dead and live birds taken to National Veterinary Research Institute (NVRI) Vom, Nigeria for further confirmation were tested using rapid test kit, haemagglutination inhibition test and viral isolation. These tests were also negative for AI but positive for vvND. Clinical signs and gross lesions of ND and Highly Pathogenic Avian Influenza (HPAI) seem not to be distinguishable in the field. This is likely going to affect disease reporting and actions to be taken. Vaccination against ND should not be totally relied upon especially when birds are not seromonitored pre and post vaccination.

Key words: Diagnosis, mortality, newcastle disease virus, broilers

INTRODUCTION

Newcastle disease is an acute, highly contagious, rapidly spreading viral disease affecting birds of all ages. It varies widely in type and severity of symptoms (Alexander, 2000; Abdu, 2005; Saidu *et al.*, 2006). The global impact of ND is enormous and it is responsible for international trade barriers of poultry and poultry products (Alexander and Jones, 2003). It is a devastating disease of poultry particularly in village and backyard poultry and a major constraint to developing poultry industry (Alexander, 1988; Spradbrow, 1993), where control remains extremely difficult or even impossible (Alexander and Jones, 2001).

The first documented report of ND in Nigeria was in Ibadan (1952) and later in other parts of the country (Fatumbi and Adene, 1979; Ezeokoli *et al.*, 1984; Baba *et al.*, 1995). In Nigeria the disease is common and more severe during the cold windy hamatan (Abdu *et al.*, 1992; Saidu *et al.*, 1994; Halle *et al.*, 1999). Farms where mixed species, exotic and local breeds are kept experience more outbreaks (Abdu *et al.*, 1992). Countries with endemic vvND and highly deficient biosecurity measures rely on intensive vaccination programme for protection against ND (Simon and Durham, 2006). Vaccine administration at 7-10 day intervals throughout the broiler grow-out period to 30-40 days depending on the age of depletion have been

reported to be effective (Simon and Durham, 2006). Newcastle disease transmission is mainly through ingestion, air route transmission is favored by suitable climatic factors and high poultry farm concentrations (McFerren, 1989; Alexander, 2001). Severity of ND depends on viral tissue tropism, virulence of the virus, immune status and route of exposure, duration and magnitude of infecting dose, host susceptibility and environmental stress factors (McFerren, 1989; Alexander, 2001; Abdu, 2005).

Clinical signs of ND are mild to severe respiratory, gastrointestinal and nervous disorders. Uncommon signs of petechiation, cyanosis and edema of combs, wattles, face especially eye lids are occasionally seen in especially the viscerotropic-velogenic (Doyle's form or Asiatic) ND outbreaks (Benard, 1981; OIE, 2000). Gross lesions include congestion and hemorrhages of skeletal and visceral organs (Beard and Hanson, 1981; Abdu and Saidu, 2000; Okoye *et al.*, 2000; Abdu *et al.*, 1992). Presumptive diagnosis of ND is based on clinical signs and gross lesions, while confirmatory diagnosis is by viral isolation and characterization (Majiyagbe and Nawathe, 1981). Based on signs and gross lesions therefore, the vvND form may not be easily distinguishable from and may likely affect HPAI reporting in the field.

MATERIALS AND METHODS

Case report: This report describes an outbreak of a velogenic-viscerotropic Newcastle disease in ND vaccinated four and six weeks old broilers.

On the 29th February, 2008, 15 live and dead birds from two flocks consisting of 325-four week's old and 450-six weeks old intensively managed broilers were reported. The birds were vaccinated against Gumboro disease at 2 weeks and Newcastle disease with la Sota in drinking water at 3 weeks of age. Clinical manifestations of the disease included sudden, high and increasing mortality noticed first on the 29th February, 2008 with 10 dead and 5 clinically sick birds presented to the veterinary clinic Gombe. History revealed that the problem started with the older flock and rapidly spread within and to the younger flock. Clinical signs seen were severe depression (Plate I), dyspnoea, swollen eyelids, gasping, rales and greenish-yellow diarrhea, severe haemorrhages and cyanosis of the legs and shanks (Plate II).

Gross lesions included severe congestion of skeletal muscles (Plate III), all visceral organs were congested and haemorrhagic, severe hemorrhages were also seen in the proventriculus (Plate IV), caecal tonsils and trachea (Plate V).

A farm visit indicated inadequate ventilation in the poultry house, very poor structural and operational biosecurity. Therapeutic agents ranging from multivitamins (Vitalyte, Amintotal) antibiotics (Neoceryl, Gentamycin, doxycyclin, tylosin powder) to locally prepared virucidal liquids (Virucin k) were administered in drinking water prior to presentation. Cloacal swabs were tested using rapid antigen test kit according to manufacturers guide lines. Blood samples were aseptically collected from brachial veins; sera were processed and tested using OIE (2005) standard procedure for haemagglutination inhibition test.

Differential diagnosis: Based on the high morbidity (100%) and mortality (100%), severe clinical signs and gross lesions seen therefore, differential diagnosis of AI, vvND, acute fowl cholera and Poisoning were made.

A tentative diagnosis: A tentative diagnosis of avian influenza was made based on the history of AI in Nigeria, clinical signs and gross lesions observed.

Rapid field and laboratory diagnosis: Ten cloacal samples of both dead and live birds from the two flocks were tested according to the manufacturers guide line using ND and AI antigen detection test kits manufactured by Animal Genetics Inc. South Korea. Haemagglutination inhibition test was conducted on sera collected from the live but diseased birds. The



Plate I: Severely depressed 3 and 6 week-old broilers showing slight cyanosis of the combs and wattles, prostration, somnolence and dropped beak on the ground

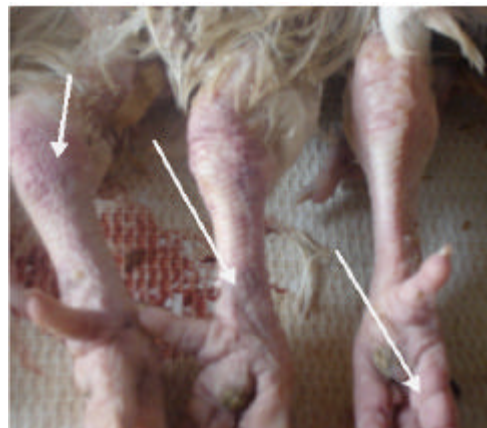

Plate II: Subcutaneous haemorrhages on the legs and shanks of Newcastle Disease infected 6 week-old broilers



Plate III: Severe congestion of the pectoral muscles of ND infected 3 and 6 week-old broilers (arrow)

Gombe state AI Desk Officer was contacted and 4 live birds were taken to NVRI, Vom for further laboratory investigation.

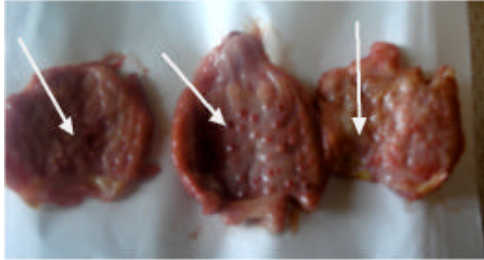


Plate IV: Severe haemorrhages of the proventriculus (arrow) of ND infected 3 and 6 week-old broilers

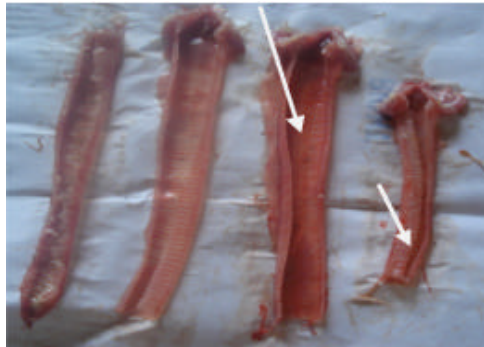


Plate V: Congested and haemorrhagic trachea (arrow) in ND infected 3 and 6-week-old broilers

RESULTS

Within 10-15 min, the test device was positive for ND and negative for AI, also HI showed high antibody titre $10.0 \log_2$ of ND when 4HAU unit was used and vvND virus was isolated.

DISCUSSION

Lack of pathognomonic signs associated with ND infections, similar clinical and gross lesions in AI and velogenic viscerotropic Newcastle disease make differentiating ND and HPAI very difficult in the field as seen in this case because an earlier diagnosis of AI was made based on signs, gross lesions and history of HPAI outbreak in Nigeria (FAO, 2006; NADIS, 2006). However, the case was finally diagnosed as ND. Doyle, who first reported and described Newcastle disease also admitted the difficulty in differentiating ND from AI and since then referred to it as "pseudo-fowl plague" (Stubbs, 1965).

There is hardly any poultry farm, commercial or rural that has not experienced ND (Alexander, 2001). Most farmers rely so much on vaccination to keep ND in check and appear to have taken vaccination as an alternative to biosecurity. However, severe forms of ND continued to occur in ND vaccinated flocks (Simon and Durham, 2006; Abdu *et al.*, 2008). Vaccination in addition may prevent disease and deaths but may not prevent viral

replication on challenge and could even lead to virulent virus becoming endemic (Alexander, 2001). Newcastle disease outbreak can be associated with very high morbidity and mortality (100%) despite vaccination as seen in this case. It was further reported that insufficient nutrition, stressful climatic factors, levels of maternally derived antibodies and viral challenge in the field, quality and health status of the day old chicks, strain of vaccine used, equipment and route used in the vaccination can influence the outcome of the disease (Alexander and Jones, 2003). It is possible that some of these factors could have worsen the outcome of this outbreak since there was inadequate ventilation in the affected farm, the owner purchased his vaccine that was not known to us and vaccinated the birds himself and the outbreak occurred during the cold dry hamatan period of the year. Non judicious application of therapeutic agents in the phase of virulent ND outbreak may further lead to higher economic losses as seen in this case because the therapeutic agents used and the cost of labour and consultation were estimated to be over =N=15,000 (Nigerian currency). A rapid AI and ND diagnosis in field situations is helpful as first step to distinguish the two disease conditions and to take an appropriate action that may prevent delays where actions are promptly required and where laboratory facilities are not readily available this is because avian influenza has greater public health and economic implications and therefore requires a more prompt diagnosis and action to avoid human exposure. The Rapid Antigen Detection Test was positive for ND; however, this test is not confirmatory despite its high sensitivity and specificity. Further evaluation of the test kit may be necessary; however, it may be useful for an initial decision before a confirmed status (which may take several days) is established. The need for rapid diagnosis and differentiation of vvND, HPAI and other respiratory diseases of poultry have been emphasized, but this is currently possible by PCR or multiplex-PCR and gene microassay which are expensive and may require standard laboratories (Simon and Durham, 2006). Under field conditions therefore, prevention of ND should not be depended only on vaccination as it may fail to protect the vaccinated birds. This is evident in this report. Vaccinated birds against ND with antibody titres $>4.5-5.0 \log_2$ appear to withstand virulent attack of NDV (Simon and Durham, 2006). Seromonitoring may be necessary to monitor the response of flocks to vaccination and this may further assist a retrospective diagnosis following exposure to ND virus. A 3-fold increase in antibody titre by HI with associated decline in egg production or increased mortality in breeder and commercial flocks is suggestive of exposure to ND virus. Immunization with attenuated, inactivated or genetically engineered vector vaccines and effective biosecurity measures are for now the major considerations in the prevention of ND outbreaks

(Simon and Durham, 2006). Effective vaccines and vaccinations must consider among others strains of ND virus to which flocks are likely going to be exposed, climatic conditions, level of maternal immunity conferred to offspring and most importantly all vaccines to be used should be vaccines tested and trusted for use by the regulatory authorities.

REFERENCES

- Abdu, P.A., U.M. Mera and L. Saidu, 1992. A study of chicken mortality in Zaria, Nigeria. Proceedings of National Workshop on Livestock and Veterinary Services, Vom, Nigeria, pp: 51-55.
- Abdu, P.A. and L. Saidu, 2000. Problems associated with diagnosis in poultry Practice. *Agvet Int.*, 1: 11-13.
- Abdu, P.A., 2005. Evolution and the pathogenicity of Newcastle Disease virus and its implication for diagnosis and control. Book of proceedings 29th November-1st December Workshop on improved Disease Diagnosis, Health, Nutrition and Risk management Practice in Poultry, Ahmadu Bello University Zaria, Nigeria.
- Abdu, P.A., A.M. Wakawa, L. Sa'idu, T.M. Joanis and M.Y. Fatihu, 2008. A severe form of Newcastle disease caused by a mesogenic virus in five-week old broilers in Zaria. *Vet. Clin. Practice Bull.*, 1: 1-6.
- Alexander, D.J., 1988. Newcastle Disease: Methods of spread, In: Alexander, D.J and Kluwer, M.A. (Eds) *Diseases of Poultry*, Academic Publishers Boston, pp: 256-272.
- Alexander, D.J., 2000. Newcastle disease and other avian paramyxoviruses. *Rev. Sci. Tech.*, 19: 443-462.
- Alexander, D.J., 2001. Newcastle disease. *Br. Poult. Sci.*, 42: 5-22.
- Alexander, D.J. and R.C. Jones, 2001. Newcastle disease. In: Jordan, F.T.W. (Ed). *Poultry Diseases*, pp: 55-63 (W.B.Saunders).
- Alexander, D.J. and R.F. Jones, 2003. Newcastle disease, other paramyxovirus and pneumovirus infections. In: Y.M. Saif (Ed) *Diseases of poultry*, Iowa State Press, pp: 63-92.
- Baba, S.S., A.D. El-Yuguda and M.M. Baba, 1995. Serological evidence of mixed infection with Newcastle disease and egg drop syndrome 1976 virus in village chickens in Borno State. *Trop. Vet.*, 16: 137-141.
- Benard, C.E., 1981. Immunity to Newcastle disease and avian influenza. *Avian Immunology*. In: Rose, M.E., Payne.IW and Freeman, BM (Eds). *Poult. Sci. Symp.*, No. sixteen, pp: 179-185.
- Ezeokoli, C.D., J.U. Umoh, A.A. Adesiyun and P.A. Abdu, 1984. Prevalence of Newcastle disease virus antibodies in local and exotic chickens under different management systems in Nigeria. *Bull. Anim. Health Prod. Afr.*, 3: 32-253.
- Fatumbi, O.O. and D.F. Adene, 1979. Susceptibility of the Nigerian local chicken to a fulminating Newcastle disease outbreak. *Nig. Vet. J.*, 8: 30-32.
- Food and Agricultural Organization (FAO) Manual, 2006. Preparing for highly pathogenic avian influenza, 3: 1-64.
- Halle, P.D., J.U. Umoh, L. Saidu and P.A. Abdu, 1999. Prevalence and seasonality of Newcastle disease in Zaria Nigeria. *Trop. Vet.*, 17: 53-62.
- Majiyagbe, K.A. and D.R. Nawathe, 1981. Isolation of virulent form of Newcastle disease from apparently normal ducks. *Vet. Record*, 2: 108-187.
- McFerrer, J.B., 1989. Control of Newcastle disease in Northern Ireland. *Proceeding Avian Exotic Disease Control Seminar*. Animal Health Report 2, NSW Agriculture and Fisheries, Glendfield, NSW, Australia, pp: 16-21.
- National Animal Disease Information and Surveillance (NADIS), 2006. *Bulletin of the Federal Department of Livestock and Pest Control Services, Nigeria*, No. 2, pp: 1, 15th October, 2006.
- Office International des Epizootics (OIE), 2000. Newcastle disease. In: *Manual of Diagnostic Tests and Vaccines for Terrestrial Animals*, adopted version. Chapter 2.6.12, pp: 1-24.
- Office International des Epizootics (OIE), 2005. Avian influenza. In: *Manual of Diagnostic Tests and Vaccines for Terrestrial Animals*, adopted version. Chapter 2.7.12, pp:1-25.
- Okoye, L.O., A.O. Agu, C.N. Chineme and G.O.N. Echeaonwu, 2000. Pathological characterization in chickens of a velogenic Newcastle disease virus isolated from a Guinea fowl. *Veterinary Pays Trop.*, 3: 325-330.
- Saidu, L., P.A. Abdu, J.U. Umoh and U.S. Abdullahi, 1994. Diseases of Nigerian indigenous chickens. *Bull. Anim. Health Prod. Afr.*, 42: 19-23.
- Saidu, L., P.A. Abdu, L.B. Tekdek, J.U. Umoh, M. Usman and S.B. Oladele, 2006. Newcastle disease in Nigeria. *Nig. Vet. J.*, 2: 23-32.
- Simon, M.S. and N.C. Durham, 2006. Newcastle disease revisited. *World Poult. J.*, 22: 48-50.
- Spradbrow, P.B., 1993. Newcastle disease in village chickens. *Poult. Sci. Rev.*, 3: 57-96.
- Stubbs, E.L., 1965. Fowl plague. In: Biester H.E. and Schwarte, L.H. (Eds), *Diseases of Poultry*, (Iowa State University Press Ames, USA., pp: 813-822.