

ISSN 1682-8356
ansinet.org/ijps



INTERNATIONAL JOURNAL OF
POULTRY SCIENCE

ANSI*net*

308 Lasani Town, Sargodha Road, Faisalabad - Pakistan
Mob: +92 300 3008585, Fax: +92 41 8815544
E-mail: editorijps@gmail.com

Effects of Feeding Diet Rich in Mycotoxins on the Health and Growth Performances of Broiler Chicken

P.A. Okiki, T.I. Ojjezeh and A.O. Ogbimi
Department of Microbiology, University of Benin, Benin City, Nigeria

Abstract: Low production performances in Nigerian poultry industry is of a serious concern. This study, an experimental exposure of broiler chicken to feed naturally contaminated with mycotoxins, is part of the efforts to unravel this problem of low productivity. Broiler chickens aged 1 day to 8 weeks were fed with diet compounded with naturally contaminated raw materials. Another set of day old broiler chicks were fed with feed compounded with high quality materials and served as control. Total aflatoxin and ochratoxin in each diet were determined by ELISA technique. The effects of mycotoxins on the birds were determined for growth performances, immunological status, as well as general well being of the birds. The total aflatoxin and ochratoxin concentrations in test feed were 200 ppb and 10 ppb respectively, while the control feed contained 15 ppb aflatoxin with no detectable level of ochratoxin. Birds fed with mycotoxin-rich diet had significantly lower growth performances ($p = 0.012$) and survival rate than control birds. Birds fed on mycotoxin rich diet had lower Infectious Bursal Disease (IBD) antibody titres (4280 ± 1470) than controls (6780 ± 1250), an indication of deleterious effect on body immune responses. There is need to monitor and enforce feed quality control in developing countries to ensure that poultry production is economically viable, so that the industry can grow.

Key words: Chicken, contaminated-feed, health-hazard, mycotoxicosis, production performances

INTRODUCTION

Mycotoxins are fungal secondary metabolites which are harmful to animals and humans producing mycotoxicosis upon exposure (Jacobsen *et al.*, 1993; Varga and Toth, 2005). The most important mycotoxins in feeds and food products are aflatoxins, ochratoxins and patulin produced mainly by *Aspergillus* and *Penicillium* species, as well as the *Fusarium* toxins which include trichothecenes, zearalenone and fumonisins (Varga and Toth, 2005).

Mycotoxin contaminated diet may lead to substantial economic losses in animal husbandry due to feed refusal, poor feed conversion, reduced weight gain, immunosuppression, interference with reproductive performances and residues in animal products (Ortatali *et al.*, 2005; Varga and Toth, 2005). The harmful effects of various mycotoxins on animals and humans have been well documented by Jacobsen *et al.* (1993).

Aflatoxins are the most studied mycotoxins (Thrasia, 2003). Aflatoxins are produced by *Aspergillus flavus* and *Aspergillus parasiticus* (Ortatali *et al.*, 2005) and could as well be produced by members of the genera *Penicillium* and *Rhizopus* (Thrasier, 2003). Aflatoxin in feed causes aflatoxicosis when fed to animals. The disease which is a major concern in poultry production is characterized by listlessness, poor feed utilization,

decreased weight gain and production, susceptibility to infections and high mortality (Ortatali *et al.*, 2005). Aflatoxins have also been reported to cause deleterious pathological, biochemical and haematological changes, as well as impairment of the cellular and humoral immune responses (Ibrahim *et al.*, 2000; Oguz *et al.*, 2003; Ortatali *et al.*, 2005).

Ochratoxin is produced by the fungi *Aspergillus ochraceous* and *Penicillium verrucosum*. Ochratoxin is primarily kidney toxin, but in high concentration they can cause liver damage (Jacobsen *et al.*, 1993).

The Nigerian poultry industry has been facing a lot of challenges in recent times, ranging from avian influenza outbreak (OIE, 2006; Obayelu, 2007), prevalence of multi-drug resistant bacteria (Okiki and Ogbimi, 2008, 2010), as well as high cost and low quality feed raw materials. There is proliferation of small scale feed mills and toll-milling outfits. There are no quality control measures in such places and in most cases they are managed by non-professionals. Farmers do patronize such outfits more than products of standard feed mills because of cheaper prices.

The objective of this study was to assess the effects of feeding molded feed rich in mycotoxins on the health and growth performances of chickens.

MATERIALS AND METHODS

Experimental exposure of broiler chickens to mycotoxins contaminated feed: Anak titan broiler day-old chicks (eighty) were divided into two groups of forty each. Group A birds were fed with feed compounded using high quality raw materials and served as control. Groundnut cake was used as major protein source. For group B birds, feeds were compounded using the same materials as for group A, but with inclusion of molded GNC. The molded raw materials used was obtained from the stock of a small scale feed mill. The percentage Crude Protein (CP) and Metabolizable Energy (ME) for each raw material used was determined in a commercial laboratory, Fish and Poultry Diseases Diagnostic Laboratory, Animal Care Services Limited, Ogere-Remo, Ogun State, Nigeria. Feed were compounded to meet 23% CP and 3000 Kcal ME for broiler starter mash and 20% CP and 2900 Kcal ME for broiler finisher mash. To ensure that the levels of mycotoxins in feed were maintained relatively constant throughout the experiment the quantities of contaminated GNC in group B feed were the same for starter and finisher feeds.

Birds in the two groups were fed with their respective broiler starters and finishers mash for 4 weeks each. The two groups of birds were subjected to the same environmental condition, received necessary vaccination and medications. Birds were observed daily for evidence of ill health and mortality and were weighed weekly.

Aflatoxin and ochratoxin assays in feed: The concentration of aflatoxin in compounded feed samples were determined by a direct competitive Enzyme-Linked Immunosorbent Assay (ELISA), using the Agra Quant[®] Total Aflatoxin Assay 4/40 Kits (Romer Laboratory Inc., Singapore). Twenty grams of ground feed samples were added to 100 ml of 70% methanol for extraction of aflatoxin and filtered. The filtrate and enzyme conjugated aflatoxin were mixed and added to antibody coated microwell. Aflatoxin in samples and standards were allowed to compete separately with enzyme conjugated aflatoxin for antibody binding sites. After a step of 5 washes, an enzyme substrate was added and blue colour developed. This was followed by addition of stop solution. Absorbances were read at 460 nm by a computerized microplate reader and total aflatoxin expressed in parts per billion (ppb).

The concentration of ochratoxin in each feed sample was determined using AgraQuant[®] Ochratoxin Assay Kits (Romer Laboratory Inc., Singapore). The technique is also a direct competitive ELISA. The procedure was same as described for aflatoxin assay.

Blood sampling: At eight weeks of age, 0.5-1.0 ml blood were collected via the wing veins from 20 birds per

group into bottles without anticoagulant. Blood samples were allowed to clot, sera separated and used for Infectious Bursal Disease (IBD) antibody assay.

IBD antibody assay: IBD antibody levels were determined using the Idexx ELISA antibody technique and kits, flock check[®] (Idexx Laboratories, USA). The technique is an indirect ELISA. Fifty microlitres of 1:500 dilutions of sera were placed in antigen polystyrene plate. Following incubation for 60 min at room temperature, the wells were washed to remove unbound antibody. Conjugate was then added and allowed to incubate at room temperature. The wells were washed again and an enzyme substrate-chromogen added. Plates were incubated for 10 min followed by addition of a stop solution. The colour change was read photometrically at optical density of 650 nm with the aid of fully automated ELISA plate reader.

Statistics: The mean and Standard Deviation (SD) were calculated for weight and IBD antibody titres and expressed as mean \pm SD. Paired t test was used to test for significant differences in growth performances and survival rate between the control and test birds. Wilcoxon sign ranked test was used to compare the IBD antibody titres between the test and control birds. The probability $p < 0.05$ was considered for minimum significant difference. All statistical analyses were performed using the SPSS 15.0 for windows.

RESULTS

The aflatoxin concentrations in the contaminated and control feeds, fed to broiler chickens, were 200 ppb and 15 ppb respectively. The ochratoxin concentrations were found to be 10 ppb for test feed and nil for control.

The mycotoxins fed birds recorded significantly lower growth performances ($T = 3.210$, $p = 0.012$) than control (Fig. 1). Survival rate was significantly reduced for test birds compared to controls ($T = 3.850$, $p = 0.007$). At the end of 8 weeks, 90% of the control and 55% of test birds were left (Fig. 2). Five (22.73%) of the 22 birds left for test birds had leg deformities, while only 1 (2.78%) of the 36 control birds left was lame. There was coccidiosis infection during the rearing period. The disease was not severe and easily controlled with coccidiostats among the control birds, but for the test birds coccidiosis was severe and was the major cause of death among this group of birds.

The range (mean \pm SD) of IBD antibody titres obtained: 5330-7910 (6780 \pm 1250) and 2310-6790 (4280 \pm 1470) for control and test birds respectively, were significantly different ($p = 0.003$). Two of the test birds (9.09%) had antibody titre values below the protective level of 2500 (Idexx ELISA). The least titre value obtained in sera of the control birds (5330) was higher than twice the 2500 limit.

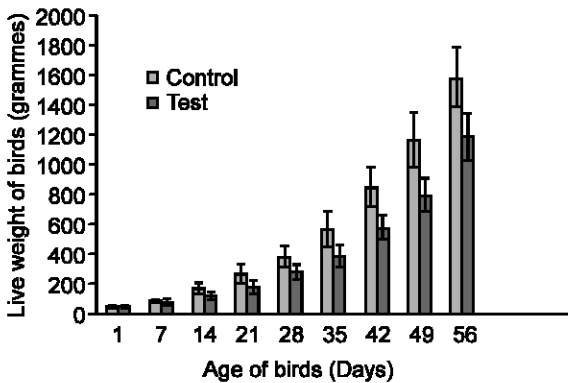


Fig. 1: Weight variation of broiler chicken fed with mycotoxin rich diet from day old ($p = 0.012$)

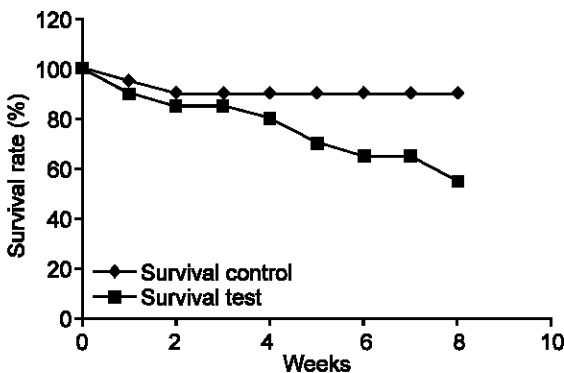


Fig. 2: Survival of broiler chicken fed with mycotoxin rich diet from day old ($p = 0.007$).

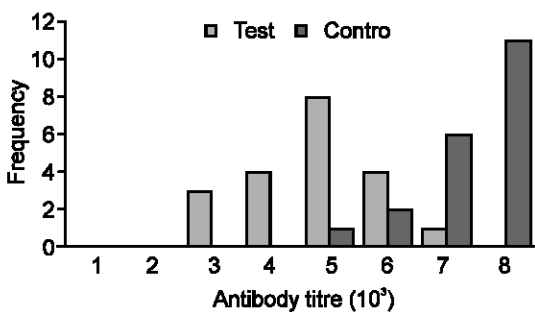


Fig. 3: IBD antibody titres of broiler chickens fed with diet rich and control ($p = 0.003$, Wilconxin Sign Ranked Test)

DISCUSSION

In the natural environment different types of fungi contaminate feed and feed raw materials thereby enriching such materials with their mycotoxins. The aflatoxin and ochratoxin concentrations reported in test feed is an indication that various forms of mycotoxins may be present in the diet.

In the study broiler chickens fed with mycotoxins rich diet recorded significantly lower growth performances ($p =$

0.012) and survival rate ($p = 0.007$) than controls. These results were in agreement with earlier studies. Lowered growth rate and increased mortality have been associated with feeding broiler with contaminated diets rich in aflatoxin (Oguz and Kutoglu, 2000), ochratoxin A and penicillanic acid (Stoew *et al.*, 2004) and fumonisins (Santurio, 2000). Birds with lameness/ paralysis of legs were higher among test birds (25%) controls (2.7%). It has been reported that aflatoxin may cause alteration of calcium and inorganic phosphate (Glahn *et al.*, 1991). This may be responsible for increased leg deformities recorded among test birds in this study. Oguz and Kutoglu (2000) reported a significant decrease in serum inorganic phosphate in 100 ppb Aflatoxin-fed chicks than controls.

The control of coccidiosis in the two groups of birds was not carried out by vaccination, rather by prophylactic treatment with coccidiostats. This was done so as to observe how the two groups of birds would respond to natural challenges of coccidial organisms which are prevalent in the environment where this study was carried out (Okiki, 2007). The result obtained showed that birds fed with mycotoxin rich diet succumbed more to natural coccidial infection than control. This is an indication that birds fed with molded feed will suffer more from outbreaks of infectious diseases.

The assay for IBD antibody levels in the two groups of birds were carried out to observe how birds fed with mycotoxins-rich diet will respond to vaccination, also to indirectly assess the humoral immune status of the birds. In the study, significantly lower IBD antibody titres were obtained for birds fed with mycotoxin-rich diet than control. Ten percent of the test chickens had IBD antibody titres below the protective level of 2500 (Idexx ELISA), which is an indication that this population of birds can succumb to IBD infection and serve as a source of outbreak to the entire flock. Okiki and Ogbimi (2008), using Idexx ELISA kits (Idexx Laboratories, USA), reported IBD antibody titres of 3149 ± 1767 (range, 981-6780) in an outbreak of gumboro among 7 week old pullet flock and IBD antibody titres of 7289 ± 1024 (range, 5470-8468) in a protected flock of the same age and breed which served as control.

Conclusion and recommendation: The results obtained in this study indicated that the various mycotoxins contained in molded feed may work in synergy affecting the general health and production performances of poultry. This will often result in high economic losses and lead to lack of interest by investors in poultry production. The need to improve and sustain poultry production in particular and animal husbandry in general, in underdeveloped countries where animal protein consumption per head is very low, can not be over emphasized.

The following recommendations are made:

- (a) Quality control measures should be in place and raw materials should be analyzed for the presence of mycotoxins before used to produce feed.
- (b) Feed should always be compounded with inclusion of mycotoxin binders as additives.
- (c) There should be laws guiding the activities of feed millers and toll milling outfits and such laws should be enforced.

REFERENCES

- Glahn, R.P., K.W. Beers, W.G. Bottje, R.F. Wideman, W.E. Huff and W. Thomas, 1991. Aflatoxicosis alters avian renal function, calcium and vitamin D metabolism. *J. Toxicol. Environ. Health*, 34: 309-321.
- Ibrahim, I.K., A.M. Shareef and K.M.T. Al-Joubory, 2000. Ameliorative effects of sodium bentonite on phagocytosis and Newcastle disease antibody formation in broiler chickens during aflatoxicosis. *Res. Vet. Sci.*, 69: 119-122.
- Jacobsen, B.J., K.L. Bowen, R.A. Shelby and U.L. Diener, 1993. Mycotoxins and Mycotoxicoses. Alabama Cooperative Extension System Circular ANR-767. Alabama A & M and Auburn University. Available from: <http://www.aces.edu/department/grain/images/ANR76702.gif>.
- Obayelu, A.E., 2007. Socio-economic analysis of the impacts of avian influenza epidemic on households poultry consumption and poultry industry in Nigeria: empirical investigation of Kwara State. *Livestock Research for Rural Development* 19 (1). <http://www.cipav.org.co/lrrd/lrrd19/1/obay19004.htm>.
- Oguz, H., H.H. Hadimli, V. Kurtoglu and O. Erganis, 2003. Evaluation of humoral immunity of broilers during chronic aflatoxicosis (50 and 100 ppb) and clinoptilolite exposure. *Revue de Medicine Veterinaire*, 154: 482-486.
- Oguz, H. and V. Kutoglu, 2000. Effect of clinoptilolite on fattening performance of broiler chickens during experimental aflatoxicosis. *Poult. Br. Sci.*, 41: 512-517.
- Okiki, P.A., 2007. Possible association of sulphanimide coccidiostats with enhanced susceptibility of chicken to infectious bursal disease. *Nig. J. Anim. Prod.*, 34: 156-162.
- Okiki, P.A. and A.O. Ogbimi, 2008. A typical infectious bursal disease with MDR *Escherichia coli* co-infection among 11-week-old pullets. *ASSET: An Int. J. Agri. Sci., Sci. Environ. Tech.*, B7: 154-163.
- Okiki, P.A. and A.O. Ogbimi, 2010. Low egg production performances associated with multidrug resistant bacteria among some Nigerian commercial layer flock. *Nig. J. Anim. Prod.*, 37: 101-108.
- Ortatali, M., H. Oguz, F. Itatipoglu and M. Karaman, 2005. Evaluation of pathological changes in broilers during chronic aflatoxin (50 and 100 ppb) and clinoptilolite exposure. *Res. Vet. Sci.*, 78: 61-68.
- Santurio, J.M., 2000. Mycotoxins and mycotoxicosis in poultry. *Revista Brasileira de Ciencia Avicola*, 2: 10-12.
- Stoev, S.D., M. Stefanov, S. Denev, B. Radia, A.M. Domijan and M. Peraica, 2004. Experimental mycotoxicosis in chickens induced by ochratoxin A and penicillin acid and intervention with natural plant extract. *Vet. Res. Commun.*, 28: 727-746.
- Thrasia, J.D., 2003. Aflatoxin and Aflatoxicosis. Available from http://www.drthrasher.org/Aflatoxins_and_Aflatoxicosis.html.
- Varga, J. and B. Toth, 2005. Novel strategies to control mycotoxins in feeds: A review. *Acta Veterinaria Hungarica*, 53: 198-2003.
- World Organization for Animal Health (OIE), 2006. Avian Influenza in Nigeria. Disease information 9 March 2006; Vol. 19 No 10. <http://www.Oie.Int/eng/info/hebdo/AIS28.HTM>.